

Case Report

Isolated microalbuminuria as the first clinical presentation of Fabry disease in an adult heterozygous female

Renzo Mignani¹, Paola Preda², Antonio Granata³, Laura Maldini¹, Paola De Giovanni¹, Marcello Montevercchi¹, Angelo Rigotti¹ and Leonardo Cagnoli¹

¹Department of Nephrology and Dialysis, Infermi Hospital, Rimini, ²Institute of Pathology, Bologna University, Policlinico S. Orsola, Bologna and ³Department of Nephrology, Dialysis and Internal Medicine, A.O. Vittorio Emanuele II, Catania, Italy

Correspondence and offprint requests to: Renzo Mignani; E-mail: rmignani@auslrn.net

Abstract

Fabry disease (FD) is a rare X-linked disorder characterized by low or absent activity of the lysosomal enzyme α -glucosidase-A that leads to progressive accumulation of glycosphingolipids in different organs and tissues. Clinical manifestations vary from classic to atypical forms characterized by one prevalent organ involvement, and a renal variant has been described in men but not in women. However, little is known about renal manifestation in females affected by FD. We herein report a case of a 22-year-old female with isolated and persistent microalbuminuria as the only sign of FD. In light of the importance of early recognition and treatment of FD organ damage, this case should call for future studies to determine how to assess organ damage, investigate the existence of a 'renal variant' in FD female patients and determine when best to start enzyme replacement therapy (ERT).

Keywords: Fabry disease; heterozygous; microalbuminuria; proteinuria

Introduction

Fabry disease (FD) is a rare X-linked disorder resulting from a deficient activity of the lysosomal enzyme α -glucosidase A (α -Gal A) that leads to progressive accumulation of glycosphingolipids in several tissues and organs. In the classical form of the disease, renal involvement commonly ensues in the second to third decades of life with overt proteinuria (>300 mg/day) rapidly leading to chronic kidney disease (CKD) and end-stage renal disease (ESRD) [1]. Cardiac and renal atypical variants of the disease with different degrees of organ impairment and the pattern of disease have been described in males [2,3].

In females, the disease presentation may range from a completely asymptomatic status to the classic form of FD [4,5]. Nonetheless, to the best of our knowledge, isolated proteinuria as the first sign of the disease is rare and has been described only in males.

Enzyme replacement therapy (ERT) with agalsidase has been demonstrated to be safe and effective in the improvement of several signs and symptoms of FD in both genders, and it is accepted that the early establishment of ERT might prevent organ damage [6]. Thus, ERT is recommended in the presence of symptoms or organ involvement [7,8]. However, due to the variable presentation and the slower progression of the disease in female patients, the questions of how to detect organ involvement and when to start therapy remain open.

Case report

VV, a 20-year-old female was referred to our clinic in 2006 for a family screening programme due to one uncle, the mother and sister being diagnosed with FD [point mutation I354K (c1061T>A) of the exon 7]. At that time, VV was completely asymptomatic for Fabry disease; leucocyte α -Gal A activity was 19.5 nmol/mg prot/h (normal values 18–50 nmol/mg prot/h), while molecular analysis showed the presence of the pathologic genotype, confirming the heterozygous status of the patient. At this time, clinical evaluation and periodic laboratory tests were unremarkable and no sign of FD could be detected.

Two years later in the first evaluation, urine analysis showed evidence of isolated persistent microalbuminuria (303 mg/L; normal value <30 mg/L) without overt proteinuria or abnormalities in the urinary electrolytes. All laboratory tests were in the normal range including serum creatinine and creatinine clearance (0.7 mg/dL and 92 mL/min, respectively). Similarly, a thorough physical examination of the patient could not elicit any sign of FD or any other disease. Specifically, body mass index, blood pressure and heart rate were 20.5 kg/m², 120/70 mmHg and 68 bpm, respectively. Skin examination was unremarkable for angiokeratomas. Slit-lamp examinations did not reveal either cornea verticillata or cataract. Electrocardiogram and echocardiogram did not show signs of cardiac hypertrophy, systolic–diastolic dysfunction or cardiac valve

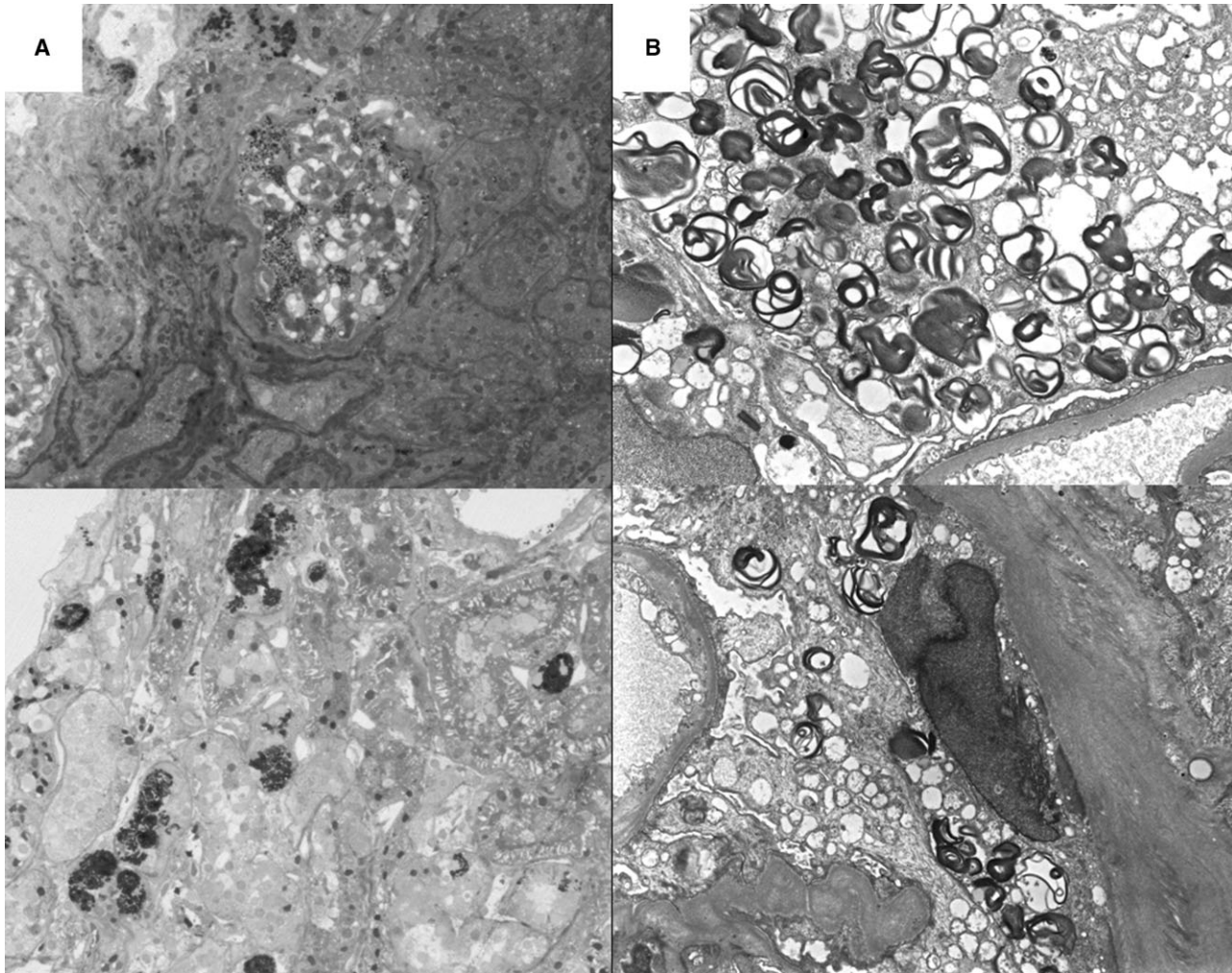


Fig. 1. Renal biopsy of an asymptomatic Fabry female patient presenting with isolated microalbuminuria (303 g/L, 24 h urine collection). Light microscopy (panel A, left) shows numerous vacuolated cells in glomerular tufts (upper panel) and tubuli (lower panel). TEM (panel B, right) shows osmiophilic 'zebra' bodies in podocytes and epithelial cells (upper panel) and endothelial cells (lower panel).

diseases. Audiometric evaluation did not show any evidence of hearing loss. Magnetic resonance imaging (MRI) of the brain was negative for infarctual encephalopathy. Finally, both sweat test and electromyography were normal, with no evidence of sensitive-motor abnormalities.

Due to the presence of isolated and persistent microalbuminuria, we decided to perform a renal biopsy to work out FD nephropathy. Light microscopy revealed numerous vacuolated cells in both glomerular tuft and tubular cells; myelin osmiophilic bodies were also present in glomeruli or between tubules (Figure 1A). Direct immunofluorescent study showed negative staining for IgA, IgM, IgG, C_{1q}, C₃ and C₄. Electron microscopy showed numerous osmiophilic and laminated 'zebra' bodies in podocytes, epithelial and endothelial cells of the glomerular tuft (Figure 1B). Thus, the renal biopsy confirmed that the patient presented FD with the sole involvement of the kidney. Considering the aggressive course of the disease in the family, the optimal blood pressure control and what was suggested by the international guidelines [8] for FD diagnosis and treatment, we started ERT with agalsidase beta (Fabrazyme-Genzyme corp.) at a standard dose of 1 mg/kg every 2 weeks, in

the hope to provide VV with an aetiological rather than antiproteinuric treatment. After 6 months of treatment, the microalbuminuria returned to the normal range (27 mg/L), while no other signs or symptoms of FD could be detected.

Discussion

Several studies have demonstrated that heterozygous patients, due to the Lyon phenomenon, may present different phenotypes ranging from the complete absence of symptoms of the classical form of Fabry disease. To the best of our knowledge, this is the first case reported of an adult heterozygous female in whom isolated microalbuminuria is the first and only presenting sign of both FD and renal involvement. The presentation of FD with a prevalent renal impairment (so-called renal variant) is rare and documented in male patients only [9]. Nonetheless, microalbuminuria has been recently described as a preliminary sign of renal impairment in symptomatic young female patients [10].

It is the authors' opinion that the present case report should question the 'watch and wait' approach and pose several questions on what should be looked at as early signs of FD and when to start ERT [7]. Indeed, the early detection of renal damage appears of paramount importance since the presence of proteinuria and/or CKD at the time of the start of ERT are independent predictors of poor outcome [11]. However, our case should suggest that microalbuminuria might be regarded as an early sign of FD nephropathy. Furthermore, the disappearance of microalbuminuria after 6 months of ERT without antiproteinuric agents [such as angiotensin-converting enzyme inhibitors (ACE-I) or angiotensin receptor blockers (ARBs)] should deserve attention since it might suggest that early intervention might also reverse FD nephropathy. This finding might be of importance if we consider data from the Fabry registry that seem to corroborate the notion that females with FD are undertreated, as only 33.8% of females currently included in the Fabry Registry are on ERT [5].

In summary, this case suggests that the kidney may be the first, and sometimes only, organ damaged by FD in heterozygous female patients and that isolated and persistent microalbuminuria instead of proteinuria should be regarded as an early marker of FD nephropathy and an indication for ERT. Nonetheless, future studies should investigate the existence of a 'renal variant,' as well as how to detect organ damage and when to start an early treatment in female FD patients.

Conflict of interest statement. R.M. received educational grants and travel grants from Genzyme Corporation.

References

1. Branton M, Schiffmann R, Kopp J. Natural history and treatment of renal involvement in Fabry disease. *J Am Soc Nephrol* 2002; 13(Suppl 2): S139–S143
2. Nakao S, Kodama C, Takenaka T *et al.* Fabry disease: detection of undiagnosed hemodialysis patients and identification of a 'renal variant' phenotype. *Kidney Int* 2003; 64: 801–807
3. von Scheidt W, Eng C, Fitzmaurice T *et al.* An atypical variant of Fabry's disease with manifestations confined to the myocardium. *N Engl J Med* 1991; 324: 395–399
4. Wang R, Lelis A, Mirocha J *et al.* Heterozygous Fabry women are not just carriers, but have a significant burden of disease and impaired quality of life. *Genet Med* 2007; 9: 34–45
5. Wilcox W, Oliveira J, Hopkin R *et al.* Females with Fabry disease frequently have major organ involvement: lessons from the Fabry Registry. *Mol Genet Metab* 2008; 93: 112–128
6. Breunig F, Weidemann F, Strotmann J *et al.* Clinical benefit of enzyme replacement therapy in Fabry disease. *Kidney Int* 2006; 69: 1216–1221
7. Eng C, Germain D, Banikazemi M *et al.* Fabry disease: guidelines for the evaluation and management of multi-organ system involvement. *Genet Med* 2006; 8: 539–548
8. Ortiz A, Oliveira J, Wanner C *et al.* Recommendations and guidelines for the diagnosis and treatment of Fabry nephropathy in adults. *Nat Clin Pract Nephrol* 2008; 4: 327–336
9. Fervenza F, Torra R, Lager D. Fabry disease: an underrecognized cause of proteinuria. *Kidney Int* 2008; 73: 1193–1199
10. Tondel C, Bostad L, Hirth A *et al.* Renal biopsy findings in children and adolescents with Fabry disease and minimal albuminuria. *Am J Kidney Dis* 2008; 51: 767–776
11. Germain D, Waldek S, Banikazemi M *et al.* Sustained, long-term renal stabilization after 54 months of agalsidase {beta} therapy in patients with Fabry disease. *J Am Soc Nephrol* 2007; 18: 1547–1557

Received for publication: 9.3.09; Accepted in revised form: 14.7.09