

Infected Groin (Graft/Patch): Managed with Sartorius Muscle Flap

Dong Yeon Ryu¹, Hyuk Jae Jung¹, Venkaesh G. Ramaiah², Julio A. Rodriguez-Lopez², and Sang Su Lee¹

¹Division of Vascular and Endovascular, Department of Surgery, Pusan National University Yangsan Hospital, Yangsan, Korea,

²Arizona Heart Institute, Phoenix, AZ, USA

Purpose: The purpose of this study was to review the natural history, clinical outcome and safety in patients undergoing sartorius muscle flap (SMF) for groin infection, including lymphocele.

Materials and Methods: We retrospectively reviewed the records of patients who underwent SMF in a single center between 2000 and 2009.

Results: Thirty patients (17 male, 13 female) underwent SMF for groin infection, which included infections of 22 artificial femoral bypass grafts (including 2 cryoveins) and 5 common femoral patch grafts, and 3 lymphocele infections (2 cardiac catheterizations and 1 penile cancer lymph node dissection). Wound isolates were most commonly Gram-positive organisms (n=22) with Gram-negative isolates and mixed infections accounting for 4 and 3 cases, respectively. In 9 patients there was no growth of organisms. Adjunctive wound vacuum-assisted wound closure therapy was performed in 18 patients. Follow-up duration ranged from 8 days to 56 months (mean 14.1 months) after SMF. Reoperation was performed in 3 patients due to wound bleeding (n=1) and reinfection (n=1). One patient underwent graft excision with external bypass operation. There was 1 mortality case due to sepsis during the study period.

Conclusion: We found that muscle flap surgery provides successful single-intervention therapy for groin infections including lymphocele. Graft ligation or aggressive excision with bypass surgery should be reserved for patients requiring rapid control of sepsis for lifesaving.

Key Words: Bypass surgery, Sartorius muscle flap, Groin infection, Transplants, Patch

Received September 14, 2015

Revised December 7, 2015

Accepted December 14, 2015

Corresponding author: Sang Su Lee

Division of Vascular and Endovascular,
Department of Surgery, Pusan National
University Yangsan Hospital, 20 Geumo-
ro, Mulgeum-eup, Yangsan 50612, Korea
Tel: 82-55-360-2124

Fax: 82-55-360-2154

E-mail: phoenixdr@naver.com

Conflict of interest: None.

Copyright © 2016, The Korean Society for Vascular Surgery

This is an Open Access article distributed under the terms of the Creative Commons Attribution Non-Commercial License (<http://creativecommons.org/licenses/by-nc/4.0>) which permits unrestricted non-commercial use, distribution, and reproduction in any medium, provided the original work is properly cited.

Vasc Spec Int 2016;32(1):11-16 • <http://dx.doi.org/10.5758/vsi.2016.32.1.11>

INTRODUCTION

Groin infection following arterial revascularization procedures is relatively uncommon; however, it is a potentially lethal complication in vascular surgery. The literature-reported incidence may vary between 0.7% to 7% of lower extremity open revascularization procedures

[1-3]. In 1980, sartorius muscle flap (SMF) to treat groin infections was first reported by Méndez Fernández et al. [4] and has been shown to be successful in the management of vascular groin infections [5]. Current treatments for groin infection include debridement as well as broad spectrum antibiotics, SMF, and use of a vacuum-assisted wound closure (VAC) device (KCI International, San Antonio, TX,

USA) [6].

In this study, we retrospectively analyzed the natural history, clinical outcome and safety of SMF in patients with groin infection.

MATERIALS AND METHODS

From September 2000 to September 2009, a retrospective analysis was performed for all patients who underwent SMF in Pusan National University Yangsan Hospital. Charts were retrospectively reviewed for patient demographics, comorbidities, clinical findings, initial vascular procedures, duration between initial operation and SMF, bacteriologic variables, use of VAC, length of stay in hospital, duration of follow-up, reintervention rates, and mortality. An early infection was defined as an infection occurring within 1 month of the revascularization procedure. A late infection was defined as one occurring after ≥ 1 month. Early infection was found in 11 cases and late infection in 10 cases (duration ranging from 35 days to 12 years).

When patients were diagnosed as infection (typically defined as the presence of erythema, discharge, fever, leukocytosis, wound dehiscence, or positive culture, or at the discretion of the primary vascular surgeon), all wounds were extensively opened and irrigated with sodium chloride solution. Deep swab, tissue or biofilm culture samples were taken and analyzed. Antibiotic sensitivity tests were also obtained. The graft was replaced with autogenous vein if required. The SMF was indicated for covering the exposed graft, and for treatment of uncontrolled lymphocele and bleeding (Fig. 1). Empirical intravenous broad-spectrum antibiotics (vancomycin plus piperacillin/tazobactam, or ciprofloxacin in those with penicillin allergy) were initially started. After detection of the specific microbiological organisms, culture-directed antibiotics were administered intravenously for 8 weeks. We tried to preserve the infected graft with SMF and antibiotic treatment whenever possible.

RESULTS

Thirty SMFs were performed in 30 patients. Patients ranged in age from 40 to 84 years (mean, 65.05). Seventeen patients were male. Patient demographics and comorbidities are listed in Table 1, and initial bypass operations, duration between initial operation and SMF, clinical findings, microbacteriology, use of VAC, length of hospital stay, and duration of follow-up are as listed in Table 2. Twenty-four patients presented with soft tissue infections surrounding the graft, 9 with sinus tracts, 5 with perigraft fluid collection, 2 with systemic sepsis, 4 with bleeding and pseudoaneurysm, and 10 with fever and malaise. *Staphylococcus* species (19 cases) were the most common pathogen. One patient had growth of *Acinetobacter baumannii*: this patient finally died due to septic condition and necrotizing fasciitis. Three patients had growth of mixed Gram-positive and negative organisms while 9 patients had no growth of bacteria.

VAC therapy was used in 20 patients after SMF (Fig. 2). The mean duration of VAC therapy was 8.1 days (range,

Table 1. Patient demographics with comorbidities (n=30)

Characteristic	Data
Male/female	17/13 (56.6/43.3)
Age (y)	65.05 (40-84)
Site, right/left	15/15 (50.0/50.0)
Atherosclerosis	28 (93.3)
Coronary artery disease	18 (60.0)
Hypertension	21 (70.0)
Diabetes mellitus	30 (100)
Tobacco use	22 (73.3)
Current smoking	8 (26.7)
Chronic obstructive pulmonary disease	6 (20.0)
End stage renal disease	4 (13.3)

Values are presented as number (%) or median (range).

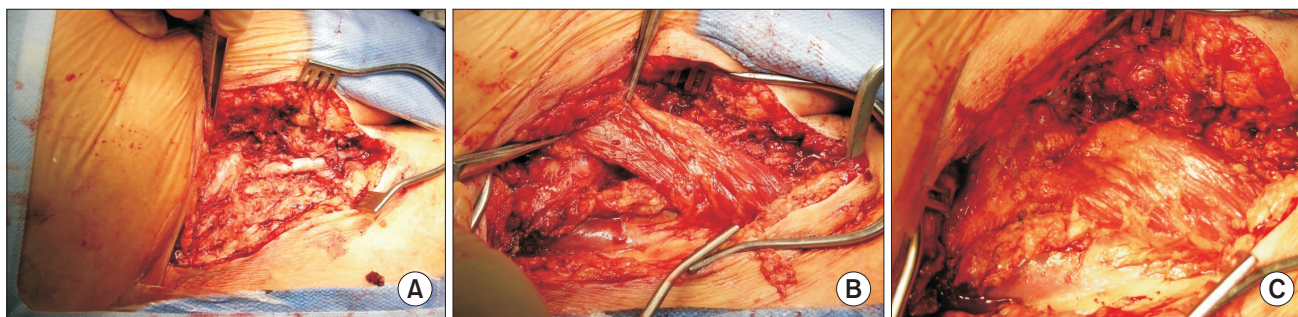


Fig. 1. (A) Groin wound infection with exposed graft at the base. (B) The sartorius muscle flap (SMF) in its detached form with its proximal insertion. (C) The SMF covering the exposed graft.

Table 2. Summary of the patients and graft infections

Patient No.	1st operation	Duration ^a (day)	Clinical finding	Microbiology	VAC	Hospital stay (day)	Follow-up (mo)
1	Fem-Pop (G)	18	Foul odor	<i>Escherichia coli</i>	Yes	12	30
2	CFA Patch (B)	28	Bleeding, swelling	<i>Staphylococcus aureus</i>	Yes	20	4
3	Aorto-Bifem (G)	70	Pain, swelling	No growth	No	8	22
4	Fem-Tib (G)	23	Pain, swelling	MRSA	Yes	7	14
5	Fem-Pop (G)	161	Serous discharge	<i>Pseudomonas aeruginosa</i>	Yes	11	12
6	CFA Patch (H)	23	Serous discharge	No growth	No	2	5
7	Fem-Fem (G)	21	Fever, pain, pus	No growth	Yes	87	12
8	Fem-Fem (H)	41	Fever, chill, pus	<i>Staphylococcus aureus</i>	No	6	11
9	Fem-Fem (H)	11	Pain, pus	MRSA	Yes	11	16
10	Fem-Tib (C)	385	Pain, mass	<i>Streptococcus agalactiae</i>	Yes	6	15
11	CFA Patch (A)	60	Pain, pus	No growth	No	7	8
12	Fem-Pop (G)	35	Pain, pus	<i>Staphylococcus aureus</i>	Yes	21	20
13	Axillo-Fem (G)	705	Pain, pus	<i>Pseudomonas aeruginosa</i>	Yes	2	12
14	Fem-Tib (C)	15	Abscess, sepsis	<i>Staphylococcus aureus</i> , <i>Sphigomonas paucimobilis</i> , <i>Klebsiella pneumoniae</i>	Yes	6	7
15	Fem-Fem (G)	23	Serous discharge	No growth	Yes	14	13
16	Fem-Pop (G)	4,322	Sinus tract, pus	MRSA	No	7	9
17	Aorto-Bifem (D)	40	Pus, pulsating mass	<i>Staphylococcus aureus</i>	Yes	5	56
18	Penile cancer lymph node dissection	62	Bleeding	No growth	No	12	39
19	Cardiac stenting	44	Fever, chill	<i>Staphylococcus epidermidis</i> , <i>MRSA</i> , <i>Enterococcus faecalis</i>	No	11	1
20	Fem-Pop (G)	44	Fever, chill	<i>Staphylococcus aureus</i>	Yes	6	15
21	Fem-Pop (G)	20	Bleeding	No growth	No	8	53
22	CFA Patch (H)	14	Pus	MRSA	Yes	5	4
23	Cardiac stenting	9	Serous discharge	<i>Enterococcus faecalis</i> , <i>Pasteurella multocida</i>	Yes	7	3
24	Fem-Fem (H)	45	Serous discharge	No growth	Yes	6	3
25	Fem-Fem (H)	24	Pus	MRSA	Yes	5	3
26	Fem-Fem (D)	48	Redness, pus	MRSA	Yes	8	11
27	Fem-Tib (C)	14	Pseudoaneurysm	<i>Staphylococcus aureus</i>	No	7	8
28	Fem-Fem (G)	13	Sepsis	<i>Acinetobacter baumannii</i>	No	22	Death
29	CFA Patch (G)	120	Serous discharge	No growth	No	5	8
30	Fem-Tib (G)	3	Fever, chill	<i>Staphylococcus aureus</i>	No	8	41

VAC, vacuum-assisted wound closure; Fem, femoral; Pop, popliteal; G, Goretex graft; CFA, common femoral artery; B, Bovine patch; Bifem, bifemoral; Tib, tibial; MRSA, methicillin-resistant *Staphylococcus aureus*; H, Hemashield graft; C, Cryovein; A, Autogenous vein; D, Dacron graft.

^aDuration between initial operation and sartorius muscle flap.

2-20 days) and mean hospital stay was 10.6 days (range, 2-87 days).

In 16 out of 18 (88.9%) cases, a secondary closure of the wound was successfully achieved with complete healing. Complications during VAC therapy include one case of wound bleeding and one case of reinfection. The mean duration of follow-up was 14.1 months (range, 8 days-56 months) after SMF, survival rate was 97%, limb salvage rate

was 97%, and reoperation was done in 3 cases (10%). There were 2 morbidity cases and 1 mortality case. These patients are reported as follows:

1) Patient 9

A 68-year-old male presented with coronary heart disease, hypertension and heavy smoking. He underwent

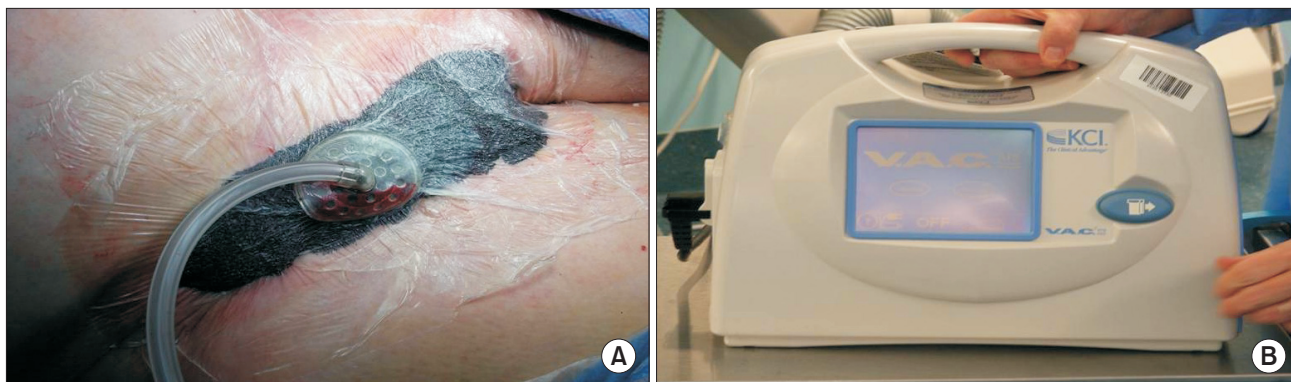


Fig. 2. (A) After vacuum-assisted wound closure (VAC) dressing, a 2.5 cm hole was cut into the drape over which a tube disc was applied. (B) VAC pressure was initiated at 125 mmHg continuously. The wound was examined 12 to 24 hours.

revascularization with femoro-femoral bypass using a Dacron graft. He subsequently showed foul odor discharge with fever and chills after eleven days of operation. In the reoperation, wide wound debridement and irrigation was done, the SMF was turned over to cover the wound, and VAC was applied. After the reoperation, bleeding was detected at the bypass graft site requiring a second-look operation. The patient underwent re-myoplasty with vein patch grafting. He was discharged without any complications and free from infection during a follow-up period of 16 months.

2) Patient 17

A 44-year-old woman presented with peripheral arterial disease and hypertension, and was a current smoker. She underwent aorto-bifemoral bypass operation using a Dacron graft. Forty days later, she had pus discharge and a pulsating mass in the groin. The patient's groin was cleaned, the SMF was turned over to cover the wound and VAC was placed. After 85 days, the patient's wound was found to be swollen, with pain and with a pulsating mass. We found infected and aneurysmal changes in the anastomosis site. She underwent evacuation of the wound and ligation of the groin vessel. After 3 days, she was operated by axillo-popliteal bypass with polytetrafluoroethylene (PTFE) graft. Eventually she improved and was disease-free during her last follow-up at 56 months.

3) Patient 28

A 40-year-old female presented with diabetes mellitus (DM), end stage renal disease (ESRD), hypertension, coronary artery disease, and poor general condition. She underwent left femoro-femoral bypass using a PTFE graft. The operation time was 5 hours due to uncontrolled

bleeding. She presented 13 days later with purulent material in the left groin wound. Wound cultures grew *Acinetobacter baumannii*. The patient subsequently underwent wide debridement with SMF and was treated with massive antibiotics. After 4 days, the sartorius flap was found to be necrotic, therefore the extensive necrotic tissue and the graft were removed, and a transtibial amputation was done. Unfortunately after 10 days, she died due to sepsis with necrotizing fasciitis.

DISCUSSION

In the previous era, the treatment of groin graft infections was total excision of the graft with massive debridement and extra-vascular reconstruction. Limb loss and mortality rates were reported as 10%-79% and 9%-58%, respectively [3,5]. In 1963, Carter et al. [7] reported in a seven-patient case series the feasibility of a conservative approach in which the original infected Dacron grafts were retained and aggressive wound debridement, antimicrobial therapy, and healing by secondary intention were performed. The authors reported improved rates of graft salvage and decreased amputation and mortality rates compared with traditional treatment methods. The SMF to treat prosthetic graft infections was first reported in 1980 [4]. According to a reported series during a 20-year period assessing outcome using SMF, the limb salvage rate was 71%-94% [5].

The sartorius muscle is supplied by segmental branches of the superficial femoral artery (SFA, type IV circulation pattern, segmental supply). Therefore, vascular surgeons might hesitate to use the proximal SMF in patients with an occluded SFA [8]. It also lacks bulk and has a limited arc rotation, making it suboptimal for large wounds. In contrast, the rectus femoralis muscle flap can be used in larger groin infections, since the rectus femoralis muscle provides significant bulk and good arc rotation,

but it also needs a longer incision in the thigh [9]. Perler et al. [10] suggested that rotational muscle flaps can be successfully used for this purpose, and has been reported to be particularly effective in early groin infections. In our case, SMFs with VAC therapy for groin infections showed acceptable results in large open wounds.

The microbial spectrum of groin infections in our study was similar to other reports in the literature [11,12]. Twenty one of 30 patients showed positive culture. An “early” infection was defined as an infection occurring within 30 days of the revascularization operation. A “late” infection was defined as one occurring after 30 days. Dosluoglu et al. [13] reported 26 early groin infections versus 7 late infections. Our case presented 11 early groin infections versus 10 late infections. The duration of late infections varied from 41 days to 4,322 days.

Calligaro et al. [14] reported only 40% graft salvage when the offending organism was *Pseudomonas*. *Pseudomonas* infection was associated with 60% limb loss in a series reported by Seify et al. [3] and Dosluoglu et al. [13] recommended graft removal in early *Pseudomonas* groin infections with exposed grafts. In contrast with previous reports, we underwent SMF with VAC in 2 patients who had pseudomonas infection with success. Some authors also observed similar good outcome with *Pseudomonas* infection [10,15].

Infections due to Gram-negative bacteria such as *Acinetobacter baumannii* are very virulent. Our patient with this infection and with poor general status (DM, ESRD, coronary heart disease, hypertension) progressed to an extreme septic condition. Therefore, the need for accurate perioperative microbiologic testing from wound swabs and graft specimens must be highlighted. In our opinion, patients with suspected or proven surgical site infection with *Acinetobacter baumannii* should be considered for aggressive treatment including graft removal with reconstruction or amputation. Engin et al. [16] reported the effectiveness of 16 different surgical methods for the treatment of groin vascular infections, including lateral femoral bypass in 5 cases, obturator bypass in 5, revascularization with homograft in 5, and femoro-femoral bypass in 1. Nevertheless, excellent limb-salvage rates (97%) and survival rates (97%) were achieved in our cases.

The proximal SMF as a successful single intervention therapy for groin lymphatic complications should also be noted [17]. Soots et al. [18] reported a group of 12 patients that were successfully treated for persistent lymphatic

wound drainage after vascular surgery in the groin. In our institution, nine patients were treated by wound revision with SMF and the lymphatic drainage ceased. Complete wound healing was achieved without complications.

VAC therapy can be a useful adjunct to the management of vascular groin infections and dehiscence, but it must be used with caution [6]. In a smaller series of 26 early (<30 day) vascular groin infections, Dosluoglu et al. [2] concluded that debridement, antibiotics and VAC therapy may be an effective treatment modality for groin wounds in patients who are too medically unstable to undergo muscle flap closure. Kotsis and Lioupis [19] also reported on the use of adjunctive VAC therapy in vascular graft infections as an effective alternative to routine muscle flap closure. We had one early bleeding and one unhealed wound in 20 patients with vascular groin infections treated by VAC. VAC can be used in patients with exposed grafts/suture lines, but close monitoring is necessary for possible bleeding, which is likely due to residual infection at the anastomotic line.

Several patient characteristics (obesity, smoking history), past medical and surgical history (DM, ESRD, prior groin surgery), and physical examination findings (groin wound drainage) have been shown to increase the risk of surgical site infections [20-22]. Muscle transposition flaps (total 29 flaps: 21 sartorius, 6 rectus femoris, and 2 gracilis) are an effective means of graft salvage in the setting of groin wound complications following lower extremity revascularization and should be considered for infection prophylaxis in high-risk patients [9]. Furthermore, Fischer et al. [23] reported prophylactic muscle flaps in vascular surgery. The SMF is an ideal prophylactic flap in high-risk groin surgery patients because of its proximity, easy mobility, effectiveness, and low complication rate.

CONCLUSION

Our data demonstrated that SMFs for the treatment of groin wound infection, including lymphoceles, after massive debridement and broad spectrum antibiotics are associated with excellent limb-salvage rates of 97% and survival rates of 97%. Its use for pseudomonas infections is still relatively controversial. VAC therapy can be useful in patients with exposed grafts/suture lines, but close monitoring is necessary for possible bleeding. Finally, SMF treatment of groin infections should be approached early and based on patient general condition.

REFERENCES

- 1) Illig KA, Alkon JE, Smith A, Rhodes JM, Keefer A, Doyle A, et al. Rotational muscle flap closure for acute groin wound infections following vascular surgery. *Ann Vasc Surg* 2004;18:661-668.
- 2) Dosluoglu HH, Schimpf DK, Schultz R, Cherr GS. Preservation of infected and exposed vascular grafts using vacuum assisted closure without muscle flap coverage. *J Vasc Surg* 2005;42:989-992.
- 3) Seify H, Moyer HR, Jones GE, Busquets A, Brown K, Salam A, et al. The role of muscle flaps in wound salvage after vascular graft infections: the Emory experience. *Plast Reconstr Surg* 2006;117:1325-1333.
- 4) Méndez Fernández MA, Quast DC, Geis RC, Henly WS. Distally based sartorius muscle flap in the treatment of infected femoral arterial prostheses. *J Cardiovasc Surg (Torino)* 1980;21:628-631.
- 5) Graham RG, Omotoso PO, Hudson DA. The effectiveness of muscle flaps for the treatment of prosthetic graft sepsis. *Plast Reconstr Surg* 2002;109:108-113.
- 6) Sumpio BE, Allie DE, Horvath KA, Marston WA, Meites HL, Mills JL, et al. Role of negative pressure wound therapy in treating peripheral vascular graft infections. *Vascular* 2008;16:194-200.
- 7) Carter SC, Cohen A, Whelan TJ. Clinical experience with management of the infected dacron graft. *Ann Surg* 1963;158:249-255.
- 8) Mathes SJ, Nahai F. *Reconstructive surgery: principles, anatomy and technique*. New York: Churchill Livingstone; 1997.
- 9) Reiffel AJ, Henderson PW, Karwowski JK, Spector JA. An interdisciplinary approach to the prevention and treatment of groin wound complications after lower extremity revascularization. *Ann Vasc Surg* 2012;26:365-372.
- 10) Perler BA, Kolk CA, Manson PM, Williams GM. Rotational muscle flaps to treat localized prosthetic graft infection: long-term follow-up. *J Vasc Surg* 1993;18:358-364.
- 11) Homer-Vanniasinkam S. Surgical site and vascular infections: treatment and prophylaxis. *Int J Infect Dis* 2007;11 Suppl 1:S17-S22.
- 12) Töpel I, Betz T, Uhl C, Steinbauer MG. The impact of superficial femoral artery (SFA) occlusion on the outcome of proximal sartorius muscle transposition flaps in vascular surgery patients. *J Vasc Surg* 2011;53:1014-1019.
- 13) Dosluoglu HH, Loghmanee C, Lall P, Cherr GS, Harris LM, Dryjski ML. Management of early (<30 day) vascular groin infections using vacuum-assisted closure alone without muscle flap coverage in a consecutive patient series. *J Vasc Surg* 2010;51:1160-1166.
- 14) Calligaro KD, Veith FJ, Schwartz ML, Goldsmith J, Savarese RP, Dougherty MJ, et al. Selective preservation of infected prosthetic arterial grafts. Analysis of a 20-year experience with 120 extracavitary-infected grafts. *Ann Surg* 1994;220:461-469; discussion 469-471.
- 15) Morasch MD, Sam AD 2nd, Kibbe MR, Hijjawi J, Dumanian GA. Early results with use of gracilis muscle flap coverage of infected groin wounds after vascular surgery. *J Vasc Surg* 2004;39:1277-1283.
- 16) Engin C, Posacioglu H, Ayik F, Apaydin AZ. Management of vascular infection in the groin. *Tex Heart Inst J* 2005;32:529-534.
- 17) Shermak MA, Yee K, Wong L, Jones CE, Wong J. Surgical management of groin lymphatic complications after arterial bypass surgery. *Plast Reconstr Surg* 2005;115:1954-1962.
- 18) Soots G, Mikati A, Warembourg H Jr, Watel A, Noblet D. Treatment of lymphorrhea with exposed or infected vascular prosthetic grafts in the groin using sartorius myoplasty. *J Cardiovasc Surg (Torino)* 1988;29:42-45.
- 19) Kotsis T, Lioupis C. Use of vacuum assisted closure in vascular graft infection confined to the groin. *Acta Chir Belg* 2007;107:37-44.
- 20) Bandyk DF. Vascular surgical site infection: risk factors and preventive measures. *Semin Vasc Surg* 2008;21:119-123.
- 21) Brothers TE, Robison JG, Elliott BM. Predictors of prosthetic graft infection after infrainguinal bypass. *J Am Coll Surg* 2009;208:557-561.
- 22) Derksen WJ, Verhoeven BA, van de Mortel RH, Moll FL, de Vries JP. Risk factors for surgical-site infection following common femoral artery endarterectomy. *Vasc Endovascular Surg* 2009;43:69-75.
- 23) Fischer JP, Nelson JA, Mirzabeigi MN, Wang GJ, Foley PJ 3rd, Wu LC, et al. Prophylactic muscle flaps in vascular surgery. *J Vasc Surg* 2012;55:1081-1086.