

OnabotulinumtoxinA Treatment for Moderate to Severe Forehead Lines: A Review

Koenraad De Boule, MD*

Alastair Carruthers, MD†

Nowell Solish, MD‡

Jean Carruthers, MD†

Wolfgang G. Philipp-Dormston,

MD§¶

Steven Fagien, MD||

Sara Sangha, PhD**

Michael Silberberg, MD, MBA††

Cheri Mao, MS‡‡

Background: With onabotulinumtoxinA approved for the treatment of glabellar and crow's feet lines and, most recently, for forehead lines (FHL), it is possible to simultaneously treat multiple areas of the upper face that are of high concern and treatment priority for aesthetically oriented individuals. This review aims to present key insights on the use of onabotulinumtoxinA for the treatment of moderate to severe FHL.

Methods: Double-blind, placebo-controlled registration trials of onabotulinumtoxinA for the treatment of FHL were included. Using findings from 3 such published studies, we discuss key concepts and clinical experience for the treatment of moderate to severe FHL with onabotulinumtoxinA (20 U in the frontalis and 20 U in the glabellar complex, with/without 24 U in crow's feet lines), including injection pattern, dose selection, efficacy and safety data, and considerations for patient selection.

Results: Across the 2 pivotal phase 3 studies, responder rates on investigator- and subject-assessed measures of appearance of FHL severity were significantly higher with onabotulinumtoxinA versus placebo for the treatment of FHL at day 30 ($P < 0.0001$), and results were maintained through 3 cycles of onabotulinumtoxinA.

Conclusions: OnabotulinumtoxinA treatment also resulted in high patient satisfaction rates. The incidence of eyebrow and of eyelid ptosis was low, and no new safety signals were detected. OnabotulinumtoxinA is safe and effective and an appropriate option for patients with moderate to severe FHL encountered in clinical practice. (*Plast Reconstr Surg Glob Open* 2020;8:e2669; doi: [10.1097/GOX.0000000000002669](https://doi.org/10.1097/GOX.0000000000002669); Published online 18 March 2020.)

INTRODUCTION

OnabotulinumtoxinA has demonstrated safety and efficacy for the aesthetic treatment of facial lines in the upper face, leading to its approval by the US Food and

Drug Administration for the treatment of forehead lines (FHL) in October 2017; prior approvals were obtained for the treatment of glabellar lines (GL) in 2002 and bilateral crow's feet lines (CFL) in 2013.¹⁻⁵ Dynamic upper facial lines develop due to repeated movement of the underlying muscles and may progress to static lines that can be

From the *Aalst Dermatology Clinic, Aalst, Belgium; †Department of Dermatology, University of British Columbia, Vancouver, British Columbia, Canada; ‡Department of Surgical Dermatology, University of Toronto, Toronto, Ontario, Canada; §Hautzentrum Köln/Cologne Dermatology, Cologne, Germany; ¶Department of Dermatology, Faculty of Health, Witten/Herdecke University, Witten, Germany; ||Aesthetic Eyelid Plastic Surgery, Boca Raton, Fla.; **Medical Affairs, Aesthetics, Allergan plc, Irvine, Calif.; ††Medical Affairs, Aesthetics, Allergan plc, Marlborough, Buckinghamshire, United Kingdom; and ‡‡Clinical Research & Development, Dermatology, Allergan Plc, Irvine, Calif.

Received for publication November 7, 2019; accepted January 8, 2020.

K.D.B. and A.C. contributed equally to the preparation of this article.

NCT02261493 and NCT02261467

Copyright © 2020 The Authors. Published by Wolters Kluwer Health, Inc. on behalf of The American Society of Plastic Surgeons. This is an open-access article distributed under the terms of the [Creative Commons Attribution-Non Commercial-No Derivatives License 4.0 \(CCBY-NC-ND\)](https://creativecommons.org/licenses/by-nc-nd/4.0/), where it is permissible to download and share the work provided it is properly cited. The work cannot be changed in any way or used commercially without permission from the journal.

DOI: [10.1097/GOX.0000000000002669](https://doi.org/10.1097/GOX.0000000000002669)

Disclosures: Dr. De Boule has served as a paid consultant, an advisory board member, and on a speakers' bureau for, and has received honoraria and a research grant from, Allergan plc. Dr. A. Carruthers serves as a consultant and investigator for Allergan plc, Alphaeon, Merz Aesthetics, and Revance. Dr. J. Carruthers has served as a paid consultant and received honoraria and a research grant from Allergan plc, Alphaeon, Bonti, Merz Aesthetics, and Revance Therapeutics, is an author and assistant editor for *Dermatologic Surgery*, and receives royalties from editorial and authorship work on *UptoDate*, an Elsevier Textbook series. Dr. Fagien serves as an investigator for Allergan plc. Drs. Mao, Sangha, and Silberberg are employees of Allergan plc and may own stock or options in the company. Dr. Philipp-Dormston has served as a paid consultant and has received research grants from Allergan plc and Galderma. Dr. Solish has served as a paid consultant, an advisory board member, and on speakers' bureaus for Allergan plc, Galderma, and Revance Therapeutics. The opinions expressed in this article are those of the authors. The authors received no honoraria related to the development of this article. All products mentioned in article: Botox (Allergan plc; Dublin, Ireland).

observed at rest.^{6,7} A large, multinational facial aging study showed that static FHL can develop at a relatively young age, earlier than GL and CFL, and that their prevalence increases over time.^{8,9} However, large variability exists among individuals as multiple factors affect the development of FHL, including age, race, gender, and sun exposure.^{6,8-10} Two studies found that static FHL were of high concern and a treatment priority for aesthetically oriented men and women.^{11,12} Approval of onabotulinumtoxinA for the treatment of FHL associated with frontalis muscle activity was based on 2 pivotal phase 3 clinical trials in subjects with moderate to severe FHL (in both studies 142 and 143) and with concurrent treatment of CFL (in study 143 only).^{3,5} The purpose of this review is to present key clinical trial data supporting the use of onabotulinumtoxinA to treat FHL and to place these results in the context of clinical practice.

METHODS

Studies included in this summary were required to be double-blind, placebo-controlled registration trials of onabotulinumtoxinA used for the treatment of FHL, published in English, and conducted by Allergan plc or its business to support product licensure. Using findings from qualified published studies, we aimed to describe key concepts that are critical for understanding the use of onabotulinumtoxinA for the treatment of moderate to severe FHL. These include putting into perspective the anatomy of the eyebrow elevator depressor complex, which guided the selection of the recommended injection pattern, and summarizing data from the dose-ranging trial that was the basis for the recommended FHL dose.¹³⁻¹⁵ We also review the pooled efficacy and safety data from 2 pivotal phase 3 clinical studies (NCT02261493 and NCT02261467) and discuss considerations for tailoring treatment to individual patients in clinical practice.^{3,5}

RESULTS

Three published studies qualified for inclusion.^{3,5,15} Each of the studies complied with the principles of the Declaration of Helsinki and were approved by an institutional review board before study initiation. All participants enrolled in the individual studies had moderate to severe, bilaterally symmetrical FHL at maximum elevation, based on validated, 4-grade Facial Wrinkle Scales (0 = none, 1 = mild, 2 = moderate, and 3 = severe) with accompanying Allergan photograph guides.

Injection Pattern Based on Anatomical Considerations

The recommended injection pattern for the treatment of FHL is derived from an understanding of the functional anatomy of the muscles in the forehead (Fig. 1), as the muscles of facial expression act in concert and not in isolation.¹ For example, the frontalis muscle raises the brow, while the depressor muscles of the glabellar complex (ie, orbicularis oculi, corrugator supercilii, procerus, and depressor supercilii) move the brow medially and downward.¹⁶⁻¹⁸ To maintain this dynamic interaction and normal brow position, the frontalis and

opposing corrugators and procerus of the glabellar complex should be treated together.^{16,19,20} Based on these considerations, the forehead injections for the phase 3 studies utilized a 10-point injection pattern in the frontalis muscle and glabellar complex to treat FHL, as in previous clinical studies.^{14,16} Proper injection placement can help prevent asymmetric forces between forehead muscles and mitigate the potential for undesired brow depression or elevation.¹⁹

Potential variations in frontalis anatomy should be considered for the location and depth of the injection points in the forehead. Thus, it is important to consider individual differences in symmetry, functionality, height, and width of the frontalis muscle. In general, there is greater frontalis mass in men compared with women.^{16,21,22} Performing a manual exam of the frontalis muscle at rest and during animation allows the physician to account for the wide variation in frontalis anatomy and strength and enables the identification of the upper margin of the frontalis to guide injection placement.^{4,17} Similarly, potential variations of glabellar contraction patterns in subjects should be accounted for to best determine the location of glabellar injection points. Altogether, a deeper understanding of the variations of the frontalis muscle and the glabellar complex will allow for a more effective, natural treatment outcome.²³

Dose Selection Based on a Dose-ranging Clinical Trial

Several smaller studies evaluated the efficacy and safety of onabotulinumtoxinA for the treatment of FHL across a wide range of doses (from 8 U to 20 U).^{13,14,24} These studies served as the basis for a prospective, randomized, double-blind, placebo-controlled dose-ranging clinical trial.¹⁵ The doses selected represented the typical dose range used in clinical practice for the frontalis (10 U or 20 U) and the 20 U approved dose for GL.^{15,25} Subjects in the study (N = 175) were randomized 1:1:1 to receive either 30 U (n = 59) or 40 U (n = 57) of onabotulinumtoxinA or placebo (n = 59), and the study treatment was administered as 10 injections: 5 in the frontalis area (10 U or 20 U) and 5 in the glabellar area (20 U).¹⁵ Most subjects were females (86.9%) and white (91.4%), and the mean (SD) age at baseline was 46.8 (9.8) years.¹⁵ The proportion of subjects with severe FHL at baseline was assessed as 50.9% when rated by both the subjects and investigators.¹⁵ No between-group differences in demographics, FHL severity at maximum eyebrow elevation, or patient-reported outcomes were observed at baseline, except for subject-assessed severity of GL appearance. For this measure, comparisons showed a possible difference at baseline for onabotulinumtoxinA 30 U versus placebo ($P < 0.05$).¹⁵

The coprimary efficacy measures were achieving a rating of none or mild in investigator and subject assessments of FHL severity at maximum eyebrow elevation at day 30 using the Facial Wrinkle Scale with Photonumeric Guide (FWS), a validated 4-point facial line severity scale (from 0 = none to 3 = severe).¹⁵ The respective percentages of subjects in the 40 U and 30 U groups who achieved the coprimary efficacy endpoint on day 30 were 91.2% and 86.4% by investigator assessment ($P < 0.001$ vs placebo)

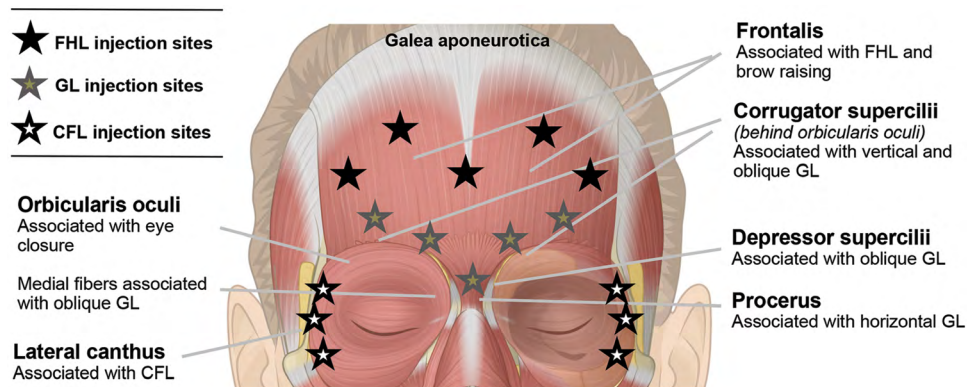


Fig. 1. Injection patterns used in studies 142 and 143.^{3,5}

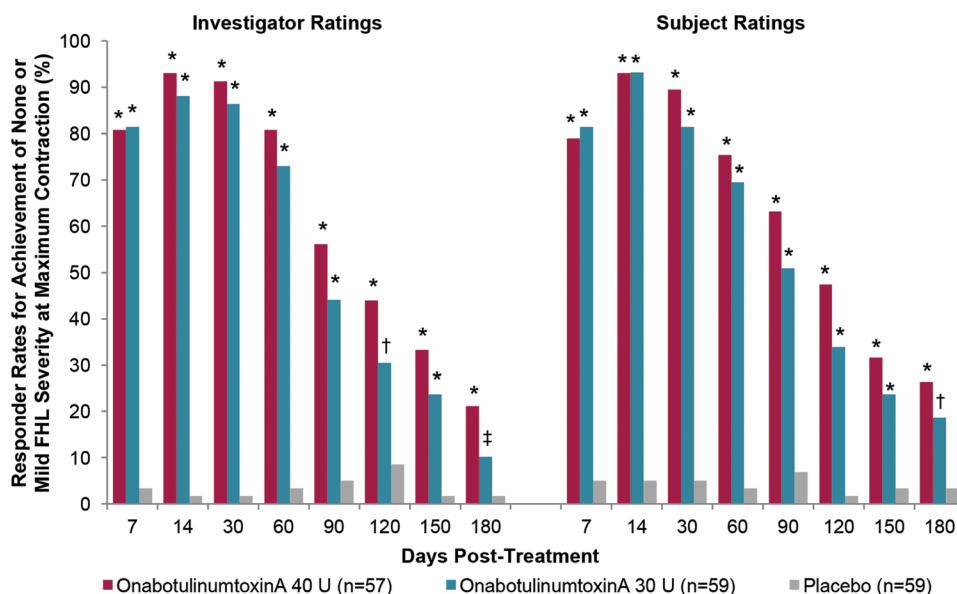


Fig 2. Responder rates for subjects achieving a severity of none or mild, based on the FWS, in FHL at maximum contraction in the dose-ranging study. * $P \leq 0.001$ vs placebo; † $P < 0.01$ vs placebo; ‡ $P < 0.05$ vs placebo. FWS, Facial Wrinkle Scale. Adapted with permission from Solish et al., *Dermatol Surg.*, 2016;42:410–419.¹⁵

and 89.5% and 81.4% by subject assessment ($P < 0.001$ vs placebo) (Fig. 2), and responder rates with both doses remained statistically higher than placebo through day 180.¹⁵ Duration of response was longer with the 40 U dose compared with the 30 U dose (Fig. 3).¹⁵ The proportion of subjects experiencing adverse events (AEs) was generally comparable between the onabotulinumtoxinA 40 U (35.1%) and onabotulinumtoxinA 30 U (33.9%) doses, and was not significantly greater than placebo (25.4%).¹⁵ Based on these findings, the 40 U dose (20 U in the frontalis and 20 U in the glabellar complex) was selected for subsequent phase 3 studies.¹⁵

Efficacy of OnabotulinumtoxinA in 2 Pooled Phase 3 Clinical Trials

The efficacy of onabotulinumtoxinA versus placebo for treatment of moderate to severe FHL was evaluated

in 2 pivotal phase 3 studies conducted across sites in Canada, Europe, and the United States.^{3,5} Subjects in studies 142 and 143 were randomized to receive onabotulinumtoxinA or placebo in FHL and GL; study 143 included the simultaneous treatment of the bilateral CFL with onabotulinumtoxinA (24 U) or placebo.^{3,5} Eligible subjects were neurotoxin-naïve men and women aged 18 years or older with moderate to severe FHL at maximum eyebrow elevation as assessed by the investigator and subject and with moderate to severe GL at maximum frown as assessed by the investigator using the FWS.^{3,5} In study 143, subjects also had investigator-assessed moderate to severe bilaterally symmetrical CFL at maximum smile.⁵ Patients were excluded if they had periocular and eyebrow asymmetry; eyebrow ptosis or excessive skin laxity in the forehead or eyebrow; eyelid folds that reached the pupil or touched the upper lash line; the need to use

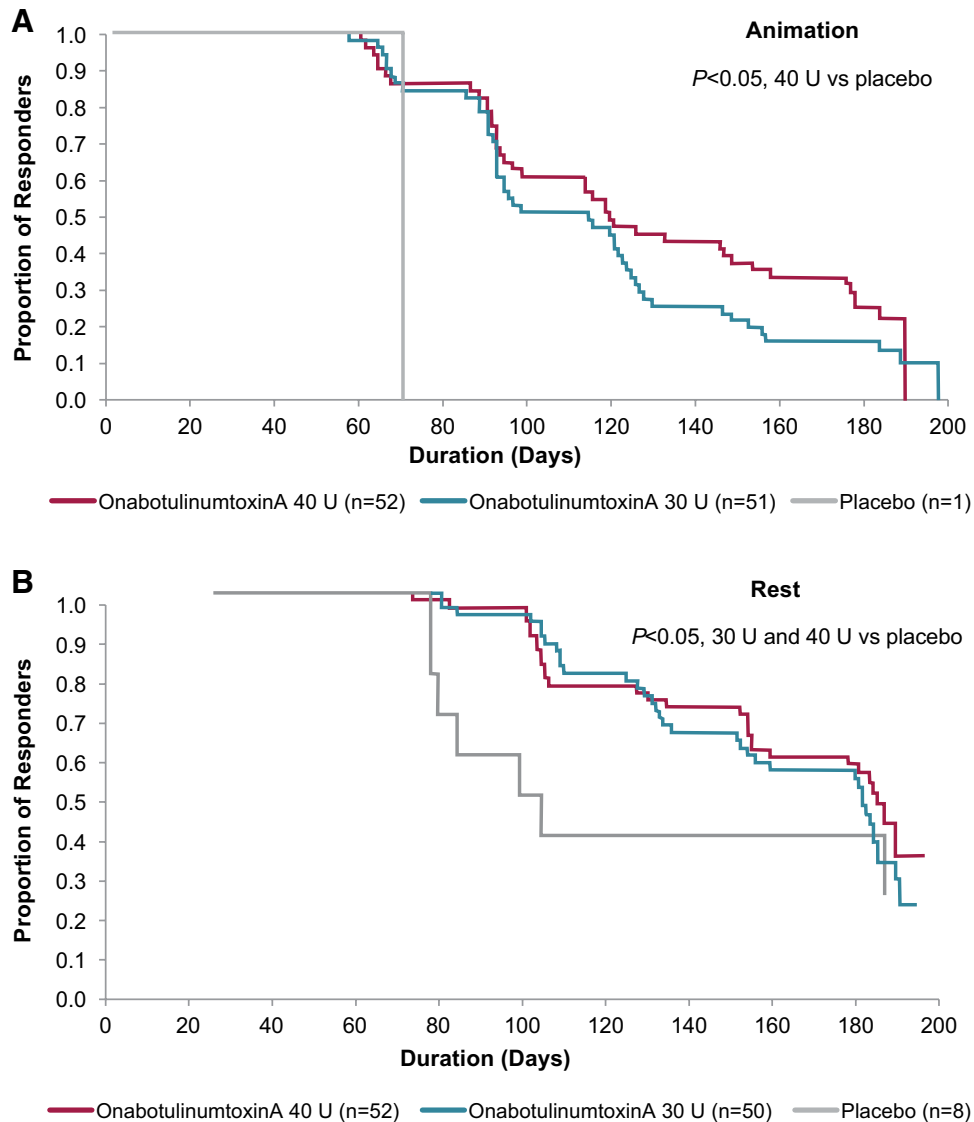


Fig 3. Investigator-assessed time to return to nonresponder status in the dose-ranging study in (A) the subset of subjects achieving a rating of none or mild at max brow elevation on the FWS on day 30 (log-rank test: 40 U, $P < 0.05$ vs placebo) and (B) the subset of subjects with at least a 1-grade improvement from baseline at rest on day 30 (log-rank test: 30 and 40 U, $P < 0.05$ vs placebo). FWS, Facial Wrinkle Scale. Adapted with permission from Solish et al. *Dermatol Surg.* 2016;42:410–419.¹⁵

Table 1. Pooled Subject Demographics and Baseline Facial Line Severity (ITT Population)

Parameter	OnabotA (n = 921; 40 U, n = 608; 64 U, n = 313)	Placebo (n = 257)
Age, mean, years	45.9	45.8
Range	18–77	22–73
Female, %	88.1	88.3
White, %	90.3	90.3
Investigator FWS rating of FHL severity at maximum eyebrow elevation, %		
Moderate	50.9	50.2
Severe	49.1	49.8
Investigator FWS rating of FHL severity at rest, %		
None	2.6	4.3
Mild	32.8	28.4
Moderate	54.0	57.2
Severe	10.6	10.1

FWS, Facial Wrinkle Scale with Photonic Guide; onabotA, onabotulinumtoxinA.

the frontalis muscle to move the upper eyelid; marked dermatochalasis; deep dermal scarring; excessively thick sebaceous skin; or the inability to substantially lessen facial lines, even when physically spreading them apart.^{3,5}

At baseline, subjects in study 142 were randomized 3:1 to receive a total dose of 40 U of onabotulinumtoxinA (20 U in the frontalis and 20 U in the glabellar complex) or placebo, and subjects in study 143 were randomized 2:2:1 to receive a total dose of 64 U of onabotulinumtoxinA (20 U in the frontalis, 20 U in the glabellar complex, and 24 U in CFL), 40 U of onabotulinumtoxinA (20 U in the frontalis, 20 U in the glabellar complex, and placebo in CFL), or placebo (in all 3 areas).^{3,5} In both studies, treatments were administered in 0.1-mL bolus injections of onabotulinumtoxinA (4 U) or placebo distributed over 10 injection sites in the frontalis and glabellar complex (Fig. 1), while 6 additional injection sites were used to treat bilateral CFL in study 143

(Fig. 1).^{3,5} Patients received a single treatment at baseline and were followed for 180 days.^{3,5} This pooled analysis comprised 1,178 subjects in the intent-to-treat (ITT) population (onabotulinumtoxinA 40 U, n = 608; onabotulinumtoxinA 64 U, n = 313; placebo, n = 257). After day 180, all eligible subjects (N = 1,077) could receive up to 2 additional open-label onabotulinumtoxinA treatments (follow-up assessments through day 360).^{3,5} Baseline characteristics of the ITT population are shown in Table 1. No substantial differences in baseline characteristics were observed between the onabotulinumtoxinA and placebo groups.

The primary endpoint for the US Food and Drug Administration was the proportion of subjects in the ITT

population achieving at least a 2-grade improvement in both investigator- and subject-rated FHL severity on the FWS at maximum eyebrow elevation during the double-blind period on day 30.^{3,5} By this composite measure, responder rates in the pooled studies were 53.1% (onabotulinumtoxinA 40 U) and 53.0% (onabotulinumtoxinA 64 U) versus 0% for placebo, and statistically significant differences versus placebo were maintained from day 7 through day 120 of treatment ($P < 0.0001$; Fig. 4).^{3,5} Secondary efficacy endpoints included the proportion of subjects in the ITT population achieving an investigator-assessed FWS FHL severity rating of none or mild at maximum eyebrow elevation, and the proportion of subjects

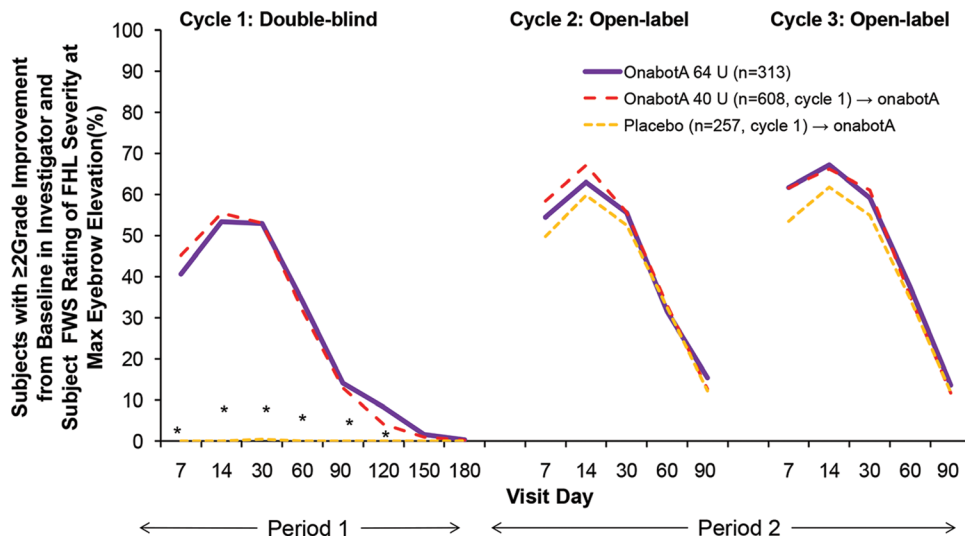


Fig 4. Proportion of subjects in the pooled ITT population achieving at least 2-grade improvement from baseline in composite investigator and subject ratings on the FWS for FHL severity at maximum brow elevation during the double-blind and open-label treatment periods. FWS, Facial Wrinkle Scale; onabotA, onabotulinumtoxinA. * $P < 0.0001$ vs placebo.

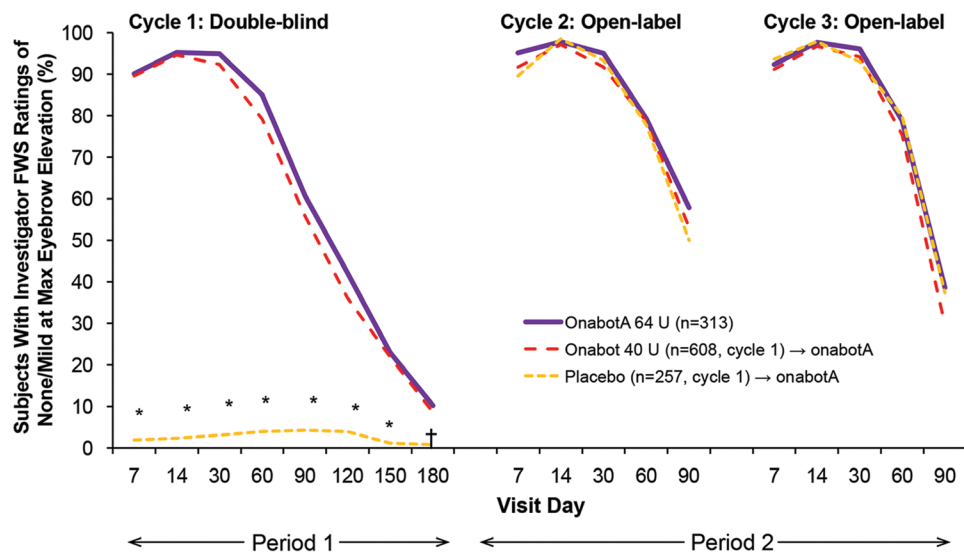


Fig 5. Proportion of subjects in the pooled ITT population achieving investigator-assessed FWS rating of none or mild at maximum eyebrow elevation during the double-blind and open-label treatment periods. FWS, Facial Wrinkle Scale; onabotA, onabotulinumtoxinA. * $P < 0.0001$; † $P < 0.05$ vs placebo.

achieving >1-grade improvement from baseline in investigator-assessed FWS ratings of the severity of static and dynamic FHL on day 30.^{3,5} Responder rates for subjects achieving an investigator-assessed FWS severity rating of none or mild for FHL at maximum brow elevation were significantly higher with onabotulinumtoxinA versus placebo on day 30 and remained significantly higher through day 180 (Fig. 5). Similarly, day 30 responder rates based on investigator-assessed FWS improvement of >1 grade at maximum brow elevation and at rest were significantly higher with onabotulinumtoxinA versus placebo; these differences remained statistically significant through day 180 (Fig. 6). All improvements observed with onabotulinumtoxinA treatment were maintained through 3 cycles of treatment. In addition, 85.6% and 87.9% of subjects treated with 40 U and 64 U, respectively, reported being

mostly or very satisfied with the effect of onabotulinumtoxinA treatment for their FHL (vs 2.4% for placebo), as assessed on day 60 using Item 5 of the validated Facial Line Satisfaction Questionnaire. Representative images of a subject before and after treatment are shown in Fig. 7.

Safety of OnabotulinumtoxinA in 2 Pooled Phase 3 Clinical Trials

The most common treatment-emergent AEs are shown in Table 2. Throughout the 6-month placebo-controlled double-blind period, 20.2% of subjects treated with onabotulinumtoxinA had treatment-emergent AEs (vs 10.2% with placebo). Over the course of 12 months, there were few cases of treatment-related eyebrow ptosis (2.6%) and eyelid ptosis (1.8%) in the total onabotulinumtoxinA group in the pooled studies, and no cases of eyebrow ptosis were observed in men. The incidence was numerically

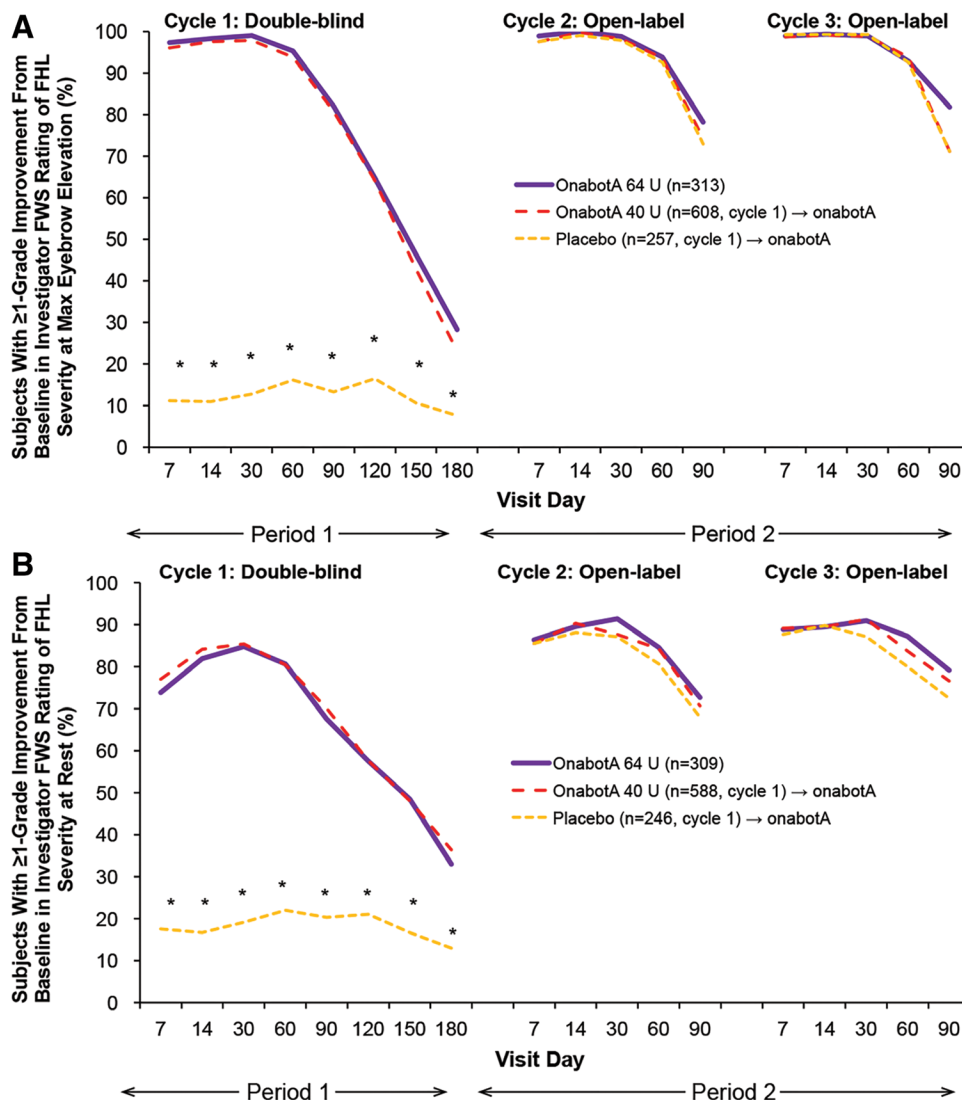


Fig 6. Proportion of subjects in the pooled ITT population achieving >1-grade improvement from baseline in the FWS rating of FHL severity (A) at maximum eyebrow elevation and (B) at rest during the double-blind and open-label treatment periods. FWS, Facial Wrinkle Scale; onabotA, onabotulinumtoxinA. **P* < 0.0001 vs placebo.

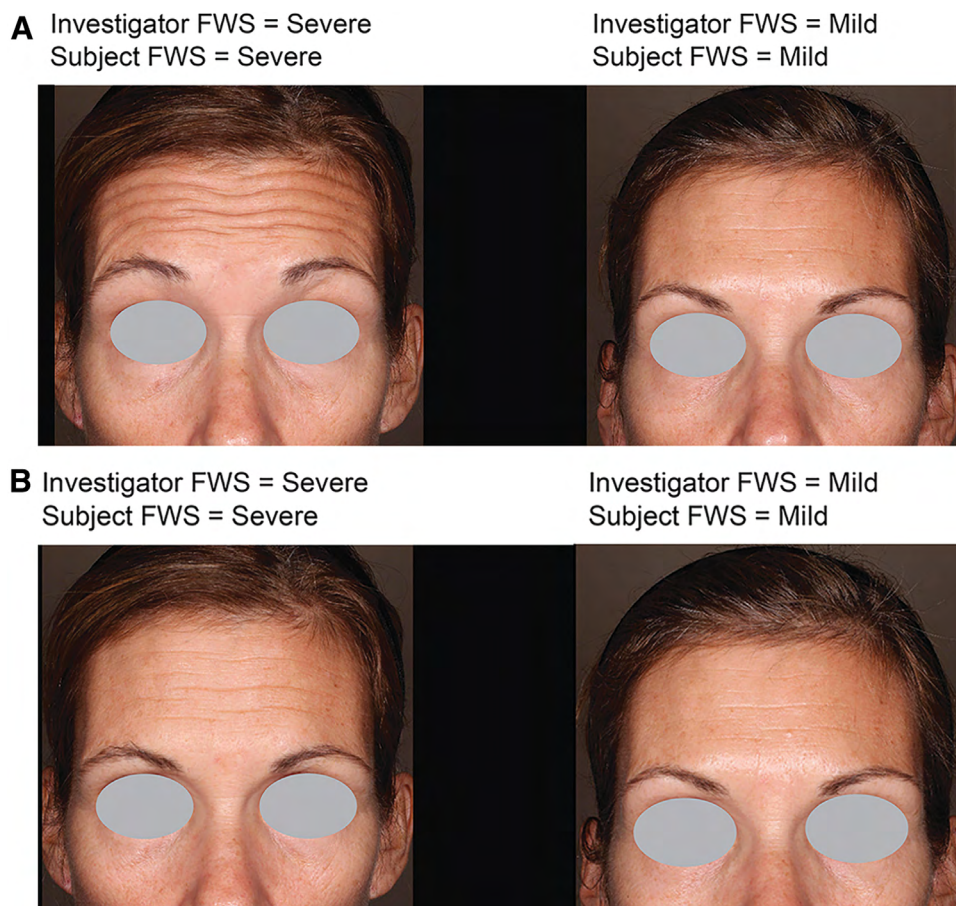


Fig 7. Representative images of a 49-year-old female subject with FHL before and after treatment with onabotulinumtoxinA (A) at maximum eyebrow elevation and (B) at rest. FWS, Facial Wrinkle Scale.

lower with onabotulinumtoxinA treatment compared with placebo for influenza and oral herpes, whereas the incidence of injection site reactions, such as bruising and hematoma, was higher with onabotulinumtoxinA (Table 2). In the double-blind treatment period, serious AEs occurred in 11 and 12 subjects in the onabotulinumtoxinA 40 U and 64 U groups, respectively (vs 2 subjects with placebo), and 1 subject in the 64 U group discontinued from the study as a result of AEs. None of the serious AEs or discontinuations were considered treatment related.

Patient Selection and Treatment Considerations

The pivotal phase 3 studies demonstrated the safety and efficacy of the approved 40 U dose of onabotulinumtoxinA for the treatment of FHL (ie, 20 U in the frontalis and 20 U in the glabellar complex) in a broad patient population.^{3,5} Although the approval was based on clinical trials that had stringent subject selection criteria, our opinion is that most subjects with FHL may be treated successfully by considering variations in forehead anatomy and functionality, and taking appropriate precautions when necessary. For example, owing to greater muscle mass in the forehead, men may require higher doses of onabotulinumtoxinA than women.^{16,17} In contrast, subjects who need to optimize their visual acuity via the frontalis

muscle, who have a very low-set hairline and an immobile galea aponeurotica, who are at risk for brow ptosis, or who have foreheads with a limited vertical dimension (<5 cm) may benefit from lower doses of onabotulinumtoxinA. It is also important to account for the height of FHL to ensure that injections are placed at least 2 cm above the eyebrows. Special considerations should be taken with subjects who have very severe horizontal FHL or those exhibiting dermatochalasis; in our experience, these subjects may benefit from combination treatment with onabotulinumtoxinA and fillers or lasers, depending on the exact presentation, because fillers and lasers can soften lines that are static or deeply etched or in areas where onabotulinumtoxinA may not be appropriate.^{16,26} Naturally, a good understanding of facial anatomy is needed, as rare occurrences of necrosis and blindness have been reported with filler injections in this area.^{27,28}

DISCUSSION

With the recent approval of onabotulinumtoxinA as the first neurotoxin for the treatment of FHL, there are now multiple indications for the use of onabotulinumtoxinA in the upper face. For effective FHL treatment, an M-shaped injection pattern is recommended in conjunction with simultaneous injection of GL; CFL can also be concurrently

Table 2. Summary of TEAEs Occurring in at Least 2% of Subjects in Any Arm in the Pooled Phase 3 Studies (Safety Population)

TEAE, no. of Patients (%)	Cycle 1			Entire Study (Cycles 1–3*)		
	Placebo (n = 256)	OnabotA 40 U (n = 608)	OnabotA 64 U (n = 313)	OnabotA 40 U (n = 692)	OnabotA 64 U (n = 746)	OnabotA Total (n = 1,144)
Headache	15 (5.9)	57 (9.4)	24 (7.7)	73 (10.5)	69 (9.2)	135 (11.8)
Nasopharyngitis	8 (3.1)	30 (4.9)	26 (8.3)	48 (6.9)	48 (6.4)	95 (8.3)
Injection site bruising	7 (2.7)	35 (5.8)	12 (3.8)	45 (6.5)	47 (6.3)	85 (7.4)
URTI	4 (1.6)	13 (2.1)	5 (1.6)	21 (3.0)	29 (3.9)	49 (4.3)
Injection site hematoma	3 (1.2)	16 (2.6)	11 (3.5)	16 (2.3)	34 (4.6)	43 (3.8)
Sinusitis	3 (1.2)	13 (2.1)	6 (1.9)	19 (2.7)	18 (2.4)	37 (3.2)
Eyebrow ptosis	0 (0)	11 (1.8)	2 (0.6)	22 (3.2)	9 (1.2)	30 (2.6)
Influenza	5 (2.0)	8 (1.3)	4 (1.3)	13 (1.9)	12 (1.6)	25 (2.2)
Eyelid ptosis	1 (0.4)	12 (2.0)	2 (0.6)	15 (2.2)	7 (0.9)	21 (1.8)
Oral herpes	6 (2.3)	5 (0.8)	4 (1.3)	7 (1.0)	11 (1.5)	17 (1.5)

*Includes subjects randomized to placebo or onabotA 40 U in cycle 1 who received onabotA 40 U or 64 U, respectively, in cycles 2 and 3. OnabotA, onabotulinumtoxinA; TEAEs, treatment-emergent adverse events; URTI, upper respiratory tract infection.

injected if desired, with no increase in the incidence rates of treatment-related AEs than that elicited by FHL and GL treatment alone.⁵ It is notable that eyebrow ptosis was rarely observed and was completely absent in men in the pivotal studies. The rates of eyebrow ptosis in the pivotal phase 3 studies were similar to or lower than those in previous studies in which FHL and GL were treated concurrently,^{13–15,24} providing further support for the use of the recommended injection pattern. Although the incidence of injection site reactions was higher with onabotulinumtoxinA treatment, none of these or other AEs were considered to be related to the distant spread of toxin. The favorable safety profile observed in the phase 3 studies also validates the use of the approved dose, which was found to provide greater efficacy and durability with similar safety as a lower dose of onabotulinumtoxinA in the dose-ranging study.¹⁵

While clinical trials provide a strong rationale for the clinical use of onabotulinumtoxinA, physicians are likely to treat patients who do not meet the stringent eligibility criteria used in these studies or make variations based on their clinical judgment. In our experience, most patients with FHL can be treated using the recommended injection pattern, although some patients may require modifications in the dose or injection pattern to account for variations in facial anatomy. These modifications may help to prevent overtreatment (or undertreatment of a hyperfunctional or large frontalis muscle), to maintain frontalis movement, and to minimize the potential for eyebrow ptosis. Using an individualized approach can be especially useful for individuals with shorter foreheads, those with preexisting conditions causing severe horizontal FHL, or for elderly individuals who use the frontalis to increase their field of vision.^{16,29}

The data reported herein are derived from clinical trials of onabotulinumtoxinA and, as with many studies of facial aesthetic treatment, most patients were white. Differences in the development and progression of FHL among individuals of different ethnic groups have been documented⁸ and should be considered when extrapolating findings from clinical trials of onabotulinumtoxinA to the treatment of individuals of other ethnic groups.^{8,9} Clinical studies that further examine these anatomical differences, as well as the treatment effect of onabotulinumtoxinA in subjects of various ethnic groups, will be informative.

CONCLUSIONS

Two pivotal phase 3 trials demonstrated that onabotulinumtoxinA is safe and effective for the treatment of FHL, using a dose of 20 U in the frontalis, with concurrent treatment of 20 U in the glabellar complex. Importantly, the results of these studies give clinical support for the concurrent treatment of brow depressors and elevators as a means to protect brow position and to maintain subject satisfaction, without increasing the incidence rates of treatment-related AEs over those produced by FHL and GL treatment alone.

Koeraad De Boule, MD

Aalst Dermatology Clinic

43 Leopoldlaan

Aalst 9300 Belgium

E-mail: koen@doctordeboule.be

ACKNOWLEDGMENTS

Medical writing and editorial assistance were provided by Illyce Nunez, PhD, and Kristin E. Larsen, PhD, of Peloton Advantage, LLC, an OPEN Health company, and were funded by Allergan plc. The authors thank Shirley Lei for her biostatistical analysis of the data and Garrett Shumate for his invaluable assistance during the initial discussions for this article.

REFERENCES

- Carruthers A, Bruce S, de Coninck A, et al. Efficacy and safety of onabotulinumtoxinA for the treatment of crows feet lines: a multicenter, randomized, controlled trial. *Dermatol Surg*. 2014;40:1181–1190.
- Moers-Carpi M, Carruthers J, Fagien S, et al. Efficacy and safety of onabotulinumtoxinA for treating crow's feet lines alone or in combination with glabellar lines: a multicenter, randomized, controlled trial. *Dermatol Surg*. 2015;41:102–112.
- Fagien S, Cohen JL, Coleman W, et al. Forehead line treatment with onabotulinumtoxinA in subjects with forehead and glabellar facial rhytids: a phase 3 study. *Dermatol Surg*. 2017;43:S274–S284.
- Botox Cosmetic Prescribing Information*. Dublin, Ireland: Allergan plc; 2017.
- De Boule K, Werschler WP, Gold MH, et al. Phase 3 study of onabotulinumtoxinA distributed between frontalis, glabellar complex, and lateral canthal areas for treatment of upper facial lines. *Dermatol Surg*. 2018;44:1437–1448.

6. Hillebrand GG, Liang Z, Yan X, et al. New wrinkles on wrinkling: an 8-year longitudinal study on the progression of expression lines into persistent wrinkles. *Br J Dermatol*. 2010;162:1233–1241.
7. Abramo AC, Do Amaral TP, Lessio BP, et al. Anatomy of forehead, glabellar, nasal and orbital muscles, and their correlation with distinctive patterns of skin lines on the upper third of the face: reviewing concepts. *Aesthetic Plast Surg*. 2016;40:962–971.
8. Rossi AM, Eviatar J, Green JB, et al. Signs of facial aging in men in a diverse, multinational study: timing and preventive behaviors. *Dermatol Surg*. 2017;43 Suppl 2:S210–S220.
9. Alexis AF, Grimes P, Boyd C, et al. Racial and ethnic differences in self-assessed facial aging in women: results from a multinational study. *Dermatol Surg*. 2019;45:1635–1648.
10. Keaney TC. Aging in the male face: intrinsic and extrinsic factors. *Dermatol Surg*. 2016;42:797–803.
11. Jagdeo J, Keaney T, Narurkar V, et al. Facial treatment preferences among aesthetically oriented men. *Dermatol Surg*. 2016;42:1155–1163.
12. Narurkar V, Shamban A, Sissins P, et al. Facial treatment preferences in aesthetically aware women. *Dermatol Surg*. 2015;41: S153–S160.
13. Carruthers J, Carruthers A. Botulinum toxin type A treatment of multiple upper facial sites: patient-reported outcomes. *Dermatol Surg*. 2007;33:S10–S17.
14. Carruthers A, Carruthers J. A single-center, dose-comparison, pilot study of botulinum neurotoxin type A in female patients with upper facial rhytids: safety and efficacy. *J Am Acad Dermatol*. 2009;60:972–979.
15. Solish N, Rivers JK, Humphrey S, et al. Efficacy and safety of onabotulinumtoxin A treatment of forehead lines: a multicenter, randomized, dose-ranging controlled trial. *Dermatol Surg*. 2016;42:410–419.
16. Carruthers J, Fagien S, Matarasso SL; Botox Consensus Group. Consensus recommendations on the use of botulinum toxin type A in facial aesthetics. *Plast Reconstr Surg*. 2004;114(6 Suppl):1S–22S.
17. Lorenc ZP, Smith S, Nestor M, et al. Understanding the functional anatomy of the frontalis and glabellar complex for optimal aesthetic botulinum toxin type A therapy. *Aesthetic Plast Surg*. 2013;37:975–983.
18. Ascher B, Talarico S, Cassuto D, et al. International consensus recommendations on the aesthetic usage of botulinum toxin type A (speywood unit)—part I: upper facial wrinkles. *J Eur Acad Dermatol Venereol*. 2010;24:1278–1284.
19. Kane M, Donofrio L, Ascher B, et al. Expanding the use of neurotoxins in facial aesthetics: a consensus panel's assessment and recommendations. *J Drugs Dermatol*. 2010;9(suppl 1):s7–22.
20. Qaqish C. Botulinum toxin use in the upper face. *Atlas Oral Maxillofac Surg Clin North Am*. 2016;24:95–103.
21. Macdonald MR, Spiegel JH, Raven RB, et al. An anatomical approach to glabellar rhytids. *Arch Otolaryngol Head Neck Surg*. 1998;124:1315–1320.
22. Costin BR, Plesec TP, Sakolsatayadorn N, et al. Anatomy and histology of the frontalis muscle. *Ophthalmic Plast Reconstr Surg*. 2015;31:66–72.
23. de Almeida AR, da Costa Marques ER, Banegas R, et al. Glabellar contraction patterns: a tool to optimize botulinum toxin treatment. *Dermatol Surg*. 2012;38:1506–1515.
24. Carruthers A, Carruthers J, Cohen J. A prospective, double-blind, randomized, parallel-group, dose-ranging study of botulinum toxin type A in female subjects with horizontal forehead rhytides. *Dermatol Surg*. 2003;29:461–467.
25. Flynn TC. Update on botulinum toxin. *Semin Cutan Med Surg*. 2006;25:115–121.
26. Carruthers J, Carruthers A, Maberley D. Deep resting glabellar rhytides respond to BTX-A and hylan B. *Dermatol Surg*. 2003;29:539–544.
27. de Maio M, DeBouille K, Braz A, et al; Alliance for the Future of Aesthetics Consensus Committee. Facial assessment and injection guide for botulinum toxin and injectable hyaluronic acid fillers: focus on the midface. *Plast Reconstr Surg*. 2017;140:540e–550e.
28. Philipp-Dormston WG, Bergfeld D, Sommer BM, et al. Consensus statement on prevention and management of adverse effects following rejuvenation procedures with hyaluronic acid-based fillers. *J Eur Acad Dermatol Venereol*. 2017;31:1088–1095.
29. Carruthers JD, Glogau RG, Blitzer A; Facial Aesthetics Consensus Group Faculty. Advances in facial rejuvenation: botulinum toxin type A, hyaluronic acid dermal fillers, and combination therapies—consensus recommendations. *Plast Reconstr Surg*. 2008;121(5 Suppl):5S–30S; quiz 31S.