

Two-Centre Retrospective Analysis on Selective Sensory Denervation of Shoulder Joint by Means of Cooled Radiofrequency in Chronic Shoulder Pain

Carola Santi¹, Thomas Haag², Christian Cooke², Michael E Schatman^{3,4}, Andrea Tinnirello⁵

¹Anesthesia, Intensive Care and Pain Management Unit, Manerbio Hospital, ASST Del Garda, Brescia, Italy; ²Pain Management Unit-Wrexham Maelor Hospital, Wrexham, UK; ³Department of Anesthesiology, Perioperative Care, & Pain Medicine, NYU Grossman School of Medicine, New York, NY, USA; ⁴Department of Population Health – Division of Medical Ethics, NYU Grossman School of Medicine, New York, NY, USA; ⁵Anesthesia and Pain Management Unit, Iseo Hospital, ASST Franciacorta, Brescia, Italy

Correspondence: Andrea Tinnirello, Ospedale di Iseo-Asst Franciacorta, Via Giardini Garibaldi 1, Iseo, BS, 25049, Italy, Tel +390303422, Email andrea.tinnirello@asst-franciacorta.it

Purpose: Radiofrequency ablation has been used to treat chronic shoulder pain with mixed results. Thanks to recent anatomical studies, the precise location of articular branches of the suprascapular, lateropectoral and axillary nerves has been determined. Cooled radiofrequency is a neuroablative modality of treatment which has been demonstrated as efficient in different anatomical locations, and targeting the aforementioned nerves could result in a complete and efficient denervation of the shoulder. The aim of this study is to assess the efficacy of a fluoroscopic guided cooled radiofrequency technique for chronic shoulder pain.

Patients and Methods: This is a retrospective observational study performed in two hospital in Wales and Italy (Wrexham NHS trust and Iseo Hospital). Forty-four patients were treated between December 2019 and January 2023. Follow-up was provided at 1-, 6- and 12-months post-procedure. Pain intensity was measured with a 0–10-point Numerical Rating Scale (NRS), and was assessed at rest and during movement. Disability was assessed with the Oxford Shoulder Score (OSS). All patients were treated with cooled radiofrequency under fluoroscopic guidance targeting the articular branches of the suprascapular, axillary and lateropectoral nerves.

Results: In the 44 patients treated, the mean NRS significantly decreased at all follow ups, pain relief of >50% was obtained in 70.4%, 61% and 51% of the patients at 1.6 and 12 month follow-ups, respectively. Disability improved significantly, with a mean OSS at 12 months follow up of 30 ± 17.5 , compared to 15 ± 3 at baseline. Medication intake (non-steroidal anti-inflammatory drugs (NSAIDs) and/or opioids) significantly decreased at all follow ups.

Conclusion: Cooled radiofrequency denervation can be an effective procedure to manage chronic shoulder pain, providing sustained pain relief and functional improvement in more than 50% of the patients.

Keywords: radiofrequency, neuromodulation, shoulder pain, pain management

Introduction

Shoulder pain is responsible for approximately 16% of all musculoskeletal complaints, with a yearly incidence of 15 new episodes per 1,000 patients seen in the primary care setting.¹ It is estimated that shoulder pain affects 5–21% of the adult population in the United States and glenohumeral joint arthritis affects nearly a third of the world's population over the age of 60 years.² Shoulder pain is defined as chronic when it has been present for greater than 6 months, regardless of whether the patient has previously sought treatment. It can be divided into 6 diagnostic categories:

- rotator cuff disorders, including tendinosis, full or partial thickness tears, or calcific tendinitis;
- adhesive capsulitis;
- glenohumeral osteoarthritis;
- glenohumeral instability;
- acromioclavicular joint pathology;

- other chronic pain conditions such as rheumatic diseases.³

Further, less common shoulder problems and non-shoulder problems such as neck-related issues which can feature as an aspect of a Neck-Shoulder-Syndrome should be considered.⁴ The variety of causes of shoulder pain makes a meticulous clinical assessment imperative, and should include a dynamic imaging assessment of the shoulder joint and rotator cuff with ultrasound.^{5,6} Shoulder pain has the strongest impact on poor quality of life among various types of musculoskeletal pain in middle aged and elderly individuals, based on the results of the Yakumo study.⁷ Shoulder arthroplasty is an indication that needs to be addressed cautiously in light of the substantial risks potentially associated with certain treatments. These risks are higher than those for knee and hip replacements overall, particularly when it comes to the increased risk of revision surgery. Such risk is greatest in those over 85 and under 60 years, according to a recently published study.⁸

Conservative, non-surgical treatment options include analgesic medication, physiotherapy and various injections. The scope for improvements with these modalities is limited, particularly in advanced osteoarthritis. Analgesic medications include acetaminophen, NSAIDs, opioids and compounds such as paracetamol/tramadol or dexketoprofen/tramadol. According to a review, opioids and NSAIDs result in a 30% reduction of pain at best, with neither demonstrating therapeutic superiority.⁹ There is also an imperative to avoid long-term opioid use in the face of emerging prescription opioid overuse concerns in Europe, albeit not at the scale that had been seen in the USA.

Radiofrequency (RF) application to selected sensory nerves offers a potentially powerful treatment option for chronic joint pain that has failed to respond to conventional treatment options, including both surgical and non-surgical modalities.^{10–12} RF ablation involves the application of high frequency electrical current to a target tissue, with the energy delivered creating ionic friction heating the tissue around the tip of the probe.¹³ Temperatures above 50°C create degeneration of neural tissue, disrupting the nociceptive inputs to the central nervous system.¹³

Applying the RF current in short (20 milliseconds) bursts followed by a pause of 480 milliseconds represents an alternative, non-destructive, modality of RF ablation which is defined as, Pulsed Radiofrequency (PRF).¹⁴ PRF has a complex neuromodulatory effect and has been widely applied to mixed motor nerves, dorsal root ganglia or intra-articularly in several reports.¹⁵ The effectiveness of PRF application for chronic joint pain is limited, and thus should be considered for patients complaining of pure or predominantly neuropathic pain.^{11,16} The evolution of RF ablation has led to the development of technologies allowing for the creation of wide lesions (up to 1 centimeter in diameter) which should increase the size of neural tissue ablation and, theoretically, improve outcomes.¹⁴ Among these recent technologies, cooled RF has been investigated and appears to be more effective compared to other modalities. Cooled RF involves circulating cool water through the probe tip to maintain lower temperatures at the tissue tip interface. The circulated water removes heat from the tissue–tip interface, which reduces charring of tissues in contact with the probe, facilitating energy delivery to the target tissue.^{13,17,18} Even if the tip of the probe temperature is maintained at 60°C, the tissue temperature reaches about 80°C, delivering spherical lesions which are larger and with more energy delivery than lesions produced by conventional RF, thus increasing the likelihood of ablating targeted neural tissue.^{13,17,18} The same treatment has been applied to knee joint pain and two RCTs support its superiority compared to standard medical management such as intra-articular hyaluronic acid and steroids.^{17,19–22} In this study, we investigate the application of cooled RF on the Lateropectoral nerve, axillary nerve, and suprascapular nerve to manage chronic shoulder pain due to various etiologies.

Shoulder Innervation Overview

The shoulder joint has a complex innervation, and with the majority of nociceptors of the glenohumeral joint located in the anterosuperior and posterosuperior side of the joint, high nociceptor concentration has been demonstrated in the subacromial bursa and in the proximal region of the long biceps tendon.^{23,24} Under pathological conditions (ie, rotator cuff injury), an increase in nociceptor concentration can be noticed in structures usually deprived of nociceptors, such as the coracoacromial and other articular ligaments.^{24,25}

The sensory and nociceptive innervation is supplied by articular branches of the Suprascapular (SSN), Axillary (AN) and Lateropectoral (LPN) nerves (Figure 1).^{26–30} The SSN is a mixed motor and sensory nerve, which at the spinoglenoid notch splits into a medial motor trunk and a lateral sensory trunk supplying the innervation of the posterior gleno-humeral

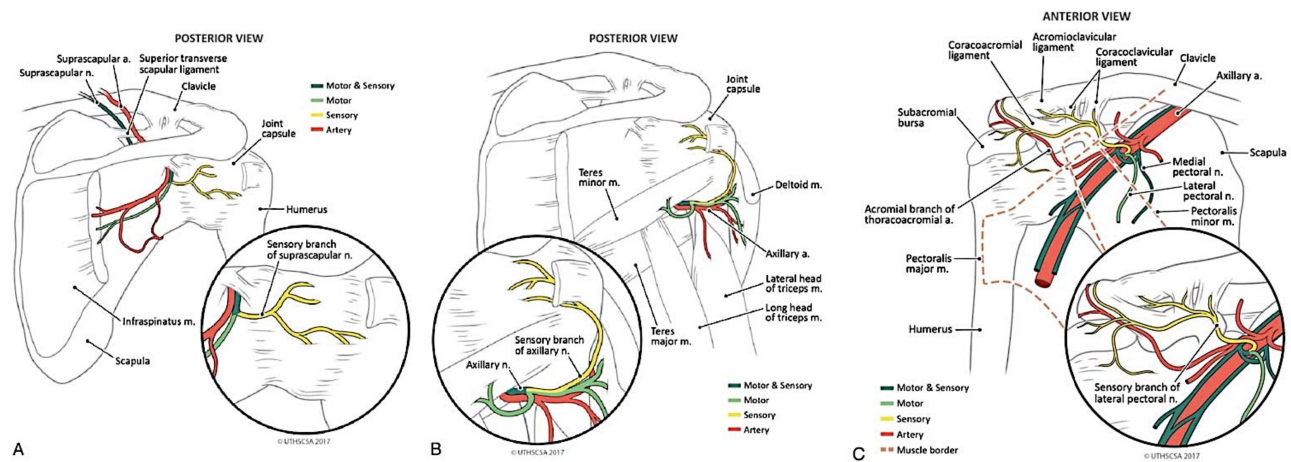


Figure 1 Medical illustrations depicting the anatomic course of SN (A), AN (B), and LPN (C). Reproduced from Eckmann MS, Bickelhaupt B, Fehl J. et al. Cadaveric Study of the Articular Branches of the Shoulder Joint. *Reg Anesth Pain Med.* 2017;42(5):564–570 with permission from BMJ Publishing Group Ltd.

joint, the posterior joint capsule, the subacromial bursa and the posterior side of the humeral head.^{27,29} The AN supplies, via sensory nerves originating from nerve branches for the deltoid muscle, the innervation of the posterior-inferior side of the joint capsule and of the humeral head and neck.²⁸

The LPN provides a sensory articular branch at the level of the coracoid process, and is responsible for the innervation of the clavicle, the acromioclavicular joint and the subacromial bursa.^{26,30} Anatomical studies have demonstrated the path of articular branches of the SSN, LPN and AN, and anatomical landmarks that are easily recognizable under fluoroscopy have been proposed. Figures 2 and 3 illustrate the anatomical landmarks for the posterior and anterior side of the shoulder joint.^{26,29–31} RF denervation has been applied to manage chronic shoulder pain, with most studies using PRF and targeting the SSN prior to its division into a medial and lateral trunk.^{10,12}

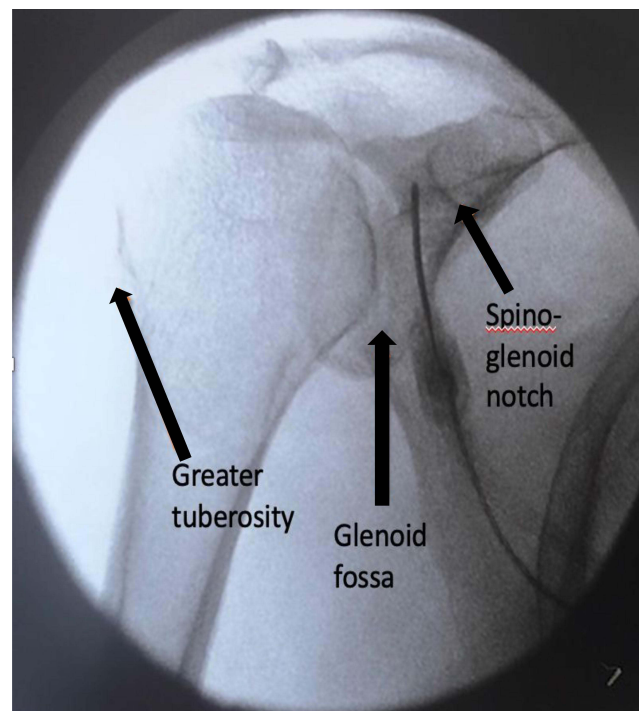


Figure 2 Postero-Anterior fluoroscopic view of the shoulder joint, arrows indicate anatomical landmarks for ablation procedure.

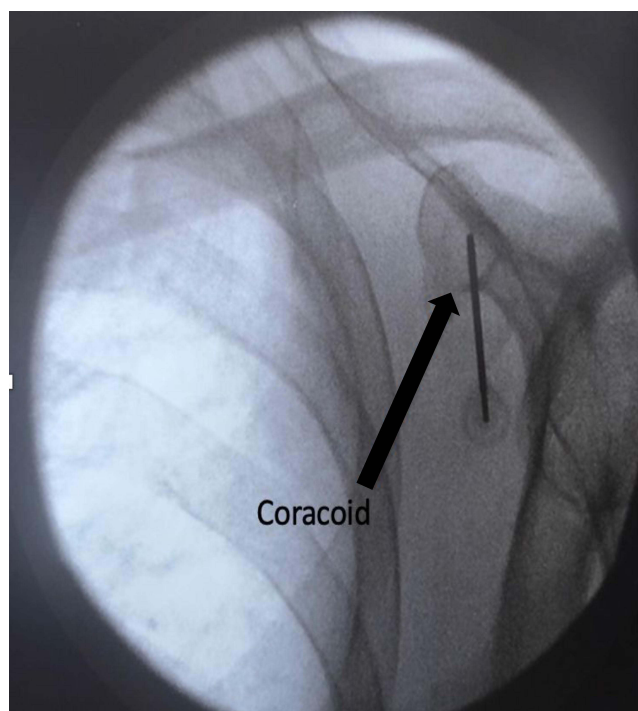


Figure 3 Antero-posterior fluoroscopic view of the shoulder joint, arrows indicate anatomical landmarks for ablation procedure.

The overall outcomes of these studies are unremarkable, as often the results of PRF are not superior to conventional medical management.^{10,12} More recent studies explored the application of RF to the AN, SSN and LPN with a success rate of 60% at three-month follow up.³¹

Material and Methods

This is a retrospective observational study of 44 patients treated between December 2019 and March 2023.

Inclusion criteria were:

- Age > 18.
- Chronic shoulder pain (NRS at movement > 6/10) lasting more than 6 months.
- Failure of other conservative treatments (joint injections, physical therapy).

Exclusion criteria were:

- Patient's refusal to give consent to the procedure or to use of their data for research purposes.
- Ongoing local or systemic infection before the procedure.
- Predominant neuropathic pain assessed with the Pain Detect questionnaire.

Patients were treated in Iseo Hospital, Italy and Wrexham Maelor Hospital, Wales. Data were retrieved from patients' hospital records; all patients provided their consent to use their data for scientific purposes. The study was approved in Italy by the local ethical committee (Comitato etico provinciale Brescia) with protocol number NP 4843 and in Wales by the Betsi Cadwaladr University Health Board with protocol number 443. The study was conducted according to the declaration of Helsinki. The primary outcomes of the study were pain at rest and during movement (calculated using Numerical Rating Scale from 0 to 10) and disability calculated with the Oxford Shoulder Score (ranging from 0 to 48).³² Secondary outcomes were patients' analgesic use, (NSAIDs and opioid intake). Regarding medication use, NSAIDs use is expressed as number of patients regularly assuming at least 1 dose of medication every week, opioid use is calculated in Morphine Equivalent Daily Dose (MEDD) expressed in milligrams (mg).

Statistical analysis was performed using Excel (Microsoft, Redmond, WA). Normality of distribution was detected through the Shapiro–Wilk test, according to the results means or medians. Standard Deviation or Interquartile Range

were calculated for continuous demographic and outcomes data. Means or medians were compared with the Wilcoxon test with $P < 0.01$ indicating significant differences.

Denervation Technique

Denervation was performed under topical skin anesthesia (lidocaine 2% 2 mL for each entry point) with slight sedation as needed (midazolam 1–2 mg iv, fentanyl 50 mcg iv). Patients taking anticoagulants were allowed to continue their treatment according to the American Society of Regional Anesthesia and Pain Medicine (ASRA) guidelines on pain procedures in patients on antithrombotic therapy.³³

Suprascapular Nerve Denervation

Patients were positioned prone with the arm lying on the side of the patient. Fluoroscopy was tilted approximately 15° caudally and 15° oblique ipsilaterally to obtain a clear view of the spinoglenoid notch. The RF probe was placed laterally to the spinoglenoid notch to target the articular branches of the SSN (Figure 4).

Axillary Nerve Denervation

With the patient lying in the same position and the fluoroscopy set for the SSN, the RF probe was placed close to the greater tuberosity of the humerus, targeting the articular branches of the AN (Figure 5).

Lateropectoral Nerve Denervation

The patient was positioned supine, with the arm lying on the side. Fluoroscopy was tilted 15° cranially and 15° oblique ipsilaterally to obtain a clear view of the coracoid process. The RF probe was positioned on the middle part of the coracoid process to target the articular branches of the LPN (Figure 6). For each target point, sensory and motor testing

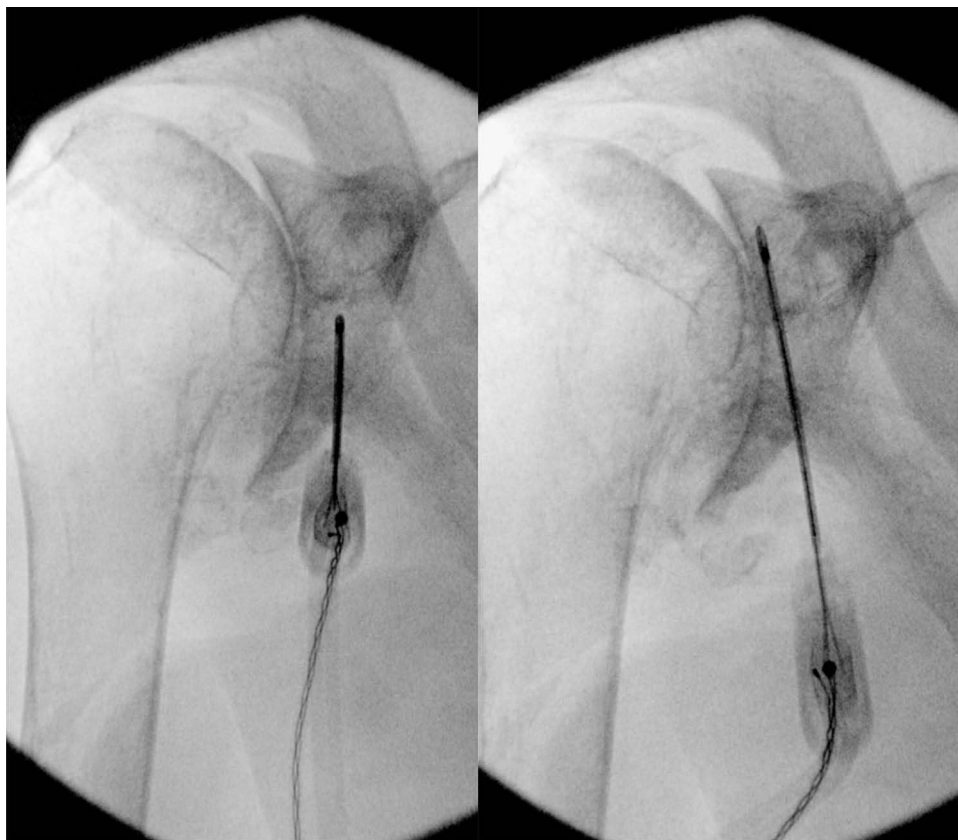


Figure 4 Fluoroscopic view with RF probe in place for the denervation of the inferior (left side) and superior (right side) articular branches of the suprascapular nerve.

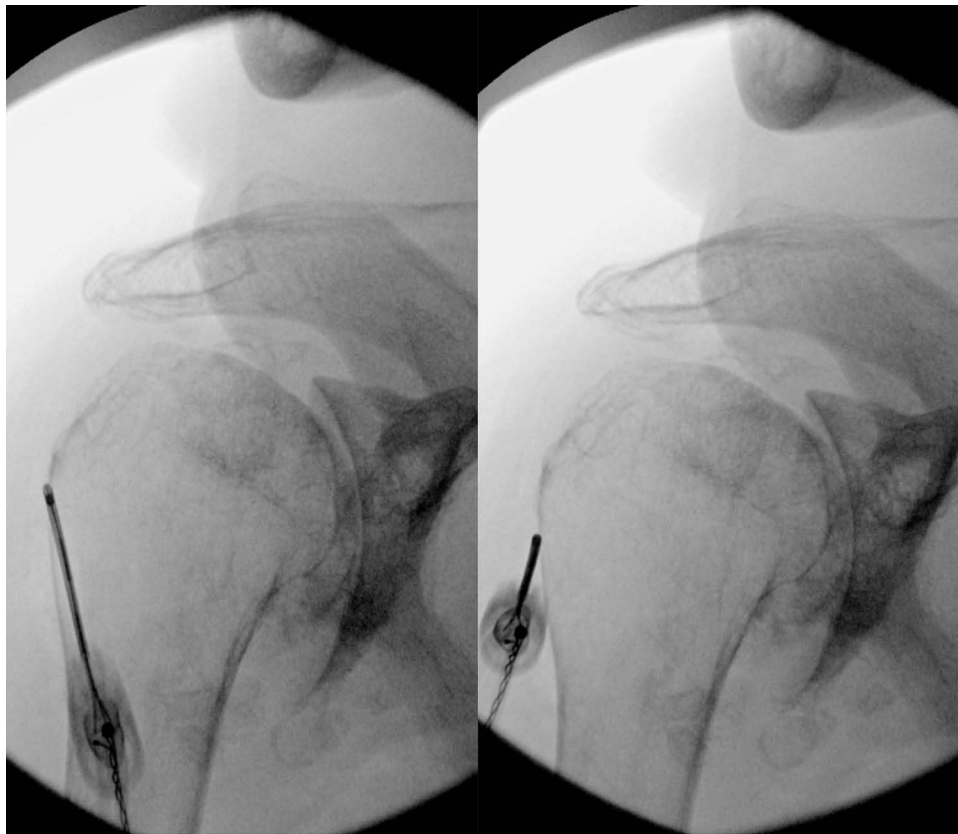


Figure 5 Fluoroscopic view with RF probe in place for the denervation of the inferior (left side) and superior (right side) articular branches of the axillary nerve.

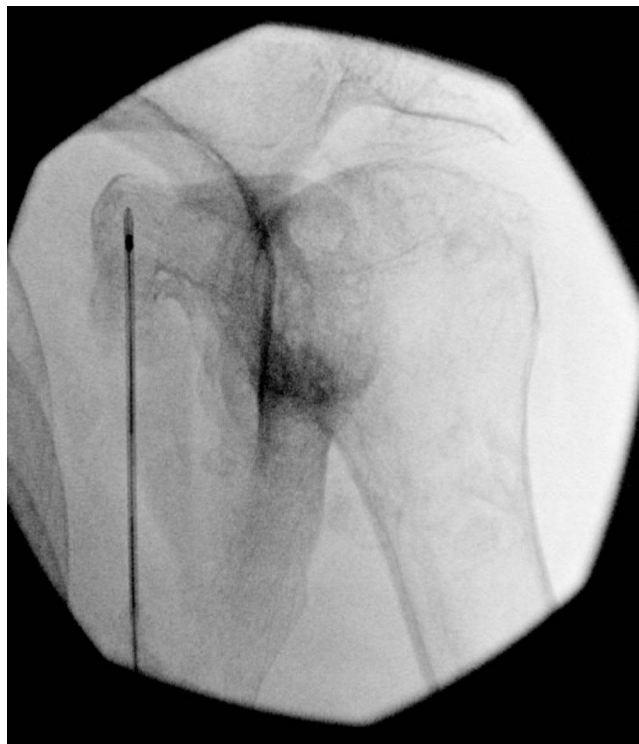


Figure 6 Fluoroscopic view with RF probe in place for the denervation of the inferior (left side) and superior (right side) articular branches of the lateropectoral nerve.

were performed at 50 hz and 2 Hz, respectively, to ensure correct positioning of the probe and to avoid lesioning of motor branches. Particularly on the SSN, motor stimulations at 2Hz were occasionally detected requiring a more lateral positioning of the probe. Cooled RF was performed at 60° for 150 seconds for each lesion, and following the treatment, a mixture of ropivacaine 0.1% and Methylprednisolone 40 mg were injected (1 mL for every lesion) to reduce post-procedural pain.

Results

Forty-four patients (17 males and 27 females) were treated between December 2019 and April 2023, and all patients have completed the 12-month follow-ups.

Population demographic data are illustrated in [Table 1](#).

Four patients (9%) had received previous arthroscopic surgery and 11 (25%) were provided with indication for shoulder joint replacement. All patients received a prognostic test block with local anesthetic (ropivacaine 0.5% 1 mL) to each denervation target. The test block was performed under fluoroscopic guidance using the same targets and approach of the RF denervation. All 44 patients reported pain relief >80% following the test block and were scheduled for denervation. Predominately neuropathic pain was ruled out in all patients using the Pain Detect questionnaire. NRS scores (both at rest and during movement) decreased at all follow up, with patients' disability also improving based upon their OSS scores ([Table 2](#), [Figures 7](#) and [8](#)). All the results were statistically significant with a $P < 0.01$. An analysis of medication use has been performed. Eighteen patients (40.9% of the total) were taking NSAIDs while 22 patients (50%) were taking opioids (mean MEDD 26.65 ± 16.5 mg/day) chronically before RF. Following the intervention, patients reported a marked decrease in medication use, and after 12 months, 7 (15.9%) and 9 (20.4%) of patients were still taking NSAIDs and opioids, respectively ([Figure 9](#)). Opioid use decreased at all follow-ups, with the median MEDD at 12 months decreasing to 8.8 ± 22.73 mg/day ([Table 3](#) and [Figure 10](#)). All the results were statistically significant with a $P < 0.01$.

No complications associated with the procedure were reported.

Table 1 Population Demographic Data at Baseline

	Median	IQR	MAX	MIN
AGE	75	13.5	90	45
BMI	26	6.75	34	19
NRS REST	6	2	8	2
NRS MOVEMENT	9	1	10	7
OSS	15	3	29	8

Abbreviations: IQR, Interquartile Range; BMI, Body Mass Index; NRS, Numerical Rating Scale; OSS, Oxford Shoulder Score.

Table 2 Pain and Disability Scores at Baseline and Different Follow Up

	Basal	1 Month	6 Months	12 Months
NRS REST	6 ± 2	$2 \pm 3^*$ ($p < 0.00001$)	$3 \pm 2^*$ ($p < 0.00001$)	$3,5 \pm 2,5^*$ ($p < 0.00001$)
NRS MOVEMENT	9 ± 1	$4 \pm 2,75^*$ ($p < 0.00001$)	$5 \pm 3,5^*$ ($p < 0.00001$)	$5 \pm 3^*$ ($p < 0.00001$)
OSS	15 ± 3	$36 \pm 20^*$ ($p < 0.00001$)	$32 \pm 17^*$ ($p = 0.003$)	$30 \pm 17,5^*$ ($p = 0.004$)

Notes: * indicates statistical significance at $P < 0.01$.

Abbreviations: NRS, Numerical Rating Scale; OSS, Oxford Shoulder Score.

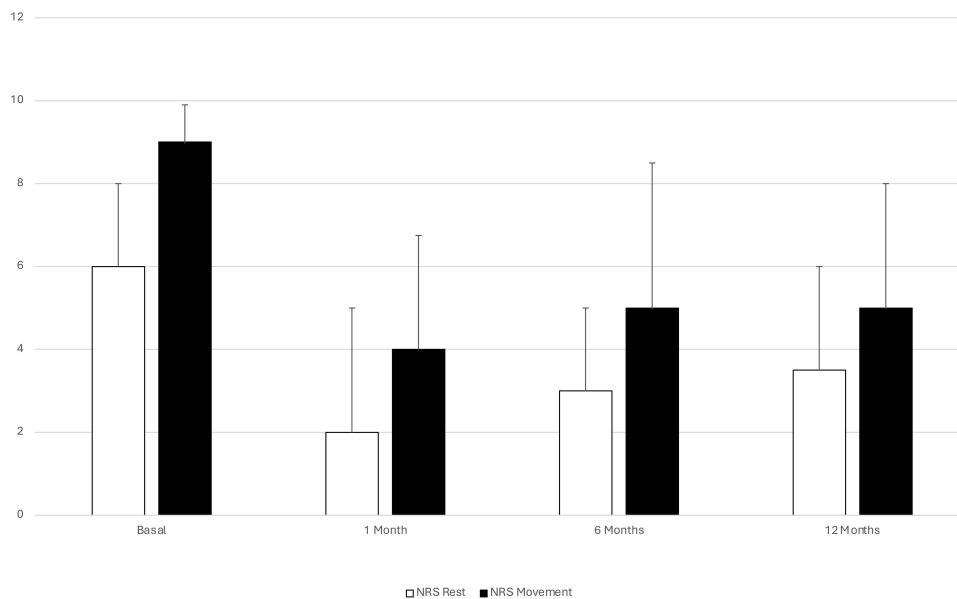


Figure 7 Median Numerical Rating Scale scores at rest and during movement for all follow ups.

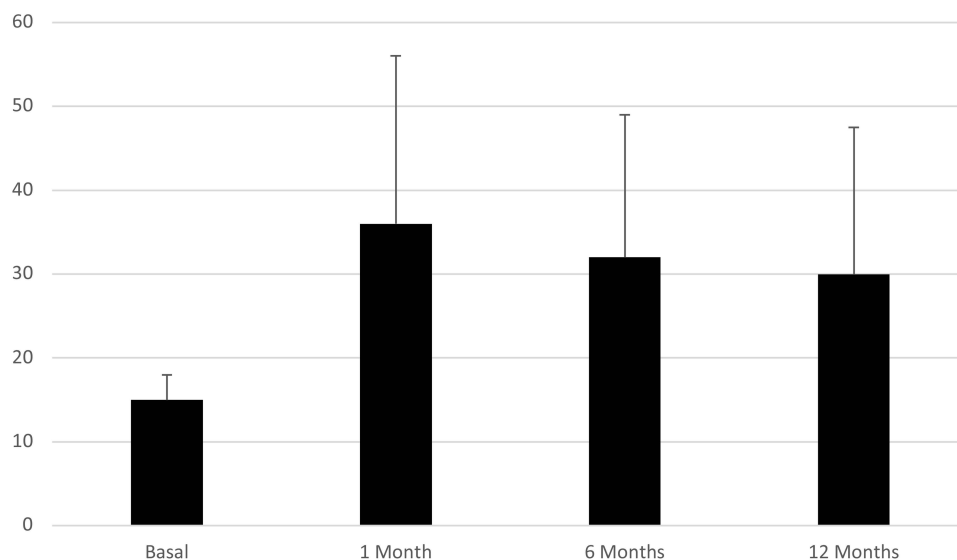


Figure 8 Median Oxford Shoulder Score values (vertical axis) for all follow ups.

Discussion

Chronic shoulder pain is a widespread condition that severely affects many patients, with surgical options often limited and often unsatisfying. Accordingly, a minimally invasive method to reduce pain and improve rehabilitation is needed. The SSN has been targeted in several reports, generally using PRF with an approach aiming to reach the nerve at the suprascapular notch, a location at which the motor and sensory components of the SSN are not divided.^{10,12} This approach has been demonstrated to achieve good pain relief lasting typically no more than 3–6 months in approximately 50% of the patients. Targeting the SSN more distally enables the treatment of only its sensory articular components with

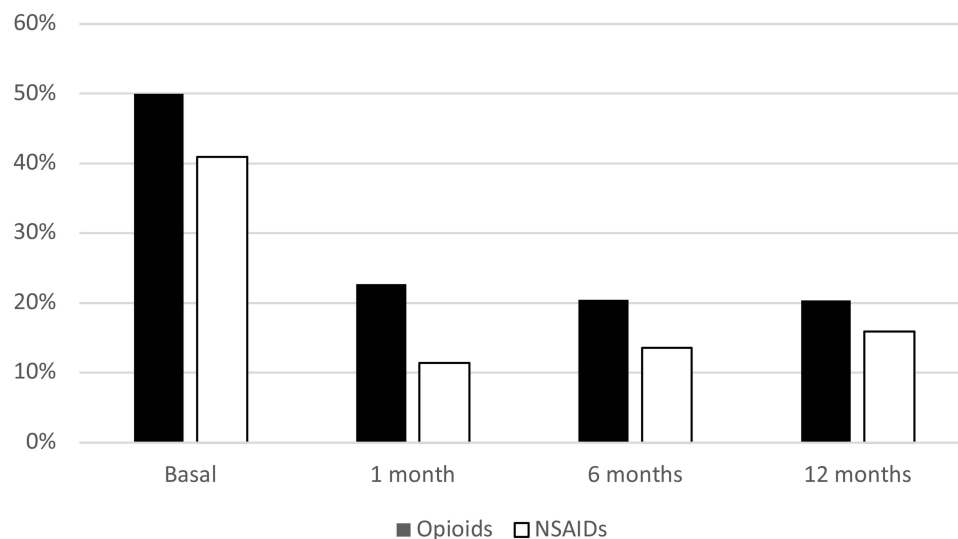


Figure 9 Percentage of patients assuming medications (NSAIDs and Opioids) for all follow ups.

a neuroablative technique, and moreover, adding the sensory branches of the AN and LPN widens the area of coverage to the anterior and lateral aspect of the shoulder joint. Cooled RF is a neuroablative modality that has been determined to be effective in several conditions such as knee joint and sacroiliac joint pain, and appears to be more effective than other modalities of RF and conservative treatments.^{10,19,34–36} Our results suggest that patients can achieve pain relief of >50% lasting at least 6 months in 61% of patients, with the success of the procedure maintained in 51% of patients at 12 months follow-up. The efficacy of this procedure is further supported by a significant reduction in medication usage, the percentage of patients receiving NSAIDs or opioids was reduced by more than a half after 12 months.

Concerns regarding RF application on large joints include the theoretical possibility of developing a proprioceptive deficit ultimately resulting in Charcot's joint.³⁷ However, no reports of such complication have been described and our population did not show any proprioceptive deficits following the procedure.^{11,37}

A potential limiting factor of this technique is the requirement of tilting the patient from the prone to the supine position during the procedure, representing an uncomfortable maneuver for elderly and less compliant patients. Ultrasound guidance could remove the need for changing position and allowing the procedure to be performed in a sitting position, making the entire intervention process easier and better tolerated.³⁸

Larger, prospective multi-site studies clearly need to be performed, as our relatively small sample size does not ensure replicability. Future investigations should aim to study specific indications and subgroups of patients (eg, glenoharthritis compared to rotator cuff pathology) as the possibility exists for differential degrees of relief among different groups of patients based on the etiologies.

Table 3 Medication Intake by Patients at Baseline and Different Follow Up

	Basal	1 Month	6 Months	12 Months
Patients taking NSAIDs (% of total)	40.9%	11.3%*	13.6%*	20.4%*
Patients taking opioids (% of total)	50%	22.7%*	20.4%*	15.9%*
MEDD (milligrams)	26.6 ± 40	13 ± 25.2*	10.8 ± 23.7 *	8.8 ± 22.7*

Notes: * indicates statistical significance at $P < 0.01$.

Abbreviations: NSAIDs, Non Steroidal Anti-Inflammatory Drugs; MEDD, Morphine equivalent Daily Dose.

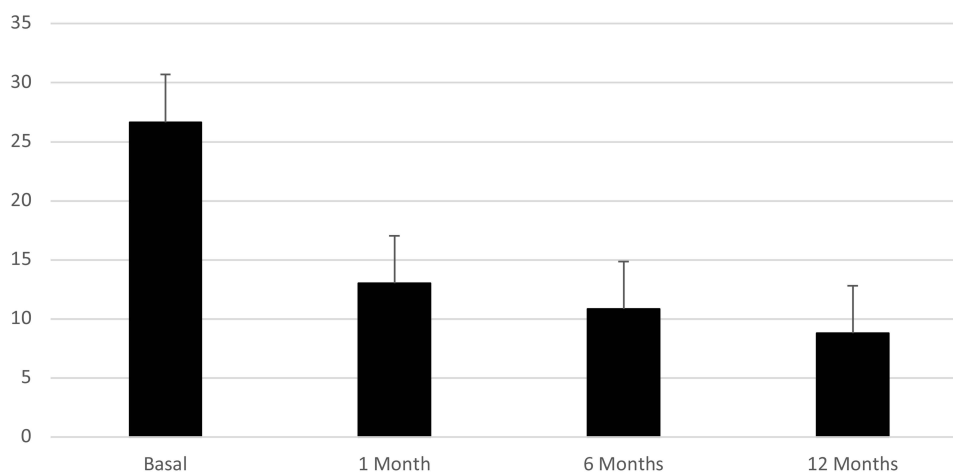


Figure 10 Opioid medication intake, expressed as MEDD (Milligrams of Morphine Equivalent Daily Dose, vertical axis) at all follow up.

Conclusion

Cooled RF application on sensory articular branches of the SSN, AN and LPN provided substantial and prolonged pain relief in patients, decreasing medication use and resulting in significant improvement of pain and function in patients who failed other conservative treatments.

These findings should be confirmed on larger population and compared to other noninvasive modalities of treatment.

Author Contributions

All authors made a significant contribution to the work reported, whether that is in the conception, study design, execution, acquisition of data, analysis and interpretation, or in all these areas; took part in drafting, revising or critically reviewing the article; gave final approval of the version to be published; have agreed on the journal to which the article has been submitted; and agree to be accountable for all aspects of the work.

Disclosure

Carola Santi reports no conflicts of interest in this work. Thomas Haag and Andrea Tinnirello received compensation from Avanos for educational events. Thomas Haag also reports personal fees from Stryker, outside the submitted work. Michael Schatman serves as Senior Medical Advisor to Apurano Pharmaceuticals. Christian Cooke reports no conflicts of interest in this work.

References

- Lucas J, Van Doorn P, Hegedus E, Lewis J, Van Der Windt D. A systematic review of the global prevalence and incidence of shoulder pain. *BMC Musculoskelet Disord.* 2022;23(1):1073. doi:10.1186/s12891-022-05973-8
- Khazzam M, Gee AO, Pearl M. Management of Glenohumeral Joint Osteoarthritis. *J Am Acad Orthop Surg.* 2020;28(19):781–789. doi:10.5435/JAAOS-D-20-00404
- Burbank KM, Stevenson JH, Czarnecki GR, Dorfman J. Chronic shoulder pain: part I. Evaluation and diagnosis. *Am Fam Physician.* 2008;77(4):453–460.
- Katsuura Y, Bruce J, Taylor S, Gullota L, Overlapping KHJ. Masquerading, and Causative Cervical Spine and Shoulder Pathology: a Systematic Review. *Glob Spine J.* 2020;10(2):195–208. doi:10.1177/2192568218822536
- Wu WT, Lin JA, Chen LR, et al. Ultrasound Imaging, Guidance, and Treatment for Shoulder-related Pain Syndrome: a Bibliometric Analysis. *Pain Physician.* 2022;25(9):E1433–E1445.
- Chang KV. Ultrasound Diagnosis and Guided Intervention of Musculoskeletal/Neuromuscular Pathology 2022. *Diagnostics.* 2023;13(11):1945. doi:10.3390/diagnostics13111945
- Imagama S, Ando K, Kobayashi K, et al. Shoulder pain has most impact on poor quality of life among various types of musculoskeletal pain in middle-aged and elderly people: yakumo study. *Mod Rheumatol.* 2020;30(3):568–572. doi:10.1080/14397595.2019.1623364
- Brolin TJ, Thakar OV, Abboud JA. Outcomes After Shoulder Replacement Surgery in the Young Patient. *Clin Sports Med.* 2018;37(4):593–607. doi:10.1016/j.csm.2018.05.008
- Smith SR, Deshpande BR, Collins JE, Katz JN, Losina E. Comparative pain reduction of oral non-steroidal anti-inflammatory drugs and opioids for knee osteoarthritis: systematic analytic review. *Osteoarthritis Cartilage.* 2016;24(6):962–972. doi:10.1016/j.joca.2016.01.135

10. Tinnirello A, Santi C, Haag T. Selective Sensory Denervation by Means of Radiofrequency (RF) Ablation: a Novel Non-surgical Treatment Approach in Chronic Joint Pain: a Narrative Review on Its Application on Knee Hip and Shoulder. *SN Compr Clin Med.* 2022;4(1):147. doi:10.1007/s42399-022-01243-9
11. Bhatia A, Peng P, Cohen SP. Radiofrequency Procedures to Relieve Chronic Knee Pain: an Evidence-Based Narrative Review. *Reg Anesth Pain Med.* 2016;41(4):501–510. doi:10.1097/AAP.0000000000000414
12. Pushparaj H, Hoydonckx Y, Mittal N, et al. A systematic review and meta-analysis of radiofrequency procedures on innervation to the shoulder joint for relieving chronic pain. *Eur J Pain.* 2021;25(5):986–1011. doi:10.1002/ejp.1735
13. Ball RD. The Science of Conventional and Water-Cooled Monopolar Lumbar Radiofrequency Rhizotomy: an Electrical Engineering Point of View. *Pain Physician.* 2014;17(2):E175–E211. doi:10.36076/ppj.2014/17/E175
14. Lee DW, Pritzlaff S, Jung MJ, et al. Latest Evidence-Based Application for Radiofrequency Neurotomy (LEARN): best Practice Guidelines from the American Society of Pain and Neuroscience (ASPN). *J Pain Res.* 2021;14:2807–2831. doi:10.2147/JPR.S325665
15. Park D, Chang MC. The mechanism of action of pulsed radiofrequency in reducing pain: a narrative review. *J Yeungnam Med Sci.* 2022;39(3):200–205. doi:10.12701/jyms.2022.00101
16. Vallejo R, Benyamin RM, Aliaga L. Radiofrequency vs. pulse radiofrequency: the end of the controversy. *Tech Reg Anesth Pain Manag.* 2010;14(3):128–132. doi:10.1053/j.trap.2010.06.003
17. Kapural L, Minerali A, Sanders M, Matea M, Dua S. Cooled Radiofrequency Ablation Provides Prolonged Pain Relief Compared to Traditional Radiofrequency Ablation: a Real-World, Large Retrospective Clinical Comparison from a Single Practice. *J Pain Res.* 2022;15:2577–2586. doi:10.2147/JPR.S373877
18. Zachariah C, Mayeux J, Alas G, et al. Physiological and functional responses of water-cooled versus traditional radiofrequency ablation of peripheral nerves in rats. *Reg Anesth Pain Med.* 2020;45(10):792–798. doi:10.1136/rapm-2020-101361
19. Davis T, Loudermilk E, DePalma M, et al. Twelve-month analgesia and rescue, by cooled radiofrequency ablation treatment of osteoarthritic knee pain: results from a prospective, multicenter, randomized, cross-over trial. *Reg Anesth Pain Med.* 2019;44(4):499–506. doi:10.1136/rapm-2018-100051
20. Davis T, Loudermilk E, DePalma M, et al. Prospective, Multicenter, Randomized, Crossover Clinical Trial Comparing the Safety and Effectiveness of Cooled Radiofrequency Ablation With Corticosteroid Injection in the Management of Knee Pain From Osteoarthritis. *Reg Anesth Pain Med.* 2018;43(1):84–91. doi:10.1097/AAP.0000000000000690
21. Kapural L, Deering JP. A technological overview of cooled radiofrequency ablation and its effectiveness in the management of chronic knee pain. *Pain Manag.* 2020;10(3):133–140. doi:10.2217/pmt-2019-0066
22. Hunter CW, Deer TR, Jones MR, et al. Consensus Guidelines on Interventional Therapies for Knee Pain (STEP Guidelines) from the American Society of Pain and Neuroscience. *J Pain Res.* 2022;15:2683–2745. doi:10.2147/JPR.S370469
23. Laumonerie P, Dalmas Y, Tibbo ME, et al. Sensory innervation of the human shoulder joint: the three bridges to break. *J Shoulder Elbow Surg.* 2020;29(12):e499–e507. doi:10.1016/j.jse.2020.07.017
24. Dean B, Gwilym SE, Carr AJ. Why does my shoulder hurt? A review of the neuroanatomical and biochemical basis of shoulder pain. *Br J Sports Med.* 2013;47(17):1095–1104. doi:10.1136/bjsports-2012-091492
25. Martínez-Gago A, García-Mesa Y, Cuendias P, et al. Sensory innervation of the human shoulder joints in healthy and in chronic pain shoulder syndromes. *Ann Anat.* 2024;252:152206. doi:10.1016/j.aanat.2023.152206
26. Tran J, Peng P, Agur AMR. Anatomical study of the innervation of glenohumeral and acromioclavicular joint capsules: implications for image-guided intervention. *Reg Anesth Pain Med.* 2019;44(4):452–458. doi:10.1136/rapm-2018-100152
27. Vorster W, Lange CPE, Briët RJP, et al. The sensory branch distribution of the suprascapular nerve: an anatomic study. *J Shoulder Elbow Surg.* 2008;17(3):500–502. doi:10.1016/j.jse.2007.10.008
28. Bickelhaupt B, Eckmann MS, Brennick C, Rahimi OB. Quantitative analysis of the distal, lateral, and posterior articular branches of the axillary nerve to the shoulder: implications for intervention. *Reg Anesth Pain Med.* 2019;44(9):875–880. doi:10.1136/rapm-2019-100560
29. Tran J, Peng P, Agur A. Evaluation of suprascapular nerve radiofrequency ablation protocols: 3D cadaveric needle placement study. *Reg Anesth Pain Med.* 2019;44(11):1021–1025. doi:10.1136/rapm-2019-100739
30. Tran J, Peng P, Agur A, Mittal N. Diagnostic block and radiofrequency ablation of the acromial branches of the lateral pectoral and suprascapular nerves for shoulder pain: a 3D cadaveric study. *Reg Anesth Pain Med.* 2021;46(4):305–312. doi:10.1136/rapm-2020-102300
31. Eckmann MS, Johal J, Bickelhaupt B, et al. Terminal Sensory Articular Nerve Radiofrequency Ablation for the Treatment of Chronic Intractable Shoulder Pain: a Novel Technique and Case Series. *Pain Med.* 2020;21(4):868–871. doi:10.1093/pm/pnz335
32. Angst F, Schwyzer H, Aeschlimann A, Simmen BR, Goldhahn J. Measures of adult shoulder function: disabilities of the Arm, Shoulder, and Hand Questionnaire (DASH) and Its Short Version (Quick DASH), Shoulder Pain and Disability Index (SPADI), American Shoulder and Elbow Surgeons (ASES) Society Standardized Shoulder Assessment Form, Constant (Murley) Score (CS), Simple Shoulder Test (SST), Oxford Shoulder Score (Oss), Shoulder Disability Questionnaire (SDQ), and Western Ontario Shoulder Instability Index (WOSI). *Arthritis Care Res.* 2011;63(S11). doi:10.1002/acr.20630
33. Narouze S, Benzon HT, Provenzano D, et al. Interventional Spine and Pain Procedures in Patients on Antiplatelet and Anticoagulant Medications (Second Edition): guidelines From the American Society of Regional Anesthesia and Pain Medicine. *Reg Anesth Pain Med.* 2017;42(1):1. doi:10.1097/AAP.0000000000000700
34. Cheng J, Pope JE, Dalton JE, Cheng O, Bensitel A. Comparative Outcomes of Cooled Versus Traditional Radiofrequency Ablation of the Lateral Branches for Sacroiliac Joint Pain. *Clin J Pain.* 2013;29(2):132–137. doi:10.1097/AJP.0b013e3182490a17
35. Patel N. Twelve-Month Follow-Up of a Randomized Trial Assessing Cooled Radiofrequency Denervation as a Treatment for Sacroiliac Region Pain. *Pain Pract.* 2016;16(2):154–167. doi:10.1111/papr.12269
36. Chen AF, Khalouf F, Zora K, et al. Cooled radiofrequency ablation provides extended clinical utility in the management of knee osteoarthritis: 12-month results from a prospective, multi-center, randomized, cross-over trial comparing cooled radiofrequency ablation to a single hyaluronic acid injection. *BMC Musculoskelet Disord.* 2020;21(1):363. doi:10.1186/s12891-020-03380-5
37. Kidd VD, Strum SR, Strum DS, Shah J. Genicular Nerve Radiofrequency Ablation for Painful Knee Arthritis: the Why and the How. *JBJS Essent Surg Tech.* 2019;9(1):e10. doi:10.2106/JBJS.ST.18.00016
38. Stogicza AR, Peng P. Cryoanalgesia for shoulder pain: a motor-sparing approach to rotator cuff disease. *Reg Anesth Pain Med.* 2022;47(9):576–580. doi:10.1136/rapm-2022-103670

Journal of Pain Research

Dovepress

Publish your work in this journal

The Journal of Pain Research is an international, peer reviewed, open access, online journal that welcomes laboratory and clinical findings in the fields of pain research and the prevention and management of pain. Original research, reviews, symposium reports, hypothesis formation and commentaries are all considered for publication. The manuscript management system is completely online and includes a very quick and fair peer-review system, which is all easy to use. Visit <http://www.dovepress.com/testimonials.php> to read real quotes from published authors.

Submit your manuscript here: <https://www.dovepress.com/journal-of-pain-research-journal>