

## Case Report

# The critical role of computed tomography in the differential diagnosis of acute calcific tendinitis of longus colli muscle: A case report

Gülden Karatağ<sup>1</sup>, Gürdal Nusran<sup>2</sup>, Coşkun Zateri<sup>3</sup>, Ozan Karatağ<sup>4</sup>

<sup>1</sup>Department of Radiology, Çanakkale State Hospital, Çanakkale, Türkiye

<sup>2</sup>Department of Orthopaedics and Traumatology, Çanakkale Onsekiz Mart University Faculty of Medicine, Çanakkale, Türkiye

<sup>3</sup>Department of Radiology, Physical Medicine and Rehabilitation, Çanakkale Onsekiz Mart University Faculty of Medicine, Çanakkale, Türkiye

<sup>4</sup>Department of Radiology, Çanakkale Onsekiz Mart University Faculty of Medicine, Çanakkale, Türkiye

Received: January 11, 2022 Accepted: May 10, 2022 Published online: August 19, 2022

## ABSTRACT

Acute longus colli calcific tendinitis (ALCT) is a non-infectious inflammatory process. The typical clinical triad is acute neck pain, neck stiffness, and odynophagia. These findings can be confused with many common pathologies. As ALCT treatment is conservative and relatively easy, making the correct diagnosis is important. Radiology is of critical importance in the diagnosis of ALCT. The detection of prevertebral calcification by computed tomography is pathognomonic. Herein, we present a case with a sudden onset of neck and occipital pain accompanied by odynophagia following acute trauma and diagnosed with ALCT by radiological examination.

**Keywords:** Computed tomography, longus colli tendinitis, neck pain, magnetic resonance imaging, odynophagia, X-ray.

Acute longus colli calcific tendinitis (ALCT) is a non-infectious inflammatory process that occurs due to amorphous deposition of calcium hydroxyapatite crystals in the tendons of the longus colli muscle, particularly at the C1 and C2 levels.<sup>[1]</sup> This process is also known as retropharyngeal calcific tendinitis.<sup>[2]</sup> It was first described by Hartley<sup>[3]</sup> in 1964. The typical clinical triad is acute neck pain, neck stiffness leading to restricted range of motion, and odynophagia.<sup>[4]</sup> It may be clinically similar and confused with many more serious pathologies including retropharyngeal abscess, epiglottitis, lymphadenitis, meningitis, spondylodiscitis, vertebral fracture, oropharyngeal or spinal tumors, disc herniation, which are more common than itself.<sup>[1,2,4,5]</sup> However, ALCT is an entity that is relatively easy to treat with a benign and conservative approach.<sup>[1,4,5]</sup>

In this article, we present a case with a sudden onset of neck and occipital pain accompanied by odynophagia findings following acute trauma and diagnosed with ALCT by radiological examination in the light of literature data.

## CASE REPORT

A 42-year-old male patient who had no previous complaints or history described severe neck pain in the upper cervical, left paravertebral and suboccipital localized regions, and throbbing occipital pain with a pulsating sensation that started two days ago and increased with movement. Neck pain did not respond to naproxen and dexketoprofen, nor to local hot/cold applications. The next day, odynophagia and a clicking sound during chewing were added to the symptoms.

**Corresponding author:** Ozan Karatağ, MD. Çanakkale Onsekiz Mart Üniversitesi Tıp Fakültesi, Radyoloji Anabilim Dalı, 17110 Çanakkale, Türkiye.

e-mail: okaratag17@gmail.com

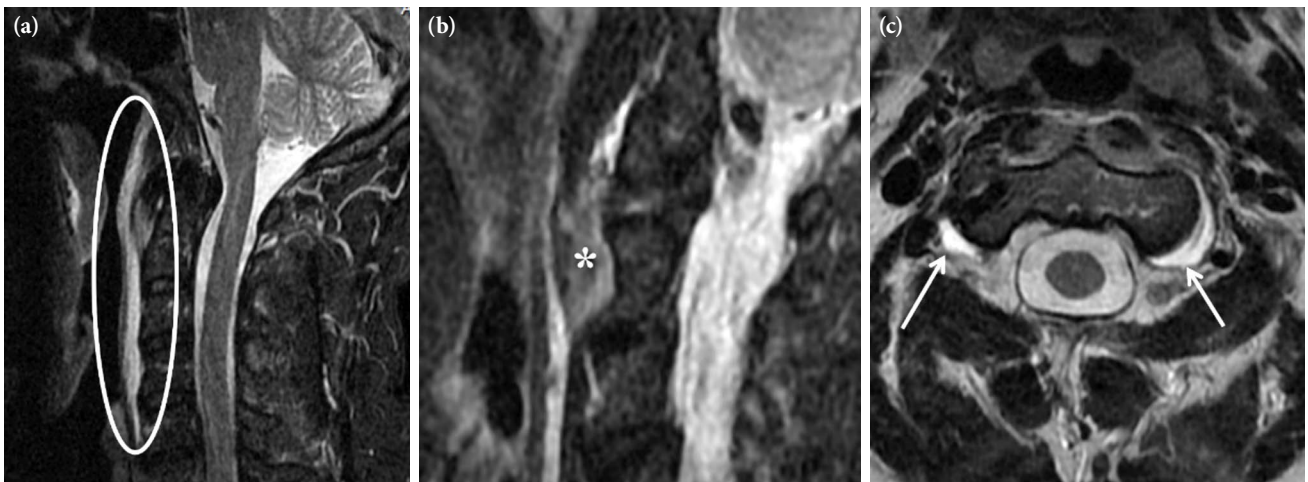
Cite this article as:

Karatağ G, Nusran G, Zateri C, Karatağ O. The critical role of computed tomography in the differential diagnosis of acute calcific tendinitis of longus colli muscle: A case report. Turk J Phys Med Rehab 2023;69(4):549-552. doi: 10.5606/tftrd.2023.10476.

©2023 All right reserved by the Turkish Society of Physical Medicine and Rehabilitation

This is an open access article under the terms of the Creative Commons Attribution-NonCommercial License, which permits use, distribution and reproduction in any medium, provided the original work is properly cited and is not used for commercial purposes (<http://creativecommons.org/licenses/by-nc/4.0/>).



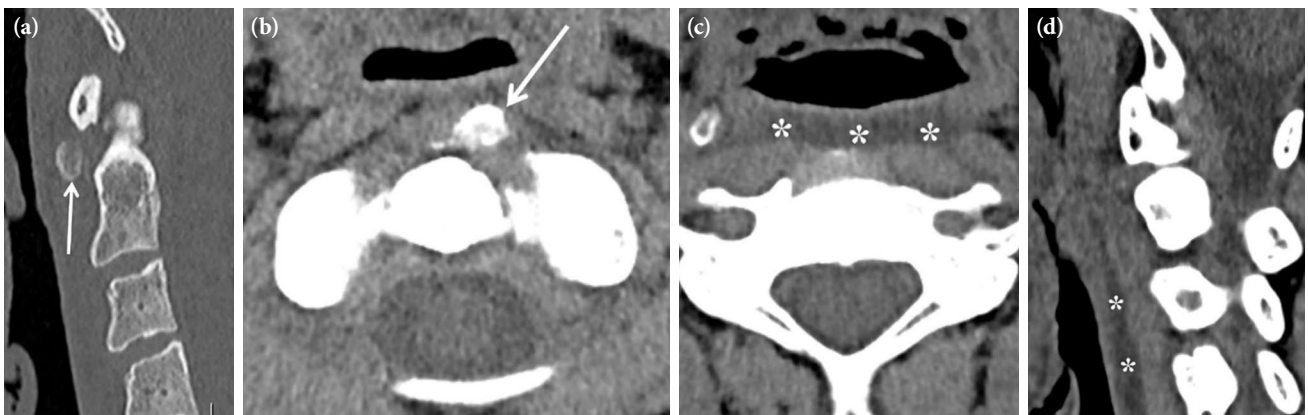


**Figure 1.** (a) Cervical MRI showing hyperintense prevertebral effusion and (b) edema of longus colli muscle and tendon on sagittal STIR image, and (c) bilateral effusion adjacent to atlantoaxial joints on axial T2-weighted image.

MRI: Magnetic resonance imaging; STIR: Short-time inversion recovery.

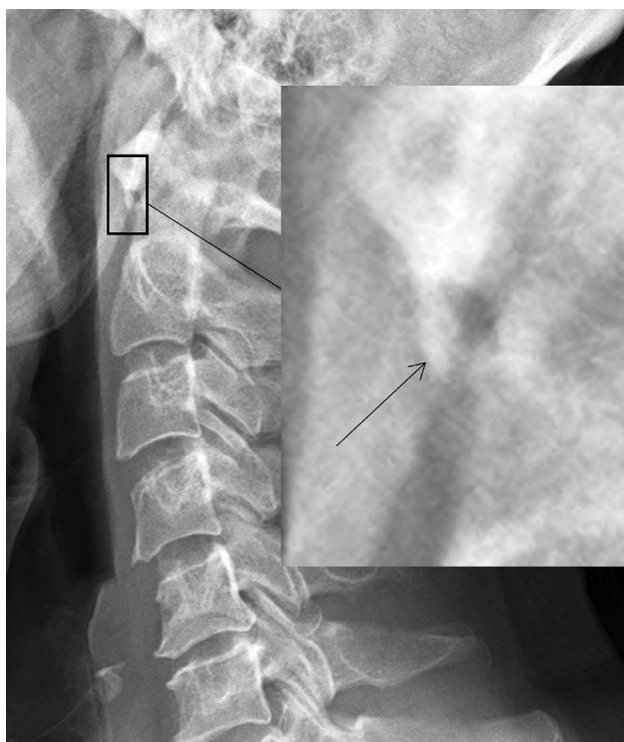On physical examination, there was a forward head posture. Tenderness and spasm were detected in the left suboccipital area and paravertebral muscles. Cervical active range of motion was severely limited and painful in all directions, and passive range of motion was open. Cervical provocative maneuvers could not be performed due to severe pain. Neurological examination and laboratory findings of the case were unremarkable. Atlantoaxial joint relationship and bone signals were normal on cervical magnetic resonance imaging (MRI). There was effusion at the level of the prevertebral-retropharyngeal area and the atlantoaxial joint (Figure 1). Longus colli muscle was thick and edematous. Upon these findings, when the patient was questioned again in terms of trauma, a history of severe impaction in the occipital-high cervical region was taken three days before the onset

of clinical findings. Thereupon, cranial MRI and cervical computed tomography (CT) examinations were performed for possible posttraumatic lesions. No intracranial abnormal MRI findings were detected. On CT, however, no fractures or abnormalities in joint relations were detected in the craniocervical junction or cervical region. Calcification was detected in the longus colli muscle-tendon trace in the left prevertebral area at the C1-C2 level (Figure 2). With these findings, the patient was diagnosed with ALCT. As medical treatment, ibuprofen 600 mg t.i.d. daily, tramadol 100 mg/day, cervical orthosis, and cold application were recommended. The patient's complaints decreased significantly on Day 3. At the end of the first week, the patient was completely symptom-free. In the control lateral cervical X-ray, the prevertebral soft tissue thickening was totally regressed. Although the opacity



**Figure 2.** (a, b) Cervical CT showing prevertebral soft tissue calcification and (c, d) retropharyngeal fluid collection.

CT: Computed tomography.



**Figure 3.** Lateral cervical X-ray showing soft tissue calcification caudal to anterior arc of atlas (arrow). Regression can also be noticed in prevertebral soft tissue thickening.

of the calcification adjacent to the atlas anterior arch was not as obvious as in CT, it could be seen (Figure 3).

## DISCUSSION

Although ALCT is a very rare disease, the literature on it has been increasing in recent years.<sup>[1,6]</sup> Langner et al.,<sup>[2]</sup> in their recent study including five ALCT cases, compiled a total of 116 ALCT cases in the literature, excluding their own cases. The diagnosis was made by clinical examination and CT in all these cases. Apart from the classical triad expected clinically in ALCT, findings such as occipital headache, trismus, sore throat, pharyngeal edema, mild fever, elevation in inflammation markers such as erythrocyte sedimentation rate and C-reactive protein, and leukocytosis can be observed.<sup>[4]</sup> These clinical findings can also be observed in some pathologies, particularly retropharyngeal abscess, which are more common than ALCT and may also lead to much more serious clinical pictures and adverse outcomes and sometimes require surgical intervention.<sup>[2,5]</sup> Moreover, thickening of the prevertebral soft tissue and fluid collection in the retropharyngeal area are common radiological findings that can be observed in both ALCT and retropharyngeal abscess.<sup>[2]</sup> Therefore, it is

of utmost importance to distinguish these entities, which differ greatly in terms of treatment and prognosis. While ALCT is treated conservatively with non-steroidal anti-inflammatory drugs and steroids, retropharyngeal abscess may require antibiotic therapy and surgical intervention in selected cases.<sup>[5]</sup> Detection of calcification in the longus colli tendon radiologically is pathognomonic for the diagnosis of ALCT.<sup>[4]</sup> This finding can be observed more clearly and distinctly in CT examination compared to X-ray and MRI. The latter shows edema and thickening of the prevertebral muscles better. Therefore, it seems more appropriate to use CT and MRI together in the diagnosis of ALCT.<sup>[2,4]</sup> In this way, unnecessary antibiotics and other medical treatments and invasive procedures can be prevented by making a correct diagnosis.<sup>[4]</sup> In our case, although common clinical findings and radiological prevertebral soft tissue thickening and fluid collection in the retropharyngeal distance did not work very well in terms of differential diagnosis, the diagnosis of ALCT was made without hesitation, since no post-traumatic findings were observed and CT showed prominent calcification in the prevertebral soft tissue at the atlantoaxial level.

Although calcium crystals are deposited in the longus colli tendon in ALCT, the mechanism of calcium deposition is not yet clear. However, it has been proposed that it may be secondary to repetitive trauma, recent injury, degeneration of the longus colli tendon, tissue necrosis, and ischemia.<sup>[1,5]</sup> As a result of the accumulation of these crystals, an inflammatory process that results in tendinitis is triggered, leading to the formation of reactive fluid collection in the retropharyngeal space.<sup>[5]</sup> In our case, initially cervical MRI was performed primarily considering pathologies related to cervical soft tissues. However, after a recent trauma history emerged, cervical CT examination was preferred in terms of possible fractures. Thus, prevertebral calcification could be detected. Although recurrent microtraumas are primarily considered in the etiology of ALCT, the history of acute single trauma three days before the onset of symptoms in our case raises suspicion, as it may be a triggering factor.

In conclusion, ALCT is a rare disease characterized by neck pain, limitation of movement, and odynophagia, in which thickening and calcification in the prevertebral soft tissue and fluid collection can be observed with CT, and can be treated conservatively within a few weeks with non-steroidal anti-inflammatory drugs and steroids. Whether there is trauma in the clinical history should be questioned for an accurate diagnosis. It is important to be

aware of this disease, particularly by radiologists and clinicians dealing with head and neck, to prevent unnecessary antibiotic treatment and interventional procedures.

**Patient Consent for Publication:** A written informed consent was obtained from the patient.

**Data Sharing Statement:** The data that support the findings of this study are available from the corresponding author upon reasonable request.

**Author Contributions:** Case preparation and data collection were performed: G.K., C.Z., G.N.; The first draft of the manuscript was written: G.K., O.K.: All authors contributed to the critical review. All authors read and approved the final manuscript.

**Conflict of Interest:** The authors declared no conflicts of interest with respect to the authorship and/or publication of this article.

**Funding:** The authors received no financial support for the research and/or authorship of this article.

## REFERENCES

1. Langford B, Kleinman Sween J, Penn DM, Hooten WM. Severe neck pain and odynophagia secondary to acute calcific longus colli tendinitis: A case report. *J Med Case Rep* 2020;14:148.
2. Langner S, Ginzkey C, Mlynski R, Weiss NM. Differentiation of retropharyngeal calcific tendinitis and retropharyngeal abscess: A case series and review of the literature. *Eur Arch Otorhinolaryngol* 2020;277:2631-6.
3. Hartley J. Acute cervical pain associated with retropharyngeal calcium deposit. A case report. *J Bone Joint Surg [Am]* 1964;46:1753-4.
4. Bannai T, Seki T, Shiio Y. A pain in the neck: Calcific tendinitis of the longus colli muscle. *Lancet* 2019;393:e40.
5. Ko-Keeney E, Fornelli R. Acute calcific tendinitis of the longus colli: Not all retropharyngeal fluid is an abscess. *Ear Nose Throat J* 2022;101:78-80.
6. Frei N, Bless N. Acute longus colli calcific tendinitis: A rare cause of neck pain. *Eur J Case Rep Intern Med* 2019;6:001126.