



Diagnostic Performance of Core Needle Biopsy for Characterizing Thyroidectomy Bed Lesions

So Yeong Jeong^{1, 2}, Jung Hwan Baek², Sae Rom Chung², Young Jun Choi², Dong Eun Song³, Ki-Wook Chung⁴, Won Woong Kim⁴, Jeong Hyun Lee²

¹Department of Radiology, Hanyang University Medical Center, Hanyang University Medical College, Seoul, Korea; ²Department of Radiology and Research Institute of Radiology, University of Ulsan College of Medicine, Asan Medical Center, Seoul, Korea; ³Departments of ³Pathology and ⁴Surgery, University of Ulsan College of Medicine, Asan Medical Center, Seoul, Korea

Objective: Thyroidectomy bed lesions frequently show suspicious ultrasound (US) features after thyroid surgery. Fine-needle aspiration (FNA) may not provide definitive pathological information about the lesions. Although core-needle biopsy (CNB) has excellent diagnostic performance in characterizing suspicious thyroid nodules, no published studies have evaluated the performance of CNB specifically for thyroidectomy bed lesions. Therefore, we aimed to evaluate the diagnostic performance and safety of CNB for characterizing thyroidectomy bed lesions.

Materials and Methods: A total of 124 thyroidectomy bed lesions in 113 patients (79 female and 34 male; age, 23–85 years) who underwent US-guided CNB between December 2008 and December 2020 were included. We reviewed the US imaging features of the target lesions and the histories of previous biopsies. The pathologic results, diagnostic performance for malignancy, and complications of CNB were analyzed.

Results: All samples (100%) obtained by CNB were adequate for pathological analysis. Pathological analysis revealed inconclusive results in two lesions (1.6%). According to the reference standard, 50 lesions were ultimately malignant (40.3%), and 72 were benign (58.1%), excluding the two inconclusive lesions. The performance of CNB for diagnosing malignant thyroidectomy bed lesions in the 122 lesions had a sensitivity of 98.0% (49/50), a specificity of 100% (72/72), positive predictive value of 100% (49/49), and negative predictive value of 98.6% (72/73). Eleven lesions were referred for CNB after prior inconclusive FNA results in thyroidectomy bed lesions, for all of which CNB yielded correct conclusive pathologic diagnoses. According to the pathological analysis of CNB, there were various benign lesions (58.9%, 73/124) besides recurrence, including benign postoperative lesions other than suture granuloma (32.3%, 40/124), suture granuloma (15.3%, 19/124), remnant thyroid tissue (5.6%, 7/124), parathyroid lesions (4%, 5/124), and abscesses (1.6%, 2/124). No major or minor complications were associated with the CNB procedure.

Conclusion: US-guided CNB is accurate and safe for characterizing thyroidectomy bed lesions.

Keywords: Core-needle biopsy; Fine-needle aspiration; Thyroidectomy; Ultrasonography; Thyroid; Thyroid cancer

INTRODUCTION

Overall, the incidence of thyroid surgery for thyroid cancer

Received: October 10, 2021 **Revised:** June 24, 2022

Accepted: June 30, 2022

Corresponding author: Jung Hwan Baek, MD, PhD, Department of Radiology and Research Institute of Radiology, University of Ulsan College of Medicine, Asan Medical Center, 88 Olympic-ro 43-gil, Songpa-gu, Seoul 05505, Korea.

• E-mail: radbaek@naver.com

This is an Open Access article distributed under the terms of the Creative Commons Attribution Non-Commercial License (<https://creativecommons.org/licenses/by-nc/4.0>) which permits unrestricted non-commercial use, distribution, and reproduction in any medium, provided the original work is properly cited.

is increasing worldwide [1]. Ultrasound is widely used for surveillance of the thyroidectomy bed and lateral neck for recurrent disease after thyroidectomy and has proven to be highly sensitive for detecting local tumor recurrence and cervical lymph node metastasis [2-4]. Any new lesion detected in the thyroidectomy bed using ultrasound requires further investigation to differentiate between recurrent tumors and benign cases, and an accurate assessment of these lesions is important to avoid unnecessary interventions and patient anxiety. However, thyroidectomy beds can have various other lesions as well as recurrent cancers, and the differentiation between them is not always possible with imaging techniques.

Tissue confirmation for various thyroidectomy bed lesions can be achieved through ultrasound-guided fine-needle aspiration (FNA). Although it is known to be a sensitive and specific modality for the evaluation of thyroidectomy bed lesions, previous studies reported a wide range (50%–95%) of conclusive results on FNA of thyroidectomy bed lesions [5–8].

In our hospital, we perform core-needle biopsy (CNB) for thyroidectomy bed lesions with previous inconclusive results or by request of clinicians who suspect that the results of ultrasound-guided FNA are inconclusive. However, to our knowledge, no published studies have evaluated CNB of thyroidectomy bed lesions, and we herein present our experience with ultrasound-guided CNB of thyroidectomy bed lesions.

Our study aimed to evaluate the diagnostic performance and safety of CNB for characterizing thyroidectomy bed lesions.

MATERIALS AND METHODS

Patient Selection

This retrospective study was approved by our Institutional Review Board, and written informed consent was obtained from all patients before CNB (IRB No. 2020-1824).

Between December 2008 and December 2020, 129 lesions (in 118 patients) in the operating bed after thyroidectomy were subjected to ultrasound-guided CNB. Five patients were lost to follow-up within 1 year and were excluded. Finally,

113 patients (79 female and 34 male; mean age, 56.8 ± 13.9 years; range, 23–85 years) with 124 thyroidectomy bed lesions were included. A flow chart of the study is presented in Figure 1.

Ultrasound-Guided CNB Procedures

Ultrasound examinations were performed using one of the following ultrasound systems: ATL HDI 5000 or iU22 (Philips Healthcare), EUB-7500 (Hitachi Medical Systems), Sequoia (Acuson), and RS 80 (Samsung Medison Co., Ltd.). Each system was equipped with a linear high-frequency probe (5–14 MHz). All ultrasound examinations and ultrasound-guided CNBs were performed by experienced radiologists under supervision of staff radiologists with > 14 years of clinical experience in performing and evaluating thyroid ultrasound images.

Ultrasound-guided CNBs were performed using a disposable 18-gauge double-action spring-activated needle (1.1 or 1.6 cm excursion; TSK Ace-cut; Create Medic) or a single-action core needle (TSK Steri-cut; Create Medic) after local anesthesia with 1% lidocaine [9,10]. Using a freehand technique, the core needle was advanced from the midline of the thyroidectomy bed towards the target lesion. After the tip of the needle advanced into the edge of the nodule, the distance of fire (1.1 or 1.6 cm) was measured. Then, the stylet and cutting cannula of the needle were fired sequentially. After CNB, each patient was monitored and firm local compression was applied to the biopsy site for 10–20 minutes [11].

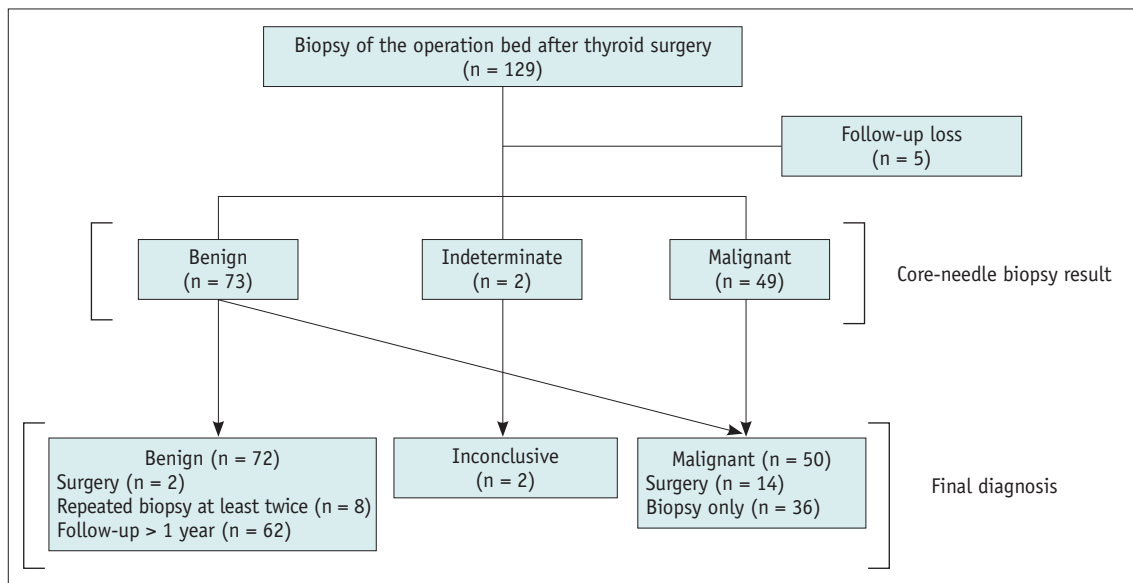


Fig. 1. Flow chart of the study. The numbers are number of lesions.

Analysis of Histologic Results

The CNB and surgical specimens were reviewed by staff histopathologists. Diagnostic criteria for CNB of the thyroidectomy bed lesions have not been standardized; therefore, in this study, CNB histological diagnoses were categorized into four categories. Non-diagnostic CNB readings included acellular specimens or adipose tissues only. Pathologic results of 'adipose tissue only' were considered the result of a mistargeting. Benign readings included suture granulomas, stromal fibrosis, granulation tissue, fibroadipose tissue, skeletal muscles, parathyroid, remnant thyroid tissue, and inflammatory lesions, including abscesses. Normal thyroid tissue was regarded as remnant thyroid tissue. An indeterminate reading was defined as atypical cells present, but insufficient for establishing a diagnosis of malignancy. A malignancy reading was defined as a specimen exhibiting atypical features sufficient for a definite diagnosis of malignancy or unequivocal features of cancer. If available, immunohistochemistry data were used to supplement the readings.

Reference Standard

Malignant lesions were diagnosed after biopsy or surgery following biopsy with specific pathological results. Benign lesions were diagnosed if they satisfied at least one of the following three criteria: 1) surgery with benign findings after CNB, 2) at least two benign findings in repeated CNB or FNA, and 3) benign findings on CNB with a stable or decreased size after more than 1 year of follow-up.

Clinical and Ultrasound Data Review

The size and location of the lesions, as well as the impression of the sonographic findings before CNB were recorded at the time of CNB. Medical records of previous operations, history of FNA or CNB at the operation bed, and laboratory findings at the time of CNB were reviewed by one of the authors (with 6 years of clinical experience in performing and evaluating thyroid ultrasound images).

Sonographic impressions of thyroidectomy bed lesions were categorized as benign, malignant, or indeterminate. Benign lesions were determined when they showed well-known typical ultrasound features, such as suture granuloma and remnant thyroid tissue [12,13]. Typical ultrasound findings of suture granulomas include lesions with internal clustered, paired, or rail-like echogenic foci, suggestive of suture materials [12,13]. Tissues appearing as normal thyroid parenchyma was considered remnant

thyroid tissue [13]. Malignant lesions were determined when the lesions without typical features of benign lesions showed hypoechoic or marked hypoechoic lesions with cystic changes, hyperechoic foci including micro/macrocalcification, and peripheral or diffuse abnormal vascularity. The reference echogenicity of the lesion was presumed to be the usual echogenicity of the normal thyroid tissue, which was determined by the radiologists who performed the ultrasonography. Indeterminate lesions were defined as those with neither malignant nor benign imaging features.

Statistical Analysis

Statistical analysis was performed using SPSS (version 19.0 for Windows; IBM Corp.). The time interval from surgery to CNB for benign and malignant lesions was compared using independent *t* tests. Diagnostic performance and the incidence of non-diagnostic, inconclusive, and conclusive results were analyzed. Diagnostic performance was determined by evaluating the diagnostic accuracy, sensitivity, specificity, positive predictive value (PPV), and negative predictive value (NPV) of CNB in thyroidectomy bed lesions by comparison with the reference standard diagnosis. For the statistical analysis, non-diagnostic, benign, and indeterminate categories were considered negative results, whereas suspicious for malignancy and malignant categories were considered positive results.

RESULTS

Demographic and Clinical Characteristics

The demographic and clinical characteristics of the patients and their lesions are summarized in Table 1. The mean longest diameter of the lesions was 14.1 ± 8.5 mm (range, 4.1–49.0 mm). The mean time interval from surgery to CNB was 89.0 ± 137.4 months. The time interval from surgery to CNB did not significantly differ between benign and malignant lesions (88.3 ± 165.9 vs. 90.0 ± 81.9 , respectively; $p = 0.944$). The average sampling number was 1.3 ± 0.5 (range 1–2). The sampling number was once in 69.4% (86/124) of cases and twice in the remaining 30.6% (38/124) of cases.

Diagnostic Performance of CNB

A sample sufficient for histopathological evaluation was obtained in 100% (124/124) of the biopsies. The conclusive result rate was 98.4% (122 of 124; 95% confidence

interval [CI]: 81.7%–100%), whereas the inconclusive result rate, including non-diagnostic and indeterminate results, was 1.6% (2 of 124; 95% CI: 0.2%–5.8%). The pathology of the two indeterminate cases was atypia of undetermined significance with architectural atypia and equivocal tumor capsule, and a few atypical cells of undetermined significance. There was no change in these two indeterminate lesions after more than 1 year of follow-up. However, as no repeated biopsy or surgery was performed to confirm the benign or malignant results, they were finally concluded to be inconclusive and excluded from the diagnostic performance calculation. Table 2 shows the performance of CNB for diagnosing malignant thyroidectomy

Table 1. Characteristics of Study Patients and Lesions

Patient Parameters	
Number	113
Age, years	56.8 ± 13.9 (23–85)
Sex	
Males	34 (30.1)
Females	79 (69.9)
Previous operation history	
Lobectomy	100 (88.5)
Total thyroidectomy	13 (11.5)
Reason for thyroidectomy	
Papillary thyroid cancer	108 (95.6)
Follicular carcinoma	2 (1.8)
Other malignancy	2 (1.8)
Nonavailable*	1 (0.9)
Nodule parameters	
No. of nodules	124
Nodule size, mm	14.1 ± 8.5 (4.1–49)
Time from initial surgery to CNB, months	
Total	89.0 ± 137.4 (1.3–1360.0)
Benign	88.3 ± 165.9 (1.3–1360.0)
Malignancy	90.0 ± 81.9 (6.8–432.2)
Reference standard diagnosis	
Benign	72 (58.1)
Malignancy [†]	50 (40.3)
Inconclusiveness	2 (1.6)
Sonographic impression	
Benign	24 (19.4)
Indeterminate	44 (35.5)
Malignancy	56 (45.2)

Data are mean ± standard deviation (range) or number of patients or lesions with % in parentheses. *One patient was referred to our hospital for a thyroidectomy bed lesion after thyroidectomy at an outside hospital, and it was unable to confirm her previous pathology, [†]Malignancy included papillary thyroid cancer, anaplastic thyroid cancer, and malignancy from another primary site. CNB = core-needle biopsy

bed lesions. The diagnostic accuracy, sensitivity, specificity, PPV, and NPV of CNB were 99.2% (121 of 122; 95% CI: 95.5%–100.0%), 98.0% (49 of 50; 95% CI: 89.5%–99.6%), 100% (72 of 72; 95% CI: 94.9%–100.0%), 100% (49 of 49; 95% CI: 92.7%–100.0%), and 98.6% (72 of 73; 95% CI: 92.6%–99.8%), respectively.

Pathologic Results of CNB

The pathologic results of CNB of thyroidectomy bed lesions are summarized in Table 3. There were 49 malignancies (43 recurrent papillary carcinomas; Figure 2, four anaplastic thyroid carcinomas, and two squamous cell

Table 2. Diagnostic Performance of CNB for Diagnosing Malignancy

	Point Estimate	95% Confidence Interval
Diagnostic accuracy	99.2 (121/122)	95.5–100.0
Sensitivity	98.0 (49/50)	89.5–99.6
Specificity	100.0 (72/72)	94.9–100.0
Positive predictive value	100.0 (49/49)	92.7–100.0
Negative predictive value	98.6 (72/73)	92.6–99.8

Data are % with the raw lesion numbers in parentheses. Non-diagnostic CNB reading included 1) absence of any identifiable tissue or cells and 2) tissue containing only a few cells insufficient for diagnosis. CNB = core-needle biopsy

Table 3. Pathologic Results of Core-Needle Biopsy at the Operation Bed after Thyroidectomy

	Total (n = 124)	Number (%)
Non-diagnostic (n = 0, 0%)		0 (0)
Benign (n = 73, 58.9%)		
Suture granuloma		19 (15.3)
Benign postoperative lesion other than suture granuloma*		40 (32.3)
Remnant thyroid tissue		7 (5.6)
Parathyroid		5 (4.0)
Abscess		2 (1.6)
Indeterminate (n = 2, 1.6%) [†]		2 (1.6)
Malignancy (n = 49, 39.5%)		
Recurrent papillary thyroid cancer		43 (34.7)
Anaplastic thyroid carcinoma		4 (3.2)
Malignancy other than thyroid origin [‡]		2 (1.6)

*Benign postoperative lesion other than suture granuloma includes stromal fibrosis, granulation tissue, and fibroadipose tissue, [†]The pathology of two indeterminate cases was atypia of undetermined significance with architectural atypia and equivocal tumor capsule, and a few atypical cells of undetermined significance. Two indeterminate cases were inconclusive results at a reference standard diagnosis, [‡]Two malignancy other than thyroid origin were squamous cell carcinoma from hypopharyngeal cancer and laryngeal cancer.

carcinomas) in the 124 CNB procedures. One squamous cell carcinoma was from hypopharyngeal cancer and one was from laryngeal cancer. The two indeterminate cases were

atypical cells of undetermined significance. The various benign lesions (73/124, 58.9%) included suture granulomas (Fig. 3), granulation, remnant thyroid tissue (Fig. 4),

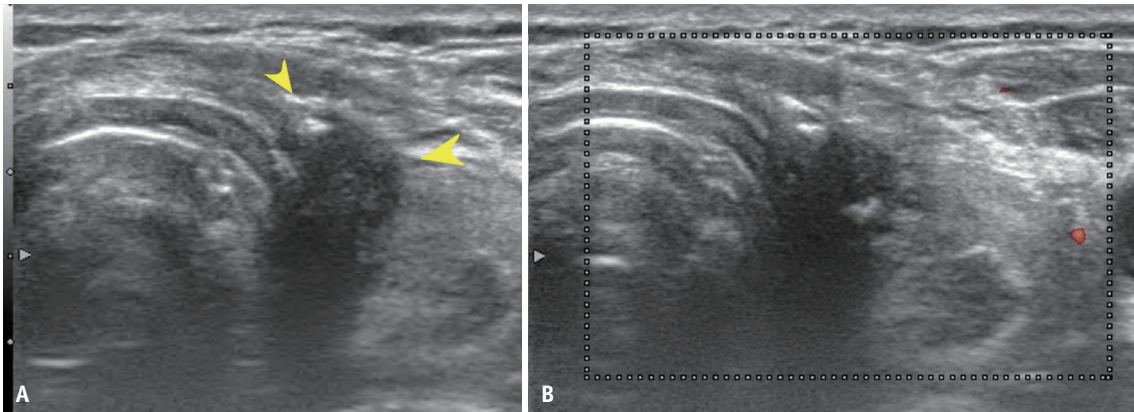


Fig. 2. A 57-year-old male with a history of total thyroidectomy due to papillary thyroid cancer 2 years previous.
A. Axial gray-scale view shows a 1.1 cm hypoechoic mass (arrowheads) at the left thyroidectomy bed. There was an inner focal macrocalcification.
B. Color Doppler image shows no definite internal vascularity. The sonographic impression of the lesion was malignant (recurrent thyroid cancer). The pathologic result of the core-needle biopsy was a recurrence of papillary thyroid cancer.

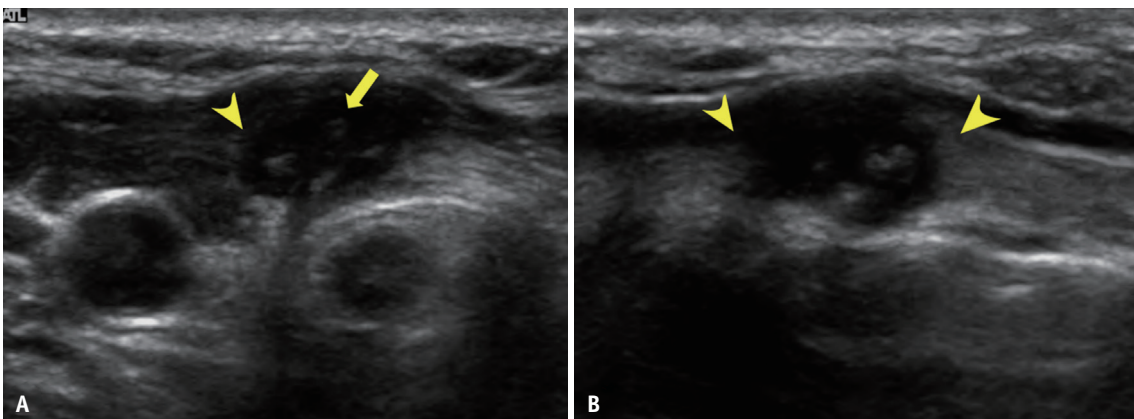


Fig. 3. A 37-year-old female with a history of total thyroidectomy due to papillary thyroid cancer 3 years previous.
A, B. Axial (**A**) and sagittal (**B**) gray-scale views show a 1.1 cm hypoechoic mass (arrowheads) with inner-paired microcalcifications (arrow) in the right thyroidectomy bed. The sonographic impression of the lesion was benign (suture granuloma). The pathologic result of the core-needle biopsy was suture granuloma.

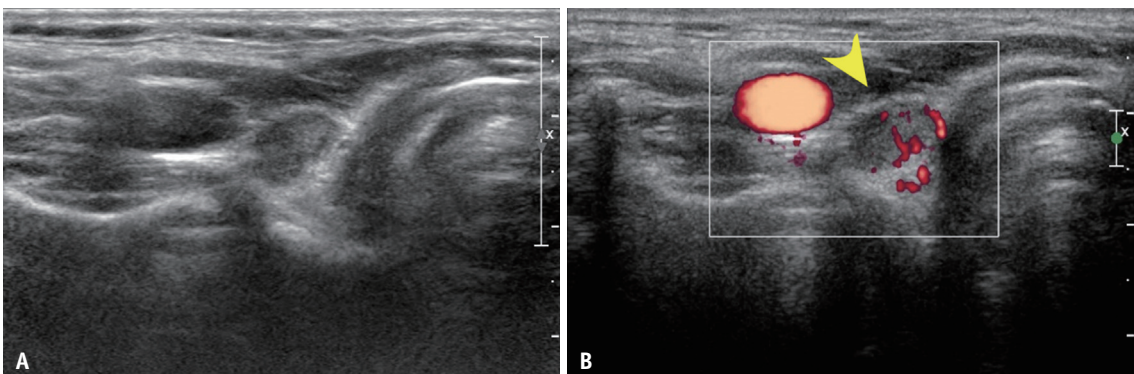


Fig. 4. A 58-year-old female with a history of total thyroidectomy due to papillary thyroid cancer 8 years previous.
A. Axial gray-scale view shows a 0.8 cm well-defined ovoid-shaped hypoechoic lesion at the right thyroidectomy operation bed. **B.** Color Doppler image shows increased internal vascularity of the mass (arrowhead). The sonographic impression of the lesion was benign (remnant thyroid tissue). The pathologic result of the core-needle biopsy was remnant thyroid tissue.

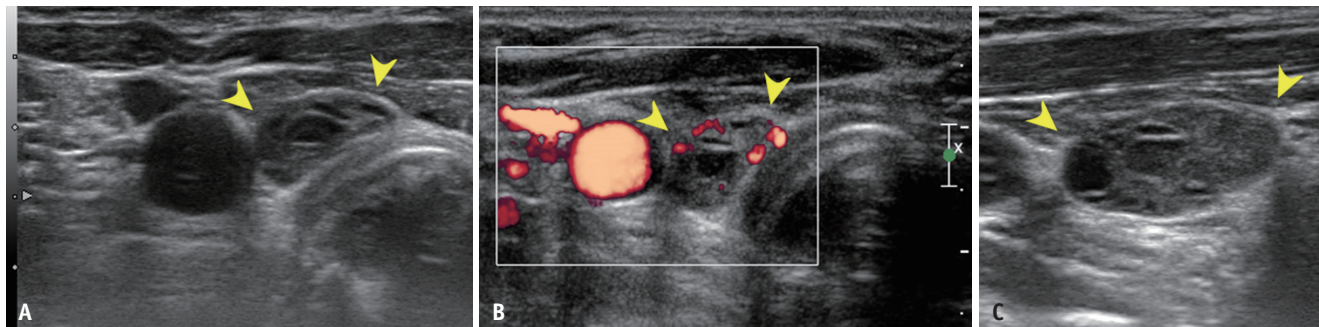


Fig. 5. A 52-year-old female with a history of right lobectomy due to papillary thyroid cancer 12 years previous. The lesion was surgically confirmed as parathyroid adenoma. **A-C.** Axial gray-scale (**A**), axial color Doppler (**B**), and sagittal gray-scale (**C**) ultrasound views show a 1.4 cm well-defined cystic and solid hypoechoic mass (arrowheads) at the right thyroidectomy bed. The sonographic impression of the lesion was malignant (recurrent thyroid cancer). The pathologic result of the core-needle biopsy was a parathyroid lesion.

Table 4. Comparison of Sonographic Impressions with CNB Results and Reference Standards

Sonographic Impression (n = 124)	CNB Results			Reference Standards		
	Benign	Indeterminate	Malignancy	Benign	Malignancy	Inconclusive
Benign (n = 24)	21	1	2	21	2	1
Indeterminate (n = 44)	31	1	12	31	12	1
Malignancy (n = 56)	21	-	35	20	36	-

CNB = core-needle biopsy

parathyroid (Fig. 5), and inflammatory lesions such as abscesses.

Of the 124 lesions, 30 (24.2%) were referred for CNB as repeated biopsies after a prior FNA (n = 27) or CNB (n = 3) of the target thyroidectomy bed lesions. Of these 30 lesions, 11 had inconclusive results at the previous biopsy, including five cases of FNA with non-diagnostic or unsatisfactory results and six cases of FNA with atypia of undetermined significance or follicular lesion of undetermined significance (indeterminate). Except for 11 inconclusive cases, 11 were benign and five were malignant on previous FNA. All 11 of these cases had correct conclusive pathological results consistent with the reference standards on repeated biopsy using CNB. One FNA case had an FNA result that was discordant with the later CNB pathologic result; in this case, the pathologic result of the initial FNA was benign, but the lesion was later confirmed as recurrent papillary thyroid cancer by CNB. Of the three cases with previous CNB, one case was benign and two were suspicious malignant with the pathology of suspicious papillary thyroid carcinoma.

Comparison of Sonographic Impressions with CNB Results and Reference Standards

Table 4 lists data reflecting comparisons of sonographic impressions, CNB results, and reference standards. In 67 out of 124 procedures (54.0%), the sonographic impressions

before the CNB were discordant with the CNB results. In 24 cases with the impression of benign on sonographic findings, two had malignant CNB results, and in 56 cases with the impression of malignancy on sonographic findings, 21 had benign CNB results, of which 20 cases were also benign according to the reference standards. Of 44 lesions with an indeterminate sonographic impression, 43 had conclusive CNB results (97.7%; 31 benign and 12 malignant), which were also concordant with the reference standards.

The sonographic impressions and reference standards were 46.0% concordant (21 benign and 36 malignant). The reference standards for 44 sonographic indeterminate lesions were 31 benignities, 12 malignancies, and 1 inconclusiveness.

Adverse Events

In all patients, CNB procedures were well tolerated and were completely performed. There were no major or minor complications associated with the CNB procedures, and no patients required hospital admission or intervention.

DISCUSSION

This is the first study to evaluate the efficacy and safety of ultrasound-guided CNB for thyroidectomy bed lesions.

Our study achieved 99.2% diagnostic accuracy without non-diagnostic results, and only 1.6% inconclusive results (2 of 124 lesions). Moreover, initially inconclusive FNA cases ($n = 11$) had conclusive results on CNB that were consistent with the reference standards. No major or minor complications were observed.

FNA is a standard procedure for the diagnosis of recurrent tumors in lymph nodes or in the thyroidectomy bed; however, inadequate cellularity or non-representative sampling can preclude an FNA-based diagnosis. To overcome this diagnostic limitation, current guidelines recommend measuring the washout thyroglobulin (Tg) concentration of the FNA specimen [4,14,15]. Although washout FNA-Tg concentration is important in assessing lesions suspected to be recurrent or metastatic, some areas of uncertainty remain, including the optimal FNA-Tg cutoff and its interpretation based on ultrasound features [16]. In addition, there can be potential false-negative results in the tall-cell or oncocyctic variant of PTC, undifferentiated/poorly differentiated carcinoma, and medullary thyroid carcinoma [17-19], or false-positive results in a remnant or ectopic thyroid lesion. Thyroidectomy bed lesions often show suspicious ultrasound features, and FNA may reveal variable cytological results such as benign, atypia of undetermined significance, or non-diagnostic results that may confuse physicians. Lesions that show persistent suspicious ultrasound features, even with benign or indeterminate cytology results, are often subjected to repeat biopsy or diagnostic surgery, which was the case for several patients in our study.

In previous studies, CNB showed excellent diagnostic performance for managing sonographically suspicious thyroid nodules, even those with initially benign, indeterminate, or nondiagnostic cytology results [20,21], which encouraged us to apply CNB to thyroidectomy bed lesions. We found that CNB yielded conclusive results for thyroidectomy bed lesions, with these results being mostly consistent with the reference standard diagnosis. We also found that CNB of thyroidectomy bed lesions was safe and showed good diagnostic value.

In our study, the diagnostic accuracy of CNB for thyroidectomy bed lesions (99.2%) was higher than that reported for FNA in previous studies. Previous studies investigating FNA of thyroidectomy bed lesions had non-negligible non-diagnostic rates, ranging from 5% to 50% [5-8]. Considering biopsy for tissue confirmation, FNA allows pathological analysis of cell cytology, but CNB provides material allowing the analysis of tissue pathology

and assessment of histologic architecture. Furthermore, scarring with desmoplastic changes at the postoperative site can yield hypocellular aspirates, which can result in inadequate, indeterminate, or false-negative cytological results. Therefore, CNB appears to be a more accurate modality than FNA for diagnosing thyroidectomy bed lesions. In our study, CNB results were excellent, with a diagnostic accuracy of 99.2%.

The main reason for biopsies of thyroidectomy bed lesions is the concern about recurrent tumors. However, the thyroidectomy operation bed is subject to various lesions other than recurrence, and some of these lesions can mimic recurrent tumors. Previous studies of thyroidectomy bed lesions have reported various recurrent tumor-mimicking benign lesions, including suture granuloma, parathyroid lesion, postoperative spindle cell tumor, fat necrosis, and nodular contoured strap muscles [8,22-25]. Because of the variety of possible lesions of the thyroidectomy operation bed, diagnosis of the lesion through cell cytology may be difficult and often inconclusive. In our study, 58.9% (73/124) of the lesions were benign on CNB pathology. Among these benign lesions, postoperative granuloma was the most common, followed by suture granuloma. Other than postoperative and suture granulomas, the various lesions included remnant thyroid tissue, parathyroid lesions, and abscesses. Understanding the various benign thyroidectomy bed lesions may allow us to avoid performing unnecessary invasive procedures.

In our study, ultrasound-guided CNB of thyroidectomy bed lesions was well tolerated without any complications. There were no large case studies evaluating the safety of CNB for thyroidectomy bed lesions; however, a previous large population study of CNB for thyroid nodules showed a low complication rate (0.33%) with no major complications and a higher sensitivity than FNA [26]. Therefore, if CNB can be performed by clinically experienced and trained operators under ultrasound guidance, it could be a safe and effective modality for the diagnosis of thyroidectomy bed lesions.

Currently, there are no established imaging assessment guidelines or diagnostic criteria for lesions in thyroidectomy beds. In our study, we applied modified guidelines for thyroid nodules or lymph nodes to the sonographic findings of thyroidectomy bed lesions. Sonographic impressions were only 46.0% consistent with both the CNB results and reference standards. In other words, sonographic impressions are often inaccurate for thyroidectomy bed lesions, and further evaluation is required. US-guided CNB

may be the method of choice for tissue confirmation. Previous studies evaluating the diagnostic performance for non-diagnostic lymph nodes or thyroid nodules also showed higher diagnostic performance with CNB than with FNA [26]. Furthermore, both CNB and FNA are safe and have low incidences of complications.

The major limitations of our study are its retrospective design and the small number of cases. Even with a long enrollment period, the number of CNBs performed in thyroidectomy cases was small, limiting the statistical power of the study results. Due to its retrospective design, sonographic features were assessed using previously captured images. Thus, further large-scale prospective studies are required to validate our results. A second limitation is that because of the long-term enrollment, CNB was performed by various radiologists using a variety of equipment. Nevertheless, CNB at the thyroidectomy site showed a high diagnostic performance. Our study only included CNB cases performed under the supervision of three staff radiologists with more than 14 years of clinical experience in performing and evaluating thyroid ultrasound images. A third limitation is that lesions that were too small to be subjected to CNB were not eligible. In our study, all procedures were performed by experienced radiologists. Therefore, when the biopsy is performed by a physician with less expertise, a core needle biopsy targeting the thyroidectomy bed lesion is only applicable when the size of the nodule is sufficiently large, and careful manipulation is needed due to anatomical difficulty. A fourth limitation is that lesions that did not change or become smaller after 1 year or more of follow-up were diagnosed as benign lesions. Thyroid cancer has a relatively slow progression course; therefore, such diagnostic criteria may be unreliable. Lastly, the indications for core needle biopsy in thyroidectomy bed lesions have not yet been determined. Therefore, there were no specific criteria for the patients included in our study, but the patients were selected mainly by the clinicians who requested the biopsy. Therefore, the selection of these study patient groups may have included a selection bias. In this regard, more in-depth studies and guidelines for thyroidectomy bed lesions are needed.

In conclusion, this study demonstrated that ultrasound-guided CNB is accurate and safe for characterizing thyroidectomy bed lesions.

Availability of Data and Material

The datasets generated or analyzed during the study are

not publicly available due privacy protection and ethics division principle but are available from the corresponding author on reasonable request.

Conflicts of Interest

Jung Hwan Baek and Jeong Hyun Lee who is on the editorial board of the *Korean Journal of Radiology* was not involved in the editorial evaluation or decision to publish this article. All remaining authors have declared no conflicts of interest.

Author Contributions

Conceptualization: So Yeong Jeong, Jung Hwan Baek, Sae Rom Chung, Young Jun Choi, Jeong Hyun Lee. Data curation: So Yeong Jeong, Jung Hwan Baek, Sae Rom Chung, Young Jun Choi, Jeong Hyun Lee. Formal analysis: So Yeong Jeong, Jung Hwan Baek. Investigation: all authors. Methodology: So Yeong Jeong, Jung Hwan Baek. Project administration: So Yeong Jeong, Jung Hwan Baek, Sae Rom Chung, Young Jun Choi, Jeong Hyun Lee. Supervision: Jung Hwan Baek, Sae Rom Chung, Young Jun Choi, Jeong Hyun Lee. Validation: all authors. Visualization: all authors. Writing—original draft: So Yeong Jeong, Jung Hwan Baek. Writing—review & editing: So Yeong Jeong, Jung Hwan Baek.

ORCID iDs

So Yeong Jeong

<https://orcid.org/0000-0003-4705-0008>

Jung Hwan Baek

<https://orcid.org/0000-0003-0480-4754>

Sae Rom Chung

<https://orcid.org/0000-0003-4219-7166>

Young Jun Choi

<https://orcid.org/0000-0001-7098-5042>

Dong Eun Song

<https://orcid.org/0000-0002-9583-9794>

Ki-Wook Chung

<https://orcid.org/0000-0002-4418-1857>

Won Woong Kim

<https://orcid.org/0000-0003-3471-2068>

Jeong Hyun Lee

<https://orcid.org/0000-0002-0021-4477>

Funding Statement

None

REFERENCES

- Burgess JR, Tucker P. Incidence trends for papillary thyroid carcinoma and their correlation with thyroid surgery and thyroid fine-needle aspirate cytology. *Thyroid* 2006;16:47-53
- do Rosário PW, Fagundes TA, Maia FF, Franco AC, Figueiredo MB, Purisch S. Sonography in the diagnosis of cervical recurrence in patients with differentiated thyroid carcinoma. *J Ultrasound Med* 2004;23:915-920; quiz 921-922
- Lee YH, Lee NJ, Kim JH, Song JJ. US diagnosis of cervical recurrence in patients operated on thyroid cancer: sonographic features and clinical significance. *Auris Nasus Larynx* 2007;34:213-219
- Haugen BR, Alexander EK, Bible KC, Doherty GM, Mandel SJ, Nikiforov YE, et al. 2015 American Thyroid Association management guidelines for adult patients with thyroid nodules and differentiated thyroid cancer: the American Thyroid Association guidelines task force on thyroid nodules and differentiated thyroid cancer. *Thyroid* 2016;26:1-133
- Bishop JA, Owens CL, Shum CH, Ali SZ. Thyroid bed fine-needle aspiration: experience at a large tertiary care center. *Am J Clin Pathol* 2010;134:335-339
- Frates MC, Parziale MP, Alexander EK, Barletta JA, Benson CB. Role of sonographic characteristics of thyroid bed lesions identified following thyroidectomy in the diagnosis or exclusion of recurrent cancer. *Radiology* 2021;299:374-380
- Park DS, Cho JS, Park MH, Ryu YJ, Hwang MJ, Shin SH, et al. Malignant thyroid bed mass after total thyroidectomy. *J Korean Surg Soc* 2013;85:97-103
- Shin JH, Han BK, Ko EY, Kang SS. Sonographic findings in the surgical bed after thyroidectomy: comparison of recurrent tumors and nonrecurrent lesions. *J Ultrasound Med* 2007;26:1359-1366
- Yeon JS, Baek JH, Lim HK, Ha EJ, Kim JK, Song DE, et al. Thyroid nodules with initially nondiagnostic cytologic results: the role of core-needle biopsy. *Radiology* 2013;268:274-280
- Na DG, Kim JH, Sung JY, Baek JH, Jung KC, Lee H, et al. Core-needle biopsy is more useful than repeat fine-needle aspiration in thyroid nodules read as nondiagnostic or atypia of undetermined significance by the Bethesda system for reporting thyroid cytopathology. *Thyroid* 2012;22:468-475
- Suh CH, Baek JH, Lee JH, Choi YJ, Kim JK, Sung TY, et al. The role of core-needle biopsy as a first-line diagnostic tool for initially detected thyroid nodules. *Thyroid* 2016;26:395-403
- Kim JH, Lee JH, Shong YK, Hong SJ, Ko MS, Lee DH, et al. Ultrasound features of suture granulomas in the thyroid bed after thyroidectomy for papillary thyroid carcinoma with an emphasis on their differentiation from locally recurrent thyroid carcinomas. *Ultrasound Med Biol* 2009;35:1452-1457
- Ko MS, Lee JH, Shong YK, Gong GY, Baek JH. Normal and abnormal sonographic findings at the thyroidectomy sites in postoperative patients with thyroid malignancy. *AJR Am J Roentgenol* 2010;194:1596-1609
- Shin JH, Baek JH, Chung J, Ha EJ, Kim JH, Lee YH, et al. Ultrasonography diagnosis and imaging-based management of thyroid nodules: revised Korean Society of Thyroid Radiology consensus statement and recommendations. *Korean J Radiol* 2016;17:370-395
- Russ G, Bonnema SJ, Erdogan MF, Durante C, Ngu R, Leenhardt L. European Thyroid Association guidelines for ultrasound malignancy risk stratification of thyroid nodules in adults: the EU-TIRADS. *Eur Thyroid J* 2017;6:225-237
- Chung SR, Baek JH, Choi YJ, Sung TY, Song DE, Kim TY, et al. Diagnostic algorithm for metastatic lymph nodes of differentiated thyroid carcinoma. *Cancers (Basel)* 2021;13:1338
- Baloch ZW, Barroeta JE, Walsh J, Gupta PK, Livolsi VA, Langer JE, et al. Utility of thyroglobulin measurement in fine-needle aspiration biopsy specimens of lymph nodes in the diagnosis of recurrent thyroid carcinoma. *Cytojournal* 2008;5:1
- Borel AL, Boizel R, Faure P, Barbe G, Boutonnat J, Sturm N, et al. Significance of low levels of thyroglobulin in fine needle aspirates from cervical lymph nodes of patients with a history of differentiated thyroid cancer. *Eur J Endocrinol* 2008;158:691-698
- Baldini E, Sorrenti S, Di Gioia C, De Vito C, Antonelli A, Gnessi L, et al. Cervical lymph node metastases from thyroid cancer: does thyroglobulin and calcitonin measurement in fine needle aspirates improve the diagnostic value of cytology? *BMC Clin Pathol* 2013;13:7
- Chung SR, Baek JH, Choi YJ, Sung TY, Song DE, Kim TY, et al. The role of core needle biopsy for the evaluation of thyroid nodules with suspicious ultrasound features. *Korean J Radiol* 2019;20:158-165
- Ha EJ, Baek JH, Lee JH, Song DE, Kim JK, Shong YK, et al. Sonographically suspicious thyroid nodules with initially benign cytologic results: the role of a core needle biopsy. *Thyroid* 2013;23:703-708
- Bin Saeedan M, Aljohani IM, Khushaim AO, Bukhari SQ, Elnaas ST. Thyroid computed tomography imaging: pictorial review of variable pathologies. *Insights Imaging* 2016;7:601-617
- Park SH, Han JK, Lee CK, Jo SS, Kim HH, Bae WK, et al. Cervical thoracic duct cyst: a case report. *J Korean Radiol Soc* 2007;56:541-544
- Kang M, Ha SY, Cho HY, An J, Chung DH, Chung YS. Fine needle aspiration cytology of postoperative spindle cell nodule in neck after thyroidectomy: a case report. *Korean J Pathol* 2013;47:89-91
- Ku EJ, Park JW. A postoperative spindle cell tumor in the thyroid bed resembling recurrent papillary thyroid carcinoma: a 4.5-year follow-up case report. *Int J Clin Exp Med* 2020;13:8127-8131
- Suh CH, Baek JH, Choi YJ, Kim TY, Sung TY, Song DE, et al. Efficacy and safety of core-needle biopsy in initially detected thyroid nodules via propensity score analysis. *Sci Rep* 2017;7:8242