

Oncology

Managing Renal Cell Carcinoma Associated Paraneoplastic Syndrome with Nephron-sparing Surgery in a Patient with von Hippel-Lindau



John M. DiBianco^a, Julie Y. An^{b,*}, Sally Tanakchi^c, Zachary Stanik^b, Aidan McGowan^b, Mahir Maruf^b, Abhinav Sidana^b, Amit Lodha Jain^b, Akhil Muthigi^b, Arvin K. George^b, Christopher Bayne^a, W. Marston Linehan^b, Shawna L. Boyle^{b,**}, Adam R. Metwalli^b

^a School of Medicine and Health Sciences, The George Washington University, Washington, DC, USA

^b Urologic Oncology Branch, Center for Cancer Research, National Cancer Institute, Bldg. 10, Hatfield Clinical Research Center, Rm 2 W-3952 10 Center Drive MSC 1210, 20892-1210, Bethesda, MD, USA

^c Laboratory of Pathology, National Cancer Institute, National Institutes of Health, Bethesda, MD, USA

ARTICLE INFO

Article history:

Received 16 February 2017

Accepted 23 February 2017

Keywords:

RCC

Oncology

Paraneoplastic

VHL

Partial nephrectomy

ABSTRACT

A patient with germline von Hippel-Lindau (VHL) gene alteration and history of multiple tumors present with classical paraneoplastic syndrome (PNS) associated with renal cell carcinoma (RCC). She underwent open nephron sparing surgery with resolution of symptoms. She remained without recurrence of RCC for the initial 2 years of her follow-up. To the best of our knowledge, this case represents the first in which PNS was specifically resolved using a partial nephrectomy in a patient with VHL. This case report provides initial evidence for the potential role of nephron sparing surgery in the management of paraneoplastic symptoms associated with hereditary RCC.

© 2017 Published by Elsevier Inc. This is an open access article under the CC BY-NC-ND license (<http://creativecommons.org/licenses/by-nc-nd/4.0/>).

Introduction

Renal cell carcinoma (RCC), accounts for 85% of renal neoplasms with an incidence of more than 60,000 new cases yearly.¹ As many as one-third of patients with RCC have reported symptoms of paraneoplastic syndrome (PNS).¹ The presence of paraneoplastic syndromes with RCC does not indicate occult metastases, nor is it a contraindication for surgery; however, it may correlate with a worse prognosis.¹

von Hippel-Lindau (VHL) is a hereditary condition associated with multiple, recurrent clear-cell RCC.² We report the case of a VHL patient with a rapidly growing RCC and clinical evidence of severe PNS which resolved following partial nephrectomy.

Case presentation

A 49-year-old female with a history of von Hippel-Lindau with a germline *VHL* gene mutation, presented to the National Institutes of Health (NIH) with persistent nausea, vomiting, fevers and symptomatic, transfusion-dependent anemia. Previously, she had been followed for her VHL at NIH for more than 12 years. At the time of admission, the patient had experienced 5 months of episodic fevers, chills with increasing frequency and duration. The patient also reported progressive fatigue, anorexia and a 15–20 lbs unintentional weight-loss. Upon admission, the patient was febrile (37.8 °C) with profound anemia and orthostatic hypotension.

The patient's past medical history included the diagnosis of VHL when retinal angiomas were identified at the age of 9. Additional medical history was notable for breast and lung cancers in addition to VHL-associated tumors (bilateral RCC, central nervous system hemangioblastomas, and pancreatic neuroendocrine tumors). Surgical history included left breast lumpectomy and radiation, left lingulectomy and mediastinal node dissection, multiple bilateral partial nephrectomy (the last intervention was 8 years prior in the ipsilateral kidney), and multiple neurosurgical interventions. The

Abbreviations and acronyms: PNS, Paraneoplastic syndrome; RCC, Renal cell carcinoma; VHL, von Hippel-Lindau disease.

* Corresponding author. Fax: +1 301 402 0922.

** Corresponding author.

E-mail addresses: julieyajean@gmail.com, julie.an@mail.nih.gov (J.Y. An).

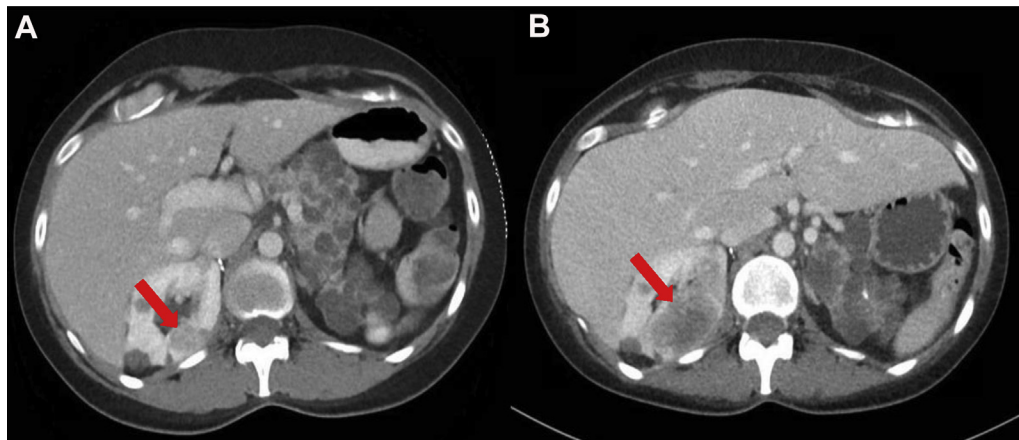


Figure 1. Preoperative axial computed tomography scans revealed a renal mass located in the right posterior upper pole that grew from approximately 2 cm (A) to 5 cm (B) in 5 months.

patient reported no prior history of paraneoplastic syndromes with previous malignancies.

A comprehensive infectious, gastrointestinal, and pulmonary workup failed to reveal a clear etiology of her symptoms. A computed tomography (CT) scan of the chest/abdomen/pelvis revealed a right upper pole RCC that grown dramatically compared to a previous CT performed 5 months earlier. Other enhancing lesions in both kidneys remained unchanged (Fig. 1). Nuclear scintigraphy also noted the right renal mass as well as stable nonspecific retroperitoneal adenopathy but no evidence of soft tissue or bone metastases. Renal mass biopsy showed poorly differentiated, Fuhrman grade 4 RCC with focal clear cell features and extensive necrosis (Fig. 2). Immunohistochemistry staining was positive for CD10 in tumor cells, and negative for CK7, TTF-1, ER, and PR. In the absence of any infectious, hematologic or pulmonary etiology, we suspected this neoplasm to be the cause of her recurring fevers and PNS as a diagnosis of exclusion. This conclusion was corroborated by consultants from infectious disease, pulmonology, thoracic oncology and internal medicine. The summary of the patient's additional hospital evaluation is presented in Table 1.

The patient underwent an open right partial nephrectomy to excise the renal mass. During the procedure, the right upper pole 5.5 cm mass was excised using wide margins due to the tumor's aggressive growth kinetics. Four other solid tumors were identified using intraoperative ultrasound and enucleated per our previously described technique.²

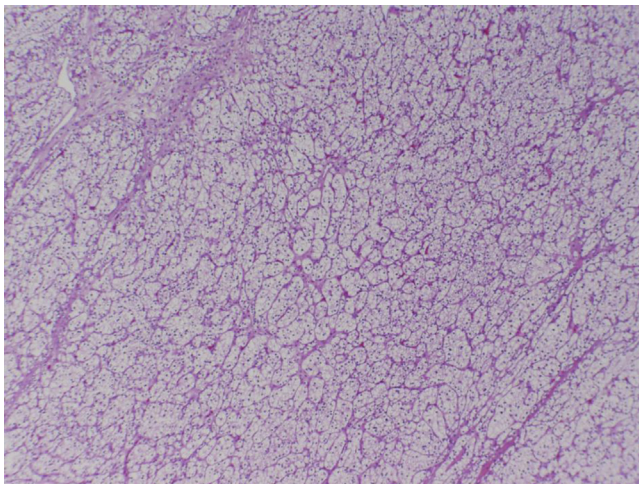


Figure 2. Renal cell carcinoma, clear cell type, Fuhrman nuclear grade 2.

The postoperative hospitalization was uneventful, and the patient was discharged approximately 2 weeks after surgery once her fevers, nausea and vomiting had resolved. At the patient's 3 month follow up visit, internal medicine consultation confirmed resolution of paraneoplastic syndrome symptoms (anorexia, transfusion dependent anemia).

Her follow up HCT had normalized to 42.0%. While the patient remained PNS symptom free over 2 years follow-up, she has recently been diagnosed with a locally recurrent right kidney tumor with hepatic metastasis.

Discussion

Paraneoplastic syndromes are rare, particularly in hereditary RCC conditions, however being familiar with their symptomatology is important to minimize patient morbidity and for surgical planning,³ and rapid recognition of PNS symptoms can lead to the diagnosis of a biologically aggressive neoplasm.³ The patient in this case presented with fever, one of the most common constitutional manifestations of paraneoplastic syndrome, present in 20–30% of RCC cases.³ It is thought that fever and other constitutional symptoms of paraneoplastic syndrome are caused by cytokines and pyrogens, such as tumor necrosis factor- β , interleukin-6 (IL-6), and IL-1, released by the tumor cells.³ Historically, paraneoplastic syndromes arising from RCC have been treated definitively with nephrectomy which has been shown to often reverse signs and symptoms of the PNS.³ However, since VHL typically manifests in bilateral and multifocal RCC and renal cysts, identifying the causative tumor may be challenging.⁴ Fortunately, an extensive review of the literature revealed no reported cases of paraneoplastic syndromes in VHL patients suggesting this a rare event. To the best of our knowledge, this case represents the first in which paraneoplastic syndrome was specifically resolved using a partial nephrectomy in a patient with VHL.

Before surgical intervention, the patient's condition had deteriorated dramatically, believed to be the result of her rapidly growing renal mass, which was identified because of the radiographic surveillance that is commonplace for VHL patients.⁴ The rapid growth was concerning and unusual for VHL-associated tumors which typically grow only 3–5 mm per year in longest dimension.⁴ After the partial nephrectomy, the patient's paraneoplastic syndrome resolved and her condition dramatically improved. Use of intraoperative ultrasound to identify and enucleate numerous solid tumors during the partial nephrectomy, simultaneously delayed the need for further surgical intervention

Table 1
Summary of hospital evaluation and results.

Metabolic	Metabolic: Na+ 138, K+ 4.2, Cl- 99, CO2 24, ^a glucose 112 (74–106 mg/dL), BUN 15, creatinine 0.86, eGFR 79, ^a Ca+ 2.41, Mg+ 0.86, phosphorus 2.7 Hepatic: ^a Albumin 2.8 (3.5–5.2 g/dL), ^a alk phos 601 (35–105 U/L), ALT 17, AST 13, T.Bili 1.1, ^a D.Bili 0.8 (0–0.3 mg/dL); Coag: ^a PT 16.2 (11.6–15.2 sec), ^a aPTT 48.7 (25.3–37.3 sec), Lipid: cholesterol 135, HDL 10, LDL 98, triglycerides 135.
Infectious	C-peptide 4.1 UA: protein 2+ (100 mg/dL), leukocyte esterase 3+, WBC 141, squamous epithelial cells 51
Hematologic	CBC: ^a Hgb 9.5 g/dL (reduced 11.4 g/dL one month prior), ^a Hct 31.3%, WBC of 9.31 × 10 ³ , platelet 653 K/uL, Anemia: MCV 81.5, reticulocyte count 1.19 (0.5–1.70%), absolute reticulocyte 45.5 (16.4–77.6 K/uL), ^a erythropoietin 26.7 (2.6–18.5 mIU/mL), ^a haptoglobin 694 (30–200 mg/dL) LDH 138 U/L, ^a iron 24 (37–145 mcg/dL), ^a transferrin 93 (200–360 mg/dL), ^a saturation 18% (20–50%), ^a ferritin 4964 (13–150 mcg/L), serum vitamin B12 439 (200–900 pg/mL). Peripheral blood smear: ^a confirmed thrombocytosis, a few red blood cells with central pallor, and many normal appearing red blood cells, consistent with prior transfusion. Bone marrow biopsy: performed 3 months prior was within normal range.
Gastrointestinal	Colonoscopy and upper endoscopy did not identify any source of bleeding.
Pulmonary	No pulmonary pathology was noted on CT chest. Thoracic oncology consult did not identify any potential thoracic etiology.
Endocrine	HgbA1c 5.7% with estimated average glucose 117 mg/dL, serum insulin level 9.4, TSH 1.0, intact PHT 20.9, FSH 24.5, LH 20.5, serum estradiol 38.8, serum progesterone 0.5

^a Significant and/or abnormal findings. (Nonmetastatic hepatic dysfunction, hypoglycemia, microcytic hypochromic iron deficiency anemia w/elevated epo).

while also ensuring the removal of the tumor cells secreting the causative cytokines, effectively managing the patient's paraneoplastic syndrome. While the patient's subsequent development of metastases is most likely due to the aggressive biology of this tumor rather than the choice of partial nephrectomy rather than radical nephrectomy,⁵ further studies are needed to confirm that.

Conclusion

To the best of our knowledge, this case represents the first in which paraneoplastic syndrome was specifically resolved using a

partial nephrectomy in a patient with VHL. We believe this case represents the potential of nephron sparing surgery for managing the paraneoplastic symptoms associated with hereditary RCC.

Consent

This patient is followed by the Clinical Manifestations and Molecular Bases of Heritable Urologic Malignant Disorders (Trial NCT00001238). All patients under this protocol have provided informed consent.

Conflict of interest

None.

Acknowledgements

This research was supported by the Intramural Research Program of the NIH, National Cancer Institute, Center for Cancer Research and the National Institutes of Health (NIH) Medical Research Scholars Program, a public–private partnership supported jointly by the NIH and generous contributions to the Foundation for the NIH from the Doris Duke Charitable Foundation, The American Association for Dental Research, the Colgate-Palmolive Company, Genentech and alumni of student research programs and other individual supporters via contributions to the Foundation for the National Institutes of Health.

References

- Palapattu GS, Kristo B, Rajfer J. Paraneoplastic syndromes in urologic malignancy: The many faces of renal cell carcinoma. *Rev Urol.* 2002;4(4):163–170.
- Metwalli AR, Linehan WM. Nephron-sparing surgery for multifocal and hereditary renal tumors. *Curr Opin Urol.* 2014;24(5):466–473.
- Sacco E, Pinto F, Sasso F, et al. Paraneoplastic syndromes in patients with urological malignancies. *Urol Int.* 2009;83(1):1–11.
- Bausch B, Jilg C, Glasker S, et al. Renal cancer in von Hippel-Lindau disease and related syndromes. *Nat Rev Nephrol.* 2013;9(9):529–538.
- Van Poppel H, Da Pozzo L, Albrecht W, et al. A prospective, randomised EORTC intergroup phase 3 study comparing the oncologic outcome of elective nephron-sparing surgery and radical nephrectomy for low-stage renal cell carcinoma. *Eur Urol.* 2011;59(4):543–552.