

Radioiodine (¹³¹I) therapy in a child with autism spectrum disorder: A complex and demanding task

ABSTRACT

In January 2017, an 11.5-year-old male child with autism was referred for radioiodine (RAI) therapy post total thyroidectomy for papillary thyroid carcinoma. The treatment required swallowing a RAI capsule and remaining isolated (48–72 h). Initially, obstacles to a successful treatment seemed insurmountable as he had complex needs and behavioral issues due to his autism, mild intellectual disability, and family environment. His mother was adamant that he would not be able to swallow the capsule and comply with the required isolation period. A multidisciplinary team was formed to explore options for successful treatment. Each option considered had its own risks and challenges. Behavioral therapy was considered to be the only possible option. It was pursued with regular, frequent contact between the child, his parents, and members of the team for counseling and behavioral modification, familiarization of the child with the staff, procedures, trial visits, and admission. The patient was successfully treated in October 2017.

Keywords: Autism spectrum disorder, isolation, lung metastases, papillary thyroid carcinoma, pediatric, radioiodine therapy

INTRODUCTION

The 11.5-year-old child, co-slept with his mother, was not responsible for his own personal hygiene, including toileting, had a very selective diet, and was not keen to go to school. He attended a special school because of his autism but following the thyroidectomy operation had not returned to school, despite full medical recovery. He also received assistance with feeding. His mother demonstrated a reluctance to progress his independence. A multidisciplinary team was formed to work diligently with the child and mother to train him and change his and his mother's behavior.

CASE REPORT

Total thyroidectomy and adjuvant radioiodine (¹³¹I) (RAI) therapy is the accepted standard treatment of patients with thyroid carcinoma but is challenging for children with behavioral issues. In fact, in a recent reported case of a child with autism spectrum disorder, RAI treatment was abandoned due to behavior-related issues and the patient was treated

with sorafenib^[1] as a second-line option. For our 11.5-year-old child, it became clear, from the first consultation session, that behavioral obstacles related to the child's autism, intellectual disability, and family environment needed to be overcome. The two main issues for the treatment were how to administer the RAI and how to keep the patient confined. A multidisciplinary team consisting of a nuclear medicine physician, oncologist, nuclear medicine technologist, hospital radiation safety officer (RSO), clinical psychologist, oncology nursing manager, anesthetist, and play therapist was formed to consider the various options to pursue the treatment. Options included extended general anesthesia which would

**GIOVANNI BIBBO, IAN KIRKWOOD,
VICTORIA SIGALAS, TRACY BENGER**

SA Medical Imaging, Women's and Children's Hospital,
South Australia, Australia


Address for correspondence: Dr. Giovanni Bibbo,
SA Medical Imaging, Women's and Children's Hospital, 72 King
William Road, North Adelaide 5006, South Australia, Australia.
E-mail: giovanni.bibbo@sa.gov.au

This is an open access journal, and articles are distributed under the terms of the Creative Commons Attribution-NonCommercial-ShareAlike 4.0 License, which allows others to remix, tweak, and build upon the work non-commercially, as long as appropriate credit is given and the new creations are licensed under the identical terms.

For reprints contact: reprints@medknow.com

How to cite this article: Bibbo G, Kirkwood I, Sigalas V, Benger T. Radioiodine (¹³¹I) therapy in a child with autism spectrum disorder: A complex and demanding task. World J Nucl Med 2019;18:293-5.

Submission: 12-Apr-18, **Accepted:** 14-May-18

Access this article online	
Website: www.wjnm.org	Quick Response Code 
DOI: 10.4103/wjnm.WJNM_40_18	

have allowed the administration of the RAI in liquid form via nasogastric tube and kept the child sedated for the isolation period; the mother being allowed to stay in the room during treatment and co-sleep with the son, and treatment at home. These options were not pursued because of radiation safety issues. Transferring patient to another facility was also considered as an interstate pediatric facility had sedated younger children for ^{131}I meta-iodobenzylguanidine therapy. However, because of the complexity of the transfer that unfolded, this ceased to be an option. Restraint and medication were also considered as the last resorts if the parents refused life-saving treatment.

Counseling and behavioral modifications seemed the only possible option and was diligently pursued over 9 months. It involved regular and frequent contact between the clinical psychologist, nuclear medicine personnel, and the play therapist with the family. During weekly consultations with the nuclear medicine staff, the mother was encouraged not to sleep with her son and for him to trial swallowing solid medication. Visits to the therapy room [Figure 1] were made on these occasions. Over time, a rapport developed between hospital staff, the child, and parents.

A diagnostic iodine (^{123}I) study performed in August 2017 demonstrated metastatic spread of his thyroid cancer. The parents realized the urgency of the treatment and the mother placed more effort in training the son to sleep alone in a separate bed and to take care of his personal hygiene. Overnight stay trials in the therapy room were organized. The initial trial was not successful but a subsequent trial was. Multiple trials at the hospital for him to swallow a placebo capsule were successful.

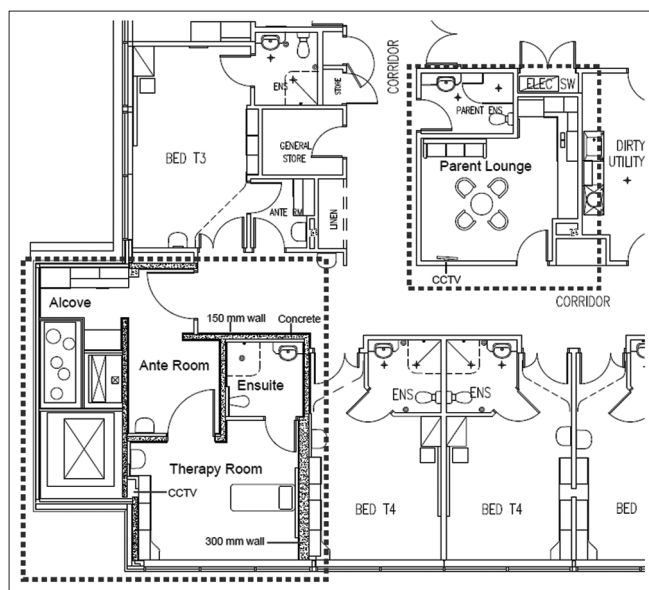


Figure 1: Layout of the therapy suite and adjacent areas

The patient was admitted for therapy on October 11, 2017, in a child-friendly purpose-built therapy suite [Figure 1] and administered with 7989 MBq of RAI in two capsules. The patient swallowed the capsules without any issues. He had been prepared with thyroxine withdrawal for 3 weeks and a low iodine diet for 2 weeks.

The therapy suite has a shielded alcove where the mother stayed overnight. A small bed can fit in this area. For entertainment, the patient was provided with a computer connected to the Internet, Wi-Fi, iPad, X-Box, DVD, craft, and books. Other treasured items were brought from home. To delineate the therapy room from the rest of the therapy suite, he was asked to set up a barrier made of playpen extension panels.^[2] He took ownership of this barrier and during the isolation period made no effort to cross the barrier which he considered was his. The parents were monitored continuously with electronic pocket dosimeters with alarms set on both dose rate and cumulative dose.

The administration of RAI was successful; however, within a few hours, the patient felt cold related to hypothyroidism. The room temperature was increased and the patient kept warm with extra blankets. He then had three episodes of vomiting at 6.7, 11.67, and 29.67 h posttreatment despite having taken anti-emetic medication. Another complication was constipation, also due to hypothyroidism.

The mother provided the main care to her son. The father was there at intermittent periods. She received a personal accumulated radiation equivalent dose of $97\ \mu\text{Sv}$, while the father received $23.8\ \mu\text{Sv}$ and all nursing staff received $13\ \mu\text{Sv}$. The RSO measured the external radiation dose rate from the patient at a distance of 3 m with a survey meter at a regular time during working hours and after the three

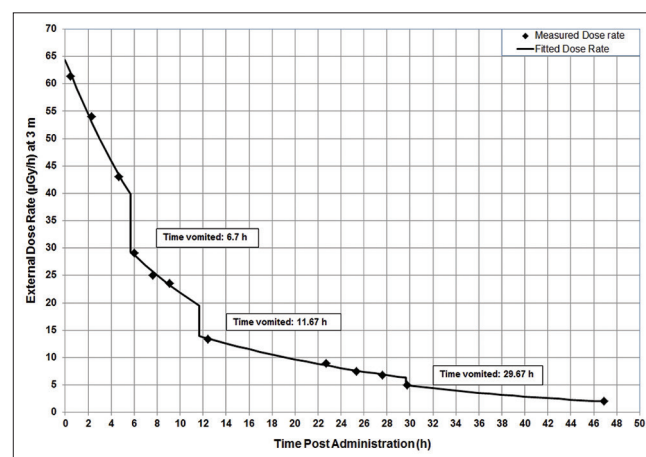


Figure 2: Measured external radiation dose rate as a function of time postadministration of radioiodine

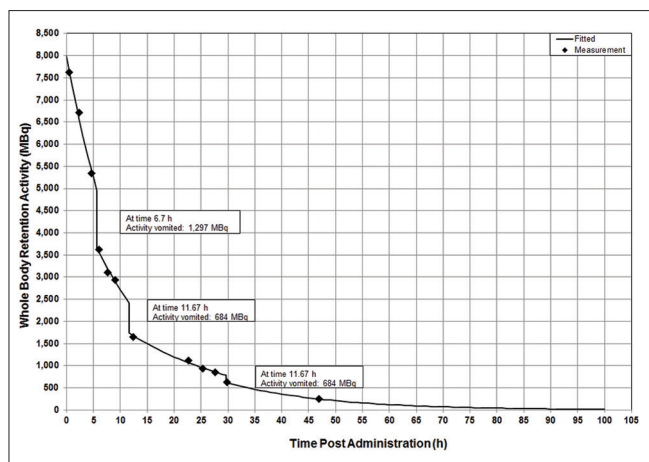


Figure 3: Whole-body retention time-activity as a function of time postadministration of radioiodine

episodes of vomiting. The external radiation dose rate curves for both raw data and exponential fitted curves are shown in Figure 2. The corresponding whole-body retention time-activity curves are shown in Figure 3. These data were used to estimate the activities contained in the vomita [Figure 3] which were 1297, 684, and 160 MBq, respectively, at 6.7, 11.67, and 29.67 h posttreatment and the whole-body and blood doses. The total vomited activity was 2141 MBq. The whole-body dose was estimated to be 243 mGy and the blood dose calculated using the formula by Hänscheid *et al.*^[3] and the blood volume formula by Retzlaff *et al.*^[4] was 388 mGy. The whole-body retention activity at 48 h was 234 MBq.

The patient was discharged 47 h postadministration of the RAI.

DISCUSSION

The patient was imaged 9 days posttreatment and showed [Figure 4] neck lymph node and focal pulmonary metastatic uptake as expected from the pretreatment diagnostic ¹²³I scans. The absorbed blood dose of 388 mGy and the whole-body retention activity at 48 h of 234 MBq were considerably less than the limit safe dose^[5] of 2 Gy and whole-body retention of 4400 MBq in the absence of diffuse lung metastases or 3000 MBq with the presence of metastases at 48 h. These values indicate that, if considered necessary in a repeat RAI procedure, an activity up to 40 GBq could be administered to the patient without exceeding the blood safe dose of 2 Gy and whole-body retention of 3000 MBq with the presence of metastases at 48 h.

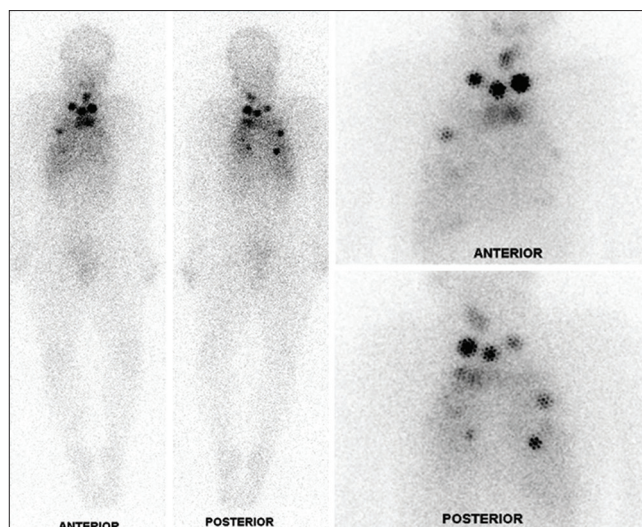


Figure 4: Posttreatment ¹³¹I imaging showing neck lymph node and focal pulmonary metastatic uptake

Declaration of patient consent

The authors certify that they have obtained all appropriate patient consent forms. In the form the patient(s) has/have given his/her/their consent for his/her/their images and other clinical information to be reported in the journal. The patients understand that their names and initials will not be published and due efforts will be made to conceal their identity, but anonymity cannot be guaranteed.

Financial support and sponsorship

Nil.

Conflicts of interest

There are no conflicts of interest.

REFERENCES

- Higuchi Y, Motoki T, Ishida H, Kanamitsu K, Washio K, Oyama T, *et al.* Sorafenib treatment for papillary thyroid carcinoma with diffuse lung metastases in a child with autism spectrum disorder: A case report. *BMC Cancer* 2017;17:775.
- Jolly Kid Z. Versatile Playpen Extension Pack. Available from: <https://www.onlinetoys.com.au/jolly-kidz-versatile-playpen-extension-pack.html>. [Last accessed on 2017 Sep 04].
- Hänscheid H, Lassmann M, Luster M, Kloos RT, Reiners C. Blood dosimetry from a single measurement of the whole body radioiodine retention in patients with differentiated thyroid carcinoma. *Endocr Relat Cancer* 2009;16:1283-9.
- Retzlaff JA, Tauxe WN, Kiely JM, Stroebel CF. Erythrocyte volume, plasma volume, and lean body mass in adult men and women. *Blood* 1969;33:649-61.
- Benua RS, Cicale NR, Sonenberg M, Rawson RW. The relation of radioiodine dosimetry to results and complications in the treatment of metastatic thyroid cancer. *Am J Roentgenol Radium Ther Nucl Med* 1962;87:171-82.