

Endoscopic Surgery for Thalamic Hemorrhage with Intraventricular Hemorrhage: Effects of Combining Evacuation of a Thalamic Hematoma to External Ventricular Drainage

Abstract

Objectives: Intraventricular hemorrhage (IVH) caused by thalamic hemorrhage leads to hydrocephalus, increased intracranial pressure, and reduced levels of consciousness. The aim of this study was to investigate the efficacy and compare the results of endoscopic surgery for the evacuation of a thalamic and intraventricular hematoma against those of external ventricular drainage (EVD) surgery. **Materials and Methods:** From January 2010 to December 2018, 68 patients with IVH caused by thalamic hemorrhage were treated in our department. Our study was approved by the Institutional Ethics Committee. The included patients were randomly divided into an EVD group and an endoscopic surgery group. The outcome was measured after 3 months using a 30-day mortality rate, pneumonia onset rate, ventriculoperitoneal (VP) shunt dependency rate, and Glasgow Outcome Scale (GOS) score. **Results:** Thirty-eight of the 68 patients were randomly assigned to the endoscopic surgery group and 30 were assigned to the EVD group. Patients treated with endoscopic surgery had significantly less drainage dependency on day 30 ($P = 0.00014 < 0.00005$) in comparison to those treated with EVD. The difference in the functional outcomes between the two groups of patients was mainly dependent on the onset of pneumonia and the consciousness level at the time of admission. The onset rate of aspiration-related pneumonia until day 30 was 11% in the endoscopic surgery group and 45% in the EVD group. The VP shunt rates were 27.8% in the endoscopic surgery group and 60% in the EVD group. The endoscopic surgery group had a significantly lower VP shunt rate compared with the EVD group. Intracerebral hemorrhage evacuation late was found to be associated with shunt-dependent rate and hospitalization. **Conclusions:** Endoscopic surgery was found to be associated with a lower GOS score and lower onset rates for shunt-dependent hydrocephalus and aspiration-related pneumonia in comparison to EVD. High evacuation rate was associated with lower shunt-dependent rate and short hospitalization.

Keywords: Endoscopic surgery, external ventricular drainage, hydrocephalus, intraventricular hemorrhage, pneumonia, thalamic hemorrhage, ventriculoperitoneal shunt

Introduction

Intraventricular hemorrhage (IVH) is a devastating neurosurgical entity commonly seen in cases involving hypertensive intracerebral hemorrhage (ICH) with extension into the ventricular system. Approximately, 10%–15% of ICH cases involve thalamic hemorrhage.^[1]

Evacuation of a thalamic hematoma via craniotomy is generally considered controversial because of the high rates of mortality and morbidity associated with this procedure. Thalamic hemorrhages are clinically significant, as they are located close to the internal capsule and ventricular system. However, with the evolution of the

neuroendoscope and hemostatic agents, the surgical evacuation deep-seated ICHs is now safer and less invasive than before.

Many studies had found that ICH volume, IVH, hydrocephalus, Glasgow Coma Scale (GCS) score, and age are the best predictors of mortality and functional outcome after thalamic ICH.^[2]

Traditional working-channel endoscopic surgery, a less invasive, alternative procedure, is relatively inefficient for evacuating a hematoma because of limited visualization of the surgical field and manipulation of surgical instruments through the working channel.^[3] IVH caused by thalamic hemorrhage is generally treated with external ventricular drainage (EVD).^[4,5]

This is an open access journal, and articles are distributed under the terms of the Creative Commons Attribution-NonCommercial-ShareAlike 4.0 License, which allows others to remix, tweak, and build upon the work non-commercially, as long as appropriate credit is given and the new creations are licensed under the identical terms.

For reprints contact: reprints@medknow.com

How to cite this article: Shimizu Y, Tsuchiya K, Fujisawa H. Endoscopic surgery for thalamic hemorrhage with intraventricular hemorrhage: Effects of combining evacuation of a thalamic hematoma to external ventricular drainage. Asian J Neurosurg 2019;14:1112-5.

Yu Shimizu,
Katsuhiro Tsuchiya,
Hironori Fujisawa

Department of Neurosurgery,
Kanazawa Medical Center,
Kanazawa, Japan

Address for correspondence:

Dr. Yu Shimizu,
Department of Neurosurgery,
Kanazawa Medical Center,
1-1 Shimoishibikimachi,
Kanazawa 920-8650, Japan.
E-mail: bleuler3a@yahoo.co.jp

Access this article online

Website: www.asianjns.org

DOI: 10.4103/ajns.AJNS_197_19

Quick Response Code:



The endoscopic approach for the evacuation of an IVH and thalamic hemorrhage led to promising results with respect to the prevention of aspiration-related pneumonia, which needs antibiotic treatment, and shunt-dependent hydrocephalus. The aim of this study was to investigate the efficacy and compare the results of endoscopic surgery for the evacuation of a thalamic and intraventricular hematoma against those of EVD surgery.

Materials and Methods

From January 2012 to December 2018, 38 patients with IVH caused by thalamic hemorrhage were treated in our department. Details regarding the study protocol, randomization, and surgical procedure were explained to close family members. Once they fully understood the study, informed consent was obtained. Our study was approved by the Institutional Ethics Committee. Randomization was accomplished using sealed envelopes containing the type of treatment. The envelopes were initially blinded to the consenting individuals and the surgeon. The selected patients were randomly divided into two groups: an EVD group and an EVD, endoscopic surgery group. Patients with thalamic hemorrhage not associated with IVH or secondary parenchymal hemorrhage were excluded. This study had a prospective and randomized design.

Operation

In the EVD and endoscopic surgery group, the procedure was performed with the patient in a supine position under general anesthesia. A 4-cm incision was made in the frontal scalp, ipsilateral to the thalamic hematoma. A burr hole (1 cm in diameter) was drilled 11 cm upward, 3 cm outside from nasion. A transcortical transventricular puncture was made with a 7-mm rigid endoscope sheath. When the ventricle was reached, the stylet was removed and a 2.7-mm, 0° endoscope (Storz) and a suction tube were inserted through this tube, permitting the simultaneous removal of intraventricular and thalamic hematomas.^[6] ARTCEREB® (Otsuka, 37°C–38°C) was used for irrigation until the intraventricular structures were fairly visible. When a bleeding vessel was encountered, the suction tube was replaced with a 3-mm unipolar suction, coagulation tube to cauterize the vessel. No intraventricular injection of an anticoagulant was administered during the procedure. Once the endoscopic procedure was completed, an external ventricular drain was placed. In the EVD group, a traditional EVD insertion was performed. An incision measuring 3 cm was made 11 cm upward, 3 cm outside from nasion, on the side with the least amount of blood in the lateral ventricle. Patients with ventricular blood received continuous drainage until there was no further reduction in cerebrospinal fluid (CSF) blood content. The EVD catheter was then sequentially weaned in daily increments of 5-cm H₂O and removed. Patients were considered for permanent

ventriculoperitoneal (VP) shunt surgery if they developed hydrocephalus. In both groups, the EVD was placed at an initial height of 12 cm from the tragus.

Clinical evaluation

The clinical evaluation data included the GCS score, age, ICH volume, and IVH severity. The ICH volume was calculated using the simplified equation $1/2A + B + C$, where A is the maximum width measured, B is the length, and C is the height.^[7] Initial IVH severity was graded according to the amount of blood in each ventricle using Graeb scores from 0 to 12, which represents the sum of the score in each ventricle, 4 is the maximum in each lateral ventricle and 2 is the maximum in the third and fourth ventricles.^[8,6] The clinical data of the patients with thalamic ICH with IVH are listed in Table 1.

Outcome analysis

Patient function was evaluated using the Glasgow Outcome Scale (GOS) score. The 30-day mortality rate, 30-day pneumonia-onset rates, and 30-day VP shunt dependency rates were also evaluated.

Statistical analysis

Data entry and analysis were done using an SPSS Statistics (Version 20.0; SPSS, IBM Corporation, Chicago, United States). For continuous variables with or without equal variances, independent *t*-tests were used to investigate differences between subsets of patients classified by categorical data. Variables with *P* < 0.05 were considered to be statistically significant.

Illustrative case

A 65-year-old male was admitted to our hospital because of left hemiparesis and disturbance of consciousness. At the time of admission, he was drowsy (GCS score 7). Computed tomography (CT) revealed a right-sided thalamic hemorrhage with a rupture into the ventricle and acute hydrocephalus [Figure 1a]. The volume of the hematoma was estimated to be 60 mL. The patient was intubated and underwent endoscopic surgery to evacuate the hematoma. Postoperative CT revealed complete removal of the thalamic hematoma [Figure 1b]. A ventricular drain was kept in lateral ventricle for 1 week after the operation. He regained consciousness 1 week later but displayed the left-sided hemiparesis. However, after 3 months, she had a GOS score of 3.

Table 1: Clinical data of patients

	EVD (n=30)	EVD + endoscopic (n=38)	P
Age	70.6	69.8	0.41
GCS	8.05	7.59	0.32
ICH volume	26.9	27.1	0.45
Graeb score	5.74	6.17	0.3

EVD – External ventricular drainage; GCS – Glasgow Coma Scale; ICH – Intracerebral hemorrhage

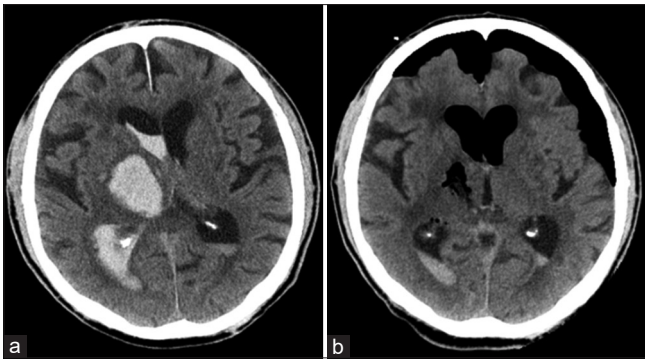


Figure 1: (a) Preoperative computed tomography reveals right thalamic hemorrhage and rupture into ventricles. (b) Postoperative computed tomography reveals complete evacuation of the thalamic hematoma

Results

All the patients in this study had hypertensive hemorrhage. These patients were randomly divided into an EVD group and an endoscopic surgery group. The clinical features of each group are shown in Table 1. Twenty patients were managed with endoscopic surgery and 18 with EVD. Their ages ranged from 49 to 88 years, with a mean age of 70.6 years. There were 14 male and 6 female patients. On admission, the patients' clinical conditions were evaluated using the GCS score. No significant differences in age were found between the two groups. There was no significant difference in ICH volume or Graeb score between the endoscopic group and the EVD group.

The mean GOS score was 3.38 in the endoscopic surgery group and 2.75 in the EVD group. Brain CT was performed pre- and postoperatively to assess the severity of the thalamic and IVH and its grading based on the Graeb scoring system. The mean length of hospitalization was 35.8 days in the endoscopic surgery group and 43.5 days in the EVD group.

The endoscopic surgery shortened administration for about 1 week. Pneumonia onset rate until 30 days after hospitalization was 11.1% in the endoscopic surgery group and 45.0% in the EVD group.

When the outcome was significantly correlated with the severity of thalamic hematoma and pneumonia onset rate, it was observed that the IVH severity did not influence the outcome. There was no significant difference in mortality rate between the endoscopic group and EVD group.

The drainage dependency 3 months postprocedurally was much lower in patients treated with endoscopic surgery. At 3 months, the drainage dependency was 27.8% in patients treated with endoscopic surgery as compared to 60.0% in patients treated with EVD [Table 2]. None of the patients who underwent endoscopic surgery experienced rebleeding events.

We classified endoscopic surgery group by ICH evacuation rate [Table 3]. Group A was 0%–80% evacuation rate and

Table 2: Result of patients after treatment

	EVD (n=30)	EVD + endoscopic (n=38)	P
30 days mortality rate (%)	15	5.6	0.31
30 days pneumonia rate (%)	45	11	0.02
GOS	2.75	3.38	0.03
Shunt dependent rate (%)	60	27.8	0.00013
Hospitalization (day)	43.5	35.8	0.011

EVD – External ventricular drainage; GOS – Glasgow Outcome Scale

Table 3: Result of each intracerebral hemorrhage evacuation rate

ICH evacuation rate	GOS (n=38)	Shunt-dependent rate (n=38)	Hospitalization (n=38)
A: 0%–80% (n=7)	3	57.1	41.3
B: 80%–100% (n=31)	3.5	19.3	33.8
P	0.12	0.04	0.026

GOS – Glasgow Outcome Scale

B was 80%–100%. Group B was lower shunt-dependent rate ($P = 0.04$) and shorter hospitalization ($P = 0.026$).

Discussion

A thalamic ICH was seen in 10%–15% of all cases of ICH,^[6] which is a severe clinical condition with an in-hospital mortality rate ranging from 12% to 37%^[9] and may even be 52% in cases involving ventricular extensive hemorrhage. Altered consciousness, IVH, hydrocephalus, ICH volume, and advanced age were independent predictors of in-hospital mortality in patients with thalamic hemorrhage.^[2] IVH has been found to be a strong predictor of in-hospital mortality in some studies,^[10] and IVH should be prioritized for treatment in cases involving thalamic hematomas with ventricular extension. The mortality rate of thalamic hemorrhage is reportedly 12% after 6 ± 6 days since stroke and 17.3% within 6 months as per Mori *et al.*'s^[11] series. In Chung *et al.*'s^[9] series, the case fatality was 37% at the time of discharge. Steinke *et al.*^[1] found that in-hospital mortality occurred in 52% of thalamic hematomas with ventricular extension and that intraventricular extension is a powerful independent predictor of mortality.

The current standard management strategy for massive thalamic IVH involves the placement of an EVD catheter. However, this procedure addresses only the sequelae of hydrocephalus and increased intracranial pressure (ICP). To address these devastating clinical sequelae caused by thalamic and IVH, various authors have studied the use of neuroendoscopic surgery.^[12] The purpose of this study was to explore a method of managing massive intraventricular and thalamic hemorrhage, which is minimally invasive and simultaneously provides maximal clinical benefit. In our study, the addition of endoscopic surgery for thalamic hemorrhage prevented pneumonia, reduced shunt

dependency, and improved the neurologic symptoms earlier than EVD only.

Blood clots within the ventricular system lead to acute obstruction of the CSF and a sudden rise in ICP. As the clot within the ventricular system undergoes lysis, the fibrin degradation products (FDPs) and bilirubin oxidation products (BOx) that are formed during the breakdown process enter and circulate in the CSF. FDPs and BOx then reach the arachnoid granulation and cause delayed communicating hydrocephalus.^[13]

This causes obstruction of normal CSF flow and acute hydrocephalus. EVD was frequently used for the relief of hydrocephalus. Hydrocephalus is associated with poor outcomes, and shunt surgery is hampered by several problems including obstruction, infection, and malfunction.^[14]

Our study showed that endoscopic surgery can decrease the incidence of shunt dependent hydrocephalus caused by thalamic hemorrhage from 60.0% to 27.8%. This may be due to the fact that endoscopic surgery can remove intraventricular and thalamic hemorrhage and also rapidly reverse ventricular dilatation and normalize ICP.

In general, as for thalamic bleeding, conservative treatment or drainage is chosen. Our study revealed that the minimally invasive endoscopic procedure for the evacuation of the thalamic hematoma helped prevent pneumonia and improved the GOS score while decreasing shunt dependency. Endoscopic surgery for thalamic bleeding with IVH has the potential to become the first-choice treatment.

Conclusions

The use of neuroendoscopy in patients with a massive IVH and thalamic hemorrhage significantly reduced drainage dependency and resulted in good clinical outcomes. This may be related to the early removal of the thalamus and intraventricular hematomas. Our study revealed a potentially better functional outcome through neuroendoscopy with considerable advantages in the hospitalization and shunt dependency.

Financial support and sponsorship

Nil.

Conflicts of interest

There are no conflicts of interest.

References

1. Steinke W, Sacco RL, Mohr JP, Foulkes MA, Tatemichi TK, Wolf PA, *et al.* Thalamic stroke. Presentation and prognosis of infarcts and hemorrhages. *Arch Neurol* 1992;49:703-10.
2. Kumral E, Kocaer T, Ertübey NO, Kumral K. Thalamic hemorrhage. A prospective study of 100 patients. *Stroke* 1995;26:964-70.
3. Auer LM, Deinsberger W, Niederkorn K, Gell G, Kleinert R, Schneider G, *et al.* Endoscopic surgery versus medical treatment for spontaneous intracerebral hematoma: A randomized study. *J Neurosurg* 1989;70:530-5.
4. Adams RE, Diringer MN. Response to external ventricular drainage in spontaneous intracerebral hemorrhage with hydrocephalus. *Neurology* 1998;50:519-23.
5. Chen CC, Lin HL, Cho DY. Endoscopic surgery for thalamic hemorrhage: A technical note. *Surg Neurol* 2007;68:438-42.
6. Chen CC, Liu CL, Tung YN, Lee HC, Chuang HC, Lin SZ, *et al.* Endoscopic surgery for intraventricular hemorrhage (IVH) caused by thalamic hemorrhage: Comparisons of endoscopic surgery and external ventricular drainage (EVD) surgery. *World Neurosurg* 2011;75:264-8.
7. Kothari RU, Brott T, Broderick JP, Barsan WG, Sauerbeck LR, Zuccarello M, *et al.* The ABCs of measuring intracerebral hemorrhage volumes. *Stroke* 1996;27:1304-5.
8. Graeb DA, Robertson WD, Lapointe JS, Nugent RA, Harrison PB. Computed tomographic diagnosis of intraventricular hemorrhage. Etiology and prognosis. *Radiology* 1982;143:91-6.
9. Chung CS, Caplan LR, Han W, Pessin MS, Lee KH, Kim JM. Thalamic haemorrhage. *Brain* 1996;119 (Pt 6):1873-86.
10. Weisberg LA. Thalamic hemorrhage: Clinical-CT correlations. *Neurology* 1986;36:1382-6.
11. Mori S, Sadoshima S, Ibayashi S, Fujishima M, Iino K. Impact of thalamic hematoma on six-month mortality and motor and cognitive functional outcome. *Stroke* 1995;26:620-6.
12. Basaldella L, Marton E, Fiorindi A, Scarpa B, Badreddine H, Longatti P. External ventricular drainage alone versus endoscopic surgery for severe intraventricular hemorrhage: A comparative retrospective analysis on outcome and shunt dependency. *Neurosurg Focus* 2012;32:E4.
13. Johnson JR, Idris Z, Abdullah JM, Alias A, Haspani MS. Prevalence of shunt dependency and clinical outcome in patients with massive intraventricular haemorrhage treated with endoscopic washout and external ventricular drainage. *Malays J Med Sci* 2017;24:40-6.
14. Diringer MN, Edwards DF, Zazulia AR. Hydrocephalus: A previously unrecognized predictor of poor outcome from supratentorial intracerebral hemorrhage. *Stroke* 1998;29:1352-7.