



Case report

Cerebrovascular accident after transurethral resection of the prostate: A rare complication

Maher Al-Hajjaj^{a,*}, Muhamad Kanjo^b, Mohammad Badr Almoshantaf^c, Sarya Swed^d, Weaam Ezzdean^e

^a Department of Urology, Aleppo University Hospital, Aleppo, Syria

^b Department of Internal Medicine, Aleppo University Hospital, Aleppo, Syria

^c Department of Neurosurgery, Ibn Al-Nafees Hospital, Damascus, Syria

^d Faculty of Human Medicine, Aleppo University, Aleppo, Syria

^e Department of Urology, Ibn Al-Nafees Hospital, Damascus, Syria

ARTICLE INFO

Keywords:

Benign prostatic hyperplasia
Cerebrovascular accident
Transurethral resection of prostate

ABSTRACT

Introduction: Benign prostatic hyperplasia is considered a worldwide disease among males in middle age. Transurethral resection of the prostate (TURP) is a wide used intervention for this condition. A few reports mentioned cerebrovascular accidents after TURP.

Presentation of case: A 65-year-old male presented with recurrent urinary retention in the past two years. Clinical examination showed a full urinary bladder with abdominal discomfort. Abdominal ultrasound revealed an enlarged prostate (90 ml) with approximately 500 ml of urine. After that, we performed transurethral resection of the prostate (TURP). The surgery was uneventful. After three days of discharge, he presented with a loss of vision in the left eye and left lower limb pain. Computed tomography of the brain showed right occipital lobe infarction. Ultrasound of the left lower limb revealed deep venous thrombosis. Echocardiography showed a patent foramen ovale. As a result, he had deep venous thrombosis with patent foramen ovale that led to infarction. We started with anticoagulants for two weeks. Later, he reclaimed his vision completely.

Clinical discussion: Cerebral vascular accidents are a rare complication of transurethral resection of the prostate. Early recognition and diagnosis of this condition will lead to good results. Searching for cardiac anomalies is the first step to reaching the diagnosis.

Conclusion: Urologists should suspect cardiac anomalies in patients who underwent TURP surgery and develop cerebrovascular accidents. Collaboration with other specialties is considered basic to help with this complication.

1. Introduction

Benign prostatic hyperplasia (BPH) is a disease with a large prevalence in both middle-aged and elderly men [1]. Of all men older than 40 years, more than half will have BPH, about a third of these will have lower urinary tract syndrome. Some will develop bladder outlet obstruction causing the urine to be retained in the bladder [2]. Symptoms of BPH usually involve reduced urinary stream, terminal dribble, incomplete bladder emptying, increased frequency in urination, bladder pain, and urination burning. BPH also increased the incidence of hospital admissions due to the need for catheterism [3]. To diagnose BPH, initially, history taking, urinalysis, and digital rectal examination are endorsed. Other assessments are highly recommended like: flow and

voiding charts, international prostate symptoms score, prostate and bladder ultrasound, biopsy, transrectal ultrasonography, and many more. Once the diagnosis is confirmed, treatment is decided depending on severity, quality of life, and patient choice [4].

Management of BPH can vary. Patients with mild symptoms can be counseled about a combination of lifestyle modification and watchful waiting. Medical treatment, involving Alpha-blockers and 5-alpha reductase inhibitors, is a clinically effective option for more bothersome symptoms. Surgery is the best long-term method but has the greatest number of complications [5]. The most famous surgical procedure nowadays is transurethral resection of the prostate (TURP). TURP procedure's possible complications are TURP syndrome, clot retention, urinary tract infection, urethral strictures, bladder neck

* Corresponding author.

E-mail address: alhajjaj963@gmail.com (M. Al-Hajjaj).

<https://doi.org/10.1016/j.ijscr.2022.106948>

Received 31 January 2022; Received in revised form 10 March 2022; Accepted 13 March 2022

Available online 16 March 2022

2210-2612/© 2022 The Authors. Published by Elsevier Ltd on behalf of IJS Publishing Group Ltd. This is an open access article under the CC BY-NC-ND license (<http://creativecommons.org/licenses/by-nc-nd/4.0/>).

contractures, and retrograde ejaculation [6,7].

Cerebrovascular accident (CVA) is hardly being mentioned in the literature as a possible complication after TURP. We present an unusual case of BPH which involves CVA complicating TURP.

This case report has been reported in line with the SCARE Criteria.

2. Case presentation

We report a case of 65 years old male who was transferred from an outpatient clinic to our hospital. At the presentation, his main complaint was acute urinary retention. He has a history of frequent urinary retention that only settled with catheterization in emergency settings. He is also 1 pack/day for 30 years smoker. There was no history of cancer or other conditions except for moderate hypertension treated with amlodipine. On examination, as expected, the bladder was full and easily palpated. Thus, cautious catheterization was performed and followed by extraction of 600 ml of urine.

General blood tests like CBC, creatinine, and Urea were within normal limits. No inflammatory markers were elevated. Abdomen and pelvis ultrasound showed normal kidneys appearance and marked hypertrophy of prostate (90 ml) as he was previously diagnosed with BPH. As a result, and due to the repeated admissions, we decided to put the patient on the scheduled list for TURP operation.

On operation day, the procedure went smoothly, taking no more than 60 min. No complications were noted during the procedure and the patient was left catheterized. So, he was discharged on a one-week follow-up appointment to remove the catheter.

After 3 days, he came with almost complete blindness in his left eye. In addition, he was suffering from right calf pain, and on examination; the calf was swollen and tender to touch. We immediately suspected DVT and ordered an urgent Doppler ultrasound. Doppler ultrasound confirmed the presence of DVT.

Computed Tomography (CT) showed in Fig. 1 right posterior

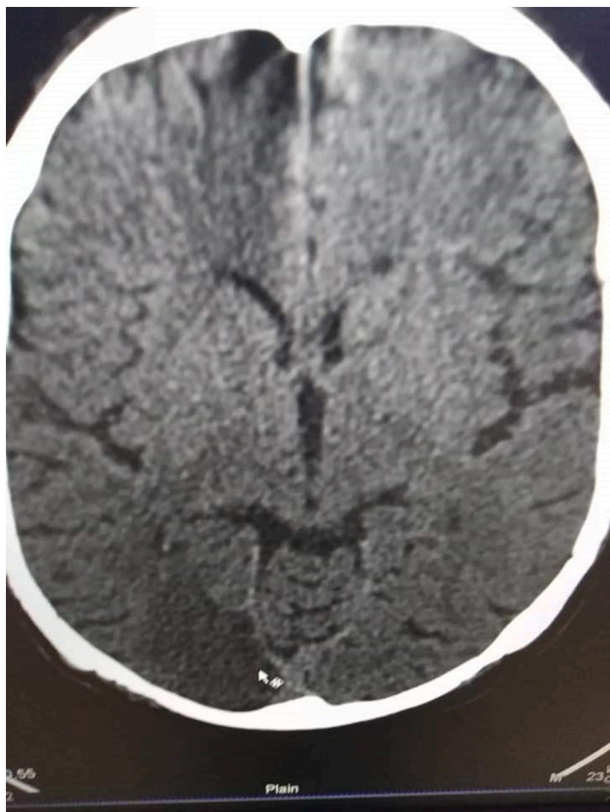


Fig. 1. Computed Tomography of the brain shows right occipital lobe infarction.

cerebral lobe infarction and he was prescribed anticoagulants (IV heparin) as a result. Moreover, a Doppler echocardiogram was ordered and discovered a patent fossa oval which can link the symptoms of both DVT and CVA. During anticoagulants therapies, no signs of cutaneous, mucosal, or renal bleeding were noted. Blood tests including complete blood count (CBC), creatinine, urea, and prothrombin time were all normal. Chest X-ray was also normal.

Finally, after 3 days of treatment, he regained full eyesight and experienced relief of calf pain. He was advised to make an appointment in the cardio surgery outpatient clinic to follow his heart abnormality. He was discharged home with complete medical fitness.

3. Discussion

Deep vein thrombosis is considered one of the most common complications of surgery. In contrast, paradoxical embolism is one rare finding to consider after surgery, which could happen due to patent foramen ovale (PFO), which is a hole between the right and left atrium that closes after birth. PFO is a flap like valve between the two atria. Patent foramen ovale allows venous thrombosis to pass through to cause an arterial embolism in terminal branches [9].

Moreover, right posterior cerebral lobe infarction is a very rare complication of urological surgeries [9]. Although, most cases of the patent foramen ovale remain asymptomatic, it might cause a paradoxical thrombosis by allowing the venous thrombosis to pass through from the venous system to the systemic circulation, whereas in about 40–50% of cases with paradoxical emboli a patent foramen ovale is diagnosed [10]. Deep venous thrombosis usually form in the lower extremity veins, or rarely in pelvic venous system as a result of surgery, trauma, bone fracture, prolonged immobilizations, cancer, pregnancy, oral contraceptives, or varicose veins [13]. And when transferred through patent foramen ovale or any right to left communications entering the systemic circulation as paradoxical emboli can cause stroke or peripheral emboli [11]. In the medical literature there are few cases that reported cerebral vascular accident after transurethral resection of the prostate. According to Sepideh Emami et al. [9], A 71-year-old has undergone a transurethral prostate resection due to benign prostatic hyperplasia which presented with severe urinary retention and hydronephrosis, although the patient has been discharged from the hospital without any complications, the patient has complained a left lower limb pain and edema along with reduced vision in both eyes one week after the surgery. The diagnosis of deep venous thrombosis (DVT) of the left lower extremity was confirmed with colored Doppler ultrasonography and they also confirmed the diagnosis of bilateral occipital ischemia by computed tomography of the brain. They have also suspected patent foramen ovale as a cause of paradoxical embolism which was later confirmed by echocardiography as it was missed during the patient's preoperative preparations.

More importantly, TURP is associated with a hypercoagulable prothrombotic state as aspirin withdrawal preoperatively increases the risk of deep venous thrombosis and embolisms, and prophylaxis with low-dose heparin should be considered to prevent venous thrombosis, according to Bell CR et al. [12]. Bell CR et al. have described four cases of pulmonary embolism after TURP as two of them were fatal in those patients.

Based on the previous, deep venous thrombosis must be considered as serious complication in patients who undergo TURP procedures and who have predispose factors for DVT, as it could lead to serious complication such as cerebral vascular accident which was described in this case, in which the patient experienced right occipital lobe infarction.

4. Conclusion

Cerebral vascular accidents are rare complications of TURP, but must be considered as a result of deep venous thrombosis along with patient

foramen ovale which should be excluded in case of any sign of systemic thrombosis in the presences of deep venous thrombosis.

Provenance and peer review

Not commissioned, externally peer reviewed.

Funding

This research did not receive any specific grant from funding agencies in the public, commercial, or not-for-profit sectors.

Ethical approval

No ethical approval was sought for this case report.

Consent

Written informed consent was obtained from the patient for publication of this case report and accompanying images. A copy of the written consent is available for review by the Editor-in-Chief of this journal on request.

Author contribution

Maher Al-Hajjaj: contributed in study concept and design, data collection, and writing the paper.

Muhamad Kanjo: contributed in data interpretation and writing the paper.

Mohammad Badr Almoshantaf, Sarya Swed, and Weaam Ezzdean: Helped in writing and reviewing the manuscript.

Registration of research studies

Not applicable.

Guarantor

Dr. Maher Al-Hajjaj.

Declaration of competing interest

The authors declare having no conflicts of interest for this article.

References

- [1] C. Persu, D. Georgescu, I. Arabagiu, V. Cauni, C. Moldoveanu, P. Geavlete, TURP for BPH. How large is too large? *J. Med. Life* 3 (4) (2010) 376. /pmc/articles/PMC3019067/.
- [2] C.G. Roehrborn, Male lower urinary tract symptoms (LUTS) and benign prostatic hyperplasia (BPH), *Med. Clin. N. Am.* 95 (1) (2011) 87–100, <https://doi.org/10.1016/J.MCNA.2010.08.013>.
- [3] A. Bertaccini, F. Vassallo, F. Martino, L. Luzzi, S.R. Rossetti, F. di Silverio, L. Comunale, Symptoms, bothersomeness and quality of life in patients with LUTS suggestive of BPH, *Eur. Urol.* 40 (Suppl. 1) (2001) 13–18, <https://doi.org/10.1159/000049872>.
- [4] J.J.M.C.H. de La Rosette, G. Alivizatos, S. Madersbacher, M. Perachino, D. Thomas, F. Desgrandchamps, M. de Wildt, EAU guidelines on benign prostatic hyperplasia (BPH), *Eur. Urol.* 40 (3) (2001) 256–263, <https://doi.org/10.1159/000049784>.
- [5] J.C. Nickel, C.E. Méndez-Probst, T.F. Whelan, R.F. Paterson, H. Razvi, 2010 update: guidelines for the management of benign prostatic hyperplasia, *Can. Urol. Assoc. J.* 4 (5) (2010) 310, <https://doi.org/10.5489/CUAJ.10124>.
- [6] J. Rassweiler, D. Teber, R. Kuntz, R. Hofmann, Complications of transurethral resection of the prostate (TURP)—incidence, management, and prevention, *Eur. Urol.* 50 (5) (2006) 969–980, <https://doi.org/10.1016/J.EURURO.2005.12.042>.
- [7] Transurethral Resection of the Prostate (TURP) Syndrome: A R... : *Anesth. Analg.* (n.d.). Retrieved January 22, 2022, from https://journals.lww.com/anesthesia-analgesia/Fulltext/1997/02000/Transurethral_Resection_of_the_Prostate_TURP_.37.aspx.
- [9] Sepideh Emami, Fatima Alfaham, Behnam Shakiba, Mehran Moghimiyan, Zahra Mirzaasgari, Loss of vision after transurethral resection of prostate: a case report, *Urol. Case Rep.* 38 (2021), 101739, <https://doi.org/10.1016/j.eucr.2021.101739>. ISSN 2214-4420.
- [10] S. Homma, S.R. Messé, T. Rundek, Y.P. Sun, J. Franke, K. Davidson, H. Sievert, R. L. Sacco, M.R. Di Tullio, Patent foramen ovale, *Nat. Rev. Dis. Primers* 21 (2) (2016 Jan) 15086, <https://doi.org/10.1038/nrdp.2015.86>.
- [11] C. Otto, Cardiac masses and potential cardiac source of embolus, in: *Clinical Echocardiography*, 5th ed., Elsevier Saunders, Philadelphia, PA, 2013, pp. 395–417, <https://doi.org/10.1177/8756479318816983>. /pmc/articles/PMC3019067/.
- [12] C.R. Bell, P.J. Murdock, K.J. Pasi, R.J. Morgan, Thrombotic risk factors associated with transurethral prostatectomy, *BJU Int.* 83 (9) (1999 Jun) 984–989, <https://doi.org/10.1046/j.1464-410x.1999.00075.x>. PMID: 10368240.
- [13] P.C. Malone, P.S. Agutter, The aetiology of deep venous thrombosis, *QJM* 99 (9) (September 2006) 581–593, <https://doi.org/10.1093/qjmed/hcl070>.