




Contents lists available at ScienceDirect

Acta Orthopaedica et Traumatologica Turcica

journal homepage: <https://www.elsevier.com/locate/aott>

Comparison of intramedullary nailing and minimal invasive plate osteosynthesis in the treatment of simple intra-articular fractures of the distal tibia (AO-OTA type 43 C1-C2)



Ozan Beytemür^{a,*}, Alican Barış^b, Cem Albay^a, Serdar Yüksel^a, Sever Çağlar^a, Ender Alagöz^a

^a Bağcılar Training and Research Hospital, Department of Orthopedics and Traumatology, İstanbul, Turkey

^b İstanbul Training and Research Hospital, Department of Orthopedics and Traumatology, İstanbul, Turkey

ARTICLE INFO

Article history:

Received 10 April 2016

Received in revised form

29 May 2016

Accepted 11 July 2016

Available online 5 November 2016

Keywords:

Distal tibial fractures

Intra-articular fractures

Intramedullary nailing

Minimally invasive plate osteosynthesis

Minimally invasive surgery

ABSTRACT

Objective: The aim of this study was to compare midterm functional and radiographic results of minimal invasive plate osteosynthesis (MIPO) with intramedullary nailing (IMN) of simple intra-articular distal tibial fractures (AO-OTA type 43 C1-C2).

Methods: Seventy-three simple intra-articular distal tibial fracture patients were evaluated retrospectively. All were treated between 2009 and 2014. The average age of the patients was 40.3 years. Thirty-seven patients were treated with IMN and 36 patients were treated with MIPO. Fibular plate osteosynthesis was applied in 5 cases (13.5%) in the IMN group and in 23 patients (63.9%) in the MIPO group.

Results: Functional results and complications of IMN and MIPO methods were assessed in 73 patients. The average union time was 16.4 ± 2.7 weeks in the IMN group and 15.2 ± 1.8 weeks in the MIPO group ($p = 0.079$). The average Olerud-Molander Ankle Score was 87.8 ± 8.1 in the IMN group and 81.5 ± 11.8 in the MIPO group ($p = 0.013$). Four patients in the IMN group experienced valgus malunion, while it was not observed in any patients in the MIPO group ($p = 0.042$). Recurvatum malunion was detected in 10 patients in the MIPO group and not seen in the IMN group ($p = 0.001$). Ankle dorsiflexion angle was $25.8 \pm 4.5^\circ$ in the IMN group and $33.3 \pm 8.9^\circ$ in the MIPO group ($p = 0.000$).

Conclusion: Simple intra-articular distal tibial fractures are successfully treated with IMN and MIPO. Prevalence of valgus malunion was higher in the IMN group and recurvatum was more prevalent in the MIPO group. MIPO is the first preference according to the literature; however, successful results have been obtained with IMN in this fracture pattern.

Level of Evidence: Level III, Therapeutic Study.

© 2016 Turkish Association of Orthopaedics and Traumatology. Publishing services by Elsevier B.V. This is an open access article under the CC BY-NC-ND license (<http://creativecommons.org/licenses/by-nc-nd/4.0/>).

Introduction

Treatment options for distal tibial fractures remain quite controversial.^{1–10} Intramedullary nailing, osteosynthesis with plates, and external fixation methods are used. Each method has its own advantages and disadvantages.

When distal tibial fractures extend to the joint line, the situation is further complicated. Currently, the most commonly used method is minimally invasive plate osteosynthesis (MIPO).³ External fixators and intramedullary nails are less preferred in practice.^{1–4} MIPO is the most often recommended technique, but studies about intramedullary nailing (IMN) are available for simple intra-articular distal tibial fractures that extend to the joint line.^{1,3,11,12}

There are many studies comparing IMN and MIPO for extra-articular distal tibial fractures in the literature.^{4–6,10,13,14} However, to our knowledge, so far there is no study comparing IMN with MIPO for AO-OTA type 43 C1-C2 simple intra-articular distal tibial fractures.

* Corresponding author. Fax: +90 212 440 40 00.

E-mail addresses: beytemur@yahoo.com (O. Beytemür), dralicanbaris@gmail.com (A. Barış), cemalbay@hotmail.com (C. Albay), serdar84yuksele@gmail.com (S. Yüksel), severcaglar@gmail.com (S. Çağlar), enderalagoz@yahoo.com (E. Alagöz).

Peer review under responsibility of Turkish Association of Orthopaedics and Traumatology.

The aim of this retrospective study was to compare midterm functional and radiographic results of MIPO with intramedullary nailing of simple intra-articular distal tibial fractures (AO-OTA type 43 C1–C2). Our hypothesis was that IMN application is as successful and perhaps more successful than MIPO for simple intra-articular distal tibial fractures. IMN application is not a contraindication for simple intra-articular extension.

Patients and methods

This study was approved by the local ethical committee of our institution (2015/422). All tibial fractures were operated on in our hospital between January 2009 and June 2014. Fractures were determined to be AO-OTA type 43C-1 and C-2.

Thirty-seven patients treated with IMN and 36 patients treated with MIPO with at least 1 year of follow-up were included in the study. Extension to the ankle joint was evaluated with computed tomography. Early irrigation and debridement, antibiotherapy, and skeletal traction were applied for open fracture patients. After observing that wound was clean and uncomplicated, permanent surgery was performed. The choice of treatment type was based on surgeon's preference and experience.

Group IMN

Ankle joints were evaluated in supine position. Ankle mortise was evaluated in the presence of fibula fractures with mortise view under fluoroscopy. Unstable fibula fractures, major displaced fractures or syndesmosis injuries were fixed with fibular plates. Temporary percutaneous K-wires or screws were then applied to distal tibia above the ankle joint line under fluoroscopy. If IMN screws were sufficient to fix intra-articular fragment, only temporary K-wire application was made. Otherwise, intra-articular fracture was fixed with proper percutaneous screws before IMN. Afterward, all patients were treated with tibial IMN (Trigen Meta-nail™; Smith & Nephew, Inc., Memphis, TN, USA) through medial parapatellar approach at 90 degrees of knee flexion.

Group MIPO

Ankle joints were evaluated in supine position. Ankle mortise was evaluated in the presence of fibula fractures with mortise view under fluoroscopy. Unstable fibula fractures, major displaced fractures or syndesmosis injuries were fixed with fibular plates. Temporary percutaneous K-wires or screws were applied to distal tibia above the ankle joint line under fluoroscopy. If plate screws were sufficient to fix the intra-articular fragment, only temporary K-wire application was made. Otherwise, intra-articular fracture was fixed with proper percutaneous screws before MIPO. Medial longitudinal incision was made at the level of the medial malleolus, and 3.5 mm LCP® medial distal tibial plate (DePuy Synthes, Warsaw, IN, USA) was inserted using minimally invasive technique. After reduction was achieved with traction and indirect fracture reduction, proximal screws and distal screws were secured to the plate with percutaneous stab incisions.

Weight-bearing was not permitted in either group for 6–8 weeks postoperatively. Partial weight-bearing was then permitted. At least 3 bridging cortex calluses on biplanar radiographs and absence of clinical pain with full load-bearing was considered full union.² Full load was allowed once radiological union was achieved (Figs. 1 and 2). Biplanar ankle radiographs and biplanar tibia radiographs were taken during follow-up of patients. All patients were assessed 2–4 weeks before union and 6 months after union was achieved.

Patient age, gender, side, fracture type (AO-OTA classification),¹⁵ open fracture classification, mechanism of injury, presence of polytrauma, smoking habit, diabetes, fibular fracture, fibular fixation, and number of non-implanted screws were recorded and evaluated for both groups. In the postoperative assessment, average follow-up period, mean time to union, union status, infection status, and malunion were assessed.

To determine malunion, distal tibial varus-valgus and procurvatum-recurvatum deformities were evaluated radiologically. Rotational deformity was assessed clinically. Comparison was made with the other limb and deformity was determined based on tibial tubercle, tibial crest, and ankle midpoint.

Clinically and radiologically, anything above 5 degrees of deformity in any plane was considered malunion. The number of screws removed from implant was reviewed. Clinical assessment of patients was conducted using the Olerud-Molander Ankle Score (OMAS)¹⁶ and by measuring ankle joint range of motion with goniometer.

Statistical analysis

SPSS software (version 22.0; SPSS Inc., Chicago, IL, USA) was used for statistical analysis. Average, standard deviation, median minimum, median maximum, frequency, and ratio values were used for data descriptive statistics. Distribution of variables was analyzed using the Kolmogorov–Smirnov test. For quantitative data analysis, Mann–Whitney U test, a Kruskal–Wallis test, and an independent sample t-test were conducted, and chi-square test was used for qualitative data analysis. Fischer's exact test was performed when chi-square test conditions were insufficient. Spearman correlation analysis was conducted. P value of <0.05 was considered statistically significant.

Results

Seventy-three patients were divided into 2 groups. Group IMN had 37 patients and group MIPO had 36 patients. Mean age was 40.3 years (range: 18–82 years). Fifty-two of the patients (71.2%) were male and 21 of the patients (28.8%) were female. There were 27 patients (36.9%) with right side fracture and 46 patients (63.1%) with left side fracture; 39 were AO-OTA 43 C1 and 34 were AO-OTA 43 C2. The mechanism of injury was a fall for 52 patients (71.2%), attack in 1 case (1.4%), traffic accident for 17 patients (23.3%), and sports injury for 3 patients (4.1%). A total of 29 patients (21.9%) were polytraumatic.

Open fracture was present in 14 patients; 8 patients (11%) had Gustilo Anderson type I, and 6 patients (8.2%) had Gustilo Anderson type II open fracture. Fibula fracture was present in 64 patients (87.6%). Fibula fractures were resolved with fibular plates in 28 patients (38.4%): 5 patients in the IMN group and 23 patients in the MIPO group. Non-implant screws were used in 29 patients in the IMN group and in 13 patients in the MIPO group. Nine patients were diabetic (12.3%), and 26 patients (35.6%) were smokers. The characteristics of the patients in each group are provided in detail in Table 1.

Mean follow-up time was 29.4 months (range: 13–50 months). The average union time was 16.4 ± 2.7 weeks in the IMN group and 15.2 ± 1.8 weeks in the MIPO group. There was no statistically significant difference between the 2 groups ($p = 0.079$). Union was achieved in all patients in the IMN group; nonunion was encountered in 1 patient in the MIPO group (Table 2).

The average OMAS was 87.2 ± 8.1 in the IMN group and 81.5 ± 11.8 in the MIPO group. There was a significant statistical difference between the 2 groups ($p = 0.013$). Ankle dorsiflexion angle was $25.8 \pm 4.5^\circ$ in the IMN group and $33.3 \pm 8.9^\circ$ in the MIPO

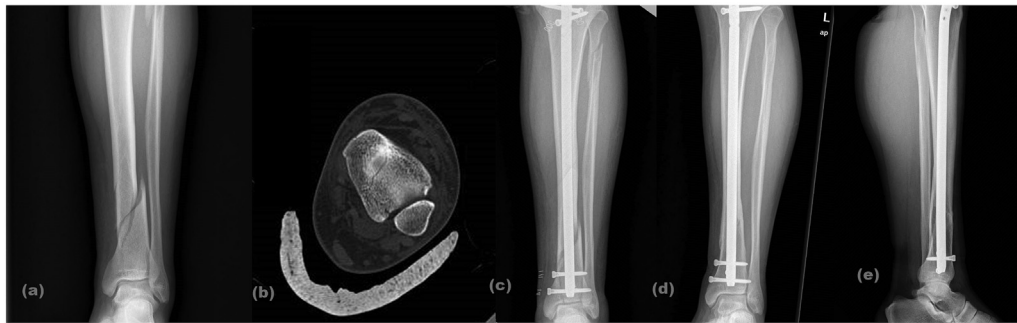

Fig. 1. A 30-year-old male AO-OTA 43 C1 (a) preoperative X-ray, (b) preoperative computed tomography, (c) early postoperative X-ray, (d, e) postoperative X-ray at 19th month.

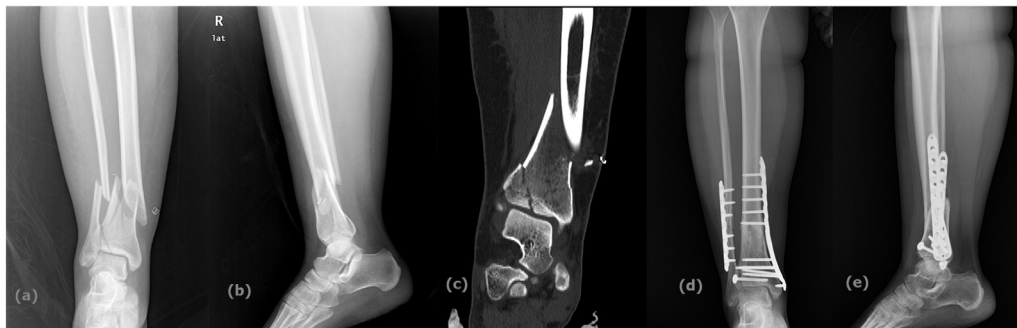

Fig. 2. A 40-year-old female AO-OTA 43 C2 (a) preoperative X-ray, (b) preoperative computed tomography, (c) early postoperative X-ray, (d, e) postoperative X-ray at 28th month.

Table 1
Characteristics of patients.

		Grup IMN		Grup MIPO	
		Average \pm s.d.		Average \pm s.d.	
Age		39,6	\pm 16,5	41,6	\pm 14,5
Sex	Female	10	27,0%	11	30,6%
	Male	27	73,0%	25	69,4%
Side	Right	12	32,4%	15	41,7%
	Left	25	67,6%	21	58,3%
Fracture type (AO/OTA classification)	C1	21	56,8%	18	50,0%
	C2	16	43,2%	18	50,0%
Open fracture type (Gustilo Anderson classification)	0	25	67,6%	34	94,4%
	I	6	16,2%	2	5,6%
	II	6	16,2%	0	0,0%
Trauma mechanism	Beaten	0	0,0%	1	2,8%
	Falling	23	62,2%	29	80,6%
	Sport injury	2	5,4%	1	2,8%
	Traffic accident	12	32,4%	5	13,9%
Polytrauma	No	32	86,5%	25	69,4%
	Yes	5	13,5%	11	30,6%
Smoking	No	29	78,4%	18	50,0%
	Yes	8	21,6%	18	50,0%
Diabete history	No	35	94,6%	29	80,6%
	Yes	2	5,4%	7	19,4%
Fibula fracture	No	2	5,4%	7	19,4%
	Yes	35	94,6%	29	80,6%
Fibula fixation	No	32	86,5%	13	36,1%
	Yes	5	13,5%	23	63,9%
External screw		1,1	\pm 0,7	0,7	\pm 1,0

group. Ankle dorsiflexion was significantly higher in the MIPO group ($p = 0.000$). Ankle plantar flexion was $39.3 \pm 5.8^\circ$ in the IMN group and $37.6 \pm 6.9^\circ$ in the MIPO group. There was no statistically significant difference between the 2 groups ($p = 0.205$) (Table 2).

In terms of complications, nonunion was seen in 1 patient in the MIPO group. In addition, superficial infection was observed in 3

patients (8.1%) in the IMN group and in 7 patients (19.4%) in the MIPO group ($p = 0.159$). Deep infection was not observed in the IMN group, but was seen in 1 patient (2.8%) in the MIPO group ($p = 0.493$). Anterior knee pain was observed in 8 patients (21.6%) in the IMN group (Table 3).

Varus malunion was observed in 1 patient (2.7%) in the IMN group but was not observed in the MIPO group ($p = 0.321$). Valgus malunion was observed in 4 patients (10.8%) in the IMN group but was not seen in any patients in the MIPO group ($p = 0.042$). Of those, valgus malunion was determined in 1 patient in fibula-fixed IMN group ($n = 5$) and in 3 patients in fibula-fixed MIPO group ($n = 32$; $p = 0.531$).

Recurvatum malunion was not observed in the IMN group, while it was observed in 10 patients (27.8%) in the MIPO group ($p = 0.001$). Procurvatum malunion was not observed in any patients in the IMN group, but it was observed in 1 patient (2.8%) in the MIPO group ($p = 0.493$). Rotation was observed in 2 patients (5.4%) in the IMN group, but was not found in any patients in the MIPO group ($p = 0.493$) (Table 3).

Average varus, procurvatum, and rotation angle showed no significant statistical differences. Average valgus angle in the IMN group was $2.1 \pm 1.8^\circ$, while it was $0.0 \pm 0.2^\circ$ in the MIPO group ($p = 0.000$). Average valgus angle of fibula-fixed IMN group ($n = 5$) was $2.60 \pm 2.41^\circ$, and average valgus angle of fibula non-fixed IMN group ($n = 32$) was $1.97 \pm 1.67^\circ$ ($p = 0.456$).

Average recurvatum angle in the IMN group was $0.3 \pm 0.8^\circ$, while it was $3.1 \pm 2.3^\circ$ in the MIPO group ($p = 0.000$) (Table 2). Malunion created no functional complaints; therefore, no intervention was applied.

Discussion

There is still no clear consensus on treatment of intra-articular distal tibial fractures.^{1–3} IMN, plate osteosynthesis, and external

Table 2
Results.

	Group IMN		Group MIPO		P		
	Average ± s.d	Med (Min–Max)	Average ± s.d	Med (Min–Max)			
Fallow up (months)	32,1 ± 9,6	33,0	13,0–50,0	26,6 ± 7,8	28,5	13,0–38,0	<i>0,011</i>
Union time (weeks)	16,4 ± 2,7	16,0	12,0–24,0	15,2 ± 1,8	15,0	12,0–20,0	0,079
Union	No	0	0,0%	1	2,8%		0,493
	Yes	37	100,0%	35	97,2%		
Olerud-molander score	87,8 ± 8,1	85,0	70,0–100,0	81,5 ± 11,8	80,0	60,0–100,0	<i>0,013</i>
Varus malalignment (degrees)	0,7 ± 1,4	0,0	0,0–6,0	0,2 ± 0,6	0,0	0,0–2,0	0,133
Valgus malalignment (degrees)	2,1 ± 1,8	2,0	0,0–6,0	0,0 ± 0,2	0,0	0,0–1,0	<i>0,000</i>
Recurvatum malalignment (degrees)	0,3 ± 0,8	0,0	0,0–3,0	3,1 ± 2,3	4,0	0,0–7,0	<i>0,000</i>
Procurvatum malalignment (degrees)	0,2 ± 0,7	0,0	0,0–3,0	0,4 ± 1,2	0,0	0,0–5,0	0,879
Rotasyon malalignment (degrees)	0,4 ± 1,2	0,0	0,0–5,0	0,2 ± 0,7	0,0	0,0–3,0	0,754
Ankle dorsi flexion (degrees)	25,8 ± 4,5	25,0	15,0–30,0	33,3 ± 8,9	35,0	15,0–45,0	<i>0,000</i>
Ankle plantar flexion (degrees)	39,3 ± 5,8	40,0	25,0–45,0	37,6 ± 6,9	40,0	20,0–50,0	0,205

The italics represents in the table for which p value is <0,05.

Table 3
Complications.

	Group IMN	Group MIPO	P
Varus malunion	1 2,7%	0 0,0%	0,321
Valgus malunion	4 10,8%	0 0,0%	<i>0,042</i>
Recurvatum malunion	0 0,0%	10 27,8%	<i>0,001</i>
Procurvatum malunion	0 0,0%	1 2,8%	0,493
Rotation malunion	2 5,4%	0 0,0%	0,493
Superficial infection	No 34 91,9%	29 80,6%	0,159
	Yes 3 8,1%	7 19,4%	
Deep infection	No 37 100,0%	35 97,2%	0,493
	Yes 0 0,0%	1 2,8%	
Knee pain	No 29 78,4%	36 100,0%	<i>0,003</i>
	Yes 8 21,6%	0 0,0%	

The italics represents in the table for which p value is <0,05.

fixators are the most recommended treatment methods, but plate osteosynthesis and IMN are currently more often preferred.

MIPO is the most preferred method for AO-OTA type 43 C1-C2 intra-articular distal tibial fractures, but there are quite a few studies on the use of IMN.^{1,3,11,12} Even though there are many studies comparing IMN and minimally invasive plates in the treatment of extra-articular distal tibial fractures in the literature,^{4–6,8,10} to our knowledge, there is no clinical study comparing intramedullary nail and MIPO in the treatment of simple intra-articular AO-OTA type 43 C1-C2 fractures.

Ristinemi et al compared external fixation and IMN for intra-articular distal tibial fractures and found no significant difference in union time or functional outcome, but encountered higher second attempt and union delay complications in the external fixation group.² We more often prefer external fixation for open fractures and comminuted displaced intra-articular fractures.

Even though soft tissue problems are more often detected in plate osteosynthesis applications, with the development of more minimally invasive plate methods, this complication rate has fallen to very low levels.^{10,17} Still, high implant irritation rates have been reported in several studies of MIPO.^{7,18} In recent years, similar low rates of infection have been reported in the literature with the development of minimally invasive systems.¹⁰ In the present study, superficial infection was detected in 7 patients (19.4%) in the MIPO group and 3 patients in the IMN group (8.1%). We observed 1 deep infection in the MIPO group (2.8%) and no such cases in the IMN group (p = 0.493).

In the literature, similar success has been reported in functional assessment comparison of MIPO and IMN.^{8,10,13,14} Present study had high OMAS scores in both 2 groups (Group IMN: 87.8; Group MIPO: 81.5), but it was statistically significantly higher in IMN group. We believe that result is due to less implant irritation with IMN, as it requires less soft tissue dissection and is less invasive

procedure than MIPO. We determined that angle of dorsiflexion was significantly higher in MIPO group (p = 0.000). Although ankle dorsiflexion is a very important parameter for functional outcome, it is included in OMAS, and therefore we believe OMAS is more important in this comparison of techniques.

Anterior knee pain is a common complication after IMN treatment; frequency rate of 10%–70% has been reported in the literature.¹⁹ The etiology is still unclear. Anterior knee pain was observed in 8 patients (21.6%) who were treated with IMN in present study. The authors think that this is due to medial parapatellar approach. In the MIPO group, this complication did not occur because the surgical procedure does not interfere with the knee.

Generally, more alignment and mechanical instability problems are seen in IMN application.^{4–6} New generation intramedullary nail types increased biomechanical strength by allowing more distal screws. In most meta-analysis studies that compare intramedullary nailing and plate osteosynthesis, malunion is much more often seen in the IMN group.⁶ It is believed that because most plate osteosynthesis is achieved using open reduction internal fixation (ORIF) method, fewer instances of malunion occur.¹⁰ Recent studies have reported similar malunion rate for IMN and MIPO methods, which both use indirect reduction techniques, in contrast to ORIF.¹⁰

Kuhn et al compared IMN and MIPO biomechanically in simple intra-articular fractures in an experimental study. They found IMN to be significantly more durable with regard to axial loadings, while no significant difference was found with respect to torsional loading.⁹

Plane of malunion was not stated clearly in the studies. Present study provides important information in terms of which malunion types to examine in further detail. We found more valgus malunion in the IMN group and more recurvatum in the MIPO group. All IMN applications were done with 90-degree knee flexion. We think that sagittal plane deformities are lessened with the effect of gravity in IMN application. Rate of coronal plane malunion (especially valgus) in IMN application was thought to occur for 2 reasons. The first has to do with reduction problems due to not being at the center of the ankle joint in the coronal plane. The second reason is different fibula fracture fixation rates: 13% in IMN Group (5 patients) and 63.9% (23 patients) in MIPO Group. Therefore, more valgus deformity in the IMN group can be explained by fewer patients with fibular fixation. No statistically significant difference in malunion was found between fibula-fixed and non-fixed IMN groups, which is thought to be because of the small number of cases. Egol et al found that 4% of patients had malunion in a fibular fixation group and 13% in a non-fibular fixation group in their study on the effect of fibular fixation on malunion.²⁰

Less occurrence of valgus deformity in the MIPO group also occurred for 2 reasons. The anatomical shape of plates reduces

coronal plane deformity, and as previously mentioned, fibula fracture fixation rate was higher in the MIPO group (63.9%). We believe that fibular fixation will reduce valgus rates in IMN practice. However, some studies have also reported that fibula fracture fixation increases surgical complication rates. Vallier et al found nonunion rates were significantly higher when fibular fracture was fixed. The same study reported that the most common malunion was valgus malunion and that fibular fixation did not decrease malunion.¹⁴

We found that sagittal plane deformities, especially recurvatum, were significantly higher in the MIPO group. MIPO application is made in a supine position. Pressing calcaneus to the operating table during surgery can cause recurvatum. This situation often escapes the attention of the surgeon. Therefore, reduction should be assessed with very good lateral fluoroscopic images during surgery. Manual traction should be applied and posterior of the fracture should be supported, leaving the calcaneus free.

The present study has some weaknesses. There was small number of cases, it was a retrospective study, and there was different fibula fracture fixation rate in the 2 groups (Group IMN: 13%, Group MIPO: 63%). In addition, as it was a retrospective study, functional assessment was done at different time for each patient.

In conclusion, IMN and MIPO had successful functional results in treatment of simple intra-articular distal tibial fractures. However, valgus malunion was more common in the IMN group, and recurvatum was more prevalent in the MIPO group. We think that this complication rate can be reduced to a lower level through careful radiological assessment during surgery. MIPO is the first preference according to the literature; however, successful results have been obtained with IMN in this fracture pattern.

Conflict of interest

The authors declare that they have no conflict of interest.

References

- Katsenis DL, Begkas D, Spiliopoulos G, Stamoulis D, Pogiatzis K. The results of closed intramedullary nailing for intra-articular distal tibial fractures. *J Orthop Trauma*. 2014;28:108–113.
- Ristiniemi J, Luukinen P, Ohtonen P. Surgical treatment of extra-articular or simple intra-articular distal tibial fractures: external fixation versus intramedullary nailing. *J Orthop Trauma*. 2011;25:101–105.
- Marcus MS, Yoon RS, Langford J, et al. Is there a role for intramedullary nails in the treatment of simple pilon fractures? Rationale and preliminary results. *Injury*. 2013;44:1107–1111.
- Yu J, Li L, Wang T, et al. Intramedullary nail versus plate treatments for distal tibial fractures: a meta-analysis. *Int J Surg*. 2015;16:60–68.
- Iqbal HJ, Pidikiti P. Treatment of distal tibia metaphyseal fractures; plating versus intramedullary nailing: a systematic review of recent evidence. *Foot Ankle Surg*. 2013;19:143–147.
- Xue XH, Yan SG, Cai XZ, Shi MM, Lin T. Intramedullary nailing versus plating for extra-articular distal tibial metaphyseal fracture: a systematic review and meta-analysis. *Injury*. 2014;45:667–676.
- Casstevens C, Le T, Archdeacon MT, Wyrick JD. Management of extra-articular fractures of the distal tibia: intramedullary nailing versus plate fixation. *J Am Acad Orthop Surg*. 2012;20:675–683.
- Li Y, Jiang X, Guo Q, Zhu L, Ye T, Chen A. Treatment of distal tibial shaft fractures by three different surgical methods: a randomized, prospective study. *Int Orthop*. 2013;38:1261–1267.
- Kuhn S, Greenfield J, Arand C, et al. Treatment of distal intra-articular tibial fractures: A biomechanical evaluation of intramedullary nailing vs. angle-stable plate osteosynthesis. *Injury*. 2015;46:99–103.
- Polat A, Kose O, Canbora K, Yanik S, Guler F. Intramedullary nailing versus minimally invasive plate osteosynthesis for distal extra-articular tibial fractures: a prospective randomized clinical trial. *J Orthop Sci*. 2015;20:695–701.
- Konrath G, Moed BR, Watson JT, Kaneshiro S, Karges DE, Cramer KE. Intramedullary nailing of unstable diaphyseal fractures of the tibia with distal intra-articular involvement. *J Orthop Trauma*. 1997;11(3):200–205.
- Robinson CM, McLauchlan GJ, McLean IP, Court-Brown CM. Distal metaphyseal fractures of the tibia with minimal involvement of the ankle. Classification and treatment by locked intramedullary nailing. *J Bone Jt Surg Br*. 1995;77:781–787.
- Janssen KW, Biert J, van Kampen A. Treatment of distal tibial fractures: plate versus nail: a retrospective outcome analysis of matched pairs of patients. *Int Orthop*. 2007;31:709–714.
- Vallier HA, Le TT, Bedi A. Radiographic and clinical comparisons of distal tibia shaft fractures (4 to 11 cm proximal to the plafond): plating versus intramedullary nailing. *J Orthop Trauma*. 2008;22:307–311.
- Marsh JL, Slongo TF, Agel J, et al. Fracture and dislocation classification compendium- 2007: orthopaedic trauma association classification, database and outcomes committee. *J Orthop Trauma*. 2007;21(Suppl. 10):S1–S133.
- Olerud C, Molander H. A scoring scale for symptom evaluation after ankle fracture. *Arch Orthop Trauma Surg*. 1984;103:190–194.
- Viberg B, Kleven S, Hamborg-Petersen E, Skov O. Complications and functional outcome after fixation of distal tibia fractures with locking plate - a multicentre study. *Injury*. 2016 Jul;47(7):1514–1518. pii: S0020-1383(16) 30126–7.
- Vidović D, Matejčić A, Ivica M, Jurišić D, Elabjer E, Bakota B. Minimally-invasive plate osteosynthesis in distal tibial fractures: results and complications. *Injury*. 2015;46:96–99.
- Weil YA, Gardner MJ, Boraiah S, Helfet DL, Lorich DG. Anterior knee pain following the lateral parapatellar approach for tibial nailing. *Arch Orthop Trauma Surg*. 2009;129:773–777.
- Egol KA, Weisz R, Hiebert R, Tejwani NC, Koval KJ, Sanders RW. Does fibular plating improve alignment after intramedullary nailing of distal metaphyseal tibia fractures? *J Orthop Trauma*. 2006;20:94–103.