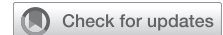

Photodynamic therapy with cryotherapy for endobronchial typical carcinoid



Vishal N. Shah, DO,^a David B. Berkheim, MD,^a Rudy P. Lackner, MD,^a and Karin P. Trujillo, MD,^b Omaha, Neb

From the ^aDivision of Cardiothoracic Surgery, Department of Surgery, University of Nebraska Medical Center; and ^bDepartment of Cardiothoracic Surgery, Methodist Physicians' Clinic, Omaha, Neb.

Disclosures: Pinnacle Biologics, the manufacturer of PDT with Photofrin (porfimer sodium), has agreed to pay the article processing charge of this manuscript. The authors reported no conflicts of interest.

The *Journal* policy requires editors and reviewers to disclose conflicts of interest and to decline handling or reviewing manuscripts for which they may have a conflict of interest. The editors and reviewers of this article have no conflicts of interest.

Received for publication Dec 23, 2021; revisions received April 9, 2022; accepted for publication April 18, 2022; available ahead of print April 22, 2022.

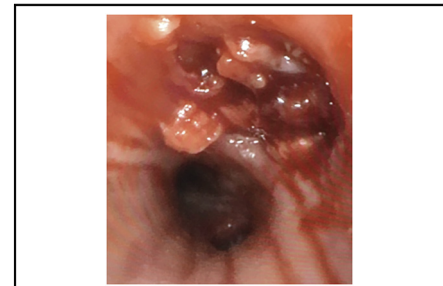Address for reprints: Vishal N. Shah, DO, Department of Surgery, Division of Cardiothoracic Surgery, University of Nebraska Medical Center, 42nd and Emile St, Omaha, NE 68198 (E-mail: ShahVN33@gmail.com).

JTCVS Techniques 2022;15:161-3

2666-2507

Copyright © 2022 The Author(s). Published by Elsevier Inc. on behalf of The American Association for Thoracic Surgery. This is an open access article under the CC BY-NC-ND license (<http://creativecommons.org/licenses/by-nc-nd/4.0/>).

<https://doi.org/10.1016/j.jtc.2022.04.018>



Endobronchial typical carcinoid tumor after PDT.

CENTRAL MESSAGE

PDT in endobronchial typical carcinoid is an effective technique in the thoracic surgeon's armamentarium that is under-used in patients unable to undergo resection or require extensive operations.

See Commentaries on pages 164 and 165.

▶ Video clip is available online.

Photodynamic therapy (PDT) is a seldom-reported application for endobronchial typical carcinoid (TC).¹⁻⁴ Although surgical resection is the mainstay of treatment, some patients may not be candidates or require extensive operations. Consequently, the authors describe their PDT experience in 2 patients (Video 1). Patient consent for publication was obtained.

METHODS

Patient Selection

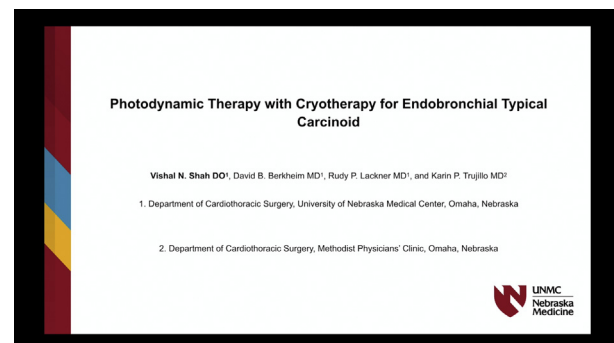
Patient 1 was a 65-year-old female with a 2-cm mass emanating from the left upper lobe bronchus and obstructing the mainstem bronchus (Figure 1, A and B). Patient 2 was a 70-year-old female with a 1.7-cm left mainstem pedunculated mass located at the bifurcation of the secondary carina (Figure 1, C). Biopsies revealed TC. Endobronchial ultrasound yielded negative lymph nodes.

Patients with purely intraluminal central TC measuring less than 2 cm, chest computed tomography (CT) without bronchial wall or lymph node invasion, and a negative mediastinum as staged by endobronchial ultrasound are ideal candidates for PDT. PDT is beneficial in patients who may require debulking to reduce the extent of planned resection (patient 1) or have an anatomically unfavorable tumor for bronchoplasty and abnormal pulmonary function making pneumonectomy high-risk (patient 2).

Treatment Protocol

Porfimer sodium 2 mg/kg is injected intravenously 48 to 72 hours before light exposure. Following the first PDT session, the patient is admitted to the hospital. Bronchoscopic reassessment with debriement to clear necrotic debris and illumination is done 2 and 4 days' post first light

illumination. Follow-up bronchoscopic examination is performed at 1 month. Endobronchial tumors are initially illuminated with 200 J/cm via insertion of the diffuser fiber through the working channel of the flexible fiberoptic bronchoscope.



VIDEO 1. Our PDT experience in 2 patients with endobronchial typical carcinoid. Video available at: [https://www.jtcvs.org/article/S2666-2507\(22\)00252-8/fulltext](https://www.jtcvs.org/article/S2666-2507(22)00252-8/fulltext).

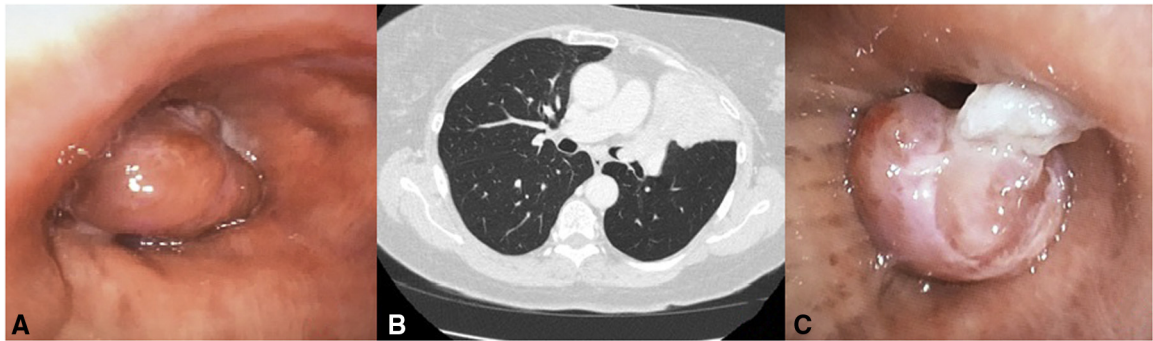


FIGURE 1. A, Typical carcinoid tumor originating from the left upper lobe bronchus (patient 1). B, Computed tomography of the chest demonstrating left upper lobe tumor extending into the proximal left mainstem bronchus (patient 1). C, Typical carcinoid tumor obstructing the left mainstem bronchus (patient 2).

Adverse Reactions Profile

Adverse reactions may include dyspnea, photosensitivity reaction, hemoptysis, pyrexia, cough, and pneumonia. Patients are advised to avoid exposure of skin and eyes to direct sunlight or bright indoor lights for at least 30 days. Due to potential for bronchial obstruction from tumor necrosis, we performed radiographs of the chest during admission.

Technique

Patient 1 received 200 J/cm interstitially and 100 J/cm to the tumor adjacent on both sides using a 2.5-cm diffuser fiber on Monday. The tumor was then illuminated with a power setting of 400 mw/cm for a dose of 200 J/cm with a 1.5-cm diffuser fiber for 500 seconds on Wednesday and Friday. The lesion was debried with cryotherapy and following this, the main bronchi were visible. One week later, the patient underwent additional debriedment and illumination with 100 J/cm for 250 seconds and following this, the left upper lobe segmental bronchi were patent. The 1-month bronchoscopy demonstrated complete airway patency.

Patient 2 initially underwent cryotherapy, but at follow-up there was persistent tumor. It was decided in our multidisciplinary tumor board to treat the refractory disease with PDT. The initial light treatment was 200 J/cm with a 1.5-cm diffuser fiber for 500 seconds. The lesion had significant tumor necrosis and debriedment was performed during the next 2 sessions. Two weeks later, the lesion was illuminated with 200 J/cm for 500 seconds. Tumor necrosis was debried with cryotherapy at 1 month. Flexible bronchoscopy revealed no tumor at 3 months (Figure 2, A).

Surveillance Protocol

We perform bronchoscopy and radiographs of the chest, alternating with chest CTs every 3 months after complete tumor clearance for the first year,

bronchoscopy with CT every 6 months for the second year and then annually.

For patient 1, bronchoscopy at 12 (Figure 2, B) and 36 months and CT at 12 (Figure 2, C) and 36 months revealed no tumor. Bronchoscopy (Figure 2, D) along with CT at 36 months revealed patient 2 to be tumor-free. Our relatively short follow-up may be insufficient to document recurrences.

DISCUSSION

Several endobronchial modalities have been reported.⁵ We avoid electrocautery or argon plasma coagulation because of the inherent risks of airway perforation and fire for both, bronchial wall damage after electrocautery, and limited penetration depth (2-3 mm) with argon plasma coagulation. In cases in which airway obstruction requires rapid relief, our first choice of treatment is neodymium-yttrium aluminum garnet laser therapy, especially since lasers offer deep penetration (up to 10 mm). Although cryotherapy does not lead to bronchial stenosis, it has less destructive power and limited penetration depth (2-5 mm) making it a poor choice for sole therapy. We believe there is adjunctive value to cryotherapy because its rapid freezing allows for thorough necrotic tumor debriedment during PDT. We prefer PDT over other modalities because it provides a predictable penetration depth (4-6 mm in a single

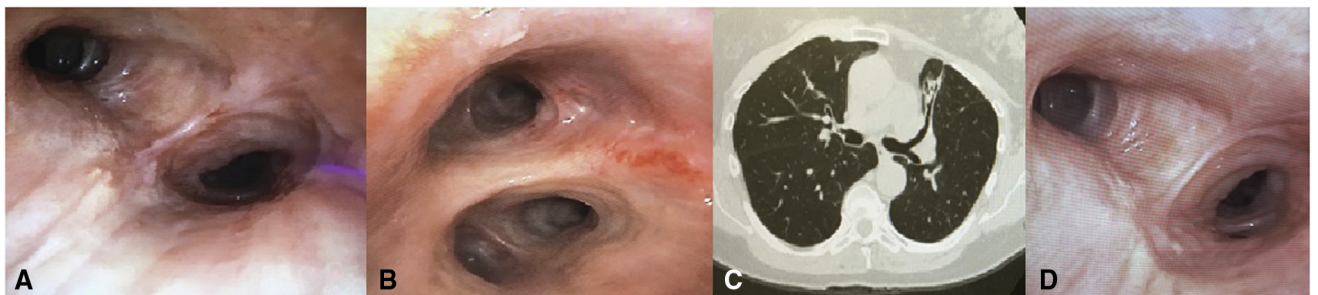


FIGURE 2. A, Bronchoscopy at 3 months demonstrating tumor clearance (patient 2). B, Bronchoscopy at 12 months demonstrating no tumor (patient 1). C, Computed tomography of the chest at 12 months demonstrating no disease (patient 1). D, Bronchoscopy at 36 months demonstrating no tumor (patient 2).

direction, up to a 10-12 mm radius), the ability to treat large surfaces, selective tumoricidal action with immunogenic properties and curative potential.¹⁻⁴

References

1. Downie GH, Qureshi A. Endobronchial ablation of typical carcinoid tumor with photodynamic therapy. *J Bronchol.* 2007;14:10-4.
2. Loewen G, Cerfolio R, Bryant A, Pettiford B, Roundy T, Skabla P, et al. Photodynamic therapy for patients with endobronchial carcinoid. *Chest.* 2016;150:706A.
3. Moghissi K, Dixon K, Gibbins S. Photodynamic therapy for bronchial carcinoid tumours: complete response over a 10-year follow-up. *Eur J Cardiothorac Surg.* 2013;43:1254-6.
4. Kurman JS, Pastis NJ, Murgu SD. Photodynamic therapy and its use in lung disease. *Curr Pulmonol Rep.* 2019;8:215-21.
5. Sachdeva A, Pickering EM, Lee HJ. From electrocautery, balloon dilatation, neodymium-doped: yttrium-aluminum-garnet (Nd: YAG) laser to argon plasma coagulation and cryotherapy. *J Thorac Dis.* 2015;7:S363.