
Peripartum Respiratory Failure with Bilateral Pulmonary Infiltrates on Chest X-Ray

Gladys W.M. Kwan Chi-Kwan Koo

Department of Anaesthesia and Intensive Care, Tuen Mun Hospital, Hong Kong, SAR, China

Key Words

Peripartum · Pulmonary infiltrates · Metastatic pulmonary choriocarcinoma · Hemoptysis · Neoplasia · Respiratory failure

Abstract

Choriocarcinoma is a gestational trophoblastic disease that carries high mortality. As this disease is highly responsive to chemotherapy, early diagnosis could lead to a favorable outcome. We report a case of metastatic pulmonary choriocarcinoma presented with hemoptysis and respiratory failure in a young woman at her third trimester. This report discusses the dilemma in deriving the diagnosis of choriocarcinoma and briefly outlines the current approaches to its treatment. Potentially life-threatening choriocarcinoma should be considered in all unusual chest radiographs of women of childbearing age. Clinicians should be aware of this possibility and proceed with the most appropriate diagnostic procedures.

Introduction

We report a case of metastatic pulmonary choriocarcinoma that presented with hemoptysis and respiratory failure. The diagnosis and management of this case are discussed.

Case Report

Our patient is a 29-year-old G5P3+2 at her 34th week of gestation. Her past obstetric history reveals that she has had 2 full-term spontaneous deliveries and 2 terminations.

She was first seen at 19 weeks of gestation and was subsequently admitted at 34 weeks for high blood pressure of 143/79 mm Hg and albuminuria (++) . Although the blood pressure remained elevated, there were no signs of clinically significant preeclampsia. The fetus growth corresponded to the course of pregnancy.

The patient was dyspneic and complained of having a cough and sputum with bloody streaks 3 days after admission. Oxygen saturation was 90% in room air, but increased to 95% upon the administration of 2 l/min of oxygen via a nasal cannula. Systolic ejection murmur was detected at the left sternal border. Contrast echocardiographic examination of the heart showed a secundum atrial septal defect (ASD) of 1.8 cm with left to right shunt and pulmonary hypertension ([fig. 1](#)). Medical history revealed that the patient had had recurrent hemoptysis for a week prior to admission. Chest X-ray showed diffuse haziness over both lung fields.

Induction of labor was subsequently performed because cardiotocographic monitoring revealed a suboptimal fetal condition. A live birth of 2.14 kg, with an Apgar score of 8 at 1 and 5 min, was delivered by vaginal delivery.

The patient was then admitted to the Intensive Care Unit because preeclampsia and suboptimal oxygenation were apparent. She was put on magnesium sulfate and diltiazem infusion for preeclampsia. Infective and rheumatological causes for the bilateral pulmonary infiltrates were sought. Signs of preeclampsia were resolved 2 days after treatment, but the patient remained dyspneic with increasing pulmonary infiltrates ([fig. 2a](#)). Although computed tomography (CT) of the thorax ruled out pulmonary embolism, extensive patchy consolidation and nodular infiltrates were found ([fig. 2b](#)).

Two days later, the patient was intubated and ventilated for progressive hypoxemia. She remained difficult to oxygenate, requiring a high level of positive end-expiratory positive pressure, inspired oxygen, and nitric oxide. Microbiological and rheumatological investigations revealed no further significant findings relating to the pulmonary infiltrates. Trophoblastic disease was suspected and the first measured serum gestational human chorionic gonadotropin (hCG) level was 614,068 IU/l. Metastatic choriocarcinoma was subsequently confirmed by an open lung biopsy, and methotrexate (MTX) was given immediately after the operation.

The patient's hCG levels dropped significantly after an initial dose of MTX, but they increased again on day 10. She was then given a combined course of etoposide (VP 16), MTX, and bleomycin. The hCG levels decreased substantially, and further 6 cycles were given. Her condition improved gradually, and she was transferred to the gynecological oncology centre, where she was subsequently discharged.

During regular follow-ups, she was found to have raised hCG levels 2 months after her last dose of chemotherapy. Whole-body CT scan and lumbar puncture revealed lung and suspected brain metastases. She was then put on chemotherapy using etoposide-methotrexate-actinomycin D-cyclophosphamide-vincristine (EMA-CO). Her hCG levels returned to normal after 4 more cycles of EMA-CO, and she remained in remission.

Discussion

Gestational Trophoblastic Neoplasia (GTN)

GTN was previously regarded as a gynecologic malignancy with high mortality, but it has recently become one of the most curable malignancies as it is chemosensitive in nature [1]. The incidence of gestational trophoblastic disease (GTD) varies between 1 in 120 pregnancies in some parts of Asia and South America and 1 in 1,200 in the United States [2]. Although choriocarcinoma, a form of GTD, is relatively rare, cases have been found in Africa, Asia and South America, with a majority of them occurring in women aged below 35 [3].

The Origin of Choriocarcinoma and Its Associated Symptoms

Choriocarcinoma has a tendency towards early vascular invasion with widespread dissemination. Trophoblastic tumors are frequently hemorrhagic, since they are often perfused by a network of fragile vessels. Symptoms of metastases may therefore result from spontaneous bleeding at metastatic foci.

Recurrent hemoptysis seems to be the most frequent symptom in pulmonary choriocarcinoma, which is often associated with chest pain and persistent cough [4], with distal metastases commonly present in the brain, vagina, and kidneys. There are 3 main types of pulmonary choriocarcinoma that are caused by hematogenous metastases [5, 6]. First, well-defined and rounded nodular lesions are observed in 65–95% of patients and some nodules may cavitate. Second, 5–15% of cases have military or alveolar pattern with indefinite borders simulating an inflammatory process on chest X-ray. Third, it may present with pulmonary infarction and hypertension due to tumor embolisation of the pulmonary artery.

Approaches to Making the Correct Diagnosis

The initial diagnosis was difficult because the patient had numerous respiratory problems. The preliminary diagnosis was thought to be primary pulmonary disease because of the apparent hemoptysis, dyspnea, and a diffuse pulmonary infiltration. The patient's rapidly deteriorating condition could not be explained as there were no autoimmune makers or signs of infection, and her CT of the thorax already ruled out pulmonary embolism. The incidental finding of the ASD with pulmonary hypertension was thought to be the culprit, but she did not respond to heart failure treatments. The elevated hCG levels coupled with other clinical presentations suggested metastatic choriocarcinoma, which was subsequently confirmed by the open lung biopsy.

Peripartum hemoptysis carries a broad differential diagnosis that encompasses a variety of causes including (i) thromboembolic diseases, such as pulmonary embolism; (ii) vascular pathology, such as vasculitis/arteriovenous malformation; (iii) inflammation; (iv) infection; (v) autoimmune disease, such as microscopic polyangiitis or pulmonary renal syndrome; (vi) peripartum cardiomyopathy, and (vii) primary or secondary malignancy.

Metastatic workup in this group of patients should include a variety of imaging techniques as well as serum hCG measurements. Most hepatic metastases in patients with abnormal liver function tests are typically shown in liver ultrasonography and CT imaging. CT and magnetic resonance imaging brain scans can facilitate the early diagnosis of asymptomatic cerebral lesion. In the absence of lung or vaginal metastasis, the risk of cerebral and hepatic spread is exceedingly low [7]. ^{218}F -fluoro-2-deoxy-D-glucose positron emission tomography (FDG-PET) can assist differential diagnosis by locating the possible metastatic or persistent lesions and by providing information on tumor activity [8].

The Significance of hCG

hCG, a tumor product of biological and clinical significance, is a glycoprotein that consists of an alpha subunit, which is structurally similar to luteinizing hormone (LH) and thyroid stimulating hormone, and a beta subunit, which provides the antigenic uniqueness that permits its detection using radioimmunoassay [9]. After pregnancy termination, there is a predictable decrease in β -hCG titer levels. By the 8th postpartum week, these values are within the normal physiological range of LH secretion. Persistent elevation of hCG levels in postpartum patients should prompt an immediate intensive diagnostic study.

Although hCG is a sensitive and specific tumor marker for monitoring response to treatment, false-positives sometimes occur at low levels due to the presence of non-specific heterophilic antibodies in the patient's sera. An additional urine pregnancy test may be useful as the heterophilic antibodies are not excreted in the urine. The lack of dilution parallelism and the absence of urine reactivity indicate that the molecule measured was a pseudogonadotropin (i.e. phantom hCG), which is the interfering substance in the hCG test [10]. Care is needed in interpreting persistently low levels of hCG in patients without a history of trophoblastic disease in order to avoid unnecessary intervention.

Treatment of GTN

High-risk metastatic disease is initially treated with combination chemotherapy with or without adjuvant radiotherapy or surgery. While several drug combinations have been used, the EMA-CO is the most effective with the reported 5-year survival rate at around 85% [11, 12]. The use of a new anti-cancer agent paclitaxel [13] or high doses of chemotherapy coupled with autologous bone marrow support and G-CSF have been reported [14]. Cisplatin, vinblastine, and bleomycin may also be effective as a 2nd-line therapy [15, 16].

There is no consensus, however, on the duration of chemotherapy. It is recommended that the chemotherapy should be stopped when the hCG levels become undetectable, yet some recommend additional courses for high-risk GTN. The ultimate decision should be based on whether the patient falls into a low- or a high-risk category and the gradient of the hCG regression curve.

Adjuvant surgical procedures, especially hysterectomy and pulmonary resection, for chemotherapy-resistant disease as well as procedures to control hemorrhage are important approaches to the management of high-risk GTN [17]. Radiotherapy with concurrent chemotherapy has been used for CNS metastasis with 5-year survival averaging at 50% [18].

Conclusions

The possibility of choriocarcinoma manifestation, albeit small, should be considered in all unusual chest radiographs of women of childbearing age. Early diagnosis is crucial, as this condition is very treatable. Clinicians should be aware of this possibility and proceed with the most appropriate diagnostic procedures.

Fig. 1. Transthoracic echocardiogram (subcostal view) showing secundum atrial septal defects with left to right shunt.

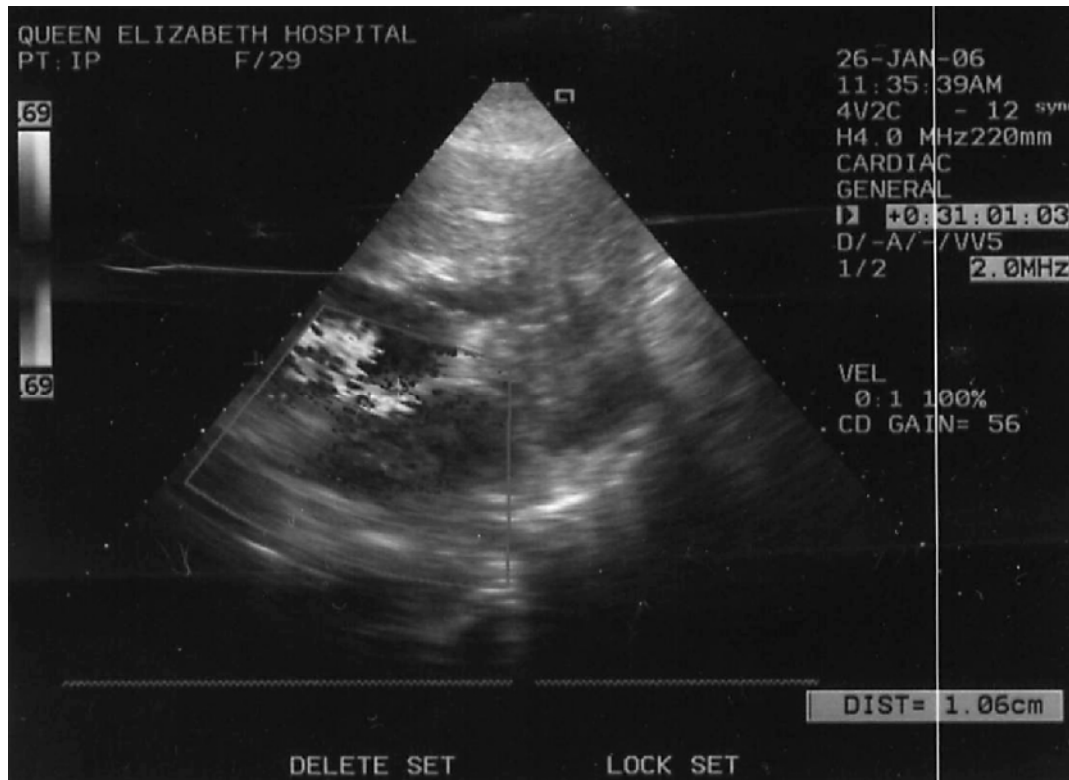
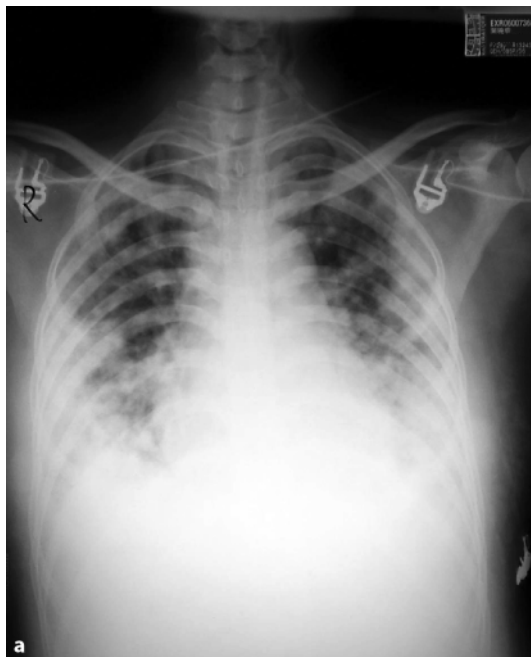
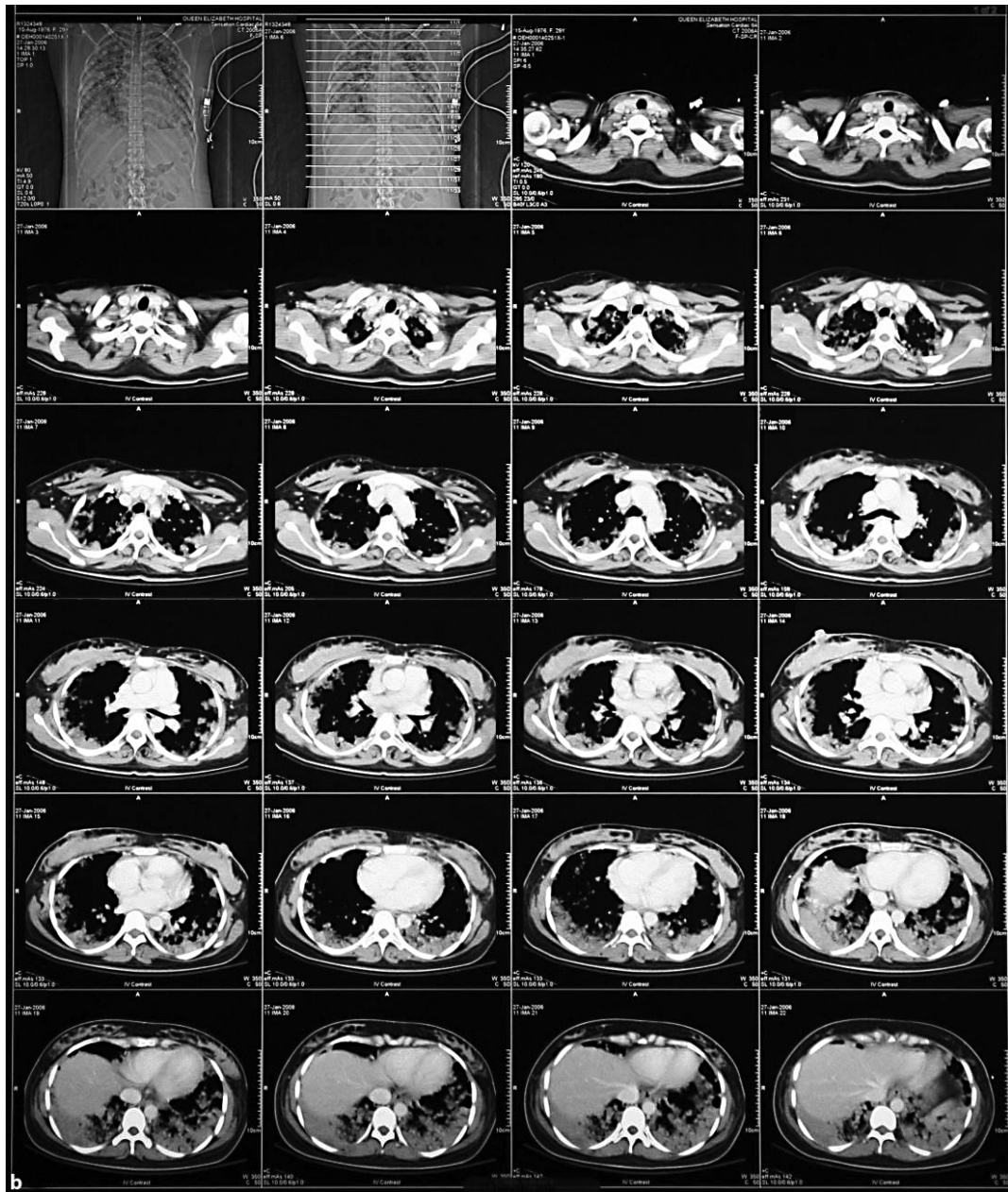


Fig. 2. Chest X-ray (a) and computer tomography of the thorax (b) show patchy and extensive nodular infiltrates.





References

- 1 Berkowitz RS, Goldstein DP: Chorionic tumors. *N Engl J Med* 1996;335:1740–1748.
- 2 Balagopal PG, Pandey M, Chandramohan K, Somanathan T, Kumar A: Unusual presentation of choriocarcinoma. *World J Surg Oncol* 2003;1:4.
- 3 Fox H, Buckley CH: The female genital tract and ovaries; in McGee JOD, Isaacson PG, Wright NA (eds): *Oxford Text Book of Pathology*, ed 2. New York, Oxford University Press, 1992, vol 2a, pp 1565–1639.
- 4 Arslanian A, Pischedda F, Filosso PL, Di Marzio P, Oliaro A, Fraire F, Papotti M: Primary choriocarcinoma of the lung. *J Thorac Cardiovasc Surg* 2003;125:193–196.
- 5 Libshitz HI, Baber CE, Hammond CB: The pulmonary metastases of choriocarcinoma. *Obstet Gynecol* 1997;49:412–416.
- 6 Bagshawe KD, Garnett ES: Radiological changes in the lungs of patients with trophoblastic tumours. *Br J Radiol* 1963;36:673–679.
- 7 Ng TY, Wong LC: Diagnosis and management of gestational trophoblastic neoplasia. Review. *Best Pract Res Clin Obstet Gynaecol* 2003;17:893–903.
- 8 Chang WC, Hung YC, Shen HP, Kao CH: Choriocarcinoma with pulmonary metastasis: report of a case of successful treatment with serial PDG-PET follow up. *J Reprod Med* 2007;52:450–452.
- 9 Smith LH, Friedman MA: Choriocarcinoma and gestational trophoblastic disease – Medical Staff Conference, University of California, San Francisco. *West J Med* 1976;124:219–225.
- 10 Cole LA: Phantom hCG and phantom choriocarcinoma. *Gynecol Oncol* 1998;71:325–329.
- 11 Nozue A, Ichikawa Y, Minami R, Tsunoda H, Nishida M, Kubo T: Postpartum choriocarcinoma complicated by brain and lung metastases treated successfully with EMA/CO regimen. *Br J Obstet Gynaecol* 2000;107:1171–1172.
- 12 Hiramatsu Y, Masuyama H, Ishida M, Murakami K, Sakurai M: Term delivery choriocarcinoma patient with brain and lung metastases successfully treated by etoposide, methotrexate, actinomycin D, cyclophosphamide and vincristine (EMA-CO) chemotherapy. *Acta Med Okayama* 2005;59:235–238.
- 13 Jones WB, Schneider I, Shapiro F, Lewis JL Jr: Treatment of resistant gestational choriocarcinoma with taxol: a report of two cases. *Gynecol Oncol* 1996;61:126–130.
- 14 Newlands ES, Bower M, Holden L, Short D, Seckl MJ, Rustin GJ, Begent RH, Bagshawe KD: Management of resistant gestational trophoblastic tumors. *J Reprod Med* 1998;43:111–118.
- 15 Wong LC, Choo YC, Ma HK: Etoposide, methotrexate and bleomycin in drug-resistant gestational trophoblastic disease. *Gynecol Oncol* 1986;24:51–57.
- 16 Willemse PH, Aalders JG, Bouma J, Sleijfer DT: Chemotherapy-resistant gestational trophoblastic neoplasia treated successfully with cisplatin, etoposide and bleomycin. *Obstet Gynecol* 1988;71:438–440.
- 17 Lurain JR, Singh DK, Schink JC: Role of surgery in the management of high-risk gestational trophoblastic neoplasia. *J Reprod Med* 2006;51:773–776.
- 18 Small W Jr, Lurain JR, Shetty RM, Huang CF, Applegate GL, Brand WN: Gestational trophoblastic disease metastatic to the brain. *Radiology* 1996;200:277–280.