



Suspending Commissural Sutures for Aortic Valve Exposure in Minithoracotomy Aortic Valve Replacement

Eunji Kim, M.D., Joon Bum Kim, M.D., Ph.D.

Department of Thoracic and Cardiovascular Surgery, Asan Medical Center, University of Ulsan College of Medicine, Seoul, Korea

ARTICLE INFO

Received February 8, 2021

Revised April 1, 2021

Accepted April 23, 2021

Corresponding author

Joon Bum Kim

Tel 82-2-3010-3580

Fax 82-2-3010-6966

E-mail jbkim1975@amc.seoul.kr

ORCID

<https://orcid.org/0000-0001-5801-2395>

Although it is attractive, a limitation of aortic valve (AV) replacement (AVR) through a mini-thoracotomy approach (mini-AVR) is the limited exposure of the AV. Here, we present a simple exposure technique named “suspending commissural sutures” for a more efficient mini-AVR. The technique involves making 3 half-depth stitches with 1-0 silk at each of the commissures, which are anchored to each corresponding pericardial surface. These stitches are tightened up so that the aortic root is axially expanded and is pulled upward. The technique of suspending commissural stitches seems to offer reasonable exposure of the AV in mini-AVR, and shows excellent early surgical outcomes.

Keywords: Aortic valve replacement, Aortic valve exposure, Minimally invasive surgery

Introduction

Aortic valve (AV) replacement (AVR) through a mini-thoracotomy approach (mini-AVR) has several demonstrable advantages over full sternotomy, such as less surgical bleeding, less postoperative pain, and faster recovery [1,2]. However, it is regarded as technically challenging because of the limited exposure of the surgical field. Here, we present a simple exposure technique for more efficient mini-AVR.

Methods

For isolated mini-AVR, an approximately 5- to 7-cm right anterior thoracotomy (RAT) incision is made through the second intercostal space, while right anterolateral thoracotomy (RALT) with a similar incisional length is performed over the fourth intercostal space for mini-AVR combined with other cardiac procedures (e.g., mitral, tricuspid, ablation, and atrial septal defect surgery). Groin access is the standard approach for cardiopulmonary bypass, but cannulation of the ascending aorta is performed in selected cases with distal atherosclerosis. The venting catheter is inserted through the right upper pulmonary vein. After aortic cross-clamping and antegrade cardioplegic arrest, an oblique aortotomy follows in the usual fashion.

Half-depth stitches with 1-0 silk are then made at each of the AV commissures, and the needles are passed through each corresponding pericardial surface so that the aortic root is suspended on the pericardium. Gentle traction and tightening up of these threads result in expansion of the aortic root axially, bringing the AV toward the incisional site so that the operating surgeon has a clear view inside the entire aortic root (Figs. 1, 2 and Supplementary Video 1). The diseased AV cusps are then excised, and the AVR is completed in the usual fashion. Of note, the commissural sutures should be released during valve sizing and placing the prosthetic valves because they are likely to interfere at the sinotubular junction once the 3 threads are tightened up, posing a risk of aortic injury during the engagement of the prostheses.

The study was approved by the Institutional Review Board of Asan Medical Center (IRB approval no., S2020-2519-0001). Informed consents were obtained from all individual participants included in the study.

Results

From November 2017 through September 2020, a total of 93 consecutive patients (age, 67.6±11.2 years; 46 women) underwent mini-AVR using this “suspending commissural sutures” technique, including 72 isolated and 21 combined



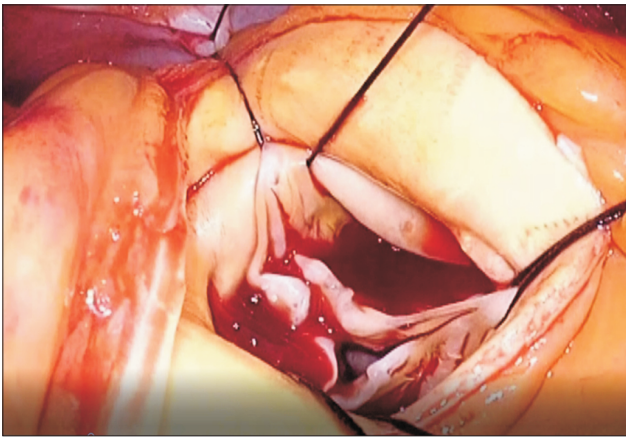


Fig. 1. Suspending commissural sutures to expose the aortic valve via right anterolateral thoracotomy.

AVRs by a single surgeon (J.B.K.) at the Asan Medical Center, Seoul, Korea, which dates from the initial experiences of the mini-AVR. Combined AVR involved mitral valve repair or replacement in 8 patients (8.6%), tricuspid annuloplasty in 5 (5.4%), ablation of atrial fibrillation in 12 (12.9%), and closure of an atrial septal defect in 5 (5.4%). Sutureless or rapid-deployment devices were used in 31 cases (33.3%). There were 3 cases of conversion to sternotomy: 2 in isolated AVR (2.8%) and 1 in combined AVR (4.8%). The mean aortic clamping and cardiopulmonary bypass times were 54.6 ± 23.3 minutes and 82.1 ± 36.6 minutes, respectively, in isolated AVR, and were 106.6 ± 39.4 minutes and 159.0 ± 56.5 minutes, respectively, for combined AVR. There was 1 case of early mortality (1.1%). The major complications that occurred were temporary neurological deficits in 3 patients (3.2%), reoperation for bleeding in 1 (1.1%), new-onset dialysis in 3 (3.2%), and permanent pacemaker implantation in 1 (1.1%). There was 1 case of repeated AVR during the index hospitalization due to paravalvular leakage after rapid-deployment isolated AVR (1.1%).

Discussion

Despite several convincing advantages of mini-AVR over standard sternotomy, the routine adoption of this method has been hindered by its limitations, including restricted exposure of the surgical field, technical difficulty, and a steep learning curve [1-3]. For these reasons, several anatomical criteria have been suggested to select suitable patients for mini-AVR, such as a favorable location of the AV relative to the sternum and a certain range of angle of the proximal aorta relative to the horizontal axis [4]. These se-

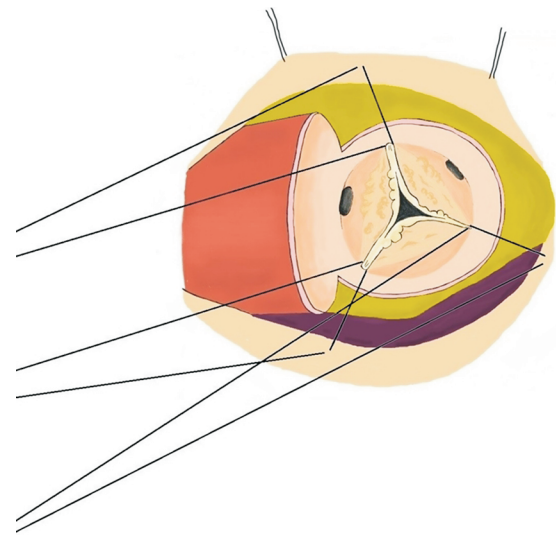


Fig. 2. Illustration of suspending commissural sutures. Half-depth stitches with 1-0 silk are made at each of the commissures, and the needles are passed through each corresponding pericardial surface so that the aortic root is suspended on the pericardium. Gentle traction of these threads results in expansion of the aortic root axially, bringing the aortic valve toward the incisional site.

lection criteria certainly make it possible to identify the best candidates for this approach, but encompass only a limited proportion of all isolated AVR patients, limiting its reproducibility and generalizability. To overcome these limitations, a method using a retracting tool inside the aortic root—the Aortic Cuff (Miami Instruments, Miami, FL, USA)—has also been introduced for better visualization of the AV in mini-AVR [5]. This useful but costly adjunct, however, may also have a limitation because the instrument itself may interfere with the surgical field in the tight spaces that are encountered in some cases.

Our technique, in these senses, has an advantage in that it makes it possible to simply expose the AV in a narrow space only by making several sutures. The use of commissural stitches is popular for conventional AVR, which gives excellent exposure of the AV. This usually involves making 3 stitches on the commissures and pulling them outward so that the aortic root is visualized wide open axially. As the incisional site is small and distant from the AV in mini-thoracotomy AVR, however, the sutured threads do not axially open the aortic root with this approach. Therefore, the visualization of the AV is typically hindered by the aortic root wall. The unique feature of the present technique is that it involves an additional tagging suture against the corresponding facing pericardium so that the thread area is pulled outward. Starting with our initial experiences, we perceived that this technique makes it possi-

ble to perform isolated AVR via RAT regardless of whether patients meet the anatomical criteria for RAT, and based on these experiences, the technique could have been extended to combined AVR through RALT, which had not been regarded as a standard approach for AVR. This technique has now been established at our center as the default approach for surgical AVR on a routine basis, with the only exceptions being combined aortic or coronary surgery, which is performed through the sternotomy approach.

To summarize, mini-AVR aided by suspending commissural sutures offered excellent exposure of the AV and showed acceptable early surgical outcomes in our series. Based on these experiences, we believe that this technique is an effective and reproducible method of exposing the AV in mini-AVR.

Conflict of interest

No potential conflict of interest relevant to this article was reported.

ORCID

Eunji Kim: <https://orcid.org/0000-0003-1597-0854>

Joon Bum Kim: <https://orcid.org/0000-0001-5801-2395>

Supplementary materials

Supplementary materials can be found via <https://doi.org/10.5090/jcs.21.014>. **Supplementary Video 1.** Aortic valve replacement using suspending the commissural sutures technique to expose the aortic valve in double valve replacement surgery via right anterolateral thoracotomy.

References

1. Brown ML, McKellar SH, Sundt TM, Schaff HV. *Ministernotomy versus conventional sternotomy for aortic valve replacement: a systematic review and meta-analysis*. J Thorac Cardiovasc Surg 2009;137:670-9.
2. Murtuza B, Pepper JR, Stanbridge RD, et al. *Minimal access aortic valve replacement: is it worth it?* Ann Thorac Surg 2008;85:1121-31.
3. Schmitto JD, Mokashi SA, Cohn LH. *Minimally-invasive valve surgery*. J Am Coll Cardiol 2010;56:455-62.
4. Glauber M, Ferrarini M, Miceli A. *Minimally invasive aortic valve surgery: state of the art and future directions*. Ann Cardiothorac Surg 2015;4:26-32.
5. Lamelas J. *Minimally invasive aortic valve replacement: the "Miami Method"*. Ann Cardiothorac Surg 2015;4:71-7.