

This article is licensed under the Creative Commons Attribution-NonCommercial 4.0 International License (CC BY-NC) (<http://www.karger.com/Services/OpenAccessLicense>). Usage and distribution for commercial purposes requires written permission.

## Single Case

# Plasmapheresis for Refractory Pruritus due to Drug-Induced Cholestasis

Hasan Al-Azzawi<sup>a</sup> Ruchi Patel<sup>b</sup> Gagan Sood<sup>b</sup> Sumit Kapoor<sup>a</sup>

<sup>a</sup>Department of Pulmonary, Critical Care and Sleep, Baylor College of Medicine, Houston, TX, USA; <sup>b</sup>Department of Abdominal Transplantation, Baylor College of Medicine, Houston, TX, USA

## Keywords

Refractory · Plasmapheresis · Cholestasis · Pruritus · Drug-induced cholestasis

## Abstract

Pruritus can be a distressing symptom seen in various cholestatic disorders. It is treated with medications like bile acid sequestrants. Drug-induced cholestasis usually resolves with withdrawal of the causative medication. We describe a case of refractory pruritus due to drug-induced cholestasis, not improved with withdrawal of the drug, managed effectively with multiple sessions of plasmapheresis.

© 2016 The Author(s)  
Published by S. Karger AG, Basel

## Introduction

Pruritus is a common and disabling symptom seen in various cholestatic liver disorders like primary biliary cirrhosis (PBC), primary sclerosing cholangitis (PSC), intrahepatic cholestasis of pregnancy (ICP), and drug-induced cholestasis, the incidence ranging from 20 to 80% [1]. Bile salts, endogenous opioids, serotonin, and lysophosphatidic acid have been implicated in the pathogenesis of pruritus [2, 3]. Plasmapheresis has been described in the literature as a safe and rapidly effective treatment for intractable pruritus due to cholestasis of PBC, PSC, and ICP [4–10]. We report a case of refractory pruritus due to drug-induced

cholestasis, not improved with withdrawal of the offending drug, managed effectively by plasmapheresis.

### Case Description

A 77-year-old male with a past medical history of obstructive sleep apnea using CPAP (continuous positive airway pressure) device at home, hypertension, hyperlipidemia, and atrial fibrillation was referred to our hospital for a higher level of care. He complained of intense itching all over the body for 10 days, which was gradually worsening and yellowish discoloration of the skin for 4 days. He was a past smoker, quit smoking 35 years ago, and had occasional alcohol intake. He denied any history of abdominal pain, fever, fatty stools, anorexia, fatigue, body piercing, or blood transfusions. There was no family history of any liver disorders. Before coming to our hospital, his pruritus was treated with diphenhydramine 25 mg 3 times a day, prednisone 40 mg daily for 5 days and fexofenadine 180 mg daily for 5 days with minimal relief. Of note, he took amiodarone 200 mg daily for 2 years for atrial fibrillation and was taken off the medication 2 months prior to the presentation. He was also taking over-the-counter herbal medication at the time of admission. His pertinent physical exam findings were scleral icterus and jaundice all over the body and evidence of scratch marks and excoriations from itching but no abdominal distention and tenderness. His admission laboratory results were significant for AST of 349 U/L, ALT of 592 U/L, ALP of 825 U/L, total bilirubin of 20 mg/dL, direct bilirubin of 12.5 mg/dL, creatinine of 1.59 mg/dL, hemoglobin of 11.5 gm/dL, INR of 1.9, PT 22.2 s, and PTT 36.3 s. His lab workup for liver failure was essentially negative including hepatitis panel, antimitochondrial antibody,  $\alpha_1$ -antitrypsin and  $\alpha$ -fetoprotein levels. The abdomen MRI upon admission showed no cirrhosis and no intra- and extrahepatic biliary dilatation. He underwent transjugular liver biopsy which showed mixed cholestatic and hepatocellular injury pattern with acute hepatitis, hepatocyte necrosis, extensive intrahepatic and intracanalicular cholestasis, and micro- and macrovesicular steatosis, probably related to drug-induced liver disease (DILD) due to the use of amiodarone and over-the-counter herbal supplements (Fig. 1, 2). His intractable pruritus was refractory to management with antihistamines and cholestyramine, and was impacting his care leading to sleep deprivation and agitation. We do not have resources for extracorporeal liver dialysis at our hospital. He was transferred to medical ICU for the initiation of plasmapheresis. He showed quick, significant, and long-lasting improvement in pruritus after 3 daily sessions (4 h each) of plasmapheresis in medical ICU. His mean total bilirubin levels improved from 21 to 14 mg/dL after 3 sessions of plasmapheresis.

### Discussion

PBC, PSC, ICP, drug-induced cholestasis, and benign recurrent intrahepatic cholestasis are the common intrahepatic cholestatic disorders associated with pruritus [1]. Pruritus or itching can manifest as simple intermittent itching to severe disability interfering with patient's quality of life, leading to sleep deprivation, emotional disturbances, and even suicidal ideations. Severe refractory pruritus has been accepted as an indication for liver transplantation to improve patient's quality of life [11]. Pruritus is usually worse at night, can be generalized or localized to palms, soles, extensor surfaces of extremities or upper trunk, and is exacerbated by stress. Multiple mechanisms have been proposed for the pathogenesis of

itching in liver disease [2, 3]. The most common theory relates to the bile salt deposition on nerve endings on the skin or direct effect of bile salts on hepatocytes. Endogenous opioids like met-enkephalins and leu-enkephalins, serotonin, and lysophosphatidic acid have also been implicated in the pathogenesis of itching. There is no single pruritogenic factor, and the treatment of pruritus is considered empiric and none of the options are consistently effective.

In the US, the prevalence of drug-induced cholestasis is reported to be around 20% in the elderly population [12]. Cholestatic and mixed cholestatic and hepatocellular injury are the 2 most severe manifestations of DILD. Drug-induced cholestasis usually resolves with withdrawal of the offending drug [13]. The conventional management of pruritus includes bile acid sequestrants like cholestyramine and colestipol which bind bile acids in the intestine, thereby preventing their enterohepatic circulation and excreting them in stool [1]. Rifampicin, phenobarbital, opioid antagonists like naltrexone and naloxone, serotonin antagonists like ondansetron and sertraline, and antihistamines have also been studied and used clinically with inconsistent results [1].

More invasive measures like plasmapheresis and extracorporeal liver dialysis with molecular adsorbent recirculating system (MARS) have been used effectively in cases of severe refractory pruritus not amenable to conventional management [4–10, 14, 15]. There have been only 2 reports in the literature of intractable pruritus due to drug-induced cholestasis managed by extracorporeal albumin dialysis using MARS but none with plasmapheresis [14, 15]. We believe that one limitation of extracorporeal liver dialysis is that it is not readily available at all centers compared to plasmapheresis. Plasmapheresis removes all peripheral and centrally acting pruritogens from plasma and tissues of patients with cholestasis and pruritus. It is a relatively safe procedure, well tolerated, even in pregnant patients [4, 10]. Some rare complications of plasmapheresis include bleeding, infection, coagulation abnormalities, and electrolyte disturbances [5].

We report a case of refractory pruritus due to drug induced cholestasis (secondary to amiodarone and herbal supplement use) where patient symptoms did not get better with withdrawal of the offending drug and the patient underwent plasmapheresis without any complications, leading to long-lasting improvement of his symptoms.

## Conclusion

Plasmapheresis is a safe and effective treatment for management of refractory pruritus in cholestatic liver diseases. We describe a case of refractory pruritus due to DILD where plasmapheresis led to a quick and long-lasting relief of patient's symptoms. Plasmapheresis should be strongly considered for refractory pruritus due to drug-induced cholestasis if symptoms are not improved with stopping the offending drug and if resources for extracorporeal liver support are limited.

## Statement of Ethics

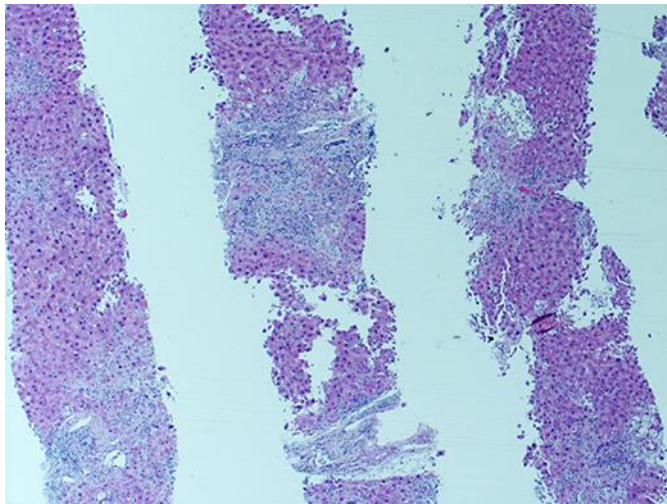
Written informed consent was obtained for the publication of this case report. The research was performed at Baylor St. Luke's Medical Center, Houston, TX. Our research is independent and impartial, and we ensure quality and integrity of the case report.

## Disclosure Statement

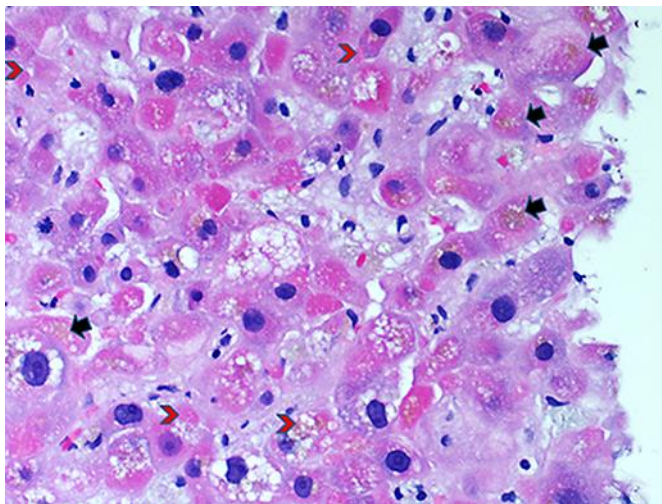
The authors have no conflict of interest to disclose.

## References

- 1 Bunchorntavakul C, Reddy KR: Pruritus in chronic cholestatic liver disease. *Clin Liver Dis* 2012;16:331–346.
- 2 Khandelwal M, Malet PF: Pruritus associated with cholestasis. A review of pathogenesis and management. *Dig Dis Sci* 1994;39:1–8.
- 3 Garden JM, Ostrow JD, Roenigk HH Jr: Pruritus in hepatic cholestasis. Pathogenesis and therapy. *Arch Dermatol* 1985;121:1415–1420.
- 4 Alallam A, Barth D, Heathcote EJ: Role of plasmapheresis in the treatment of severe pruritus in pregnant patients with primary biliary cirrhosis: case reports. *Can J Gastroenterol* 2008;22:505–507.
- 5 Ambinder EP, Cohen LB, Wolke AM, Field SP, Adelsberg B, Schaffner F, Zaroulis CG: The clinical effectiveness and safety of chronic plasmapheresis in patients with primary biliary cirrhosis. *J Clin Apher* 1985;2:219–223.
- 6 Fuhrmann V, Drolz A, Trauner M: Extracorporeal artificial liver support systems in the management of intractable cholestatic pruritus. *Liver Int* 2011;31(suppl 3):31–33.
- 7 Geerdink P, Snel P, van Berge Henegouwen GP, Huybregts A, Tangerman A, Kunst VA, van Tongeren JH: Treatment of intractable pruritus in patients with cholestatic jaundice by plasma exchange and plasma perfusion. *Netherlands J Med* 1978;21:239–244.
- 8 Omokawa S, Yamashita M, Malchesky PS, Koo AP, Matsushita M, Nose Y: Therapeutic plasmapheresis for cholestatic liver diseases: study of 9 cases. *Prog Clin Biol Res* 1990;337:233–236.
- 9 Pusl T, Denk GU, Parhofer KG, Beuers U: Plasma separation and anion adsorption transiently relieve intractable pruritus in primary biliary cirrhosis. *J Hepatol* 2006;45:887–891.
- 10 Warren JE, Blaylock RC, Silver RM: Plasmapheresis for the treatment of intrahepatic cholestasis of pregnancy refractory to medical treatment. *Am J Obstet Gynecol* 2005;192:2088–2089.
- 11 Murray KF, Carithers RL Jr: AASLD practice guidelines: evaluation of the patient for liver transplantation. *Hematology* 2005;41:1407–1432.
- 12 Lewis JH: Drug-induced liver disease. *Med Clin North Am* 2000;84:1275–1311.
- 13 Padda MS, Sanchez M, Akhtar AJ, Boyer JL: Drug induced cholestasis. *Hepatology* 2011;53:1377–1387.
- 14 Bellmann R, Feistritz C, Zoller H, Graziadei IW, Schwaighofer H, Propst A, Wiedermann CJ, Joannidis M: Treatment of intractable pruritus in drug induced cholestasis with albumin dialysis: a report of two cases. *ASAIO J* 2004;50:387–391.
- 15 Anand JS, Chodorowski Z, Hajduk A, Waldman W: Cholestasis induced by parabolan successfully treated with the molecular adsorbent recirculating system. *ASAIO J* 2006;52:117–118.



**Fig. 1.** Focal areas of periportal confluent necrosis with focal disruption of the limiting plate by inflammation, ductular reaction, and fibrosis. Magnification  $\times 20$ .



**Fig. 2.** The hepatocytes showed predominant microvesicular steatosis with many pale pink Mallory-Denk bodies (red arrowheads). There is also marked intrahepatic and intracanalicular cholestasis (black arrowheads). Magnification  $\times 200$ .