


ORIGINAL ARTICLE

Additional value of advanced ultrasonography in pregnancies with two inconclusive cell-free DNA draws

Francesca Bardi¹  | Bo B. Bet^{2,3} | Eva Pajkrt^{2,3} | Ingeborg H. Linskens^{3,4} | Mireille N. Bekker⁵ | Erik A. Sistermans⁶  | Caterina M. Bilardo^{1,2,3} | Ayten Elvan-Taşpınar¹

¹Department of Obstetrics and Gynecology, University Medical Center Groningen, University of Groningen, Groningen, The Netherlands

²Department of Obstetrics and Gynaecology, Amsterdam UMC Location University of Amsterdam, Amsterdam, The Netherlands

³Amsterdam Reproduction and Development, Amsterdam, The Netherlands

⁴Department of Obstetrics and Gynaecology, Amsterdam UMC Location Vrije Universiteit Amsterdam, Amsterdam, The Netherlands

⁵Department of Obstetrics and Gynecology, University Medical Center Utrecht, Utrecht, The Netherlands

⁶Department of Human Genetics and Amsterdam Reproduction & Development Research Institute, Amsterdam UMC Location Vrije Universiteit Amsterdam, Amsterdam, The Netherlands

Correspondence

Francesca Bardi, Fetal Medicine Unit, Department of Obstetrics & Gynecology, University Medical Center Groningen (UMCG), Hanzeplein 1, Groningen 9700 RB, The Netherlands.

Email: f.bardi@umcg.nl

Abstract

Objective: We aimed to evaluate the additional value of advanced fetal anatomical assessment by ultrasound in pregnancies with twice inconclusive noninvasive testing (NIPT) due to low fetal fraction (FF).

Methods: We performed a multicenter-retrospective study between 2017 and 2020 including 311 pregnancies with twice inconclusive NIPT due to low $FF \leq 1\%$. Women were offered invasive testing and advanced fetal anatomical assessment at ≤ 18 weeks' gestation. Ultrasound findings, genetic testing, and pregnancy/postnatal outcomes were evaluated.

Results: Ninety-two/311 (29.6%) women underwent invasive testing. Structural anomalies were diagnosed in 13/311 (4.2%) pregnancies (nine at the first scan and four at follow-up). In 6/13 (46.2%) cases, genetic aberrations were confirmed (one case of Trisomy 13 (detectable by NIPT), two of Triploidy, one of 16q12-deletion, HCN4-mutation and UPD(16) (nondetectable by NIPT). Genetic aberrations were found in 4/298 (1.3%) structurally normal pregnancies (one 47XYY, two microscopic aberrations, one monogenic disorder found postpartum). Structural anomalies in genetically normal fetuses (2.0%) were not more prevalent compared to the general pregnant population (OR 1.0 [0.4–2.2]).

Conclusion: In pregnancies with twice inconclusive NIPT due to low FF, fetal structural anomalies are not more prevalent than in the general obstetric population. The detailed anatomical assessment has the added value to detect phenotypical features suggestive of chromosomal/genetic aberrations and identify pregnancies where advanced genetic testing may be indicated.

Francesca Bardi and Bo B. Bet should be considered joint first author.

This is an open access article under the terms of the Creative Commons Attribution-NonCommercial License, which permits use, distribution and reproduction in any medium, provided the original work is properly cited and is not used for commercial purposes.

© 2022 The Authors. Prenatal Diagnosis published by John Wiley & Sons Ltd.

Key points**What's already known about this topic?**

- Inconclusive cell-free DNA (cfDNA) results due to low fetal fraction (FF) are obtained in about 1%–8% of blood draws and can be due to maternal, fetal, or placental causes. Fetal aneuploidy is associated with low FF.

What does this study add?

- The prevalence of structural anomalies in pregnancies with twice inconclusive cfDNA due to low FF is not increased compared to the general obstetric population. Detailed ultrasonography may help in identifying pregnancies where advanced invasive testing is indicated.

1 | INTRODUCTION

The implementation of noninvasive prenatal testing (NIPT) by cell-free DNA (cfDNA) has revolutionized the way prenatal aneuploidy screening is performed. Initially, it was exclusively offered to women with a high risk at the combined test (CT) to screen for Trisomy 21, 18, and 13, given its high sensitivity and low false-positive rate.¹ However, nowadays, in the Netherlands, all pregnant women can choose for NIPT and can opt for a test aimed at the analysis of the common trisomies only or for a genome-wide test reporting also other autosomal chromosomal aberrations.^{2,3} Until recently, women were given a choice between the CT and NIPT as a first tier test. However, given the extremely low uptake of this test, the CT is not offered anymore since October 2021.³ Cell-free DNA performance relies, among others, upon the FF, which is expressed as the percentage of cytotrophoblastic cfDNA, originating from apoptotic chorionic villous cells, compared to maternal cfDNA.⁴ Some laboratories use a minimum amount of FF to generate a reliable result and to minimize the number of false-negative cases. Based on early studies, a minimum FF threshold of 4% was often chosen, but for many methods, reliable results can be obtained at much lower FF.^{5–8} If FF falls below a certain percentage, the test is considered as unreliable by some laboratories and generates a “failed,” “inconclusive,” or “nonreportable” result. Whether or not tests should fail based on low FF alone is under much debate as the FF measurement has a large variability.⁹ Furthermore, when whole-genome sequencing (WGS)-based methods are used, the reliability does not depend on FF alone, but also on the amount of data (read number) generated. In the literature, the proportion of inconclusive results ranges between 1% and 8%, depending, among others, on the laboratory technology used and the gestational age at blood draw.^{7,10,11} Because of the variability in the FF measurement, and as FF increases slightly with gestational age, a subsequent second draw is able to provide a conclusive result in about two-thirds of the cases.^{7,12,13} However, since low FF is also associated with other maternal and fetoplacental factors, the repeated test fails a second time in approximately 0.6% of total draws.⁷ Maternal factors associated with low FF include in vitro fertilization (IVF) conception, ethnicity, high body mass index (BMI), maternal autoimmune diseases, and malignancy, while fetoplacental factors include multiple gestations, placental insufficiency,

and (mosaic) aneuploidies, such as Trisomy 18, 13, and Triploidy.^{14–17} Women are offered invasive testing following a twice inconclusive cfDNA result because of the reported increased risk of aneuploidies of about 4%–6%.^{17,18} However, given the small risk of procedure-induced miscarriage, some parents decline the test.¹⁹ For this reason, in alternative or complementarily to invasive testing, an early detailed assessment of the fetal anatomy may be offered as well. The objective of the study was to identify the added value of this scan offered before second-trimester anatomical screening and next to invasive testing in pregnancies with twice inconclusive NIPT results.

2 | METHODS**2.1 | Prenatal screening in the Netherlands**

Prenatal screening was implemented in the Netherlands in 2007. At the time, the screening offer included the CT at 11–14 weeks of gestation and second-trimester anatomical screening at 18–22 weeks. In 2014, NIPT by cfDNA was introduced by the TRIDENT-1 study to screen for Trisomy 21, 18, and 13 for women with a high risk at the CT.²⁰ In 2017 the cfDNA offer was universally extended to all pregnant women from 11 weeks of gestation by the TRIDENT-2 study.⁷ Since then, parents can opt for either screening for Trisomy 21, 18, and 13 or for a genome-wide test, which also includes chromosomal aberrations with a size resolution of 10–20 Mb. None of the two panels include screening for sex-chromosomal aberrations. First-trimester anatomical screening by ultrasound has been introduced in the Netherlands in September 2021 and was therefore not routinely offered to women at the time of this study.

2.2 | Study design

In this multicenter retrospective cohort study, we collected data from three academic centers in The Netherlands (University Medical Center Groningen, Amsterdam University Medical Center—locations VUmc and AMC—and University Medical Center Utrecht) on all singleton pregnancies in which cfDNA was, for two consecutive blood draws, unable to provide a valid test result between April 2017 and

April 2020. In line with the national guidelines, all women who received a first inconclusive cfDNA test were offered to repeat the test. Only cases in which the second draw provided, once again, an inconclusive result was included in the study. According to the national protocol, all women were referred to a fetal medicine unit for invasive testing. In our cohort, the advanced fetal anatomical assessment by ultrasound was offered as well, next to invasive testing. Cutoffs for low FF were determined by validation experiments. For the second blood draw, the same cutoff of for low FF was applied.

2.3 | Exclusion criteria

All women in our cohort were enrolled in the TRIDENT-2 study; therefore, the same exclusion criteria were applied.⁷ For this study, we further excluded all cases of twice inconclusive cfDNA results due to reasons other than low FF. Additionally, all cases for which the cfDNA analysis had been performed in clinical laboratories that were not located in the Netherlands were excluded as well. Finally, we excluded cases in which the advanced fetal anatomical assessment was performed in concomitance to second trimester anatomical screening, starting from 18 weeks of gestation.

2.4 | Laboratory testing

All cfDNA sample analyses were performed at the clinical genetic laboratory of the Amsterdam University Medical Center, location VUmc according to the previously described protocol.⁷ Between April 2017 and June 2018, the Illumina HiSeq4000 sequencer was used for genome-wide shallow sequencing and DEFrag was used to measure FF in male fetuses. A blood redraw was requested when FF was lower than 4% or when DEFrag indicated a "bad cluster".²¹ From June 2018, the Illumina Veriseq system was used with a FF cutoff for all pregnancies of $\leq 1\%$ as reported by the Veriseq software used (Veriseq version 1, Illumina). Bioinformatic analysis for aneuploidies was performed using the WISECONDOR (v2.0.1) algorithm under standard settings for aneuploidy and other unbalanced chromosomal aberrations.²² Between June 2018 and the end of the study, we used the Illumina Veriseq system that comes with a FF prediction program, but we used WISECONDOR for aneuploidy calling.

2.5 | Anatomical assessment and invasive testing

Advanced fetal anatomical assessment was performed at the referral centers as soon as possible and before 18 completed weeks of gestation. A systematic scanning protocol was used to evaluate fetal anatomy (Supplementary Material S1). Time allocated to the scan was 60 min. The advanced anatomical assessment was performed by transabdominal ultrasound, and when indicated, transvaginally. All scans were performed by fetal medicine specialists. Next to the fetal anatomical assessment, women were offered invasive testing

according to the national protocol. Genetic testing included quantitative fluorescent- polymerase chain reaction (QF-PCR) in cases, and if indicated, Array-CGH. Whole-exome sequencing (WES) was only offered in case of structural anomalies seen on ultrasound or post-natal pathology. Women who declined invasive testing were still eligible for advanced anatomical assessment by ultrasound.

2.6 | Data collection

All data for this study were collected and stored at the participating centers in clinical software (Astraia GmbH Munchen, Mosos BMA, electronic patient dossiers). Datasets from the individual centers were then exported into a research database built in REDcap software (Research Electronic Data Capture) using predefined queries.

2.7 | Study outcomes

The following maternal demographic characteristics were recorded: age, ethnicity, BMI, medical and obstetric history, maternal medication use, and type of conception. Additionally, we documented gestational age at both times of blood draw and at advanced ultrasound, ultrasound findings at advanced ultrasound, maternal complications during pregnancy or delivery, results of genetic testing, pregnancy outcome, and neonatal follow-up. Pregnancy outcome (including presence of structural anomalies after delivery) was obtained for all cases and neonatal follow-up was available for the cases with ultrasound abnormalities. To compare maternal BMI in our cohort to that of the general obstetric population opting for cfDNA testing, we extrapolated mean BMI from the TRIDENT-2 national database including data on all NIPT tests performed in the Netherlands.³ We used the European registration of congenital anomalies (EUROCAT) database as a historical comparison for the prevalence of structural anomalies in the general population.²³

2.8 | Ultrasound abnormalities

All ultrasound abnormalities were recorded. We defined as multiple congenital anomaly (MCA) abnormalities in which at least two distinct organ systems were affected. Additionally, we recorded the following ultrasound findings as soft markers: absent/hypoplastic nasal bone, tricuspid regurgitation, renal pyelectasis ≥ 10 mm, short femur $< p5$, single umbilical artery (SUA), and fetal echogenic bowel.

2.9 | Statistical analysis

Maternal weight, height, and gestational age at assessment were provided as continuous variables. Weight and height were used to calculate the maternal BMI. All other data were categorical. For descriptive statistical analysis, parameters were summarized as

means (and SD or 95% CI) for parameters with normal distributions; as median (and IQR) for parameters with skewed distributions; and as *n* (%) for categorical parameters. Baseline characteristics between groups were compared using independent sample *t*-test or chi-square test, depending on type of variable being continuous or dichotomous. Descriptive statistical analyses were performed using SPSS version 27 (IBM-Corporation).

2.10 | Ethical consideration

The study was formally approved by the local Medical Ethical Committee of the University Medical Center of Groningen (ID 2021.00551) and Amsterdam University Medical Center (ID 2021.0721).

3 | RESULTS

3.1 | Baseline characteristics

In total, 332 pregnant women were referred to our fetal medicine units. Six cases (1.8%), in which the inconclusive results were due

to laboratory technical issues, were excluded. Additionally, another 3 (0.9%) cases were excluded because the cfDNA analysis had not been performed in a clinical laboratory in the Netherlands. Finally, 12 (3.6%) cases were excluded because advanced ultrasonography was not performed. After application of the exclusion criteria, a total of 311 cases were available for analysis. Baseline characteristics of the included cases are presented in Table 1.

The maternal BMI in our cohort (28.8 ± 6.0 kg/m²) was significantly higher than that of the general Dutch pregnant population choosing for NIPT (23.8 ± 4.2 kg/m²) ($p \leq 0.001$).

3.2 | cfDNA testing and additional tests

The first cfDNA draw was performed at a mean gestational age of 12.0 (± 0.8) weeks and the second draw at 13.9 (± 1.1) weeks. Time between the two cfDNA draws ranged from 5 to 32 days with a mean of 2.0 weeks (± 0.8) (Table 2). After the second inconclusive cfDNA result, 33.4% ($n = 104$) of parents opted for additional investigations: a third draw cfDNA in two cases, the CT in 10 cases with gestational age <14 weeks and in 92 for invasive testing. Of these, QF-PCR alone was performed in 20 cases, QF-PCR in combination with array-CGH

TABLE 1 Baseline characteristics of included cases

Demographic characteristics	
Age (years) mean \pm SD	32.0 \pm 4.1
BMI (kg/m ²), mean \pm SD (missing = 7)	28.8 \pm 6.3
Obesity—BMI > 30, <i>n</i> % (missing = 7)	121 (38.9)
Auto-immune disorders (<i>n</i> , %)	7 (2.2)
Maternal cancer (<i>n</i> , %)	1 (0.3)
Use of medication (<i>n</i> , %)	25 (8.0)
Thyroid hormone replacement	8 (2.6)
Anticoagulation therapy	4 (1.3)
Antihypertensive medication	3 (1.0)
Obstetrics characteristics (<i>n</i> , %)	
Nulliparous (<i>n</i> , %)	191 (61.4)
Conception (<i>n</i> , %) (missing = 14)	
Spontaneous	276 (92.6)
Ovulation induction	5 (1.7)
Intrauterine insemination	6 (2.0)
IVF, ICSI	10 (3.4)
Previous miscarriage	72 (23.2)
History of congenital anomalies	9 (2.9)
History of pregnancy complications	14 (4.5)
Pre-eclampsia or HELPP	7 (2.2)
Other (FGR, gestational diabetes, and preterm birth)	7 (2.2)

Abbreviations: BMI, body mass index; FGR, fetal growth restriction, ICSI, intracytoplasmic sperm injection.

TABLE 2 Characteristics of the first and second blood draws of cell-free DNA (cfDNA) testing

cfDNA characteristics (mean \pm SD)	
Gestational age—first draw (weeks) (missing 17)	12.0 \pm 0.8
Gestational age—second draw (weeks) (missing 18)	13.9 \pm 1.1
Time between draws (weeks)	2.0 \pm 0.7

TABLE 3 Additional investigations performed after two inconclusive cell-free DNA (cfDNA) results

Noninvasive tests (n, %)	
Third draw cfDNA	2 (0.6)
Combined test	10 (3.2)
Invasive tests	
QF-PCR only	20 (6.4)
QF-PCR and array-CGH	67 (21.5)
QF-PCR array-CGH and WES	5 (1.6)
Total	92 (29.6)

Abbreviation: WES, Whole-exome sequencing.

in 67, and in combination with whole-exome sequencing (WES) in five cases with ultrasound anomalies (Table 3).

All women underwent a detailed scan at a gestational age ranging between 13 and 18 weeks with a mean of 16.2 (\pm 1.5) weeks. The time between the second cfDNA draw and the ultrasound examination ranged from 0 to 46 days with a mean of 2.2 (\pm 1.0) weeks.

3.3 | Ultrasound anomalies at the advanced fetal anatomical assessment

At the advanced fetal anatomical assessment, 293 (94.2%) pregnancies had a normal scan. In the remaining 18 (5.8%) cases, 9 (2.9%) structural anomalies were diagnosed and in 9 (2.9%) cases, soft markers were observed. Among the nine cases with structural anomalies, one case of Trisomy 13 with cystic hygroma resulted in fetal demise and in the eight remaining cases, structural anomalies were confirmed at follow-up ultrasound. Two cardiac defects were diagnosed, one was a complex heart defect in a fetus where a microarray analysis revealed a 16q12-deletion and the other was a ventricular septal defect (VSD) not confirmed after birth. Additionally, one case with VACTERL and one case of severe fetal growth restriction (FGR) and SUA in a fetus subsequently diagnosed with Triploidy were found. The remaining four ultrasound anomalies consisted of a case of polydactyly, club foot, renal agenesis, and cerebral cyst. There were no genetic diagnoses in these cases (Table 4).

Among the nine cases with soft markers (echogenic bowel; $n = 1$, hypoplastic nasal bone; $n = 1$, SUA; $n = 1$, multiple markers; $n = 6$, see Table 4), six performed invasive testing, all with normal results. Four cases had a normal follow-up scan and an uneventful pregnancy outcome. In the remaining five, the soft markers were confirmed at

follow-up ultrasound. The pregnancy was uneventful in all five, but in one neonate, medium-chain acyl-CoA dehydrogenase deficiency (MCADD) was detected at neonatal screening (Table 4).

3.4 | Ultrasound anomalies at follow-up scan

In the group with an initial normal advanced fetal anatomical assessment, six structural anomalies were diagnosed at second-trimester anatomical screening. Of these six cases, in two a chromosomal anomaly (Triploidy, UPD16) was found and in one a single-gene disorder (HCN4-mutation). In one fetus, a sinus thrombosis was diagnosed at follow-up scan. In the last two of these six cases, the suspicion of isolated VSD was not confirmed after birth and two healthy children were born (Figure 1, Table 4).

In total, next to the two VSD cases with normal outcomes, 13 (4.2%) structural anomalies were confirmed in the population, of which 69% (9/13) at the early fetal anatomical assessment and 31% (4/13) at follow-up ultrasound.

The baseline risk of structural anomalies (excluding genetic anomalies) in the EUROCAT database over 2010–2019 was 2.02%; compared to the 2.0% (6/301, excluding 10 with genetic anomalies) found in our cohort, this resulted in an odds ratio of 1.0 [0.4–2.2], $p = 0.974$.

3.5 | Genetic aberrations

The overall incidence of genetic aberrations in the cohort was 3.2% ($n = 10$). These included four (1.3%) cases of numeric chromosomal abnormalities: Triploidy ($n = 2$), Trisomy 13 ($n = 1$), and 47, XYY ($n = 1$), of which only the cases with Trisomy 13 could have theoretically been detected by a successful cfDNA testing. The remaining six genetic anomalies were one case of UPD (16) (0.3%), three cases (1%) of microscopic aberrations diagnosed by array-CGH, and two (0.6%) cases of single-gene disorders diagnosed by WES.

Genetic anomalies were diagnosed in six of the 13 (46%) fetuses with structural anomalies and in four of the 298 (1.3%) without structural anomalies. These four cases with genetic diagnosis and normal ultrasound were: two microscopic aberrations diagnosed by array-CGH (del 16q23.1 (AdamTS18), del Xp22.2 (MID1)), one case of 47,XYY, and one single-gene disorder diagnosed postpartum at neonatal screening (MCADD) (Tables 4 and 5, Figure 1).

3.6 | Subgroup analysis

Mean maternal BMI in the group with structural or genetic anomalies (25.5 ± 3.8 kg/m²) was significantly lower than in the group without (28.8 ± 6.3 kg/m², $p = 0.033$). In women with maternal risk factors (autoimmune disease, cancer, and medication use during pregnancy), anomalies occurred in 3.2% (1/31) of the cases. In the group without maternal risk factors, the rate of anomalies was 5.9% (165/280). Due

TABLE 4 Ultrasound anomalies in the study population and pregnancy outcome

Case	First advanced ultrasonography	Follow-up ultrasonography	Postnatal outcome
Structural anomalies			
1	CHD (VSD)	Isolated VSD	LB, PTB 36 + 1, healthy
2	CHD (TGA, VSD, DORV)	Complex CHD	TOP 20 + 5, complex CHD, 16q12-deletion of 1.7mb
3	MCA (FGR, SUA)	Severe FGR, SUA	IUFD 20 + 4, triploidy
4	MCA (CHD, clubfeet, echogenic bowel, megacystis, pyelectasis, SUA)	VACTERL	TOP 16 + 0, VACTERL
5	Polydactyly	Polydactyly, macrosomia, polyhydramnios	LB, polydactyly
6	Clubfoot unilateral	Clubfoot unilateral	LB, clubfoot unilateral
7	Midline brain cyst	Ventriculomegaly, corpus callosum agenesis	TOP 23 + 2, anomalies confirmed
8	Unilateral renal agenesis, ambiguous genitalia	Unilateral renal agenesis, ambiguous genitalia	LB, unilateral renal agenesis, phenotypic female, genotypic male
9	Cystic hygroma	-	Fetal demise 17 + 2, trisomy 13
10	No anomalies	AVSD, sinus bradycardia	LB, AVSD, HCN4-mutation
11	No anomalies	Dural sinus malformation, sinus thrombosis	TOP 23 + 4
12	No anomalies	Hypoplastic aortic arch, VSD, FGR	LB, postnatal diagnosis of UPD 16
13	No anomalies	MCA (FGR, oligohydramnios, oral cleft, rocker-bottom feet, VSD)	TOP 20 + 0, triploidy
14	No anomalies	Isolated VSD	LB, healthy
15	No anomalies	Outlet VSD	LB, healthy
Soft markers			
1	Hypoplastic nasal bone, CPC, echogenic heart focus	No anomalies	LB, healthy
2	Hypoplastic nasal bone, echogenic bowel	No anomalies	LB, healthy
3	Hypoplastic nasal bone	No anomalies	LB, healthy
4	Short femur length, tricuspid regurgitation	No anomalies	LB, healthy
5	CPC, echogenic bowel	Echogenic bowel	LB, healthy
6	Echogenic bowel	Echogenic bowel	LB, postnatal diagnosis of MCADD (ACADM-gene)
7	Echogenic bowel, short femur length	Short femur length	LB, healthy
8	Hypoplastic nasal bone, SUA	SUA	LB, healthy
9	SUA	CPC, SUA	LB, healthy

Abbreviations: AVSD, atrial ventricular septal defect; CHD, congenital heart defect; CPC, choroid plexus cyst; DORV, double outlet right ventricle; FGR, fetal growth restriction; IUFD, intrauterine fetal death; LB, life birth; MCA, multiple congenital anomalies; MCADD, medium-chain acyl-CoA dehydrogenase deficiency; PTB, preterm birth; SUA, single umbilical artery; TGA, transposition of great arteries; TOP, termination of pregnancy; UPD, uniparental disomy; VSD, ventricular septal defect.

to the low sample size, the two groups were not statistically comparable.

4 | DISCUSSION

This study shows that structural anomalies were found in 4.2% of pregnancies with twice inconclusive cfDNA due to low FF and that 69% of these anomalies could already be detected before routine

second trimester anatomical screening by advanced ultrasonography. The occurrence of isolated structural anomalies in genetically normal fetuses in 2% of pregnancies is not increased compared to the general obstetric population (OR 1.0). As expected, a strong association is observed between structural anomalies and genetic aberrations, found in 46% of structurally abnormal fetuses. Our results confirm the fact that, also in this cohort of women with twice inconclusive cfDNA screening, fetal anomalies are associated with fetal aneuploidies and other genetic imbalances.²⁴

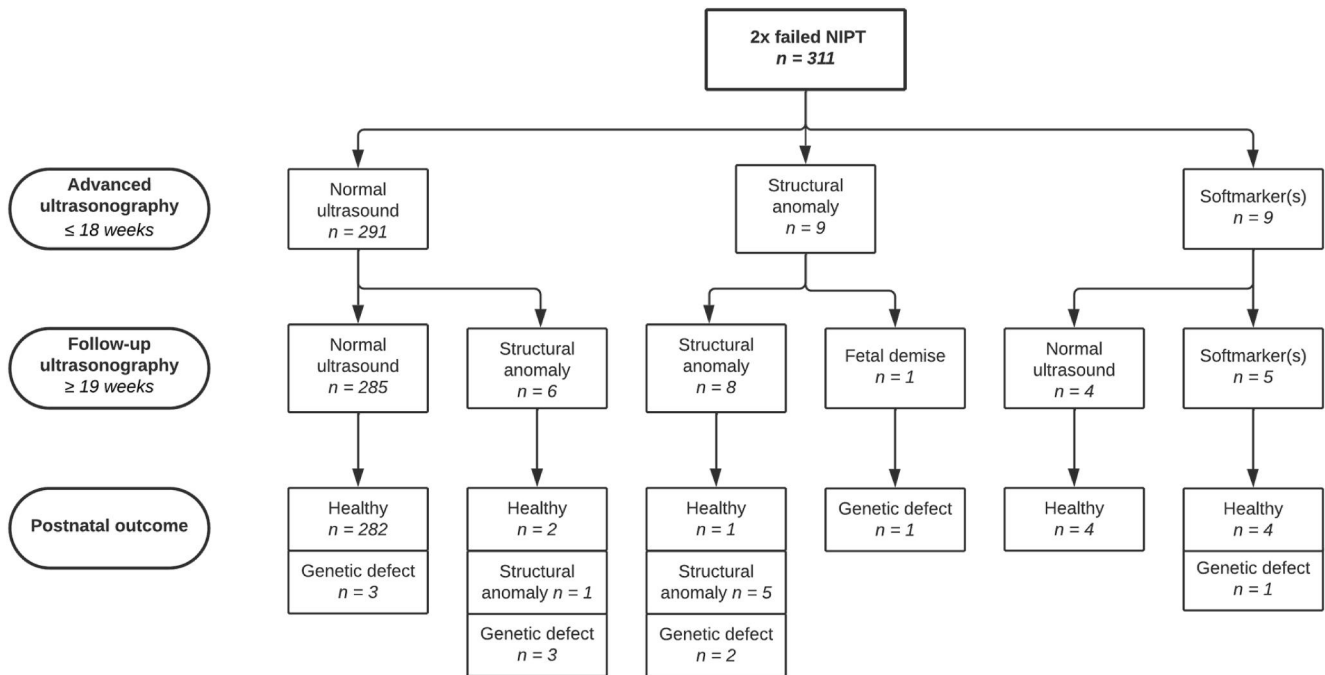


FIGURE 1 Flowchart patient population

TABLE 5 Genetic aberrations in fetuses with normal findings at first advanced ultrasonography and no structural anomaly at follow-up

Genetic aberration	Outcome
Del 16q23.1 (AdamTS18, 499 kb)	Live birth
Del Xp22.2 (MID1, 258 kb)	Live birth
47, XYY	TOP, 19 + 2

Of the six genetic aberrations diagnosed in structurally abnormal fetuses, half were aneuploidies and the others were one case of UPD (16), one chromosomal microscopic aberration (CMA), and one single-gene disorder. In pregnancies with no ultrasound anomalies that underwent an invasive procedure, four genetic aberrations were diagnosed. These included one case of 47XYY and two chromosomal microscopic aberrations diagnosed prenatally, and one single-gene disorder diagnosed at neonatal screening. The structural anomalies detected in our cohort were heterogeneous. We mainly observed cardiac defects and MCA but also unilateral renal agenesis with ambiguous genitalia ($n = 1$), clubfoot ($n = 1$), and polydactyly ($n = 1$). Besides structural anomalies, also soft markers were detected in 2.9% of the pregnancies with twice failed cfDNA. However, except for the case of MCADD diagnosed after birth in fetus with echogenic bowel, all other soft markers were not confirmed at later scans and/or had an uneventful pregnancy outcome, confirming previous studies.^{25,26} The relevance of soft markers detected before the mid-trimester scan needs still to be elucidated.^{27,28}

In our management protocol of twice inconclusive NIPT results, invasive testing is routinely offered, but, as shown in this study, in

practice, only few women (29.6%) (92/311) accept this offer. In case of structural anomalies suggestive of trisomies or of other genetic disorders observed at an advanced fetal examination, the motivation to undergo an invasive procedure seems to become stronger.

4.1 | Interpretation

4.1.1 | Low fetal fraction and maternal characteristics

Inconclusive cfDNA results due to low FF have been reported in 1%–8% of pregnancies, depending on assay technology and laboratory policies.^{7,10,11} Among factors able to affect circulating FF, high maternal BMI is a well-recognized one. The inverse relationship between BMI and FF is firmly established and may explain a proportion of the inconclusive cfDNA results at first/second draws.^{6,29,30} The rationale is that the increased circulating volume in obese mothers, together with the increased ratio between maternal and fetal DNA due to a higher proportion of apoptotic maternal adipose cells, contributes to a lower measurable FF.²⁹ Indeed, mean maternal BMI in our population ($28.8 \pm 6.0 \text{ kg/m}^2$) was higher than the 23.8 kg/m^2 ($\pm 4.2 \text{ kg/m}^2$) of the Dutch pregnant population choosing for NIPT (TRIDENT-2). Although high maternal BMI is also known to be associated with an increased risk of fetal anomalies, in this cohort, mean BMI was significantly higher in the group without fetal anomalies, suggesting that it could have been an explanation for the failed cfDNA result.^{31,32} Furthermore, maternal autoimmune and oncological diseases, as well as medication use, have been reported to

influence FF by affecting the quantity or the quality of the circulating maternal DNA fragments.³³ In our study, 8 (2.5%) mothers suffered from autoimmune disorders ($n = 7$) or cancer ($n = 1$) and all but one (case with dural sinus malformation) had a normal ultrasound. Moreover, also all mothers using medications during pregnancy ($n = 25$, 8%) had a good pregnancy outcome. Notably, medications used in our cohort were mostly antihypertensive medications and thyroid hormone supplement, both not directly linked to lower FF.³³ Due to the low sample size, we could not statistically test this association.

4.1.2 | Low fetal fraction and fetal anomalies

Pregnancies with inconclusive cfDNA results have been associated with fetal aneuploidies, especially Trisomy 13, 18, and Triploidy.^{5,15,34,35} There is general consensus that the low FF is the result of the commonly smaller and dysfunctional placentae in these pregnancies.¹² Indeed, FF derives from apoptotic trophoblastic cells in the chorionic villi and not from the developing fetus.⁵ This is further reinforced by recent studies reporting the association between low FF and abnormal placentation, associated with FGR and pregnancy complications, and suggesting that low PAPP-A levels could be regarded as a proxy for low FF.^{35–37} In our study, the rate of aneuploidies was 1.3%, which is slightly higher than the 0.8% described in the general population, but lower than the rates reported by other authors (2%–7%).^{5,11,38} Interestingly though, next to the more common aberrations (Triploidy, Trisomy 13), we detected one case of UPD (16) (0.3%), three cases of CMA (1%) and two cases of single-gene disorders (0.7%). While for the case with UPD (16), FGR might reflect a lower placental mass and therefore explain the lower circulating FF, the etiological origin of the inconclusive cfDNA results in the other pregnancies remains unclear. To our knowledge, no studies have described the prevalence of sub-microscopic aberrations and single-gene disorders in pregnancies with low FF. Interestingly, an increased prevalence of genetic aberrations in pregnancy with low first trimester PAPP-A has been reported.^{35–37} Again, an abnormally developed placenta seems to be the common denominator of both low PAPP-A levels and low FF.³⁹ Notably, among all genetic anomalies diagnosed in this study, only one case of Trisomy 13 (with structural anomalies) could have been detected by NIPT. Five could be suspected based on ultrasound anomalies, but the remaining four (one associated with isolated echogenic bowel and three cases without ultrasound findings) could have not been diagnosed without invasive testing. This underscores the complementary role of invasive testing and ultrasonography, which contribute to the maximization of prenatal detection rates of fetal anomalies when used together. However, it is also clear that ultrasonography cannot replace invasive testing.

Isolated structural anomalies (without underlying genetic aberrations) were diagnosed in 2% of fetuses in our cohort, which are

substantially similar to the prevalence (2.02%) in the general obstetric population.²³ A higher rate (4.1%) was reported by a recent study on the relationship between low FF and pregnancy complications in euploid male fetuses.³⁵ However, the authors did not report on CMA or single-gene disorders, which may have been present in fetuses with ultrasound anomalies and normal karyotype. After the introduction in the Netherlands, since September 2021, of a routine first trimester anatomical assessment, next to cfDNA, it will be interesting to see the impact on the diagnosis of both structural and genetic anomalies of this new policy.

5 | CONCLUSION

In pregnancies with twice inconclusive cfDNA due to low FF, the prevalence of structural anomalies is not increased compared to the general obstetric population. Nevertheless, the detailed anatomical assessment has the added value to detect stigmata suggestive of chromosomal and genetic aberrations and use fetal phenotype to identify pregnancies where advanced genetic testing may be indicated.

ACKNOWLEDGMENT

This study received no specific funding.

CONFLICT OF INTEREST

All authors declare that they have no conflict of interest.

DATA AVAILABILITY STATEMENT

The data that support the findings of this study are available on request from the corresponding author.

ORCID

Francesca Bardi  <https://orcid.org/0000-0001-5311-2207>

Erik A. Siermans  <https://orcid.org/0000-0001-7187-4563>

REFERENCES

1. Gil MM, Accurti V, Santacruz B, Plana MN, Nicolaides KH. Analysis of cell-free DNA in maternal blood in screening for aneuploidies.pdf. *Ultrasound Obstet Gynecol*. 2017;50(3):302–314. <https://doi.org/10.1002/uog.17484>
2. Jani JC, Gil MM, Benachi A, et al. Genome-wide cfDNA testing of maternal blood. *Ultrasound Obstet Gynecol*. 2020;55(1):13–14. <https://doi.org/10.1002/uog.21945>
3. van der Meij KRM, de Groot-van Mooren M, Carbo EWS, et al. Uptake of fetal aneuploidy screening after the introduction of the non-invasive prenatal test: a national population-based register study. *Acta Obstet Gynecol Scand*. 2021;0–2. <https://doi.org/10.1111/aogs.14091>
4. Faas BH, De Ligt J, Janssen I, et al. Non-invasive prenatal diagnosis of fetal aneuploidies using massively parallel sequencing-by-ligation and evidence that cell-free fetal DNA in the maternal plasma originates from cytotrophoblastic cells. *Expet Opin Biol Ther*. 2012; 12(Suppl 1):S19–S26. <https://doi.org/10.1517/14712598.2012.670632>

5. Hui L, Bianchi DW. Fetal fraction and noninvasive prenatal testing: what clinicians need to know. *Prenat Diagn.* 2020;40(2):155-163. <https://doi.org/10.1002/pd.5620>
6. Scott FP, Menezes M, Palma-Dias R, et al. Factors affecting cell-free DNA fetal fraction and the consequences for test accuracy. *J Matern Neonatal Med.* 2018;31(14):1865-1872. <https://doi.org/10.1080/14767058.2017.1330881>
7. van der Meij KRM, Sistermans EA, Macville MVE, et al. TRIDENT-2: national implementation of genome-wide non-invasive prenatal testing as a first-tier screening test in The Netherlands. *Am J Hum Genet.* 2019;105(6):1091-1101. <https://doi.org/10.1016/j.ajhg.2019.10.005>
8. Luo Y, Hu H, Jiang L, et al. A retrospective analysis the clinic data and follow-up of non-invasive prenatal test in detection of fetal chromosomal aneuploidy in more than 40, 000 cases in a single prenatal diagnosis center. *Eur J Med Genet.* 2020;63(9):104001. <https://doi.org/10.1016/j.ejmg.2020.104001>
9. Persson F, Prensky L. Variability of "reported fetal fraction" in noninvasive prenatal screening (NIPS). *Clin Chem.* 2021;67:863-866. <https://doi.org/10.1093/clinchem/hvab014>
10. Gil MM, Quezada MS, Revello R, Akolekar R, Nicolaides KH. Analysis of cell-free DNA in maternal blood in screening for fetal aneuploidies: updated meta-analysis. *Ultrasound Obstet Gynecol.* 2015;45(3):249-266. <https://doi.org/10.1002/uog.14791>
11. Yaron Y. The implications of non-invasive prenatal testing failures: a review of an under-discussed phenomenon. *Prenat Diagn.* 2016;36(5):391-396. <https://doi.org/10.1002/pd.4804>
12. Revello R, Sarno L, Ispas A, Akolekar R, Nicolaides KH. Screening for trisomies by cell-free DNA testing of maternal blood: consequences of a failed result. *Ultrasound Obstet Gynecol.* 2016;47(6):698-704. <https://doi.org/10.1002/uog.15851>
13. Hestand MS, Bessem M, van Rijn P, et al. Fetal fraction evaluation in non-invasive prenatal screening (NIPS). *Eur J Hum Genet.* 2019;27(2):198-202. <https://doi.org/10.1038/s41431-018-0271-7>
14. Galeva S, Gil MM, Konstantinidou L, Akolekar R, Nicolaides KH. First-trimester screening for trisomies by cfDNA testing of maternal blood in singleton and twin pregnancies: factors affecting test failure. *Ultrasound Obstet Gynecol.* 2019;53:804-809. <https://doi.org/10.1002/uog.20290>
15. Suzumori N, Sekizawa A, Takeda E, et al. Classification of factors involved in nonreportable results of noninvasive prenatal testing (NIPT) and prediction of success rate of second NIPT. *Prenat Diagn.* 2019;39(2):100-106. <https://doi.org/10.1002/pd.5408>
16. Benn P, Valenti E, Shah S, Martin K, Demko Z. Factors associated with informative redraw after an initial no result in noninvasive prenatal testing. *Obstet Gynecol.* 2018;132(2):428-435. <https://doi.org/10.1097/aog.0000000000002728>
17. Norton ME, Jacobsson B, Swamy GK, et al. Cell-free DNA analysis for noninvasive examination of Trisomy. *N Engl J Med.* 2015;372(17):1589-1597. <https://doi.org/10.1056/nejmoa1407349>
18. Chan N, Smet ME, Sandow R, Silva Costa F, McLennan A. Implications of failure to achieve a result from prenatal maternal serum cell-free DNA testing: a historical cohort study. *BJOG An Int J Obstet Gynaecol.* 2018;125(7):848-855. <https://doi.org/10.1111/1471-0528.15006>
19. Gil MM, Molina FS, Rodríguez-Fernández M, et al. New approach for estimating risk of miscarriage after chorionic villus sampling. *Ultrasound Obstet Gynecol.* 2020;56(5):656-663. <https://doi.org/10.1002/uog.22041>
20. Oepkes D, Page-Christiaens GCL, Bax CJ, et al. Trial by Dutch laboratories for evaluation of non-invasive prenatal testing. Part I—clinical impact. *Prenat Diagn.* 2016;36(12):1083-1090. <https://doi.org/10.1002/pd.4945>
21. van Beek DM, Straver R, Weiss MM, et al. Comparing methods for fetal fraction determination and quality control of NIPT samples. *Prenat Diagn.* 2017;37(8):769-773. <https://doi.org/10.1002/pd.5079>
22. Straver R, Sistermans EA, Holstege H, Visser A, Oudejans CBM, MJT R. WISECONDOR: detection of fetal aberrations from shallow sequencing maternal plasma based on a within-sample comparison scheme. *Nucleic Acids Res.* 2014;42(5):e31. <https://doi.org/10.1093/nar/gkt992>
23. EUROCAT. Prevalence Charts and Tables [Internet]; 2022. https://eu-rd-platform.jrc.ec.europa.eu/eurocat/eurocat-data/prevalence_en
24. Bardi F, Bosschieter P, Verheij J, et al. Is there still a role for nuchal translucency measurement in the changing paradigm of first trimester screening? *Prenat Diagn.* 2020;40(2):197-205. <https://doi.org/10.1002/pd.5590>
25. Prentice G, Welsh A, Howat A, Ross D, Henry A. Isolated 'soft signs' of fetal choroid plexus cysts or echogenic intracardiac focus—consequences of their continued reporting. *Australas J Ultrasound Med.* 2019;22(4):253-264. <https://doi.org/10.1002/ajum.12180>
26. Whitlow BJ, Lazanakis ML, Kadir RA, Chatzipapas I, Economides DL. The significance of choroid plexus cysts, echogenic heart foci and renal pyelectasis in the first trimester. *Ultrasound Obstet Gynecol.* 1998;12(6):385-390. <https://doi.org/10.1046/j.1469-0705.1998.12.060385.x>
27. Kenkhuis MJA, Bakker M, Bardi F, et al. Effectiveness of 12–13-week scan for early diagnosis of fetal congenital anomalies in the cell-free DNA era. *Ultrasound Obstet Gynecol.* 2018;51(4):463-469. <https://doi.org/10.1002/uog.17487>
28. Bardi F, Smith E, Kuilman M, Snijders R, Bilardo C. Early detection of structural anomalies in a primary care setting in The Netherlands. *Fetal Diagn Ther.* 2018;46:1-8. <https://doi.org/10.1159/000490723>
29. Wang E, Batey A, Struble C, Musci T, Song K, Oliphant A. Gestational age and maternal weight effects on fetal cell-free DNA in maternal plasma. *Prenat Diagn.* 2013;33(7):662-666. <https://doi.org/10.1002/pd.4119>
30. Kruckow S, Schelde P, Hatt L, et al. Does maternal body mass index affect the quantity of circulating fetal cells available to use for cell-based noninvasive prenatal test in high-risk pregnancies? *Fetal Diagn Ther.* 2019;45(5):353-356. <https://doi.org/10.1159/000492028>
31. Persson M, Cnattingius S, Villamor E, et al. Risk of major congenital malformations in relation to maternal overweight and obesity severity: cohort study of 1.2 million singletons. *BMJ.* 2017;357:1-8. <https://doi.org/10.1136/bmj.j2563>
32. Stothard KJ, Tennant PWG, Bell R, Rankin J. Maternal overweight and obesity and the risk of congenital anomalies: a systematic review and meta-analysis. *JAMA, J Am Med Assoc.* 2009;301(6):636-650. <https://doi.org/10.1001/jama.2009.113>
33. Bianchi DW. Cherchez la femme: maternal incidental findings can explain discordant prenatal cell-free DNA sequencing results. *Genet Med.* 2018;20(9):910-917. <https://doi.org/10.1038/gim.2017.219>
34. Palomaki GE, Kloza EM, Lambert-Messerlian GM, et al. Circulating cell free DNA testing: are some test failures informative? *Prenat Diagn.* 2015;35(3):289-293. <https://doi.org/10.1002/pd.4541>
35. Becking EC, Wirjosoekarto SAM, Scheffer PG, et al. Low fetal fraction in cell-free DNA testing is associated with adverse pregnancy outcome: analysis of a subcohort of the TRIDENT-2 study. *Prenat Diagn.* 2021;41(10):1296-1304. <https://doi.org/10.1002/pd.6034>
36. Morris RK, Bilagi A, Devani P, Kilby MD. Association of serum PAPP-A levels in first trimester with small for gestational age and adverse pregnancy outcomes: systematic review and meta-analysis. *Prenat Diagn.* 2017;37(3):253-265. <https://doi.org/10.1002/pd.5001>
37. Lindquist A, Poulton A, Halliday J, Hui L. Prenatal diagnostic testing and atypical chromosome abnormalities following combined first-trimester screening: implications for contingent models of

- non-invasive prenatal testing. *Ultrasound Obstet Gynecol.* 2018;51(4): 487-492. <https://doi.org/10.1002/uog.18979>
38. Syngelaki A, Hammami A, Bower S, Zidere V, Akolekar R, Nicolaides KH. Diagnosis of fetal non-chromosomal abnormalities on routine ultrasound examination at 11–13 weeks' gestation. *Ultrasound Obstet Gynecol.* 2019;54(4):468-476. <https://doi.org/10.1002/uog.20844>
39. Petersen OB, Vogel I, Ekelund C, Hyett J, Tabor A. Potential diagnostic consequences of applying non-invasive prenatal testing: population-based study from a country with existing first-trimester screening. *Ultrasound Obstet Gynecol.* 2014;43(3):265-271. <https://doi.org/10.1002/uog.13270>

SUPPORTING INFORMATION

Additional supporting information can be found online in the Supporting Information section at the end of this article.

How to cite this article: Bardi F, Bet BB, Pajkrt E, et al.

Additional value of advanced ultrasonography in pregnancies with two inconclusive cell-free DNA draws. *Prenat Diagn.* 2022;42(11):1358-1367. <https://doi.org/10.1002/pd.6238>