



Contents lists available at ScienceDirect

Saudi Journal of Biological Sciences

journal homepage: www.sciencedirect.com

Original article

Current practices of plastic surgeons at King Abdulaziz University Hospital in requesting breast imaging studies prior to non-oncological breast surgeries

Lama H. Meriky^{a,*}, Laila K. Ashkar^b^a Faculty of Medicine, King Abdulaziz University, Jeddah, Saudi Arabia^b Department of Radiology, Faculty of Medicine, King Abdulaziz University, Jeddah, Saudi Arabia

ARTICLE INFO

Article history:

Received 4 March 2020

Revised 5 March 2021

Accepted 7 March 2021

Available online 17 March 2021

Keywords:

Preoperative breast imaging

Preoperative mammogram

Breast cosmetic surgeries

ABSTRACT

Background: In the context of the high incidence of breast cancer and the high frequency of breast cosmetic surgeries, malignant and/or premalignant lesions are frequently detected incidentally in postoperative histopathology specimens. The current literature does not provide clear practice guidelines for the use of preoperative imaging prior to non-oncological breast surgeries.

Objectives: In this study, we aimed to determine the current practices of plastic surgeons at King Abdulaziz University Hospital (KAUH) and their use of preoperative breast imaging before non-oncological breast surgeries.

Design: Non-intervention/ retrospective record review.

Settings: Department of Radiology at King Abdulaziz University Hospital (KAUH).

Methods: In 08/06/2017 at King Abdulaziz University Hospital, we conducted a single-center, retrospective chart review of the medical files of candidates for non-oncological breast surgery in order to examine preoperative imaging requests by plastic surgeons in the period 01/01/2013 to 08/06/2017.

Main outcome measures: The practice of plastic surgeons at KAUH in requesting preoperative imaging prior non-oncological breast surgeries.

Sample size: 104 patients.

Results: We found that, in the period 2013 to 2017, 104 women who underwent non-oncological breast surgeries were evaluated for recent preoperative breast imaging. Only 37 patients (35.6%) were found to have had preoperative imaging, and only less than one fifth (19.4%) of those 37 patients had abnormal preoperative imaging results, all of which were negative for malignancy.

Conclusions: Although the yield of malignancy on preoperative breast imaging was zero in women seeking non-oncological breast surgeries at KAUH, we recommend the establishment of unified practice guidelines to be followed by plastic surgeons for better postoperative screening in different risk groups.

Limitations: Lack of follow up of patients postoperatively for any development of malignancy.

© 2021 Published by Elsevier B.V. on behalf of King Saud University. This is an open access article under the CC BY-NC-ND license (<http://creativecommons.org/licenses/by-nc-nd/4.0/>).

1. Introduction

The current literature does not provide clear practice guidelines for the use of preoperative imaging prior to non-oncological breast surgeries.

In the context of the high incidence of breast cancer and the high frequency of breast cosmetic surgeries, malignant and/or premalignant lesions are frequently detected incidentally in postoperative histopathology specimens. A recent study that examined breast reduction specimens found the incidence of breast cancer to be between (0.06 and 0.4%) (Clark et al., 2009). Thus, it is important that plastic surgeons make every effort to detect malignant breast lesions before performing reconstructive breast surgeries.

* Corresponding author at: Faculty of Medicine, King Abdulaziz University, P.O. Box 5203, Nafee bin Alhareth, Jeddah 22431, Saudi Arabia.

E-mail address: lama.meriky@hotmail.com (L.H. Meriky).

Peer review under responsibility of King Saud University.



Production and hosting by Elsevier

In their proposed guidelines for imaging prior to augmentation mammoplasty in patients with no risk factor for malignancy, the European Society of Breast Cancer Specialists (Cardoso, 2012) proposed that a preoperative imaging workup should be performed using bilateral breast ultrasound for women below the age of 35 years and a mammogram for those above that age. Although proposed by respected experts, this guideline falls short of being an accepted clinical guideline. A recent study by Miglioretti showed that screening mammography tends to have a lower sensitivity in women with breast augmentation (Miglioretti et al., 2004) rendering the acquisition of preoperative image quite useful for the follow up in this particular population group. In contrast, a retrospective study by Snodgrass in 1994 investigated the utility of preoperative mammograms in young women who had undergone non-oncological breast surgeries; the authors concluded that preoperative mammograms are not cost-effective and should, therefore, not be performed on a routine basis (Snodgrass et al., 1997). The current literature does not make preoperative imaging recommendations for patients undergoing reduction mammoplasty (Carloni et al., 2014).

Thus, it seems that plastic surgeons are inconsistent by when requesting imaging prior to cosmetic surgeries. This study will review the current practices of plastic surgeons at our hospital in order to aid the development of clear preoperative guidelines for preoperative imaging prior to non-oncological breast surgeries.

2. Methods

The study took place in King Abdulaziz University Hospital (KAUH) on 08/06/2017. The unit of biomedical ethics at KAUH approved our retrospective review of the medical files of patients who had undergone elective, non-oncological breast surgeries, such as bilateral breast augmentation and reconstruction, bilateral breast reduction and mastopexy in the period 01/01/2013 to 08/06/2017.

We searched hospital records for patients that had undergone elective breast surgery through the database provided at KAUH (Phoenix); we identified a total of 159 patients. Inclusion criteria were that female patients must have undergone elective breast surgery in the study period. Exclusion criteria were women who had undergone reconstructive breast surgeries in the context of underlying breast cancer and a total of 55 patients were excluded.

A total of 104 patients met the inclusion criteria; we reviewed the electronic records of each patient, including preoperative imaging studies, surgical notes and histopathology notes.

Patients were identified as “having preoperative imaging studies requested” if they had undergone one or more of the following preoperative imaging studies in the year preceding their surgery: (i) bilateral breast ultrasound, (ii) bilateral mammography, (iii) breast magnetic resonance imaging (MRI). We anonymized the names of the requesting plastic surgeons; here we refer to the plastic surgeons as Surgeon A, B, C and D.

Radiologists evaluated preoperative imaging, followed the American College of Radiology Breast Imaging Reporting and Data System (BI-RADS). Radiologists defines normal findings as those documented with BI-RADS category 1 or 2, with BI-RADS 1 being “negative” and BI-RADS 2 being “benign finding”. Radiologists defined abnormal findings as those documented with BI-RADS category 3–6 or category 0.

We checked the medical records of patients who underwent bilateral breast reduction in order to ascertain whether postoperative surgical specimens had been excised and sent for histopathology analysis. Where available, histopathology reports of the examined specimens were reviewed for the presence of any abnormal findings.

Data collected were inserted into the Statistical Package for The Social Sciences (SPSS) and analysis was done using the SPSS version 24.0.

3. Results

This study included 104 female patients, of which 95 (84.8%) were Saudi, with mean age 34.7 (9.2) years range (20–64 years). None of the study patients presented with any particular risk factors for breast cancer.

Out of the 104 patients, only 37 (35.6%) had underwent imaging prior to their surgery. Of the 37 patients, (62.2%, n = 23) were more 30 years old. While the remaining (37.8%, n = 14) patients were under 30 years old (Fig. 1).

On the other hand, patients who did not undergo preoperative imaging (64.4%, n = 67) had an approximated age distribution with 37 patients (44.8%) being under the age of 30, while 30 patients (55.2%) were above the age of 30 (Fig. 6).

We found a clear variability in the use of preoperative imaging among the group of 4 plastic surgeons. The highest rate for preoperative imaging requests was for Surgeon C who had a (100%, n = 7) request rate. Next came Surgeon A with a request rate of (37.5%, n = 18), then Surgeon B who had a preoperative imaging request rate of (25.5%, n = 12), and finally Surgeon D who did not request preoperative imaging for any of their 2 patients (0.0%) request rate, (n = 2) (Fig. 2).

We noted the surgery type for the patients for whom preoperative imaging was requested. A total of (45.9%, n = 17) of those patients underwent a bilateral breast augmentation, followed by (29.7%, n = 11) who underwent bilateral reduction mammoplasty and, finally, (24.3%, n = 9) underwent mastopexy (Fig. 3).

Of the patients who underwent bilateral breast reduction, (89%, n = 17) had an excisional biopsy sent for histopathology analysis, findings were all benign results in the form of normal, fibrofatty breast tissue, fibrocystic changes, fibroadenomas(s), papilloma(s) and duct ectasia (Table 1).

The subset of patients who didn't undergo preoperative imaging and had histopathological assessment for either reduction mammoplasty or mastopexy (n = 7), showed benign results; 1 patient (14.3%) biopsy showed normal results, 3 patients (42.8%) showed fibrocystic changes, other patient (n = 114.3%) biopsy showed fibrocystic changes with an intraductal papillomatosis, another patient (n = 114.3%) showed fibrocystic changes on one breast with focal fibrosis and adenosis on the other breast, lastly one patient (n = 114.3%) biopsy showed stromal fibrosis alone (Table 2).

Different modalities of preoperative imaging were used. Bilateral mammograms were used in (35.1%, n = 13) of the patients, breast ultrasound in (29.7%, n = 11), both ultrasound and mammogram in (24.3%, n = 9), and breast MRI in (10.8%, n = 4) (Fig. 4).

The majority of patients who underwent preoperative imaging (80.6%, n = 29) showed normal findings, while (19.4%, n = 7) showed abnormal findings. Of the patients with abnormal findings, (13.8%, n = 5) were categorized as BI-RADS 3 and (5.6%, n = 2) were categorized as BI-RADS 0. None of the patients were diagnosed with malignancy (BI-RADS 5) (Fig. 5).

4. Discussion

It is estimated that, internationally, more than one million women are diagnosed with breast cancer every year. There were approximately 459,000 breast cancer related deaths recorded in 2008, making it the leading cause of cancer mortality that creates a substantial burden as well as a global health concern (Coughlin and Ekwueme, 2009; Youlden et al., 2012).

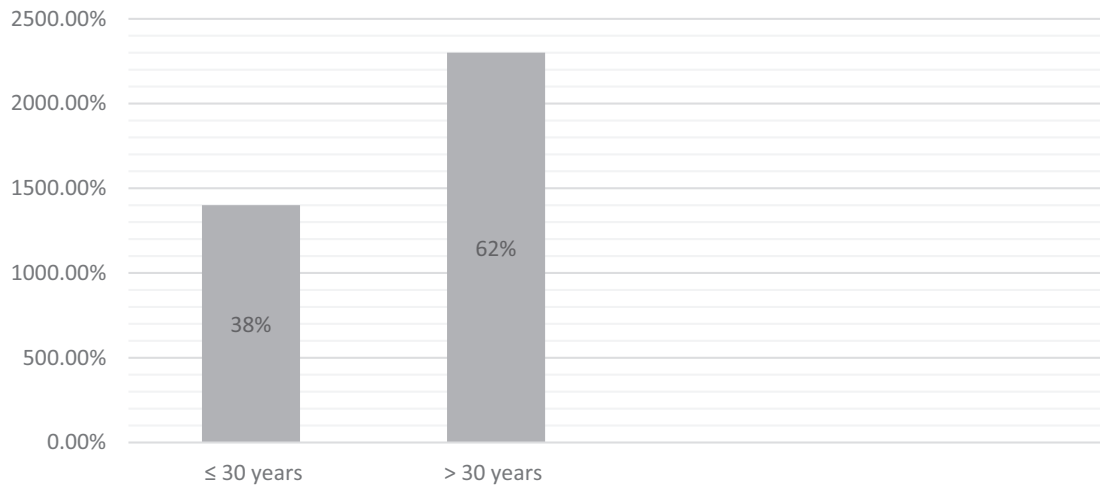


Fig. 1. Age categories in patients with preoperative imaging.

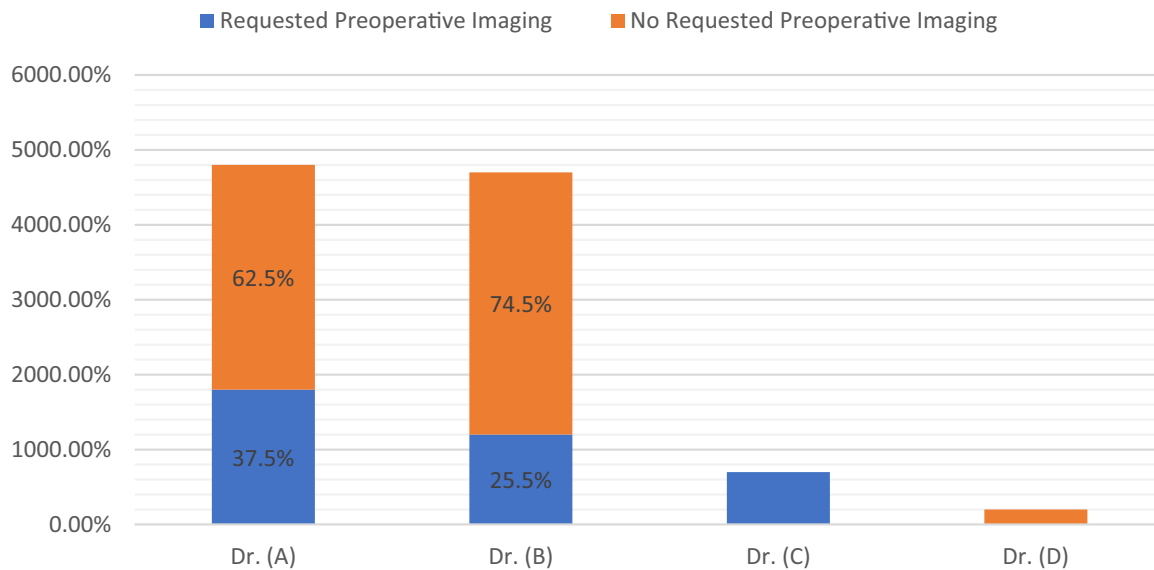


Fig. 2. Ordering surgeons.

In Saudi Arabia, according to a study published by Saudi Cancer Registry in 2013, a total of 6922 female breast cancer cases were recorded in a 7-year period. Women aged 30–44 years of age had the highest overall percentage (38.6%) of female breast cancer cases (Alghamdi et al., 2013).

According to the American Society of Plastic Surgeons, there were 290,467 breast augmentation surgery procedures, 39,148 breast reduction procedures, and 101,264 mastopexy procedures in America during 2016, making breast augmentation the most common cosmetic surgical procedure that year. The group with the highest number of breast augmentation procedures (37%) was women aged 30–39 years (Complete Plastic Surgery Statistics Report, 2016). The increasing popularity of cosmetic surgeries in this cancer-prone age group in Saudi Arabia means that it is imperative that plastic surgeons request preoperative

imaging in order to detect any significant disorder of the breast (s) prior to cosmetic surgery.

A systematic literature review by Carloni revealed a failure to provide a consensual recommendation regarding the performance of preoperative imaging assessment prior to breast surgery in non-oncological patients presenting for plastic surgeries (Carloni et al., 2014).

Because reduction mammoplasty distorts the architecture of the breast, breast-sparing options are limited or impossible when adenocarcinoma of the breast is incidentally found postoperatively in the reduction specimens. Therefore, it is important to detect breast cancer before women breast reduction surgery (Campbell et al., 2010).

Additionally, obtaining a preoperative mammogram as a baseline for detecting abnormalities after the cosmetic surgery is cru-

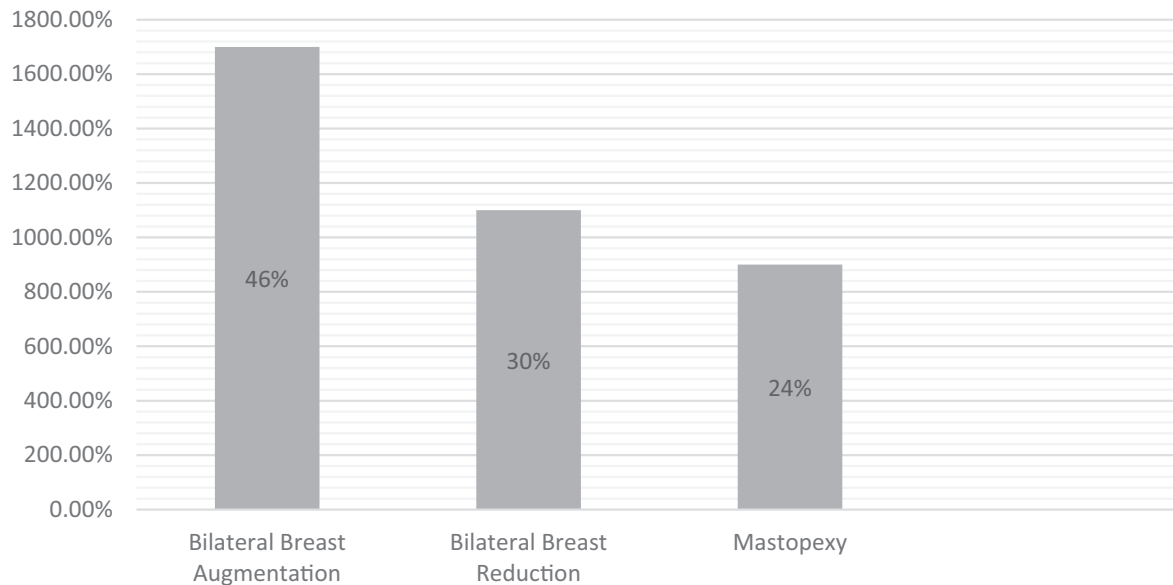


Fig. 3. Types of operations.

Table 1
Histopathology findings in patients with preoperative imaging.

Histopathology Acquisition	Number	Percentage
Yes	17	89.5%
No	2	10.5%
Findings on Histopathology		
Normal	4	23.5%
Fibroadenoma(s)	2	11.8%
Fibrocystic Changes	7	41.2%
Papilloma(s)	1	5.9%
Fibrofatty Tissue	2	11.8%
Duct Ectasia	1	5.9%

Table 2
Histopathology findings in patients without preoperative imaging.

Histopathology Acquisition	Number	Percentage
Yes	7	10.4%
No	60	89.6%
Findings on Histopathology		
Normal	1	14.3
Fibrocystic changes	3	42.8
Fibrocystic changes with intraductal papillomatosis	1	14.3
Rt breast; fibrocystic changes. Lt breast; focal fibrosis and adenosis	1	14.3
Stromal fibrosis	1	14.3
Normal	1	14.3

cial for the success of future mammographic screening; postoperative imaging can be especially difficult for patients with implants and postsurgical architectural distortion. If a patient with a significant family history of breast cancer desires breast augmentation, then the plastic surgeon has a duty of care to warn the patient beforehand that the implant could possibly reduce the chance of early detection of cancer.

The European Society of Breast Cancer Specialists advocates for the use of preoperative imaging studies in women undergoing cosmetic breast augmentation (Cardoso et al., 2012). On the other hand, some experts argue that the rate of finding breast cancer on preoperative imaging has been low, concluding that preoperative imaging may not be cost-effective (Snodgrass et al., 1997). Abnormal imaging results sometimes influence the decision to proceed with surgery or to delay it.

There are no clear and widely accepted guidelines for plastic surgeons on the use of screening mammography prior to breast reconstructive surgeries. The aim of this study is to determine the current practice of plastic surgeons regarding their requests for preoperative screening breast imaging prior to non-oncological breast surgeries at KAUH.

Out of 104 female patients aged 20–64 years, preoperative imaging was requested in 37 patients (35.6%), the vast majority of whom (62.2%, $n = 23$) were more than 30 years old. Out of those 37 patients, 45.9% ($n = 17$) underwent a bilateral breast augmentation, followed by 29.7% ($n = 11$) who underwent bilateral reduction mammoplasty and, finally, 24.3% ($n = 9$) underwent mastopexy.

Our study revealed inter-surgeon variability. The highest rate of preoperative imaging requests was for Surgeon C (100%, $n = 7$), followed by Surgeon A (37.5%, $n = 18$), then Surgeon B (25.5%, $n = 12$), and finally Surgeon D who made no preoperative imaging requests (0.0%, $n = 2$). This variability is understandable in the absence of clear guidelines.

The clear majority of patients in our study who underwent preoperative imaging had normal findings, with just less one fifth (19.4%) having abnormal findings. Of the patients whose preoperative imaging showed abnormal findings, we found that those abnormalities were all either of a benign nature or were reported as incomplete. Of the patients who had bilateral breast reduction surgeries, 89% ($n = 17$) had their excised specimen sent for histopathology; findings were benign with no evidence of malignancy in all cases.

Giving this low yield of abnormalities in preoperative breast imaging in women seeking cosmetic breast surgeries at KAUH, in our opinion, preoperative imaging should be requested.

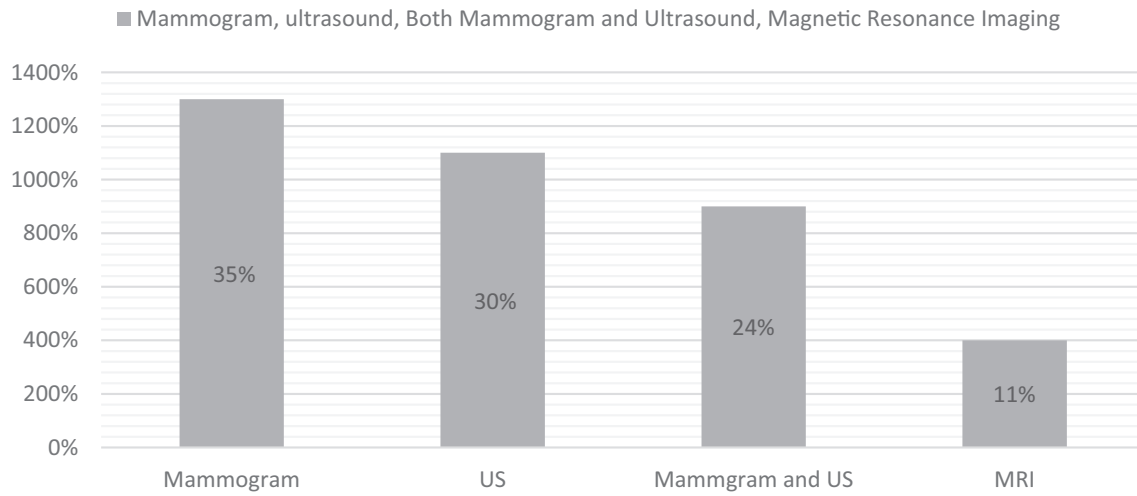


Fig. 4. Types of preoperative imaging.

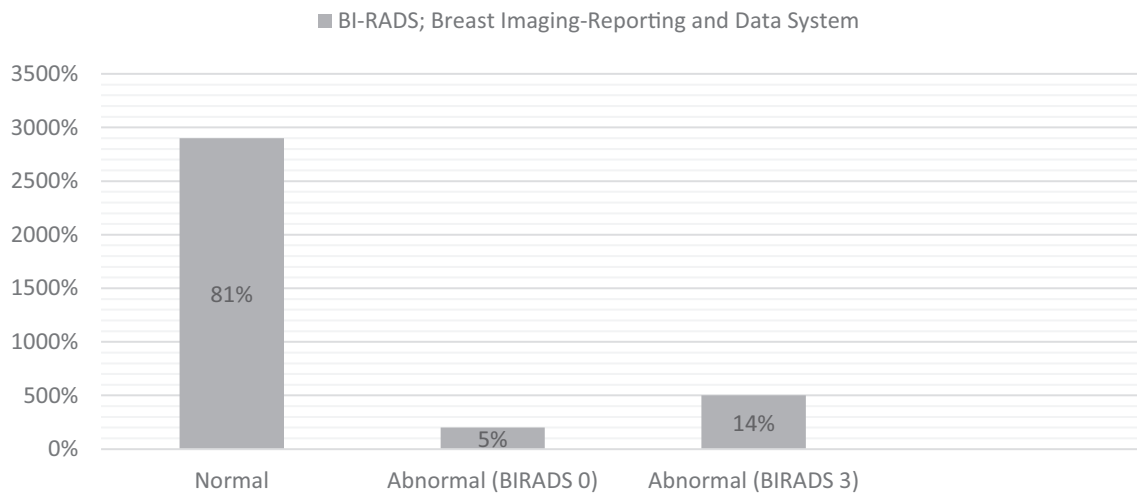


Fig. 5. Findings of preoperative imaging.

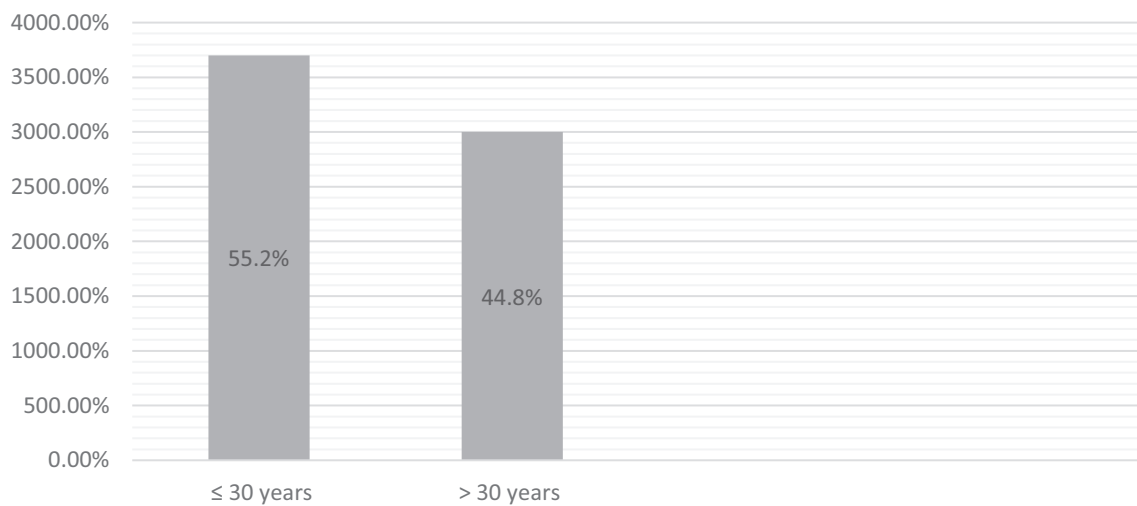


Fig. 6. Age categories in patients with no preoperative imaging.

Further studies and reviews are needed to identify practices at different hospitals in order to provide a scientific evidence base and to establish firm practice guidelines for plastic surgeons to follow in the future.

5. Limitation of study

Lack of follow up of patients postoperatively for any development of malignancy.

6. Conclusion

Although we found the rate of abnormalities found in preoperative breast imaging to be small in women seeking cosmetic breast surgeries at KAUH, the discrepancy found in the surgeons' practice was quite relevant. We, therefore, call for unified practice guidelines to be established for use by plastic surgeons prior to non-oncological breast surgery. Such guidelines will allow surgeons to improve patient care and will facilitate harmonization of surgical practice. And in order to implement that, we recommend that surgeons consider incorporating breast imaging as a standard part of their preoperative evaluation, for diagnosing abnormalities, and to establish a baseline for future imaging.

7. Formatting of funding sources

This research did not receive any specific grant from funding agencies in the public, commercial, or not-for-profit sectors.

Declaration of Competing Interest

None.

Acknowledgments

This research did not receive any specific grant from funding agencies in the public, commercial, or not-for-profit sectors.

References

- Alghamdi, I.G., Hussain, I.I., Alghamdi, M.S., El-Sheemy, M.A., 2013. The incidence rate of female breast cancer in Saudi Arabia: an observational descriptive epidemiological analysis of data from Saudi Cancer Registry 2001–2008. *Breast Cancer (Dove Med Press)*. 2013;5:103–9. Epub 2013/10/17. doi: 10.2147/BCTT.S50750. PubMed PMID: 24648763; PubMed Central PMCID: PMC3929249.
- Campbell, M.J., Clark, C.J., Paige, K.T., 2010. The role of preoperative mammography in women considering reduction mammoplasty: a single institution review of 207 patients. *Am. J. Surg.* 199 (5), 636–640. <https://doi.org/10.1016/j.amjsurg.2010.01.011>. PubMed PMID: 20466108.
- Cardoso, F., Loibl, S., Pagani, O., Graziottin, A., Panizza, P., Martincich, L., et al., 2012. The European Society of Breast Cancer Specialists recommendations for the management of young women with breast cancer. *Eur J Cancer*. 2012;48 (18):3355–77. Epub 2012/10/29. doi: 10.1016/j.ejca.2012.10.004. PubMed PMID: 23116682.
- Carlioni, R., Delay, E., Gourari, A., Ho Quoc, C., Tourasse, C., Balleyguier, C., et al., 2014. Preoperative imaging prior to breast reconstruction surgery: benchmarking bringing together radiologists and plastic surgeons. Proposed guidelines. *Ann Chir Plast Esthet*. 2014;59(2):e13–9. Epub 2014/02/18. doi: 10.1016/j.anplas.2013.07.010. PubMed PMID: 24556529.
- Clark, C.J., Whang, S., Paige, K.T., 2009. Incidence of precancerous lesions in breast reduction tissue: a pathologic review of 562 consecutive patients. *Plast Reconstr Surg*. 124 (4), 1033–1039. <https://doi.org/10.1097/PRS.0b013e3181b45801>. PubMed PMID: 19935286.
- Complete Plastic Surgery Statistics Report. 2016.
- Coughlin, S.S., Ekwueme, D.U., 2009. Breast cancer as a global health concern. *Cancer Epidemiol*. 2009;33(5):315–8. Epub 2009/11/07. doi: 10.1016/j.canep.2009.10.003. PubMed PMID: 19896917.
- Miglioretti, D.L., Rutter, C.M., Geller, B.M., Cutter, G., Barlow, W.E., Rosenberg, R., et al., 2004. Effect of breast augmentation on the accuracy of mammography and cancer characteristics. *JAMA* 291 (4), 442–450. <https://doi.org/10.1001/jama.291.4.442>. PubMed PMID: 14747501.
- Snodgrass, K., Yu, J., Doster, E., Camp, M., Moody, D., Given, K., 1997. The value of preoperative mammograms in nononcologic breast surgery. *South Med J* 90 (4), 402–404. PubMed PMID: 9114831.
- Youlden, D.R., Cramb, S.M., Dunn, N.A., Muller, J.M., Pyke, C.M., Baade, P.D., 2012. The descriptive epidemiology of female breast cancer: an international comparison of screening, incidence, survival and mortality. *Cancer Epidemiol*. 2012;36(3):237–48. Epub 2012/03/2. doi: 10.1016/j.canep.2012.02.000. PubMed PMID: 22459198.