

Multilevel Anterior Lumbar Interbody Fusion Combined with Posterior Stabilization in Lumbar Disc Disease—Prospective Analysis of Clinical and Functional Outcomes*

Artrodese lombar intersomática anterior multinível combinada com estabilização posterior em discopatia—análise clínico-funcional prospectiva

Diogo Lino Moura^{1,2} David Lawrence² Josué Pereira Gabriel²

¹Orthopedics Service, Centro Hospitalar e Universitário de Coimbra, Coimbra, Portugal

²Spine Institute of Ohio, Grant Medical Center, Columbus, OH, United States of America

Address for correspondence: Diogo Lino Moura, Serviço de Ortopedia, Centro Hospitalar e Universitário de Coimbra, Coimbra, Portugal (e-mail: dflmoura@gmail.com).

Rev Bras Ortop 2019;54:140–148.

Abstract

Objective This was a prospective controlled study with lumbar degenerative disc disease patients submitted to instrumented anterior lumbar interbody fusion (ALIF) combined with posterior stabilization.

Methods A sample with 64 consecutive patients was operated by the same surgeons over 4 years. Half of the ALIFs occurred at 2 levels, 43.8% at 3 levels, and 6.25% at 1 level. Interbody cages with integrated screws, filled with bone matrix and bone morphogenetic protein 2, were used.

Results Half of the patients had undergone previous lumbar spine surgeries, 75% presented with associated degenerative listhesis, and 62.5% had posterior lumbar compression disease. Approximately 56% of the sample had at least 1 risk factor for nonunion. The Oswestry index changed from 71.81 ± 7.22 at the preoperative assessment to 24.75 ± 7.82 at the final follow-up evaluation, while the visual analogue pain scale changed from 7.88 ± 0.70 to 2.44 ± 0.87 ($p < 0.001$). Clinical and functional improvements increased with the number of operated levels, proving the efficacy of multilevel ALIF, performed in 93.75% of the sample. The global complication rate was of 7.82%, with no major complications. No cases of nonunion were observed.

Conclusion Instrumented ALIF combined with posterior stabilization is a successful option for uni- and multilevel degenerative disc disease of the L3 to S1 segments, even in the significant presence of risk factors for nonunion and of previous lumbar surgeries, assuring very satisfactory clinical-functional and radiographic outcomes with a low medium-term complication rate.

Keywords

- ▶ lumbar vertebrae/surgery
- ▶ spinal fusion
- ▶ prospective studies
- ▶ scoliosis/surgery
- ▶ risk factors

* Work developed at the Serviço de Ortopedia of the Centro Hospitalar e Universitário de Coimbra, Coimbra, Portugal.

Resumo

Objetivo Estudo prospectivo controlado em pacientes com discopatia degenerativa submetidos a artrodese intersomática lombar anterior instrumentada combinada com estabilização posterior.

Métodos Amostra com 64 pacientes consecutivos operados pelos mesmos cirurgiões ao longo de quatro anos. Metade das artrodeses intersomática lombar anterior foi efetuada em dois níveis, 43,8% em três níveis e 6,25% em um nível. Foram usadas caixas intersomáticas com parafusos integrados preenchidas com matriz óssea e proteína morfogenética óssea 2.

Resultados Metade da amostra apresentava cirurgias prévias à coluna lombar, 75% listeses degenerativas associadas e 62,5% patologia compressiva posterior da coluna lombar. Aproximadamente 56% da amostra apresentavam pelo menos um fator de risco de não união da artrodese. O índice Oswestry passou de $71,81 \pm 7,22$ no pré-operatório para $24,75 \pm 7,82$ na avaliação no fim do tempo de seguimento, enquanto a escala visual analógica da dor passou de $7,88 \pm 0,70$ para $2,44 \pm 0,87$ ($p < 0,001$). A melhoria clínico-funcional foi crescente de acordo com a intervenção num número superior de níveis, o que comprova a eficácia da artrodese intersomática lombar anterior multinível, aplicada em 93,75% da amostra. A taxa global de complicações foi de 7,82% e de complicações major de 0%. Não se identificou qualquer caso de não união.

Palavras-chave

- ▶ vértebras lombares/ cirurgia
- ▶ fusão vertebral
- ▶ estudos prospectivos
- ▶ escoliose/cirurgia
- ▶ fatores de risco

Conclusão A artrodese intersomática lombar anterior instrumentada combinada com estabilização posterior é uma opção de sucesso na discopatia degenerativa uni ou multinível dos segmentos de L3 a S1, mesmo em presença significativa de fatores de risco de não união e cirurgias prévias da coluna lombar, garante resultados clínico-funcionais e radiográficos muito satisfatórios e reduzida taxa de complicações em médio prazo.

Introduction

Anterior lumbar interbody fusion (ALIF) is a therapeutic option for lumbar spine degenerative disc disease and spondylolisthesis at the L3-L4, L4-L5 and L5-S1 levels, which are increasingly common conditions in modern society.¹ In theory, the anterior interbody fusion has biomechanical and morbidity advantages over the posterior, oblique or lateral approaches.^{2,3} The anterior lumbar spine approach allows a better exposure of the disc space and the application of a larger interbody cage, thus effectively restoring the intervertebral space height, lumbar lordosis, the sagittal balance, and the physiological distribution of forces on the anterior and middle columns of Denis (80% of axial compressive forces occur in the anterior and middle columns); this, theoretically, reduces the risk of adjacent disc disease and the need for future surgical interventions. These factors, also theoretically, increase the potential for interbody fusion since the cage is more subjected to compression forces in the anterior column of Denis and the stimulus to bone fusion is more effective.¹⁻⁶ In addition, the anterior cage position corresponds to the most vascularized region of the vertebral body, stimulating the fusion.^{4,5} The most effective discectomy under direct visualization through a wider space leaves less disc residues that can interpose themselves and impair the interbody fusion compared with other approaches, assuring a greater fusional area. The bigger interbody spacing

provided by the larger cage also allows a significant increase in the intervertebral foramina height, which effectively decreases the conflict with spinal roots, as well as the symptomatology.^{3,7,8} Regarding morbidity, unlike the posterior approaches, which involve extensive paravertebral muscle dissection, and the lateral approach, which involves crossing the psoas muscle, the anterior lumbar spine approach does not interfere with any spinal muscle and does not include muscular detachments. Thus, theoretically, there is less bleeding, which may allow a faster postoperative pain relief (reducing the need for painkillers) and functional improvement (with shorter hospital stay), as well as earlier spine stability, because it does not interfere with the supporting musculature.^{3,5,6,8-10} Moreover, the anterior approach neither implies in the removal of posterior spinal elements, nor in the entry into the spinal canal or in the manipulation of the spinal roots to access the disc space; as such, it decreases the risk of iatrogenic injury and of complications in these important structures compared with the posterior approaches.^{3,6,8}

Despite these theoretical advantages and the fact that ALIF has been described since the 1930s for the treatment of various lumbar spine conditions, its exact indications and clear advantages remain to be proven.^{1,2,8,11}

Concerns regarding iatrogenic and potentially fatal large vessel damage, as well as the limited experience of

orthopedic surgery in the anterior approach to the lumbar spine, often lead many surgeons away from this interbody fusion technique. Currently, large prospective studies on ALIF remain limited, and this technique is deferred to posterior, oblique, or lateral interbody fusions in many centers.

Material and Methods

This was a prospective controlled study in 64 consecutive patients with lumbar degenerative disc disease treated with ALIF combined with posterior stabilization over 4 years; all of the procedures were performed by the same surgeons and complied with the same therapeutic protocol.

The mean follow-up time was of 27.64 ± 11 months (minimum time of 12 months; range: 12–48 months). All of the patients completed a conservative treatment period, including symptomatic control and physical therapy, before the surgical intervention. The patients were studied for diagnosis, symptomatology, nonunion risk factors (obesity, smoking, diabetes mellitus), multilevel surgery,^{2,12,13} surgical intervention characteristics, hospitalization, and ALIF-related complications. For the clinical-functional analysis, the Oswestry¹⁴ index of inactivity and the visual analogue pain scale were used;¹⁵ the preoperative values were compared with those obtained in the final evaluation of each patient. The radiological analysis included implant migration signs, fixation failure, and the presence of peri-implant osteolysis (indirect signs of nonunion). The variables were statistically treated using the IBM SPSS Statistics for Windows, Version 23.0 (IBM Corp., Armonk, NY) software. The Shapiro-Wilk normality test identified asymmetric variable distributions, and nonparametric statistical tests were applied. *P*-values < 0.05 were considered statistically significant. The present study was approved by the relevant institution.

Therapeutic Protocol

The ALIF procedure is detailed in ►Table 1. The anterior approach to the lumbar spine is performed and completed by an experienced vascular surgeon. The ALIF procedure is complemented in a second operative time and in a second hospitalization with a posterior percutaneous transpedicular fixation (270° interbody fusion) or, if a decompressive lam-

inoforaminectomy is required, with a posterolateral procedure (360° or circumferential interbody fusion). All of the surgical procedures are performed with intraoperative neuromonitoring. All of the patients are clinically and radiographically evaluated in the 1st week, at 6 weeks, at 3 months, at 6 months and 1 year postoperatively, followed by annual visits (►Figs. 1 and 2). Computed tomography (CT) scans were not performed to confirm union.

Results

Most of the patients (75%, $n = 48$) were male, with a mean age of 53.63 ± 9.47 years old (range: 29–69 years old). Three-quarters of the sample ($n = 48$) had degenerative listhesis associated with disc disease, and 62.5% ($n = 40$) presented with a concomitant lumbar spine posterior compressive condition. Twenty patients had already been operated and presented with some degree of neurological deficit, ranging from decreased muscle strength to foot drop. The main symptoms were lumbosacral radiculopathy (96.88%; $n = 62$) and axial lumbar pain (65.63%; $n = 42$). Half of the patients had undergone previous lumbar spine interventions, which were divided between posterior lumbar interbody fusions (PLIFs) ($n = 8$) and transforaminal lumbar interbody fusions (TLIFs) ($n = 4$) in 1 level, laminectomies ($n = 12$), and microdiscectomies ($n = 8$) (►Fig. 3). All of the PLIF cases were nonunion situations, whereas the TLIF patients presented adjacent disc disease. Posterior fixation was maintained in cases of previous PLIFs and TLIFs. More than half of the patients (56.25%, $n = 36$) had at least 1 risk factor for nonunion of the interbody fusion, whose distribution is shown in ►Fig. 4. The distribution of surgical segments is shown in ►Fig. 5; ALIF was multilevel in 93.75% of the cases. The dimensions of the most frequently used interbody cages according to segment were: 14 mm/8° ($n = 12$) in L3-L4; 14 mm/8° ($n = 12$); 16 mm/8° ($n = 12$) in L4-L5; and 14 mm/12° ($n = 12$) and 15 mm/12° ($n = 12$) in L5-S1. Intra- and postoperative ALIF parameters are indicated in ►Table 2.

There was a statistically significant improvement between the preoperative evaluation and the final evaluation at the end of the follow-up period in both analyzed scores (►Figs. 6 e 7). The Oswestry index decreased from 71.81 ± 7.22 at the preoperative period to 24.75 ± 7.82 at

Table 1 Details of the anterior lumbar interbody fusion surgery performed in all patients from the sample

Therapeutic protocol	
Approach route	Lumbar spine retroperitoneal abdominal anterior route
Number of operated levels	According to the presence of degenerative disc disease, listhesis and need of lumbar lordosis repair
Interbody cages	Anatomical, lordotic, with notches and optional screw integration through the implant. Cages are made of polyetheretherketone (PEEK)
Cage filling	Demineralized bone material and absorbable collagen plaque with human recombinant bone morphogenetic protein (BMP-2) (Infuse [Medtronic]®)
Cage fixation	Cages are fixed with three screws, two at the inferior vertebral body and one in the superior vertebral body

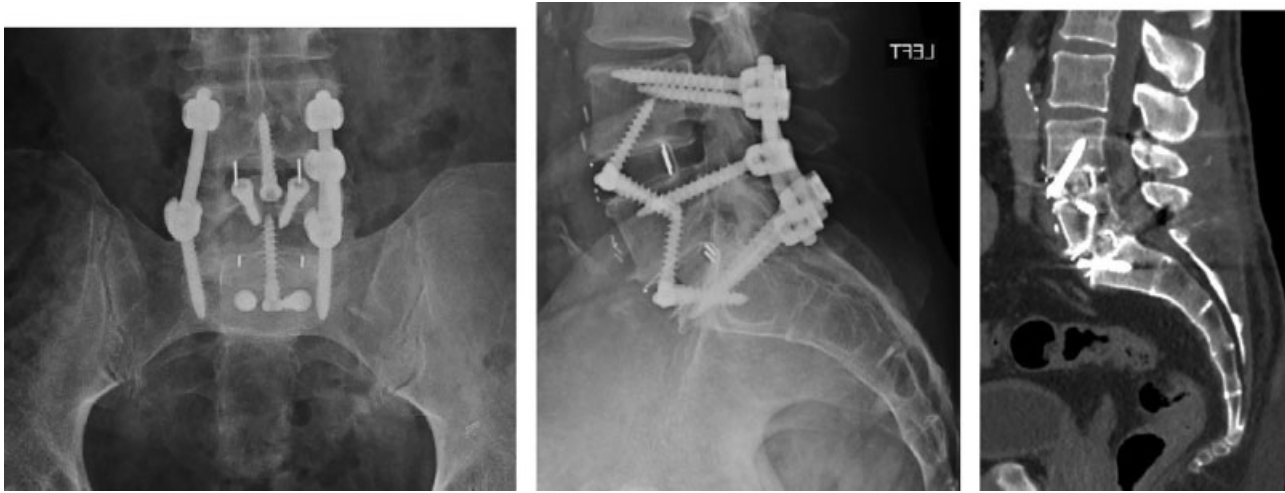


Fig. 1 Example of a 2-level ALIF – L4-L5 and L5-S1—using cages with 3 integrated screws and a percutaneous posterior transpedicular attachment. Anteroposterior and lateral radiographs and a computed tomography scan show union (interstitial bone bridges in L4-L5 and L5-S1) (the abdominal computed tomography was performed for another clinical reason).

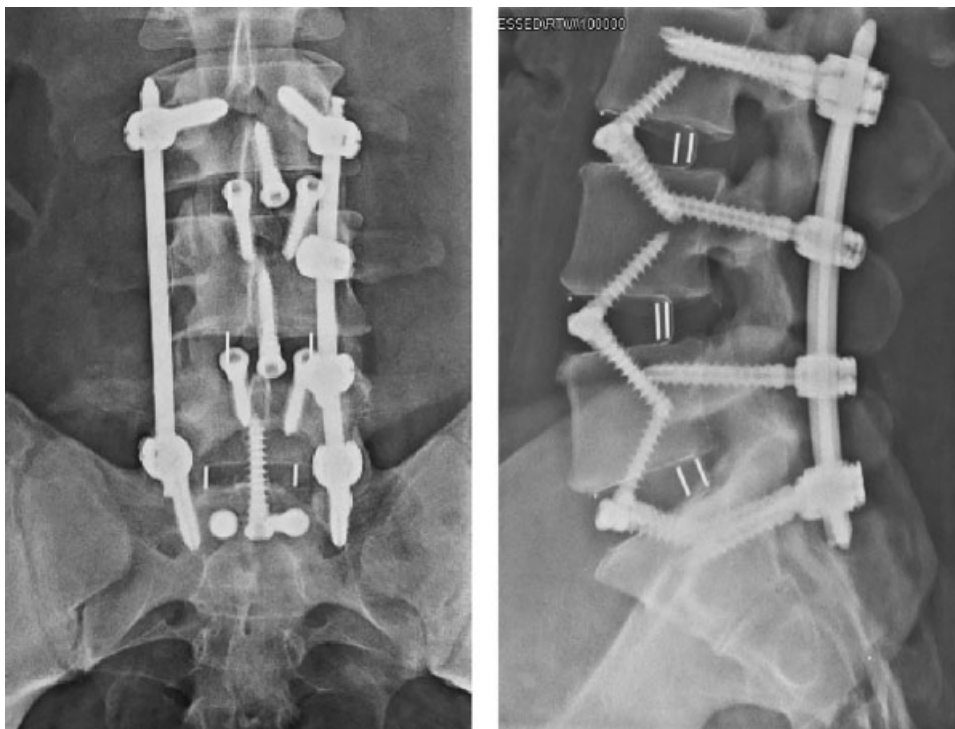


Fig. 2 Example of a 3-level ALIF – L3-L4, L4-L5 and L5-S1—using cages with 3 integrated screws and a percutaneous posterior transpedicular attachment. Anteroposterior and lateral radiographs.

the end of the follow-up period ($p < 0.001$), corresponding to a mean decrease of 47.06 ± 5.29 (37–54). The visual analogue scale of pain decreased from 7.88 ± 0.70 to 2.44 ± 0.87 ($p < 0.001$), corresponding to a mean reduction of 5.44 ± 0.61 (5–7). There was a significant direct correlation between both scores in the preoperative evaluation ($\rho = 0.79$; $p < 0.001$) and the final evaluation ($\rho = 0.87$; $p < 0.001$). Patients with prior neurological deficits had significantly less favorable preoperative scores (Oswestry: 74.40 ± 6.44 ; and visual analogue scale: 8.20 ± 0.77) compared with neurologically intact individuals (Oswestry: 70.64 ± 7.31 ; and visual analogue scale: 7.73 ± 0.62 ;

$p = 0.05$ and $p = 0.016$, respectively). Patients with risk factors presented significantly lower preoperative and final Oswestry and analogue visual scale scores than individuals without any identified risk factor (–Table 3). When we analyzed each risk factor separately, we found significantly less favorable scores in obese, smokers, and diabetic patients, as well as in those with previous lumbar spine surgeries. Patients with concomitant posterior lumbar conditions who had undergone a laminoforaminectomy and a postlateral interbody fusion also had significantly less favorable scores (–Table 3). Patients with prior neurological deficits tended to present a more pronounced improvement in clinical-

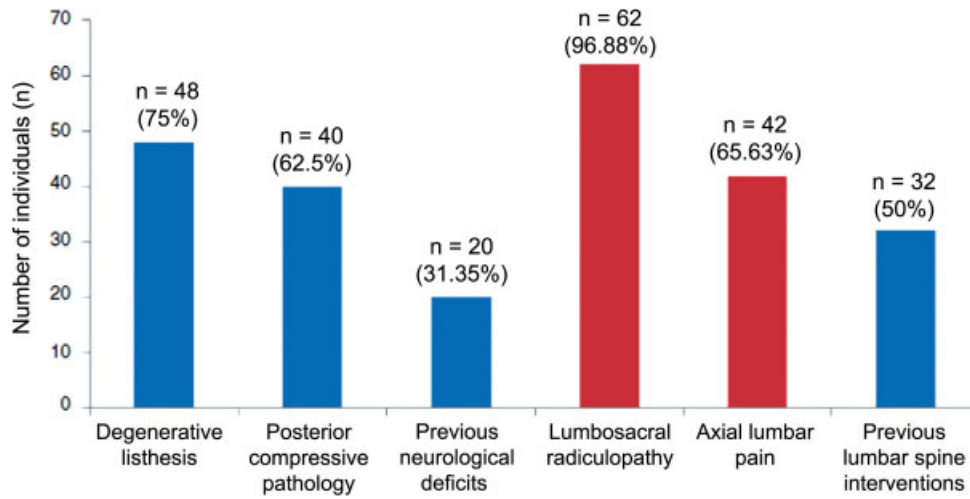


Fig. 3 Distribution of surgical indications and observed symptomatology

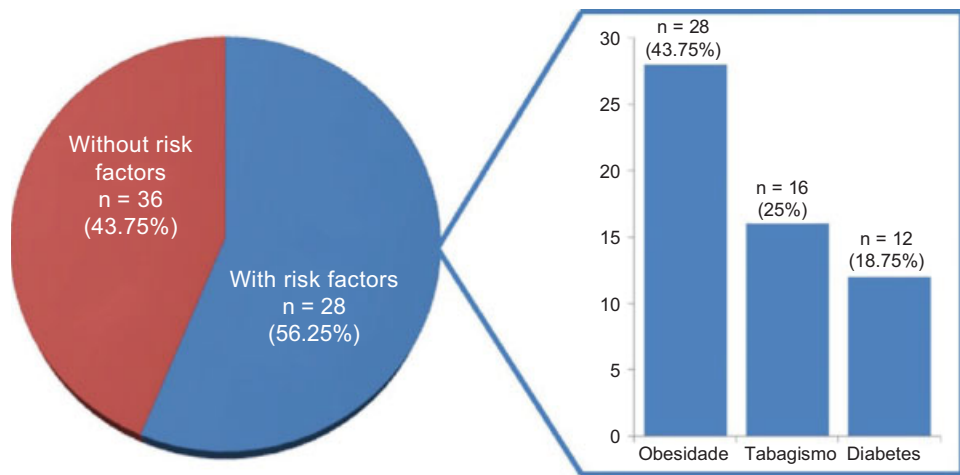


Fig. 4 Distribution of the risk factors for nonunion

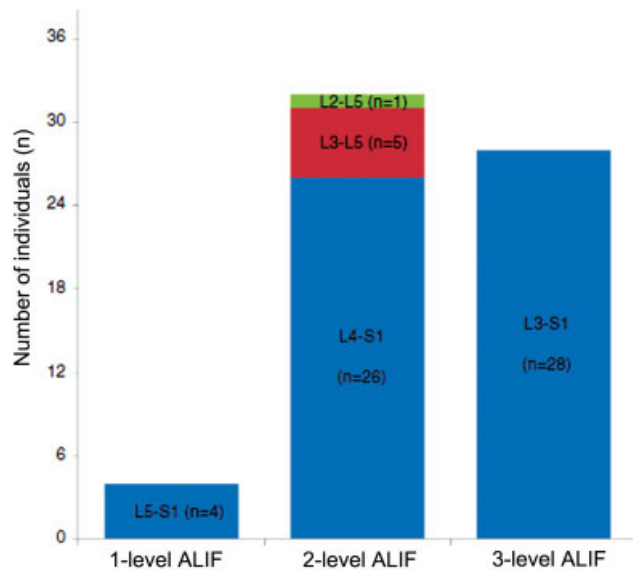


Fig. 5 Distribution of operated intervertebral segments

Table 2 Anterior lumbar interbody fusion surgery intra- and postoperative parameters

Parameters	Mean and standard deviation values
Age	53.63 ± 9.47 years old
Mean ALIF time	105.63 ± 24.49 minutes
Blood loss during ALIF	96.88 ± 60.99 mL
ALIF-related hospitalization time	4.25 ± 0.98 days

Abbreviation: ALIF, anterior lumbar interbody fusion.

functional scores, with no statistical significance. A significant direct correlation was identified between the number of risk factors in each patient and the preoperative ($\rho = 0.67$; $p < 0.001$) and final Oswestry indexes ($\rho = 0.79$; $p < 0.001$), and the preoperative ($\rho = 0.39$; $p = 0.001$) and final visual analogue scales ($\rho = 0.58$; $p < 0.001$). Significant direct correlations were also confirmed between

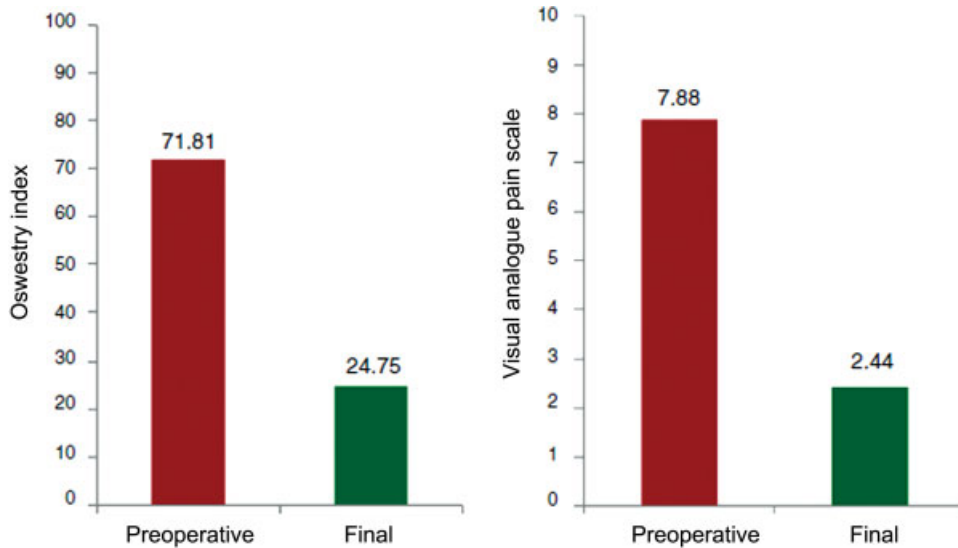


Fig. 6 Distribution of the clinical and functional scores: Oswestry index and visual analogue pain scale at the preoperative evaluation and the last follow-up evaluation

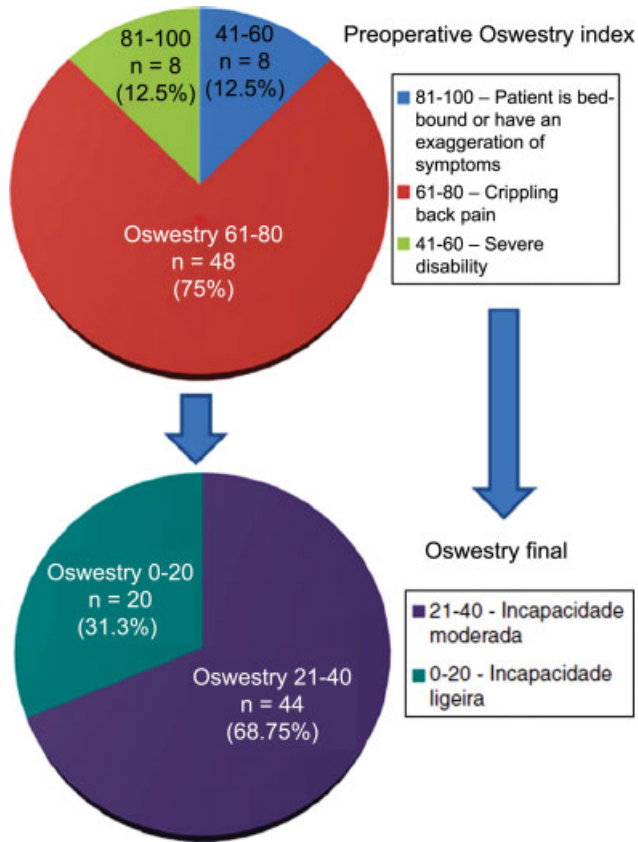


Fig. 7 Distribution of disability degrees according to the Oswestry index at the preoperative evaluation and the last follow-up evaluation

the number of operated levels and the mean surgical time ($\rho = 0.86$; $p < 0.001$; 1 level = 50.00 ± 12.00 ; 2 levels = 94.38 ± 11.76 ; 3 levels = 126.43 ± 24.49 minutes), as well as the mean blood loss ($\rho = 0.52$; $p < 0.001$; 1 level = 25.00 ± 5.00 ; 2 levels = 103.13 ± 81.75 ; 3 levels = 100.00 ± 13.61 mL). In addition, the mean improvement in both scores showed a significant direct correlation with

the number of operated levels ($\rho = 0.40$; $p = 0.001$), with the most marked improvement in the 3-level ALIF (► **Table 4**).

The ALIF complications were limited to 3 superficial infections of the surgical wound (4.69%), and to 3 small dehiscences of the surgical wound (3.13%). There were no major or fatal complications, such as laceration or large vessel thrombosis, or any intraoperative complications. There was no retroperitoneal hematoma, abdominal incisional hernia, retrograde ejaculation, or erectile dysfunction. There were no complications in the subsequent stabilization interventions made in a second surgical time. Thus, the overall complication rate was of 7.82%, and the major complication rate was of 0%. No case of nonunion, of implant migration or of adjacent disc disease development was identified during the follow-up period. Patients with complications presented a significantly higher mean age (64.50 ± 4.81 years old) compared to those with no complications (52.07 ± 8.95 years old) ($p < 0.001$).

Discussion

We believe that ALIF combined with posterolateral fixation or interbody fusion is a surgical intervention that ensures a more solid, stable, and durable lumbar spine. It is a particularly important procedure in young patients, in whom the restoration of the sagittal balance and of the physiological loads on the Denis columns may decrease evolution to adjacent disc disease, posterior column overload, and early arthroscopy.^{2,4-6,8} Recent instrumented ALIF techniques have proven results in the literature, with a significant improvement in the clinical-functional scores after surgical intervention and interbody union rates $> 90\%$ and with $< 10\%$ of major complications.^{3,8,10,16,17}

Despite the good stabilization of the current instrumented ALIF, we believe that, especially in the presence of nonunion risk factors, it is important to complement the construction with a posterior transpedicular stabilization to

Table 3 Clinical and functional evaluation in several subgroups and their differences

	Preoperative Oswestry index	Final Oswestry index	Mean Oswestry index reduction	Preoperative visual analogue pain scale	Final visual analogue pain scale	Mean visual analogue pain scale reduction
With risk factors	75.44 ± 5.92	30.22 ± 3.85	45.22 ± 5.23	8.11 ± 0.75	2.89 ± 0.57	5.22 ± 0.42
Without risk factors	67.14 ± 6.00	17.71 ± 5.68	49.43 ± 4.42	7.57 ± 0.50	1.86 ± 0.85	5.71 ± 0.71
<i>p-value</i>	< 0.001 ^a	< 0.001 ^a	0.003 ^a	0.03 ^a	< 0.001 ^a	0.002 ^a
Obese patients	77.00 ± 5.16	30.71 ± 2.35	46.29 ± 5.44	8.14 ± 0.65	2.86 ± 0.36	5.29 ± 0.46
Nonobese patients	67.78 ± 5.91	20.11 ± 7.43	47.67 ± 5.17	7.67 ± 0.68	2.11 ± 1.01	5.56 ± 0.69
<i>p-value</i>	< 0.001 ^a	< 0.001 ^a	0.384	0.007 ^a	< 0.001 ^a	0.127
Smokers	75.00 ± 7.30	29.75 ± 4.97	45.25 ± 4.97	8.00 ± 0.73	3.00 ± 0.73	5.00
Nonsmokers	70.75 ± 6.94	23.08 ± 7.92	47.67 ± 5.30	7.83 ± 0.69	2.25 ± 0.84	5.58 ± 0.65
<i>p-value</i>	0.043 ^a	0.002 ^a	0.17	0.416	0.005 ^a	< 0.001 ^a
Diabetic patients	80.67 ± 4.38	31.33 ± 0.98	49.33 ± 3.45	8.33 ± 0.49	3.00	5.33 ± 0.49
Nondiabetic patients	69.77 ± 6.12	23.23 ± 7.92	46.54 ± 5.53	7.77 ± 0.70	2.31 ± 0.92	5.46 ± 0.64
<i>p-value</i>	< 0.001 ^a	< 0.001 ^a	0.097	0.011 ^a	0.007 ^a	0.628
Primary surgery	68.13 ± 8.01	19.63 ± 7.53	48.50 ± 5.05	7.50 ± 0.51	1.88 ± 0.79	5.63 ± 0.71
Previous spinal surgeries	75.50 ± 3.70	29.88 ± 3.64	45.63 ± 5.20	8.25 ± 0.67	3.00 ± 0.51	5.25 ± 0.44
<i>p-value</i>	< 0.001 ^a	< 0.001 ^a	0.013 ^a	< 0.001 ^a	< 0.001 ^a	0.023 ^a
With neurological deficits	74.40 ± 6.44	25.20 ± 7.06	49.20 ± 3.97	8.20 ± 0.77	2.40 ± 0.82	5.80 ± 0.77
Without neurological deficits	70.64 ± 7.31	24.55 ± 8.21	46.09 ± 5.56	7.72 ± 0.62	2.45 ± 0.90	5.27 ± 0.45
<i>p-value</i>	0.907	0.058	0.062	0.016 ^a	0.900	0.004 ^a
With posterior compression	73.90 ± 7.31	25.30 ± 8.63	48.60 ± 5.48	8.20 ± 0.61	2.60 ± 0.93	5.60 ± 0.67
Without posterior compression	68.33 ± 5.65	23.83 ± 6.31	44.50 ± 3.86	7.33 ± 0.48	2.17 ± 0.71	5.17 ± 0.38
<i>p-value</i>	0.003 ^a	0.315	0.002 ^a	< 0.001 ^a	0.022 ^a	0.006 ^a

^a P values with statistical significance.

Table 4 Improvement degree or average reduction of clinical and functional scores according to the number of operated levels between preoperative evaluation and the most recent evaluation

Number of operated levels	Average improvement in clinical and functional scores	
	Oswestry index	Visual analogue pain scale
1	40.00 ± 1.11	5.00 ± 1.12
2	46.13 ± 5.53	5.25 ± 0.44
3	49.14 ± 4.16	5.71 ± 0.71

increase stability and maximize the desired interbody fusion, as well as to reduce the increased risk of nonunion in these cases. However, this topic is controversial, and the current literature is inconsistent. Some studies demonstrate that standalone instrumented ALIF without posterior stabilization does not yield significant differences in terms of clinical-functional and radiographic outcomes compared with circumferential lumbar interbody fusion, so a second surgery

can be avoided in cases with no need of posterior decompression.^{3,6,7,9-11,18,19} However, other studies showed superior union rates for instrumented ALIFs combined with posterior fixation, demonstrating that, although ALIF fixation with an anterior plaque or cage-integrated screws significantly increases stability, it is still inferior compared with the posterior instrumentation.²⁰⁻²⁵ Moreover, the additional stability offered by posterior fixation or interbody fusion may probably contribute to decrease the intensity or even avoid symptoms in case of a nonunion ALIF, allowing these lack of fusions to be tolerated or asymptomatic. Further large randomized prospective studies are required to prove the effectiveness and safety of instrumented ALIF cages without additional stabilization.

The robustness of the anterior and of the posterior assembly and the noninductive potential of bone morphogenetic protein 2 (BMP-2) in the interbody cage may be responsible for the lack of any nonunion in this sample, even in the presence of a substantial number of patients with nonunion risk factors, and with half of them with previous lumbar spine surgeries. The use of Infuse® (Medtronic,

Fridley, MN, USA) also avoids morbidity and possible complications during the obtainment of an iliac crest autograft.^{3,10} Although patients with previous PLIF nonunions had less favorable clinical-functional scores, the review using another approach (anterior approach) and ALIF resulted in very satisfactory outcomes.^{2,26}

The increasing clinical-functional improvement according to the number of instrumented intervertebral segments should be analyzed with caution, since 1-level ALIF was performed in only 4 patients; as such, outcomes may be biased by the small size of this group in comparison with 2-level and 3-level ALIFs, with a consequent loss of statistical power. Nevertheless, we believe that these results can be justified because of 2- and 3-level ALIFs (corresponding to 93.75%) allow not only the individual treatment of such segments, but also avoid an eventual clinical deterioration due to adjacent disc disease, assuring a more reliable lumbar lordosis and sagittal physiological balance restoration compared to 1-level ALIF. The clinical-functional improvement observed in multilevel ALIFs also shows the reduced morbidity of the retroperitoneal anterior lumbar spine approach during the extension of the intervention to several segments; it also ensures that the multilevel intervention does not affect negatively the clinical-functional recovery, even if the surgical time and hemorrhagic losses are higher than in 1-level ALIF.

Despite the risk of potentially fatal complications associated with the anterior retroperitoneal abdominal approach, we consider that its execution and accountability (during the opening, the possible vascular complications treatment, the closing, and the follow-up of any approach-related complications in the postoperative period) by an expert surgeon may be an important factor for the reduced complication rate found in the present sample.^{2,3,6,8,16,27-30} In addition to the reduced morbidity characteristics of the retroperitoneal anterior approach, the experience of the surgeon allows us to save surgical time and reduce hemorrhagic losses, which may also contribute to the decreased complications rates, to the shorter hospitalization times, and to the clinical-functional improvement in our study.^{28,30}

In summary, we consider that the very satisfactory clinical-functional and radiographic outcomes obtained in the present study are due to the biomechanical advantages of instrumented ALIF combined with posterior stabilization, to the frequent use of multilevel ALIF and its advantages in the more effective restoration of lumbar lordosis, to the surgical technique, both in its approach and procedure, and to the interbody cages with integrated screws and filled with bone matrix and BMP-2.

The main advantage of this prospective study is the uniform application of the same therapeutic protocol to all patients, and the fact that all of the procedures were performed by same surgeons, allowing a considerable bias reduction due to treatment variation. The main limitations of the present study were the lack of randomization or blinding and the fact that this is a convenience sample with heterogeneous group sizes.

Conclusion

The favorable biomechanics of instrumented ALIF combined with posterior stabilization is a satisfactory therapeutic option in uni- or multilevel degenerative disc disease in the L3-L4, L4-L5 and L5-S1 levels, associated or not with posterior compressive lumbar disease, even in the presence of significant nonunion risk factors and of previous lumbar spine surgeries. It assures very satisfactory clinical-functional and radiographic outcomes and a reduced complication rate in the medium-term.

Conflicts of Interest

The authors have no conflicts of interest to declare.

References

- Phan K, Thayaparan GK, Mobbs RJ. Anterior lumbar interbody fusion versus transforaminal lumbar interbody fusion—systematic review and meta-analysis. *Br J Neurosurg* 2015;29(05):705–711
- Rao PJ, Loganathan A, Yeung V, Mobbs RJ. Outcomes of anterior lumbar interbody fusion surgery based on indication: a prospective study. *Neurosurgery* 2015;76(01):7–23
- Burkus JK, Gornet MF, Schuler TC, Kleeman TJ, Zdeblick TA. Six-year outcomes of anterior lumbar interbody arthrodesis with use of interbody fusion cages and recombinant human bone morphogenetic protein-2. *J Bone Joint Surg Am* 2009;91(05):1181–1189
- Truumees E, Majid K, Brkaric M. Anterior lumbar interbody fusion in the treatment of mechanical low back pain. *Semin Spine Surg* 2008;20(02):113–125
- Mummaneni PV, Haid RW, Rodts GE. Lumbar interbody fusion: state-of-the-art technical advances. Invited submission from the Joint Section Meeting on Disorders of the Spine and Peripheral Nerves, March 2004. *J Neurosurg Spine* 2004;1(01):24–30
- Strube P, Hoff E, Hartwig T, Perka CF, Gross C, Putzier M. Stand-alone anterior versus anteroposterior lumbar interbody single-level fusion after a mean follow-up of 41 months. *J Spinal Disord Tech* 2012;25(07):362–369
- Zhang JD, Poffyn B, Sys G, Uyttendaele D. Are stand-alone cages sufficient for anterior lumbar interbody fusion? *Orthop Surg* 2012;4(01):11–14
- Udby PM, Bech-Azeddine R. Clinical outcome of stand-alone ALIF compared to posterior instrumentation for degenerative disc disease: A pilot study and a literature review. *Clin Neurol Neurosurg* 2015;133:64–69
- Kim JS, Kim DH, Lee SH, Park CK, Hwang JH, Cheh G, et al. Comparison study of the instrumented circumferential fusion with instrumented anterior lumbar interbody fusion as a surgical procedure for adult low-grade isthmic spondylolisthesis. *World Neurosurg* 2010;73(05):565–571
- Lammler J, Whitaker MC, Moskowitz A, Duong J, Dong F, Felts L, et al. Stand-alone anterior lumbar interbody fusion for degenerative disc disease of the lumbar spine: results with a 2-year follow-up. *Spine* 2014;39(15):E894–E901
- Madan SS, Boeree NR. Comparison of instrumented anterior interbody fusion with instrumented circumferential lumbar fusion. *Eur Spine J* 2003;12(06):567–575
- Glassman SD, Anagnost SC, Parker A, Burke D, Johnson JR, Dimar JR. The effect of cigarette smoking and smoking cessation on spinal fusion. *Spine* 2000;25(20):2608–2615
- Pilitsis JG, Lucas DR, Rengachary SS. Bone healing and spinal fusion. *Neurosurg Focus* 2002;13(06):e1

- 14 Fairbank JC, Pynsent PB. The Oswestry Disability Index. *Spine* 2000;25(22):2940–2952, discussion 2952
- 15 Freyd M. The graphic rating scale. *J Educ Psychol* 1923;43:83–102
- 16 Sasso RC, Kitchel SH, Dawson EG. A prospective, randomized controlled clinical trial of anterior lumbar interbody fusion using a titanium cylindrical threaded fusion device. *Spine* 2004;29(02):113–122, discussion 121–2
- 17 Pavlov PW, Meijers H, van Limbeek J, Jacobs WC, Lemmens JA, Obradov-Rajic M, et al. Good outcome and restoration of lordosis after anterior lumbar interbody fusion with additional posterior fixation. *Spine* 2004;29(17):1893–1899, discussion 1900
- 18 Choi KC, Ryu KS, Lee SH, Kim YH, Lee SJ, Park CK. Biomechanical comparison of anterior lumbar interbody fusion: stand-alone interbody cage versus interbody cage with pedicle screw fixation – a finite element analysis. *BMC Musculoskelet Disord* 2013;14:220
- 19 Cain CM, Schleicher P, Gerlach R, Pflugmacher R, Scholz M, Kandziora F. A new stand-alone anterior lumbar interbody fusion device: biomechanical comparison with established fixation techniques. *Spine* 2005;30(23):2631–2636
- 20 McCarthy MJH, Ng L, Vermeersch G, Chan D. A radiological comparison of anterior fusion rates in anterior lumbar interbody fusion. *Global Spine J* 2012;2(04):195–206
- 21 Anjarwalla NK, Morcom RK, Fraser RD. Supplementary stabilization with anterior lumbar intervertebral fusion—a radiologic review. *Spine* 2006;31(11):1281–1287
- 22 El Masry MA, Badawy WS, Rajendran P, Chan D. Combined anterior interbody fusion and posterior pedicle screw fixation in patients with degenerative lumbar disc disease. *Int Orthop* 2004;28(05):294–297
- 23 Oxland TR, Lund T. Biomechanics of stand-alone cages and cages in combination with posterior fixation: a literature review. *Eur Spine J* 2000;9(Suppl 1):S95–S101
- 24 Tzermiadianos MN, Mekhail A, Voronov LI, Zook J, Havey RM, Renner SM, et al. Enhancing the stability of anterior lumbar interbody fusion: a biomechanical comparison of anterior plate versus posterior transpedicular instrumentation. *Spine* 2008;33(02):E38–E43
- 25 Beaubien BP, Freeman AL, Turner JL, Castro CA, Armstrong WD, Waugh LG, et al. Evaluation of a lumbar intervertebral spacer with integrated screws as a stand-alone fixation device. *J Spinal Disord Tech* 2010;23(05):351–358
- 26 Gertzbein SD, Hollopeter MR, Hall S. Pseudarthrosis of the lumbar spine. Outcome after circumferential fusion. *Spine* 1998;23(21):2352–2356, discussion 2356–7
- 27 Chiriano J, Abou-Zamzam AM Jr, Urayeneza O, Zhang WW, Cheng W. The role of the vascular surgeon in anterior retroperitoneal spine exposure: preservation of open surgical training. *J Vasc Surg* 2009;50(01):148–151
- 28 Mobbs RJ, Phan K, Daly D, Rao PJ, Lennox A. Approach-related complications of anterior lumbar interbody fusion: results of a combined spine and vascular surgical team. *Global Spine J* 2016;6(02):147–154
- 29 Wood KB, Devine J, Fischer D, Dettori JR, Janssen M. Vascular injury in elective anterior lumbosacral surgery. *Spine* 2010;35(9, Suppl):S66–S75
- 30 Quraishi NA, Konig M, Booker SJ, Shafafy M, Boszczyk BM, Grevitt MP, et al. Access related complications in anterior lumbar surgery performed by spinal surgeons. *Eur Spine J* 2013;22(Suppl 1):S16–S20