

Skeletal Metastases Presenting as Superscan on Technetium 99m Methylene Diphosphonate Whole Body Bone Scintigraphy in Different Type of Cancers: A 5-Year Retro-prospective Study

P. Ram Manohar, Tanveer A. Rather, Shoukat H. Khan, Dharmender Malik

Department of Nuclear Medicine, SKIMS, Srinagar, Jammu and Kashmir, India

Abstract

The purpose of the study is to find out the overall incidence of superscan among different type of cancers, causes of superscan and its relationship with other parameters such as age, sex, duration of disease, and serum alkaline phosphatase (ALP) levels. This was a retro-prospective study. Records of all previous bone scans and reported patients of superscan were re-evaluated retrospectively. Patients who were diagnosed as having superscan in the preceding 3 years with confirmed histopathological diagnosis were included in the retrospective group. In the prospective group, all the patients who were reported to have superscan appearance over the past 2 years of prospective period were included. Total of 6027 bone scans were examined in a 5-year period and out of which 80 cases were diagnosed as superscan. The overall incidence of superscan in different type of cancers was 1.3% (80/6027). Prostate cancer (46/80) was the most common cause of superscan appearance followed by breast cancer (10/80). Out of 6027 patients referred for bone scan, 307 patients had prostate cancer on histopathological examination. Out of 307 patients with prostate cancer, 46 had superscan appearance. Incidence of superscan in prostate cancer was 14.98% (46/307), and 71.73% (33/46) prostate cancer patients with superscan had Gleason score of 8 and above 8 with mean serum prostate-specific antigen level was 178.42 ng/ml in symptomatic patients and 122 ng/ml in asymptomatic patients. Out of all patients with superscan, 71 patients (88.7%) had elevated serum ALP levels. Overall incidence of superscan in our study was 1.3% in different type of cancer patients, and the most common cause of superscan appearance was prostate cancer. Incidence of superscan appearance in prostatic cancer patients was 14.98%.

Keywords: Breast cancer, prostate cancer, serum prostate-specific antigen, superscan, technetium 99m methylene diphosphonate bone scan

Introduction

Human skeleton is a living active organ that changes during normal physiological process of growth, remodeling, and in response to various pathological processes. Any process which interferes in the constantly

changing dynamics of osteoclastic resorption and osteoblastic formation of bone results in various pathological and structural abnormalities. Nowadays, a number of structural and functional imaging modalities such as radiographs, computed axial tomography, magnetic resonance imaging, and bone scintigraphy with varying levels of sensitivity and specificity are employed to detect such abnormalities.^[1]

Address for correspondence:

Dr. Tanveer A. Rather, Department of Nuclear Medicine, SKIMS, Srinagar - 190 001, Jammu and Kashmir, India.
E-mail: tanveerrather@rediffmail.com

Access this article online

Quick Response Code:



Website:
www.wjnm.org

DOI:
10.4103/1450-1147.181153

This is an open access article distributed under the terms of the Creative Commons Attribution-NonCommercial-ShareAlike 3.0 License, which allows others to remix, tweak, and build upon the work non-commercially, as long as the author is credited and the new creations are licensed under the identical terms.

For reprints contact: reprints@medknow.com

How to cite this article: Manohar PR, Rather TA, Khan SH, Malik D. Skeletal metastases presenting as superscan on technetium 99m methylene diphosphonate whole body bone scintigraphy in different type of cancers: A 5-year retro-prospective study. World J Nucl Med 2017;16:39-44.

Radiographs can detect a change in skeletal lesion when it has progressed to about 50% change in bone mineralization.^[2] On the other hand, even a 5% change in osteoblastic turnover can be detected by technetium 99m (Tc99m) methylene diphosphonate (MDP) bone scintigraphy with its sensitivity being between 80% and 100% depending on the site of lesion and type of cancer.^[2] Thus, radiographs have a limited sensitivity as compared to Tc99m MDP bone scintigraphy in detecting an early bony lesion.^[2]

Metastases on a bone scan can appear in different patterns. They may present either as a solitary or multiple foci or diffusely increased tracer uptake throughout the skeletal system.

“A bone scan which demonstrates diffusely increased skeletal radioisotope uptake relative to soft tissue in association with absent or faint renal activity (absent kidney sign)” is known as a superscan.^[1,2]

Faint renal uptake or activity is defined as an undoubtedly diminished renal activity compared with rib activity on visual inspection.^[3]

The mechanism most likely responsible for superscan appearance is diffuse reactive bone formation. This could be either due to diffuse metastatic disease or a generalized metabolic disease such as hyperparathyroidism. Because of increased uptake in skeletal system, the soft tissue uptake of radioisotope is very less, which results in increased skeleton to soft tissue activity ratio. Depending upon the degree of reactive bone formation, renal and bladder activity is faint or absent. The normal skeletal to renal ratio of absorption:isotope is 40%:60%. In cases of superscan, this ratio can be altered to up to 86%:14%.^[4,5]

Certain types of metastatic cancers such as prostate cancer, breast cancer, and lung cancer; metabolic bone disease such as renal osteodystrophy, Paget’s disease, and hyperparathyroidism; hematological disease including leukaemia, lymphoma, Waldenstrom’s disease, and myeloproliferative disease;^[6] and some miscellaneous conditions such as hyperthyroidism,^[6] fibrous dysplasia, intracranial glioma,^[7] hypervitaminosis D,^[8] and systemic mastocytosis^[9] may show a superscan appearance on bone scintigraphy.

Pattern of uptake in superscan due to metastatic disease is different from that of metabolic disease. In metastatic disease, pattern of uptake is diffuse or there is heterogeneous uptake or patchy distribution of radiotracer in axial skeleton. In case of metabolic bone disease, uptake is more uniform in appearance, extends to distal appendicular skeleton and intense calvarial uptake that is disproportionate to the remainder of skeleton.^[10]

In literature, many case reports have been published about superscan appearance but a single well-designed institutional based study to describe the causes of superscan appearance, overall incidence of superscan appearance in different type of cancers and its relationship with other parameters such as age, sex, duration of disease, serum alkaline phosphatase (ALP) levels, and tumor markers such as serum prostate-specific antigen (PSA) are not available. The present study was conducted to analyze the superscan appearance in skeletal metastatic disease and to find out its relationship with parameters such as cause, age, sex, duration of disease, serum ALP, and serum PSA.

Materials and Methods

The aim of the study was to analyze overall incidence and the causes of superscan on Tc99m MDP whole body bone scan in a 5-year (3 + 2) retrospective and prospective study manner in patients with established diagnosis of malignancy and to find out relationship between the superscan and other parameters such as age, sex, duration of disease, severity of disease, serum ALP, and serum PSA levels.

This was a 5-year retro-prospective study conducted in the Nuclear Medicine Department of SKIMS. This study was cleared by the Ethics Committee.

The records of all previous bone scans and reported patients of superscan of retrospective group were re-evaluated by two nuclear medicine physicians who were blinded to the clinical details of the patients. Patients reported as having superscan on Tc99m MDP whole body scintigraphy in preceding 3 years with confirmed histopathological diagnosis of malignancy were included in the retrospective group. In the prospective group, patients with histopathology proven cancer who were reported to have superscan on Tc99m MDP bone scintigraphy over a period of 2 years were included. Clinical details of the patients were recorded. Patient’s details of retrospective group were retrieved from their case records.

Exclusion criteria included all such patients who had received chemotherapy and radiotherapy in last 4 months prior to bone scan, patients with abnormal renal function test (elevated blood urea, serum creatinine) and patients with unknown pathology.

Intense and diffusely or heterogeneously increased tracer uptake throughout the skeleton system with markedly diminished or no renal activity (absent kidney sign) and excellent bone details with poor soft tissue uptake were reported as superscan. Faint renal uptake was defined as an undoubtedly diminished renal activity compared

with rib activity on visual inspection. All the scans were reported by two nuclear medicine physicians separately and only those scans having concordance were included in the study.

Statistical methods

All the continuous variables of the study were described by descriptive statistics such as mean, median, and standard deviation (SD). Categorical variables were described by frequency and percentages.

Results

In the 5-year study period, we evaluated whole body bone scans of 6027 patient with underlying malignancy, out of which 80 patients were reported as superscans and overall incidence of superscan appearance in different type of cancer patients was 1.3% [Table 1]. Sixty-three (78.7%) were men and 17 (21.2%) were women [Table 2]. The mean age of the patients was 58.4 ± 1.4 years (SD), and median age was 60 years. Superscan appearance was commonly seen in the 60–69 years age group [Table 3]. Most common cause of superscan in men was prostate cancer and in women was breast cancer. Overall prostate cancer was the most common cause 57.5% (46/80) [Figure 1] followed by breast cancer 12.5% (10/80), lung cancer 11.25% [Figure 2] (9/80), stomach cancer 6.25% (5/80), transitional cell bladder cancer 5% (4/80), medullary thyroid cancer 2.5% (2/80), nasopharyngeal cancer 1.25% (1/80), squamous cell carcinoma of esophagus 1.25% (1/80), minor salivary gland cancer (oncocyctic variety) 1.3% (1/80), and Ewing's sarcoma 1.25% (1/80) [Table 4].

All the prostate cancer patients had adenocarcinoma on histopathological examination. All patients with breast cancer had invasive ductal cell carcinoma. Out of 9 lung cancer patients, three had small cell lung cancer and six were diagnosed as nonsmall cell lung cancer. All patients with stomach cancer had adenocarcinoma (signet ring cell type).

Out of 80 patients of superscan, 71 patients (88.7%) had elevated serum ALP levels (normal serum ALP level 45–125 U/L) with a mean serum ALP level of 615.80 U/L [Table 5]. Fifty-two patients (65%) presented with musculoskeletal pain symptoms. Fifty-seven patients (72%) had Stage 4 disease (other than skeletal metastases) before reporting as a superscan. Twenty-six patients (32.5%) had been reported as superscan in the first 6 months of diagnosis of disease and their mean duration of disease was 18.7 months. Out of 6027 patients referred for bone scan, 307 patients had prostate cancer on histopathological examination. In 307 patients with prostate cancer, 46 had superscan appearance. Incidence of superscan in prostate cancer was 14.98% (46/307) [Table 6].

Table 1: Incidence of superscan in 5 years retro-prospective group

Total number of bone scans in different type of cancer patients over a 5-year period	Number of superscans	Incidence (%)
6027	80	1.3

Table 2: Sex distribution

Diagnosis	Number of male patients	Number of female patients	Total
Prostate cancer	46	00	46
Breast cancer	00	10	10
Lung cancer	07	02	09
Bladder cancer	03	01	04
Thyroid cancer	01	01	02
Nasopharynx cancer	01	00	01
Stomach cancer	02	03	05
Ewing's sarcoma	01	00	01
Esophagus cancer	01	00	01
Minor salivary gland cancer	01	00	01
Total	73	07	80

Table 3: Age distribution

Age interval (years)	Number of patients	Percentage
20-29	03	3.75
30-39	03	3.75
40-49	11	13.75
50-59	16	20.00
60-69	27	33.75
70-79	20	25.00
80-89	01	1.25
Total	80	100

Table 4: Histopathology of tumors in superscan group

Case	Histopathology	Number	Percentage
Prostate cancer	Adenocarcinoma	46	57.5
Breast cancer	Invasive ductal cell carcinoma	10	12.5
Bladder cancer	Transitional cell carcinoma	04	5.0
Stomach cancer	Adenocarcinoma	05	6.0
Thyroid cancer	Medullary carcinoma	02	2.5
Nasopharynx cancer	Embryonal round cell sarcoma	01	1.3
Esophageal cancer	Squamous cell carcinoma	01	1.3
Minor salivary gland cancer	Oncocyctic cell carcinoma	01	1.3
Ewing's sarcoma	Round cell tumor	01	1.3
Lung cancer	Small cell lung carcinoma	03	3.75
	Squamous cell lung carcinoma (moderately differentiated)	03	3.75
	Adenocancer of lung	02	2.5
	Anaplastic (poorly differentiated)	01	1.2

In prostatic superscans, mean and median Gleason score was 8 and 8, respectively, 33 (71.7%) patients had Gleason score of 8 and above 8 [Table 7]. Out of 46 patients with prostatic superscan, 33 patients were symptomatic and

13 were asymptomatic. In symptomatic patients, serum PSA levels were ranged from 3 to 1222 ng/ml with a mean serum PSA level of 178.4 ng/ml. In asymptomatic patients, serum PSA levels were ranged from 12 to 840 ng/ml with a mean serum PSA level of 122 ng/ml (normal serum PSA level 0-4 ng/ml) [Table 8].

Discussion

Superscan is defined as “a bone scan which demonstrates markedly increased skeletal radioisotope uptake relative to soft tissues in association with absent or faint renal activity (absent kidney sign).”

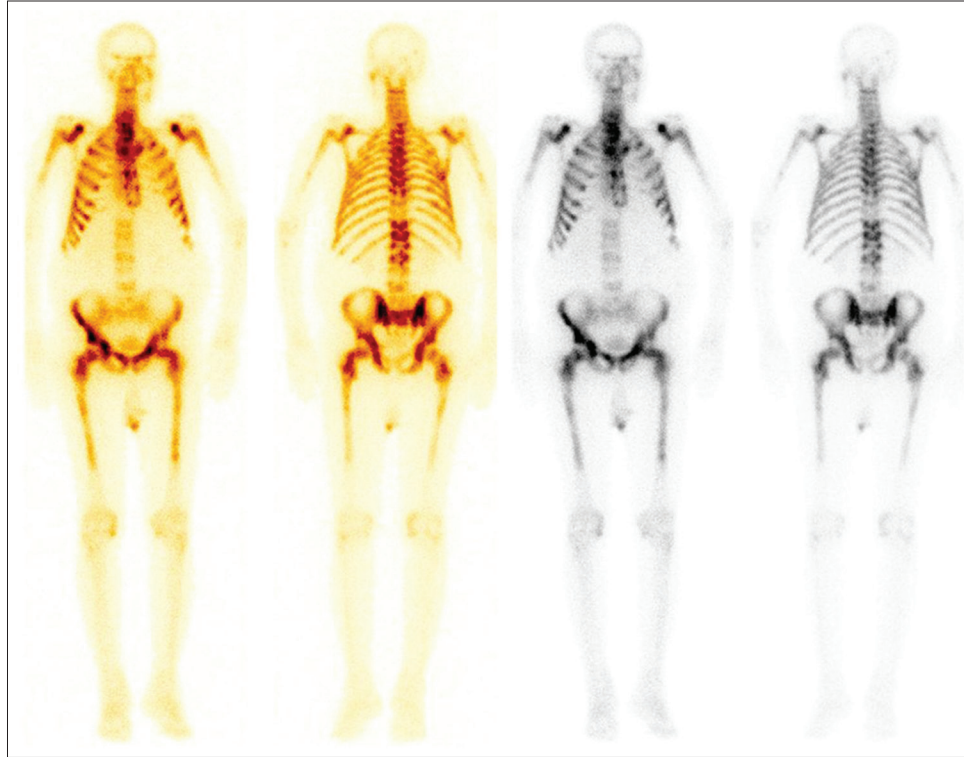


Figure 1: Superscan appearance of bone scan in prostate cancer patient

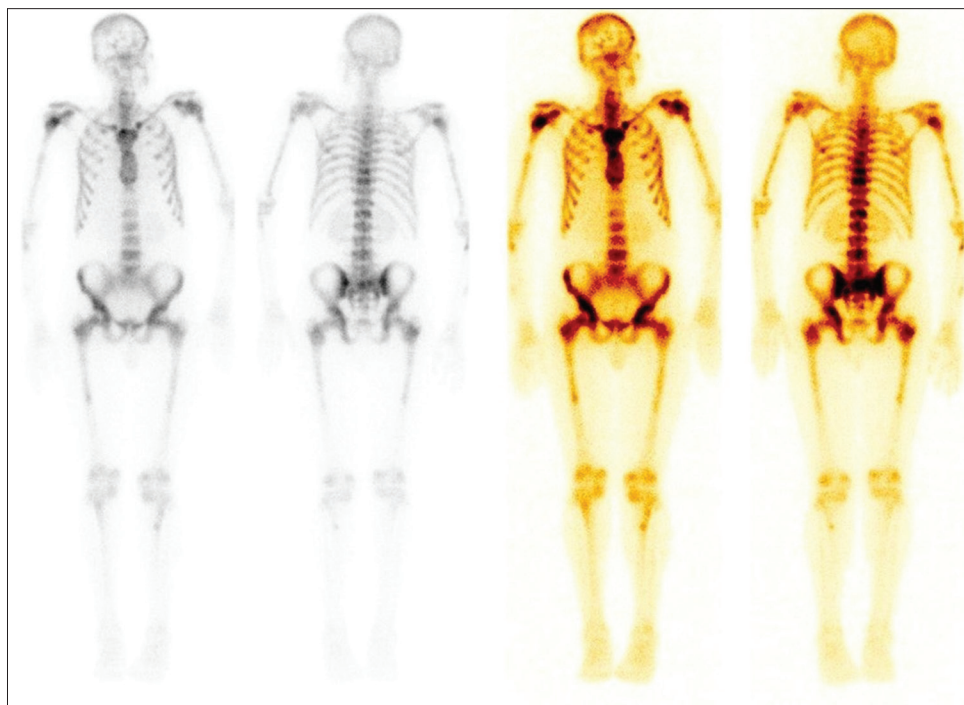


Figure 2: Superscan appearance of bone scan in lung cancer patient

Table 5: Serum alkaline phosphatase levels in superscan group (normal range 45-125 U/L)

Serum ALP Levels in superscan patients	Number of patients with superscans	Percentage	Mean ALP levels (U/L)	Range (U/L)
Elevated	71	88.7	615.80	30-3466
Normal	09	11.2	81.25	

ALP: Alkaline phosphatase

Table 6: Incidence superscan appearance in prostate cancers patients in 5 year study period

Total number of prostate cancer patients in a 5 years study	Number of superscans and incidence (%)	Number of positive bone scans excluding superscans (%)	Number of negative bone scans (%)	Total number of positive bone scans (%)
307	46 (14.98)	139 (45.2)	122 (39.7)	185 (60.2)

Table 7: Relationship between Gleason score and prostate cancer patients with superscan

Gleason score	Number of patients	Percentage
≤6	4	8.69
7	9	19.5
8-10	33	71.73
Total	46	100

Table 8: Correlation of serum prostate specific antigen levels with symptoms in prostatic superscan patients (normal serum prostate specific antigen level 0-4 ng/ml)

Prostate cancer patients with superscan appearance	Number of patients	Maximum serum PSA levels (ng/ml)	Minimum serum PSA levels (ng/ml)	Mean serum PSA levels (ng/ml)
Symptomatic	33	3	1222	178.42
Asymptomatic	13	12	840	122.00

PSA: Prostate specific antigen

Superscan was first described by Osmond *et al.* in 1970.^[11]

Frankel *et al.*^[12] published a case report of superscan appearance in a patient with confirmed diagnosis of lymphoma. In a review of 513 bone scans by Thrupkaew *et al.*,^[13] from 1972 to 1973, three superscans were reported that included two with breast cancer and one with prostate cancer.

A prospective study conducted by Cheng and Holman^[14] for a period of 2 years in 1980 to study causes of an increased skeletal:renal uptake ratio. It was observed that increased skeletal:renal uptake ratio was mainly associated with diffuse metastatic bone disease and prostate cancer being the most common cause.

In 1974, Sy *et al.*^[15] reported superscan appearance in six patients of prostate cancer and one patient of bladder cancer. In same year, Sy^[16] reported superscan appearance in four primary hyperparathyroidism patients. Again in 1975, by Sy and Mittal^[17] conducted a prospective study and reported superscan pattern of bone scan in secondary hyperparathyroidism. Witherspoon *et al.*,^[18] in 1975, reported superscan appearance in four patients of prostate cancer and in one patient of renal cell cancer.

In 1977, Fogelman *et al.*^[19] reported superscan appearance in renal osteodystrophy and prostate cancer patients. In 1995, Choi *et al.*^[20] conducted a retrospective study with 234 patients of stomach cancer and found that 106 (45.3%) had abnormal bone scan results and 6 (2.6%) patients had superscan pattern of bone scan. In 1996, Liu *et al.*^[21] conducted a prospective study with 407 patients of nasopharyngeal carcinoma, out of which six patients (1.5%) had a superscan pattern of bone scan with elevated levels of serum ALP levels.

Constable and Cranage had conducted a prospective study in prostatic cancer patients and reported incidence of superscan appearance in prostatic cancer patients was 17%.^[22]

In our study, overall incidence of superscan in different type of cancers was 1.3%, and we found that in patients with underlying malignancy superscan appearance was most commonly seen in prostate cancer followed by the breast and lung cancer. Besides superscan appearance was also seen in cancers such as transitional cell carcinoma of the bladder, medullary thyroid cancer, minor salivary gland cancer, Ewing's sarcoma, squamous cell carcinoma of the esophagus, and nasopharyngeal cancer, which are uncommon causes. The incidence of superscan appearance in prostatic cancer patients was 14.9%. This incidence is roughly correlated with reported incidence of superscan appearance (17%) in prostate cancer patients by Constable and Cranage.^[22]

Our study revealed that superscan appearance was most commonly seen in age group of 60-69 years and 71 (88.7%) patients with superscan appearance had elevated serum ALP levels with a mean serum ALP level of 615.80 U/L. In patients of prostate cancer having superscan appearance of bone scintigraphy, 71.73% (33/46) had a Gleason score of 8 and above 8. The serum PSA levels were grossly elevated ranging from 3 to 1222 ng/ml. In symptomatic patients with prostate cancer, the mean serum PSA levels were 178.42 ng/ml, and in asymptomatic patients, it was 122 ng/ml.

Conclusion

From our study, we could conclude that superscan appearance is rare. Besides the type of cancer; age of the patient, elevated serum ALP levels, markedly elevated serum PSA levels and symptoms of the patient should raise a high suspicion of diffuse skeletal metastases (superscan) in patients with underlying malignancy referred for bone scintigraphy. This will help in reducing the false negative results after being misinterpreted as normal scan on bone scintigraphy.

Financial support and sponsorship

Nil.

Conflicts of interest

There are no conflicts of interest.

References

- Brenner AI, Koshy J, Morey J, Lin C, DiPoce J. The bone scan. *Semin Nucl Med* 2012;42:11-26.
- Love C, Din AS, Tomas MB, Kalapparambath TP, Palestro CJ. Radionuclide bone imaging: An illustrative review. *Radiographics* 2003;23:341-58.
- Kim SE, Kim DY, Lee DS, Chung JK, Lee MC, Koh CS. Absent or faint renal uptake on bone scan. Etiology and significance in metastatic bone disease. *Clin Nucl Med* 1991;16:545-9.
- Ohashi K, Smith HS, Jacobs MP. "Superscan" appearance in distal renal tubular acidosis. *Clin Nucl Med* 1991;16:318-20.
- Buckley O, O'Keefe S, Geoghegan T, Lyburn ID, Munk PL, Worsley D, *et al.* 99mTc bone scintigraphy superscans: A review. *Nucl Med Commun* 2007;28:521-7.
- Pour MC, Simon-Corat Y, Horne T. Diffuse increased uptake on bone scan: Super scan. *Semin Nucl Med* 2004;34:154-6.
- Schatzki SC, Mcilmoyle G, Lowis S. Diffuse osteoblastic metastases from an intracranial glioma. *AJR Am J Roentgenol* 1977;128:321-3.
- Fogelman I, McKillop JH, Cowden EA, Fine A, Boyce B, Boyle IT, *et al.* Bone scan findings in hypervitaminosis D: Case report. *J Nucl Med* 1977;18:1205-7.
- Sy WM, Bonventre MV, Camera A. Bone scan in mastocytosis: Case report. *J Nucl Med* 1976;17:699-701.
- Manier SM, Van Nostrand D. Super bone scan. *Semin Nucl Med* 1984;14:46-7.
- Osmond JD 3rd, Pendergrass HP, Potsaid MS. Accuracy of 99mTc-diphosphonate bone scans and roentgenograms in the detection of prostate, breast and lung carcinoma metastases. *Am J Roentgenol Radium Ther Nucl Med* 1975;125:972-77.
- Frankel RS, Johnson KW, Mabry JJ, Johnston GS. "Normal" bone radionuclide image with diffuse skeletal lymphoma. A case report. *Radiology* 1974;111:365-6.
- Thrupkaew AK, Henkin RE, Quinn JL 3rd. False negative bone scans in disseminated metastatic disease. *Radiology* 1974;113:383-6.
- Cheng TH, Holman BL. Increased skeletal: Renal uptake ratio: Etiology and characteristics. *Radiology* 1980;136:455-9.
- Sy WM, Patel D, Faunce H. Significance of absent or faint kidney sign on bone scan. *J Nucl Med* 1975;16:454-6.
- Sy WM. Bone scan in primary hyperparathyroidism. *J Nucl Med* 1974;15:1089-91.
- Sy WM, Mittal AK. Bone scan in chronic dialysis patients with evidence of secondary hyperparathyroidism and renal osteodystrophy. *Br J Radiol* 1975;48:878-84.
- Witherspoon LR, Blonde L, Shuler SE, McBurney DB. Bone scan patterns of patients with diffuse metastatic carcinoma of the axial skeleton. *J Nucl Med* 1976;17:253-7.
- Fogelman I, McKillop JH, Boyle IT, Greig WR. Absent kidney sign associated with symmetrical and uniformly increased uptake of radiopharmaceutical by the skeleton. *Eur J Nucl Med* 1977;2:257-9.
- Choi CW, Lee DS, Chung JK, Lee MC, Kim NK, Choi KW, *et al.* Evaluation of bone metastases by Tc-99m MDP imaging in patients with stomach cancer. *Clin Nucl Med* 1995;20:310-4.
- Liu RS, Chu YK, Chu LS, Yeh SH, Yen SH, Chen KY, *et al.* Superscan in patients with nasopharyngeal carcinoma. *Clin Nucl Med* 1996;21:302-6.
- Constable AR, Cranage RW. Recognition of the superscan in prostatic bone scintigraphy. *Br J Radiol* 1981;54:122-5.