

Actinotignum schaalii Infection: A Clandestine Cause of Sterile Pyuria?

Lucy E. Horton,¹ Sanjay R. Mehta,¹ Lejla Aganovic,² and Joshua Fierer¹

¹Department of Medicine, VA San Diego Healthcare System and University of California, San Diego, School of Medicine, San Diego, California; ²Department of Radiology, VA San Diego Healthcare System, San Diego, California

Actinotignum schaalii is an underappreciated cause of urinary tract infections (UTIs) in older adults. The diagnosis may be missed due to difficulty isolating and identifying the organism. Complications can result because the organism is intrinsically resistant to 2 commonly used drugs to treat UTI, as illustrated by this case.

Keywords. *Actinotignum schaalii*; chronic prostatitis; epididymitis; orchitis; urinary tract infection (UTI).

Actinotignum schaalii is increasingly being recognized as a cause of urinary tract infections (UTIs) in older adults. *A. schaalii* (formerly named *Actinobaculum schaalii*) is a small, Gram-positive coccoid rod that is part of the normal microbiota. In 1997, it was reclassified from the genus *Actinomyces* [1]. It is difficult to identify in urine with typical microbiology laboratory techniques, as it grows slowly and cannot be definitely identified using standard biochemical assays. Additionally, *A. schaalii* may be mistaken for normal skin flora such as *Corynebacterium* and dismissed as a contaminant. Identification may require the use of molecular methods such as 16s rDNA sequencing and/or Matrix Assisted Laser Desorption/Ionization Time-of-Flight (MALDI-TOF) mass spectrometry.

A. schaalii is a facultative anaerobe that grows slowly (4 to 5 days) on enriched blood agar media in 5% carbon dioxide or in an anaerobic atmosphere. It is catalase and oxidase negative and does not reduce nitrate to nitrite. It is almost uniformly susceptible to beta-lactam antibiotics, but almost always resistant to TMP-SMX and fluoroquinolones [2].

Most clinical reports involving *A. schaalii* describe it as a cause of UTIs, typically in the elderly and in those with

underlying urologic conditions. It has also been reported to cause bacteremia and associated complications including endocarditis and osteomyelitis. Interestingly, nearly all reports about this uro-pathogen originate from Europe [3–7].

Here we describe a case of a man with chronic prostatitis and acute epididymo-orchitis and relapsing epididymitis due to *A. schaalii*.

CASE

A 73-year-old male was referred to our infectious diseases clinic for evaluation of recurrent epididymitis with negative urine cultures. His medical history was notable for benign prostatic hypertrophy, osteoarthritis, hypertension, depression, and post-traumatic stress disorder.

He was first found to have an elevated prostate-specific antigen (PSA) 19 years earlier during routine age-recommended screening. At that time, he underwent prostate biopsy, which showed only glandular hyperplasia and no malignancy. Over the next 18 years, the PSA remained chronically elevated and gradually rose to a baseline of 10 ng/mL, with 2 documented peak values over 16 ng/mL. During this time, his prostate was repeatedly noted to be enlarged on exam, but he never had any urinary symptoms or systemic infections. He underwent 4 additional prostate biopsies, with histopathology on all showing only benign tissue with glandular hyperplasia and chronic inflammation. He also had multiple additional cystoscopies and magnetic resonance imaging scans demonstrating prostatic hypertrophy without any evidence of malignancy. Approximately 3 years into this course, he was evaluated by a urologist for his persistently elevated PSA, and although he was asymptomatic, he was treated with levofloxacin for 1 month for chronic prostatitis based on his biopsies and elevated PSA, but had no clinical improvement.

Two years prior to our encounter, he presented to the emergency department with left testicular swelling without pain or any urinary symptoms. Scrotal ultrasound showed left-sided epididymo-orchitis. Urinalysis showed pyuria (>100 WBC/hpf), but routine aerobic culture was negative (urine Gram stain was not performed). He was treated with oral ciprofloxacin for 14 days, and his symptoms resolved. A post-treatment urinalysis was normal. He remained symptom-free for almost 2 years until he again developed swelling of his left testicle with mild pain but without dysuria or urinary frequency. At this time, his dipstick urinalysis was negative, and after evaluation by his primary care doctor, he was treated for epididymitis with oral ciprofloxacin for 10 days. His symptoms improved, but 2 weeks after treatment was stopped, he developed recurrent pyuria and microscopic hematuria. Several weeks after this

Received 20 November 2017; editorial decision 2 January 2018; accepted 24 January 2018.

Correspondence: L. Horton, M.D., M.P.H., University of California, San Diego Division of Infectious Diseases, 9500 Gilman Drive #0711 La Jolla, CA 92093-0711 (lhorton@ucsd.edu).

Open Forum Infectious Diseases®

© The Author(s) 2018. Published by Oxford University Press on behalf of Infectious Diseases Society of America. This is an Open Access article distributed under the terms of the Creative Commons Attribution-NonCommercial-NoDerivs licence (<http://creativecommons.org/licenses/by-nc-nd/4.0/>), which permits non-commercial reproduction and distribution of the work, in any medium, provided the original work is not altered or transformed in any way, and that the work is properly cited. For commercial re-use, please contact journals.permissions@oup.com
DOI: 10.1093/ofid/ofy015

episode, his PSA increased from his baseline of 12 ng/mL to 21 ng/mL, but returned to 12 ng/mL 2 months later. He denied any prior history of sexually transmitted infections and has not been sexually active for several years. He works as a building contractor and stated that each episode of epididymitis had started shortly after he lifted a heavy object.

During our evaluation in the infectious diseases clinic, he was asymptomatic, but a urine culture obtained after prostatic massage yielded a heavy growth of bacteria that was misidentified as *Gardnerella vaginalis* based on Gram stain, colony appearance, slow growth, and a positive hippurate test. He was not treated for this organism, and when he returned 1 month later for his scheduled follow-up, he was having another recurrence of left-sided epididymitis with a swollen, erythematous testicle and urinary urgency, but without fevers or other symptoms of a systemic infection. This episode also began after he lifted a heavy object. Urinalysis showed many white blood cells, pH 8, and negative nitrites. The Gram stain of urine showed small pleomorphic Gram-positive rods, and the culture again grew an organism that appeared to be *Gardnerella*, so he was started on oral metronidazole and azithromycin. Ultrasound of the scrotum showed a mass-like enlargement of the left epididymis tail with cystic changes and calcifications compatible with chronic epididymitis with abscess formation (Figure 1A).

At this time, an anaerobic urine culture was ordered because *Gardnerella* is reported to grow better anaerobically, and indeed the growth anaerobically was faster and more abundant. However, the VITEK 2 anaerobic card identified the organism as *Actinobaculum schaalii* (renamed *Actinotignum schaalii*), and MALDI-TOF analysis (Bruker, Billerica, MA) confirmed it as *A. schaalii*. Although there are no Clinical and Laboratory Standards Institute standards for interpreting results, disk sensitivity testing showed apparent sensitivity to penicillin and tetracycline, but resistance to ciprofloxacin and

erythromycin (although testing was done in a 5% carbon dioxide environment, which may have decreased that drug's activity). He was switched to doxycycline 100 mg twice daily and treated for an additional 4 weeks, to complete a 6-week course. He has remained asymptomatic for 6 months after completing his treatment, with a normal urinalysis and sterile anaerobic urine culture. Follow-up ultrasound examinations were done after treatment, and although they were improved and he was asymptomatic, the scans remained abnormal until 5 months after the end of treatment (Figure 1B).

After the diagnosis was confirmed, paraffin-embedded tissue blocks from the most recent prostate biopsy in 2014 were sent for 16s DNA analysis but were negative for bacterial DNA.

DISCUSSION

A. schaalii is considered a commensal bacterium of the genitourinary tract, but is now recognized to be a cause of symptomatic UTIs and occasionally associated bacteremia [3, 4]. Recently the full genome of this bacterium was sequenced and showed genes encoding attachment pili, which could allow for urothelial colonization [8]. Studies on the prevalence of *Actinotignum* found that the bacterium was present in the urine of healthy patients, suggesting it is part of the urinary flora. Additional studies using polymerase chain reaction analysis identified *Actinotignum* on skin in the groin region of men and in vaginal swabs, but not in fecal samples, indicating it is unlikely to be a bowel flora but rather a part of the urogenital flora [7]. However, most of the samples tested in these studies came from patients with urological disorders, and none excluded chronic prostatitis as the source of *A. schaalii*. We believe that this case illustrates that this organism can cause chronic prostatitis, and that under some circumstances it can also be a cause of epididymitis. In this case, we hypothesize that the individual had reflux of infected urine down his vas deferens into his epididymis [9] when he did a Valsalva maneuver while lifting a heavy object.

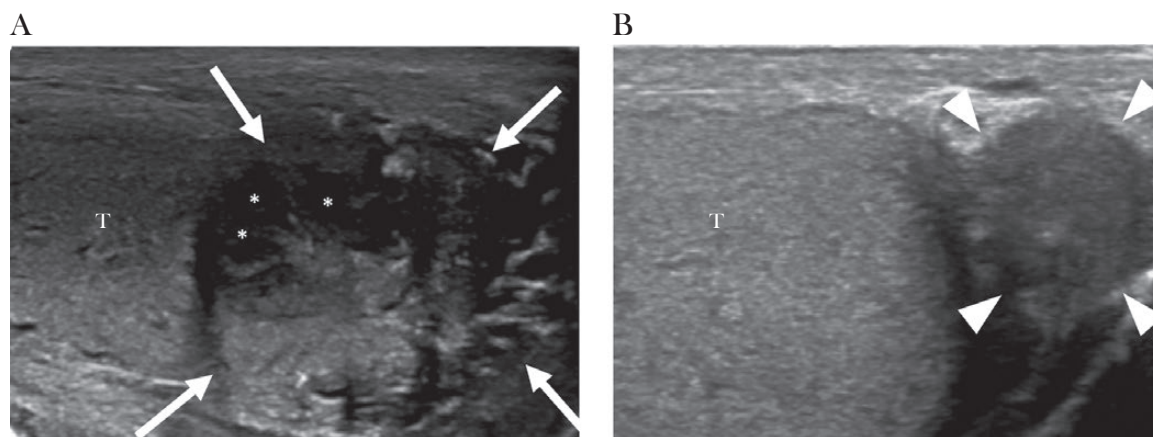


Figure 1. (A) Initial ultrasound image demonstrates enlarged and heterogeneous epididymal tail consistent with epididymitis (arrows). Several hypoechoic areas are also present (asterisks), consistent with abscesses. Doppler image showed increased vascularity of the left epididymal tail (not shown). Abbreviation: T, testis. (B) Follow-up ultrasound 6 months later demonstrates resolution of previous findings with a normal-appearing epididymal tail (arrowheads).

It is unlikely that *A. schaalii* is truly an emerging pathogen; more likely, we are better at growing and identifying it. It is very likely that the incidence of this infection is underestimated, as incubation of urine cultures in a 5% CO₂ atmosphere is not recommended [10]. Even if urines are cultured in the permissive atmosphere, this organism is unlikely to grow in 48 hours, the usual time allotted for incubating urine cultures in the United States. Thus, this organism may be another cause of “sterile” pyuria or, as in this case, of sterile epididymo-orchitis. Patients with recurrent sterile pyuria, particularly elderly patients, or those with a predisposing urogenital condition (including benign prostatic hyperplasia, catheterization, neurologic bladder, and atypical genitourinary anatomy predisposing to reflux) should have a urine sample sent for Gram stain and anaerobic culture if routine cultures are sterile and the laboratory does not incubate urine cultures in a 5% CO₂ atmosphere. MALDI-TOF is a reliable technology to identify *A. schaalii* [11]. The VITEK 2 anaerobic card also identified this isolate, but more studies are needed to determine its accuracy, and it is not standard to use an anaerobic card to identify a nonanaerobic organism. Making the correct identification is important because the organism is resistant to co-trimoxazole and fluoroquinolones, 2 drugs that are commonly given as empiric therapy for urinary tract infections. Typically, 2 weeks of treatment with β-lactams seems to be effective unless the patient has chronic prostatitis; then 4–6 weeks of treatment with an antibiotic that crosses the blood-prostate barrier is recommended [12].

Acknowledgements

We thank the staff of the VA San Diego Microbiology Laboratory.

References

1. Lawson PA, Falsen E, Akervall E, et al. Characterization of some *Actinomyces*-like isolates from human clinical specimens: reclassification of *Actinomyces suis* (Soltys and Spratling) as *Actinobaculum suis* comb. nov. and description of *Actinobaculum schaalii* sp. nov. *Int J Syst Bacteriol* **1997**; 47:899–903.
2. Cattoir V, Varca A, Greub G, et al. *In vitro* susceptibility of *Actinobaculum schaalii* to 12 antimicrobial agents and molecular analysis of fluoroquinolone resistance. *J Antimicrob Chemother* **2010**; 65:2514–7.
3. Lotte R, Lotte L, Ruimy R. *Actinotignum schaalii* (formerly *Actinobaculum schaalii*): a newly recognized pathogen—review of the literature. *Clin Microbiol Infect* **2016**; 22:28–36.
4. Lotte L, Lotte R, Durand M, et al. Infections related to *Actinotignum schaalii* (formerly *Actinobaculum schaalii*): a 3-year prospective observational study on 50 cases. *Clin Microbiol Infect* **2016**; 22:388–90.
5. Tsudin-Sutter S, Frel R, Weisser M, et al. *Actinobaculum schaalii* - invasive pathogen or innocent bystander? A retrospective observational study. *BMC Infect Dis* **2011**; 11:289.
6. Pedersen H, Senneby E, Rasmussen M. Clinical and microbiological features of *Actinotignum bacteremia*: a retrospective observational study of 57 cases. *Eur J Clin Microbiol Infect Dis* **2017**; 36:791–6.
7. Olsen AB, Andersen PK, Bank S, et al. *Actinobaculum schaalii*, a commensal of the urogenital area. *BJU Int* **2013**; 112:394–7.
8. Kristiansen R, Dueholm MS, Bank S, et al. Complete genome sequence of *Actinobaculum schaalii* strain CCUG 27420. *Genome Announc* **2014**; 2:e00880–14.
9. Badenoch AW. Vaso-epididymal reflux syndrome. *Proc R Soc Med* **1953**; 46:847–9.
10. Amy L. Leber, ed. *Clinical Microbiology Procedures*. Vol. 1. 4th ed. Chapter 3.12.14. Washington, DC: ASM Press; **2014**.
11. Stevens RP, Taylor PC. *Actinotignum* (formerly *Actinobaculum*) *schaalii*: a review of MALDI-TOF for identification of clinical isolates, and a proposed method for presumptive phenotypic identification. *Pathology* **2016**; 48:367–71.
12. Meares EM Jr. Prostatitis: review of pharmacokinetics and therapy. *Rev Infect Dis* **1982**; 4:475–83.