

All-Inside Anterior Cruciate Ligament Reconstruction as a Salvage for Small or Attenuated Hamstring Grafts



LCDR Patrick E. Jones, M.D., and LCDR Dustin J. Schuett, D.O.

Abstract: Anterior cruciate ligament (ACL) tears represent one of the most common sports-related injuries in the young population. There are multiple studies showing higher failure rates in the younger population with an allograft supporting the routine use of an autograft. In addition, higher failure rates have been shown with grafts narrower than 8 mm in diameter. This places the surgeon in an operative dilemma determining what to do with a narrow graft or an attenuated hamstring during harvest. All-inside ACL reconstruction is a promising technique for reliably creating sufficiently wide grafts without the need for allograft augmentation. The purpose of this Technical Note is to detail a graft preparation using the all-inside technique as a bailout during hamstring autograft ACL when the graft is narrow or one of the tendons is attenuated during harvest.

Anterior cruciate ligament (ACL) reconstruction remains one of those most common orthopaedic procedures in the young population.¹ The use of an allograft in these patients is controversial with several studies showing good success but many showing higher failure rates. Based on recent literature, it would appear that for young patients, an autograft, specifically an autograft with a diameter of 8 mm and more, is associated with fewer graft failures. The majority of surgeons routinely use an autograft for ACL reconstruction in young patients.²⁻⁴ The question for many surgeons in this situation is what to do if the harvested hamstring autograft once prepared for implantation is narrower than 8 mm or if there is a complication with the tendon harvest resulting in a short or truncated tendon. Traditionally, in these settings the autograft is augmented with an allograft. However, several recent

studies have shown an increase in retear rates in autografts augmented with an allograft as compared with smaller autografts without augmentation.^{5,6}

All-inside ACL reconstruction, as initially described by Lubowitz et al.,^{7,8} is becoming more common as a form of soft tissue ACL recon given its ability to generate larger grafts.

In addition, all-inside ACL reconstruction patients have reported lower postoperative pain compared with traditional soft tissue ACL reconstruction with no difference in measured outcomes, making all-inside a very favorable graft option.⁹

This Technical Note presents a unique method of preparing an ACL graft that can be used in the setting of small hamstrings or a truncated hamstring during harvest. This method allows easy conversion from a traditional doubled-over hamstring autograft prep (using semitendinosus and gracilis) to a quadrupled hamstring tendon graft incorporating both harvested tendons for added graft width. This technique requires minimal additional equipment and can save the need for augmentation with an allograft or need to harvest an additional graft from another site.

Surgical Technique

The setup for this procedure is like a standard ACL using either a regular operating room table with a lateral post or an arthroscopic leg holder. The leg is prepped and a standard tibial incision is made midway between the tibial tubercle and medial border of the tibia. The hamstring tendons are identified beneath the sartorial fascia elevated from the tibia and harvested with a closed tendon stripper. The tendons are cleaned

From the Department of Orthopaedic Surgery, United States Naval Hospital Okinawa, FPO, Armed Forces Pacific, U.S.A.

The authors report that they have no conflicts of interest in the authorship and publication of this article. Full ICMJE author disclosure forms are available for this article online, as [supplementary material](#).

The views expressed in this article are those of the authors and do not necessarily reflect the official policy or position of the Department of the Navy, Department of Defense, or the U.S. Government.

Received October 23, 2017; accepted November 20, 2017.

Address correspondence to LCDR Patrick E. Jones, M.D., Naval Hospital Okinawa, PSC 482 box 1600, FPO, Armed Forces Pacific 96362, U.S.A. E-mail: patrick.e.jones34.mil@mail.mil

Published by Elsevier on behalf of the Arthroscopy Association of North America. This is an open access article under the CC BY-NC-ND license (<http://creativecommons.org/licenses/by-nc-nd/4.0/>).

2212-6287/171302

<https://doi.org/10.1016/j.eats.2017.11.007>

Table 1. Steps for Graft Prep

1. The 2 tendons are cleaned of muscle, and both ends are whipstitched
2. The longer of the 2 tendons is passed through the no-button tightrope and the free ends are passed in opposite directions through the femoral tightrope
3. Pass the stitched ends of the tendon through the middle of the tendon on either side of the no-button tightrope using a free needle
4. Size the shorter tendon to the length of the quadrupled tendon by wrapping it around. Making this tendon too long can inhibit your ability to tension the graft. Cut the shorter tendon to the length of the quadrupled tendon and whipstitch the cut end
5. Place the short tendon inside the quadrupled tendon passing through the femoral tightrope loop
6. The free ends of the short tendon are then passed through the quadrupled tendon on either side of the no-button tightrope next to where the quadrupled tendon free ends had been passed in step 3
7. Place the graft on stretch while holding the suture tails; at this point, individually tension the tails to bring them down to dock inside the quadrupled graft and secure them around the graft station post
8. Using a No. 2 fiberwire or other high-strength nonabsorbable suture, place 4 circumferential cerclage stitches around the graft starting inside the graft and making sure that the needle passes through every strand of the tendon
9. Care should be taken to bury the knot inside the graft per previously described technique guides
10. Once graft prep is completed, ACL reconstruction can proceed as previously described for all-inside ACL reconstruction

ACL, anterior cruciate ligament.

and doubled over. If the graft width is 8 mm or greater, a standard ACL using tibial interference screw fixation and an ACL tightrope (Arthrex, Naples, FL) for femoral fixation is performed. An all-inside technique is performed if the grafts are less than 8 mm when doubled over. This can also be used if one of the grafts attenuates during harvest and sufficient length is not possible to double over and obtain interference fixation.

Graft Preparation

A graft prep station assists with the graft preparation and tensioning of the graft construct. A Tightrope RT (Arthrex) loop is used for fixation on the femoral side and a no-button tightrope loop (Arthrex) is used on the tibial side (Table 1). To start, the tendons are cleaned of any muscle and both ends of the tendon are whipstitched (Fig 1). The longer of the 2 tendons is passed through the no-button tightrope and brought through the Tightrope RT in opposite directions creating a quadrupled hamstring graft (Fig 2). The ideal length is 75 mm of this quadrupled graft that allows for 30-mm graft inside the knee and 45 mm of graft for combined femoral and tibial ingrowth. However, a shorter graft can be used with adjustments made to the depth of the femoral and tibial sockets. The free tails are then passed through the tibial end of the graft using a free needle that effectively tucks the tails inside the graft bundle

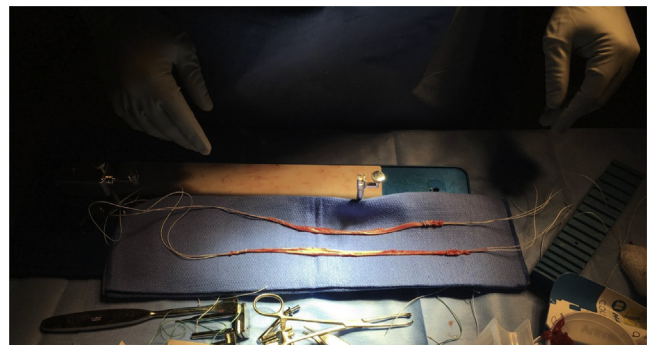


Fig 1. Gracilis and semitendinosus tendons have been harvested; their doubled-over width is 7 mm. The ends of both tendons have been whipstitched.

(Fig 3). Next, the remaining tendon is doubled over and sized to match the length of the quadrupled tendon. The extra length of the tendon is then removed from the end of the tendon toward the musculotendinous junction that tends to be less robust than the insertion (Fig 4). The ends are whipstitched, and the doubled-over tendon is placed inside the quadrupled graft with the whipstitch tails placed through the tibial end of the graft with care taken not to tether the suture components of the no-button tightrope (Figs 5 and 6). The quadrupled graft is then tensioned through the Tightrope RT and the attachable button system tightrope, and the tails of the whipstitches are tensioned independently and secured (Fig 7). Next, the multiple bundles of tendon are secured using 4 cerclage stitches placed 10 mm and 20 mm, respectively, from the ends of the graft. This task is made easier by placing an Addson forceps through the middle of the graft into the graft prep station to prevent graft rotation and improve visualization of the middle of the graft (Fig 8). It is important that the cerclage stitches pass through every limb of the tendon. The knots are buried inside the graft bundle, as described in the all-inside technique guides

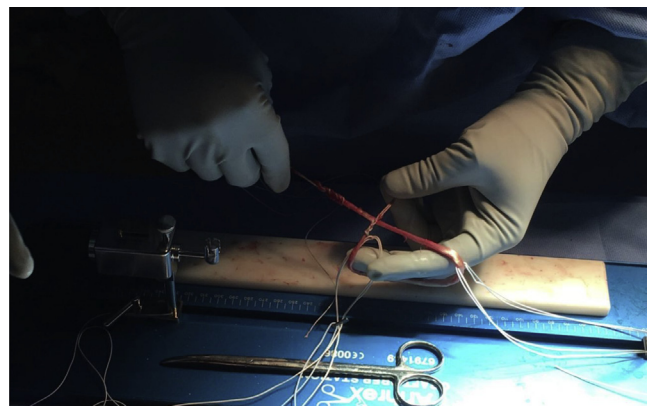

Fig 2. The longer of the 2 tendons is passed through the no-button tightrope and the stitched ends are passed in opposite directions through the femoral tightrope loop.

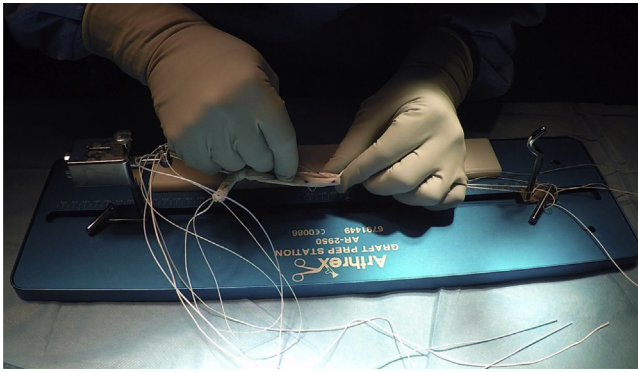


Fig 3. The stitched ends are passed through the tibial side of the tendon on either side of the no-button tightrope using a free needle.

and by Lubowitz et al.⁷ The resulting graft should have the short strand of tendon encapsulated inside the quadrupled graft (Fig 9). Video 1 further shows all steps of this preparation technique using an allograft tendon; however, this technique would primarily be used with an autograft in the situations outlined above.

ACL Reconstruction

All-inside ACL reconstruction is performed in the technique described by Lubowitz.^{7,8} The femoral socket can be drilled using a flip cutter (Arthrex) or using an accessory medial portal. The tibial tunnel is made using a flip cutter. Passing stitches are placed through the femoral and tibial socket and retrieved from inside the joint and brought out through the medial portal to ensure that there is no soft tissue bridge. The medial portal is slightly enlarged to facilitate graft passage. The Tightrope RT is then drawn into the femoral socket, and the button is flipped on the lateral cortex of the femur. The tensioning sutures are toggled to draw the graft into

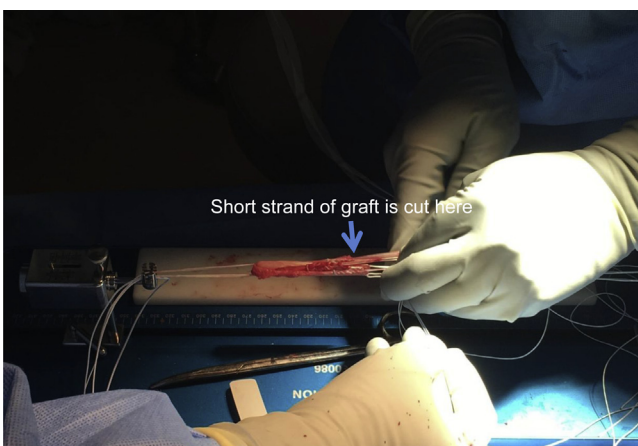

Fig 4. The shorter tendon is wrapped around the quadrupled tendon and marked to the length of the quadrupled tendon, as shown with the blue arrow. The tendon is then cut and re-whipstitched at that level.




Fig 5. The short tendon is placed inside the quadrupled tendon.

the femoral socket and secured. The no-button tightrope and whipstitch tails are then passed through the tibial socket using the passing suture. The sutures are tensioned and the graft is docked into the tibial tunnel. At this point, the graft is cycled several times. The attachable button system is then placed on the no-button tightrope, and the 2 ends are alternatively tightened to close down the loop and tension the graft; this is performed with the knee in full extension and a posterior drawer force. The whipstitch tails are also placed into the button outside the strands of the no-button loop and tied over top after final tensioning of the no-button loop.

Backup Fixation

Lastly, the ends of the whipstitches are placed into a 4.75-mm swivel-lock (Arthrex) as backup fixation; this step also helps lay the knot down against the tibia creating less bulk. Once the ACL graft has been secured and final tensioning on the femoral and tibial sides completed and appropriate graft tension has been confirmed, a point is marked 1.5 cm distal to the tibial tunnel on the medial face of the tibia. A 4.5-mm drill bit is then used to make a unicortical hole to at least a

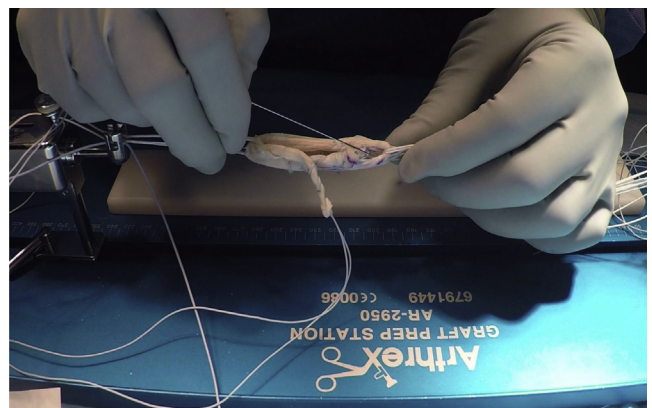


Fig 6. The short tendon stitches are passed through the end of the quadrupled tendon on either side of the no-button tightrope and next to the stitches for the quadrupled tendon.

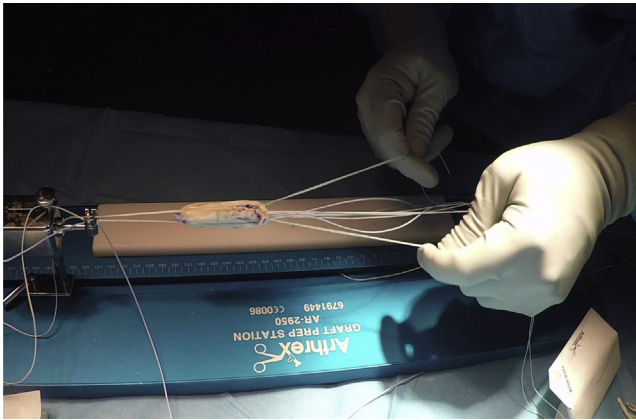


Fig 7. The strands can be independently tensioned and the graft put on stretch.

depth of 20 mm. Afterward, the hole is taped and the suture ends are placed into a 4.75-mm biocomposite swivel lock; the anchor is placed into the hole and all strands are independently tensioned to remove slack. The swivel-lock is then advanced providing backup fixation for the tails of the graft and drawing the knot down onto the tibia decreasing implant prominence.

Postoperatively, patients are allowed to weight bear as tolerated with crutches for assistance. They are maintained in full leg extension in a brace until they can perform a straight leg raise. Range of motion is emphasized for first 6 weeks with strengthening to follow. Return to running is allowed at 3 months and return to sport is allowed at 6 to 9 months after surgery.

Discussion

Numerous graft options exist for ACL reconstruction with the hamstring autograft being one of the more common methods particularly in young patients. Predicting which patients will have inadequate hamstrings is notoriously challenging. Xie et al.¹⁰ noted that




Fig 8. Using a No. 2 fiberwire or other high strength nonabsorbable suture, 4 circumferential cerclage stitches are placed around the graft starting inside the graft and making sure that the needle passes through every strand of the tendon.

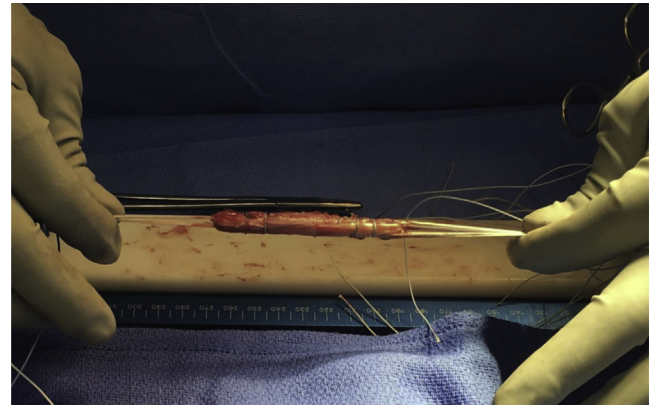


Fig 9. The completed graft has 4 cerclage stitches at 10 and 20 mm from either end of the graft. The shorter tendon is enshrouded in the quadrupled tendon providing a tight graft that should pass easily into the tunnels.

females with body mass index less than 20, height less than 170 cm (5 foot 7 inches), and weighing less than 57.4 kg (126 lbs) are at highest risk of having a doubled-over semitendinosus and gracilis tendon width smaller than 7 mm. Despite this, it remains difficult to accurately predict which patients will have small tendons and near impossible to predict which patients will have a complication during graft harvest.

The surgeon is then left with the dilemma of what to do with a graft less than 8 mm or a tendon that was attenuated during harvest. At that point, the surgeon can accept a narrow graft, augment the graft with an allograft, and create a hybrid construct or harvest from a different site either the contralateral hamstring or the patella or quadriceps tendon.

Accepting a narrow graft has its own risks as narrow grafts below 8 mm have been well described as a risk for rerupture.^{11,12} Augmentation with an allograft is widely accepted; however, multiple studies have shown increased rerupture rates with allograft hybrids and some have shown poor incorporation of an allograft in a hybrid construct.^{5,6,13,14} Furthermore, allograft is not always readily available depending on the location or supply level of the institution where the ACL reconstruction is being performed. Harvesting from a secondary site conveys additional morbidity to the patient and depending on the chosen graft can require prepping in both legs or reprepping and redrapping, which is not ideal.

Table 2. Advantages and Disadvantages of All-Inside Bailout

Advantages	Disadvantages
<ul style="list-style-type: none"> • Ability to convert narrow grafts into adequate-sized grafts • Does not require additional • Does not require the use of an allograft 	<ul style="list-style-type: none"> • Potential for inconsistent graft tensioning • Graft prep is technically challenging and may require a skilled assistant • Additional time with graft prep can add to overall case time

The technique described in this Technical Note has been used in scenarios where the harvested hamstring tendons measure less than 8 mm and placing a narrow graft was felt not to be in the best interest of the patient. This technique has also been employed when a tendon was attenuated during harvest. Although this is a rare complication, it can happen even in an experienced surgeon's hands.

An advantage of this technique is that it effectively uses both tendons that have presumably already been harvested, rather than disposing of one when converting from a doubled-over hamstring to a quadrupled all-inside graft. The quadrupled tendon and doubled-over tendon can lead to a reliably large-diameter graft. In addition, this technique can use a short tendon (we have effectively incorporated strands as short as 130 mm) as opposed to other techniques for quadrupled hamstring grafts requiring both tendons to be 270 mm in length.¹⁵

The technical challenges of this technique involve independently tensioning the doubled-over tendon and quadrupled tendon so as to not negate the effect of one of them. We typically tension the quadrupled tendon first during prep and then tension the doubled-over tendon and have found that keeping the doubled tendon length a few millimeters shorter than that of the quadrupled tendon allows tensioning without the graft bottoming out on the tibial side of the quadrupled tendon (Table 2).

A limitation of this technique is that graft assembly can be technically challenging and usually requires a second surgeon or skilled assistant for prep. Typically in our institution when this situation is encountered, a second surgeon is called into the room to prepare the graft so the intra-articular diagnostic portion of the surgery as well as notch preparation and addressing any associated meniscal pathology can be completed while the graft is being prepared. In addition, we have found converting from traditional to all-inside ACL reconstruction can add 20 to 30 minutes to the case.

Despite these limitations, this technique provides a rescue option for situations of attenuated graft harvest or narrow hamstring graft width during ACL reconstruction. In situations where an allograft is not available or not desired to salvage a narrow or truncated graft, this technique can produce a graft of adequate width that does not require the added morbidity of additional harvest.

References

- Mall NA, Chalmers PN, Moric M, et al. Incidence and trends of anterior cruciate ligament reconstruction in the United States. *Am J Sports Med* 2014;42:2363-2370.
- Barrett GR, Luber K, Replogle WH, Manley JL. Allograft anterior cruciate ligament reconstruction in the young, active patient: Tegner activity level and failure rate. *Arthroscopy* 2010;26:1593-1601.
- Bottoni CR, Smith EL, Shaha J, et al. Autograft versus allograft anterior cruciate ligament reconstruction: A prospective, randomized clinical study with a minimum 10-year follow-up. *Am J Sports Med* 2015;43:2501-2509.
- McGuire DA, Hendricks SD. Allograft tissue in ACL reconstruction. *Sports Med Arthrosc* 2009;17:224-233.
- Burrus MT, Werner BC, Crow AJ, et al. Increased failure rates after anterior cruciate ligament reconstruction with soft-tissue autograft-allograft hybrid grafts. *Arthroscopy* 2015;31:2342-2351.
- Pennock AT, Ho B, Parvanta K, et al. Does allograft augmentation of small-diameter hamstring autograft ACL grafts reduce the incidence of graft retear? *Am J Sports Med* 2017;45:334-338.
- Lubowitz JH, Ahmad CS, Amhad CH, Anderson K. All-inside anterior cruciate ligament graft-link technique: Second-generation, no-incision anterior cruciate ligament reconstruction. *Arthroscopy* 2011;27:717-727.
- Lubowitz JH. All-inside anterior cruciate ligament graft link: Graft preparation technique. *Arthrosc Tech* 2012;1:e165-e168.
- Lubowitz JH, Schwartzberg R, Smith P. Randomized controlled trial comparing all-inside anterior cruciate ligament reconstruction technique with anterior cruciate ligament reconstruction with a full tibial tunnel. *Arthroscopy* 2013;29:1195-1200.
- Xie G, Huangfu X, Zhao J. Prediction of the graft size of 4-stranded semitendinosus tendon and 4-stranded gracilis tendon for anterior cruciate ligament reconstruction: A Chinese Han patient study. *Am J Sports Med* 2012;40:1161-1166.
- Conte EJ, Hyatt AE, Gatt CJ, Dhawan A. Hamstring autograft size can be predicted and is a potential risk factor for anterior cruciate ligament reconstruction failure. *Arthroscopy* 2014;30:882-890.
- Mariscalco MW, Flanigan DC, Mitchell J, et al. The influence of hamstring autograft size on patient-reported outcomes and risk of revision after anterior cruciate ligament reconstruction: a Multicenter Orthopaedic Outcomes Network (278 MOON) cohort study. *Arthroscopy* 2013;29:1948-1953.
- Darnley JE, Léger-St-Jean B, Pedroza AD, Flanigan DC, Kaeding CC, Magnussen RA. Anterior cruciate ligament reconstruction using a combination of autograft and allograft tendon: A MOON cohort study. *Orthop J Sports Med* 2016;4:2325967116662249.
- Yamakado K, Kitaoka K, Nakamura T, et al. Histologic analysis of the tibial bone tunnel after anterior cruciate ligament reconstruction using solvent-dried and gamma-irradiated fascia lata allograft. *Arthroscopy* 2001;17:32.
- Kern M, Love D, Cotter EJ, Postma W. Quadruple-bundle semitendinosus-gracilis graft technique for all-inside anterior cruciate ligament reconstruction. *Arthrosc Tech* 2016;5:e1317-e1320.