

Received: 2020.03.03


Accepted: 2020.05.20

Available online: 2020.06.17

Published: 2020.08.03

Thymolipoma Association with Myasthenia Gravis: Case Report

Authors' Contribution:

Study Design A
Data Collection B
Statistical Analysis C
Data Interpretation D
Manuscript Preparation E
Literature Search F
Funds Collection GBEF 1 **Sharifah A. Othman**
EF 1 **Othman Y. AlFrayyan**
ACDEF 1 **Zeead M. AlGhamdi**
E 2 **Fahd Makhdom**
E 1 **Yasser AlJehani**
E 1 **Hatem Y. Elbawab**
E 3 **Mohamed El-Shawarby**1 Thoracic Surgery Division, Department of Surgery, King Fahad Hospital of The University, College of Medicine, Imam Abdulrahman Bin Faisal University, Dammam, Eastern Region, Saudi Arabia
2 Cardiac Surgery Division, Department of Surgery, King Fahad Hospital of The University, College of Medicine, Imam Abdulrahman Bin Faisal University, Dammam, Eastern Region, Saudi Arabia
3 Department of Pathology, King Fahad Hospital of The University, College of Medicine, Imam Abdulrahman Bin Faisal University, Dammam, Eastern Region, Saudi Arabia**Corresponding Author:** Zeead M. AlGhamdi, e-mail: zghamdi@iau.edu.sa**Conflict of interest:** None declared**Patient:** Female, 56-year-old
Final Diagnosis: Thymolipoma association with myasthenia gravis
Symptoms: Acute congestive heart failure • asymptomatic thymolipoma
Medication: —
Clinical Procedure: —
Specialty: Surgery**Objective:** Rare co-existence of disease or pathology**Background:** Thymolipoma, which was described initially by Hall in 1949, is an uncommon benign thymic tumor that represents around 9% of all thymic tumors. The incidence of thymolipoma is around 0.12 out of 100 000 cases per year, with a higher incidence in the younger age population. Thymolipoma incidence has been linked to different autoimmune diseases, including myasthenia gravis, in half of the reported cases. There are 34 reported cases in the literatures documenting such a relationship between thymolipoma and myasthenia gravis. The exact pathogenesis is unclear. However, some genetic findings revealed the presence of myoid cells, which might play a vital role in this association.**Case Report:** A 56-years-old female known to have myasthenia gravis presented to the Emergency Department with acute congestive heart failure, atrial fibrillation, and stroke secondary to infected vegetation from the mitral valve. The patient underwent a semi-urgent mitral valve replacement surgery treating her cardiac presentation along with an extended thymectomy to control her myasthenia gravis disease. The final histopathological assessment of the removed thymus revealed a thymolipoma pathology.**Conclusions:** The possibility of thymolipoma as an anterior mediastinal mass should be kept in mind when dealing with an older age group of myasthenia gravis patients on steroids. Concomitant heart surgery and thymectomy are feasible, and extended thymectomy is the treatment of choice for thymolipoma in myasthenia gravis patients with a better complete remission rate after resection. However, further comparative studies are needed for a more reliable conclusion of the postoperative myasthenia gravis response after resection.**MeSH Keywords:** Myasthenia Gravis • Thymectomy • Thymus Gland • Thymus NeoplasmsFull-text PDF: <https://www.amjcaserep.com/abstract/index/idArt/923989>

1127



—



2



8



Background

Thymolipoma, in general, is a slow-growing benign tumor located in the anterior mediastinum. Thymolipoma accounts for 2% to 9% of all thymic tumors. The majority are asymptomatic and diagnosed incidentally. Histologically, it combines a normal thymic tissue with mature adipose tissue. Half of the reported cases showed an association with variant autoimmune diseases such as myasthenia gravis, aplastic anemia, hypogammaglobulinemia, lichen planus, and Graves' disease [1]. Only 34 cases reported the association of thymolipoma and myasthenia gravis worldwide. Herein, we present a case of a female who is known to have myasthenia gravis who presented to the Emergency Department (ED) with acute congestive heart failure and was diagnosed with a thymolipoma after a concomitant surgical intervention for mitral valve replacement and an extended thymectomy.

Case Report

A 56-years-old female was known to have hypertension, antiphospholipid syndrome, epilepsy, and myasthenia gravis for the last 18 years. Her myasthenia gravis diagnosis and disease management occurred in another hospital. The patient presented to the ED with acute congestive heart failure, infective endocarditis, and severe mitral valve regurgitation secondary to infected vegetation. She was admitted to the Cardiac Care Unit (CCU) at our hospital for semi-urgent mitral valve surgery, and we were involved at this stage to evaluate the possibility of concomitant myasthenia gravis surgical management utilizing the sternotomy access for mitral valve replacement. Her history revealed bulbar symptoms in the form of swallowing difficulty initially, which progressed later to generalized muscle weakness. Her symptoms were relatively controlled on azathioprine, pyridostigmine, and corticosteroids. Her myasthenia gravis symptoms became worse with this acute cardiac presentation, and we classified her clinically as moderate weakness with stage IIIA according to the Myasthenia Gravis Foundation of America (MGFA). Her acetylcholine receptor (AChR) antibody test was positive, and the preoperative chest x-ray showed no precise mediastinal mass. Unfortunately, the patient developed respiratory distress secondary to heart failure, which required intubation. For that reason, the requested enhanced-contrast chest computed tomography (CT) scan was canceled. Her echocardiogram performed and showed an ejection fraction of 59%. The patient's consent for both procedures was obtained. First, we performed a median sternotomy approaching the thymus. Localized thymoma measuring 2×2 cm in the left lower horn was noticed, and a complete extended thymectomy was achieved (Figure 1). After thymectomy, the cardiac surgeon successfully replaced the mitral valve. The patient returned to CCU in stable condition. The thymus

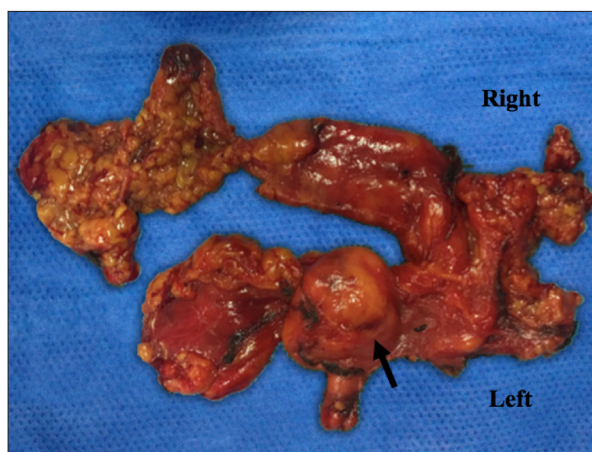


Figure 1. Gross appearance of completely resected thymus showing 2×2 cm size of well-demarcated thymolipoma lesion within the left lower horn of the thymus (arrows).

gland weight was 40 g, and the left lobe size was 7×3×1.5 cm, while the right lobe was 9×3×1.8 cm. The histopathological examination disclosed thymic gland tissues within an abundant mature adipose tissue, consistent with thymolipoma with no evidence of thymic hyperplasia or malignancy (Figure 2). The postoperative course was uneventful, and she was transferred to the regular ward on day 15 postoperatively. She was discharged in excellent condition.

Discussion

Alternative thymic gland pathological changes have been encountered in patients with myasthenia gravis disease such as thymoma, thymolipoma, thymic follicular hyperplasia, and thymic atrophy. Thymolipoma is one of the benign thymic tumors. The first thymolipoma description in the literature was in 1916 by Lange. Since then, multiple reports describing this rare tumor have been published. Thymolipoma accounts for approximately 2% to 9% of all thymic tumors with an incidence of 0.12 out of 100 000 cases per year at any age without apparent gender preferences [2]. The large amount of mature fat is separating the thymic tissue in thymolipoma without any mitotic activity or atypia. Although numerous theories have been suggested concerning the pathogenesis of thymolipoma, the precise answer is not available, and the discussion is still controversial. The most engaging theory for us is that first, thymolipoma represents a neoplasm of the thymic fat with involuting thymic remnants. Second is the hyperplasia theory that proposes diffuse thymic enlargement replaced by fatty tissue [3].

Recently, long-term use of steroids thought to have a role in fatty degeneration of thymomas, which stimulates the transformation from thymoma to thymolipoma. Chien et al. observed

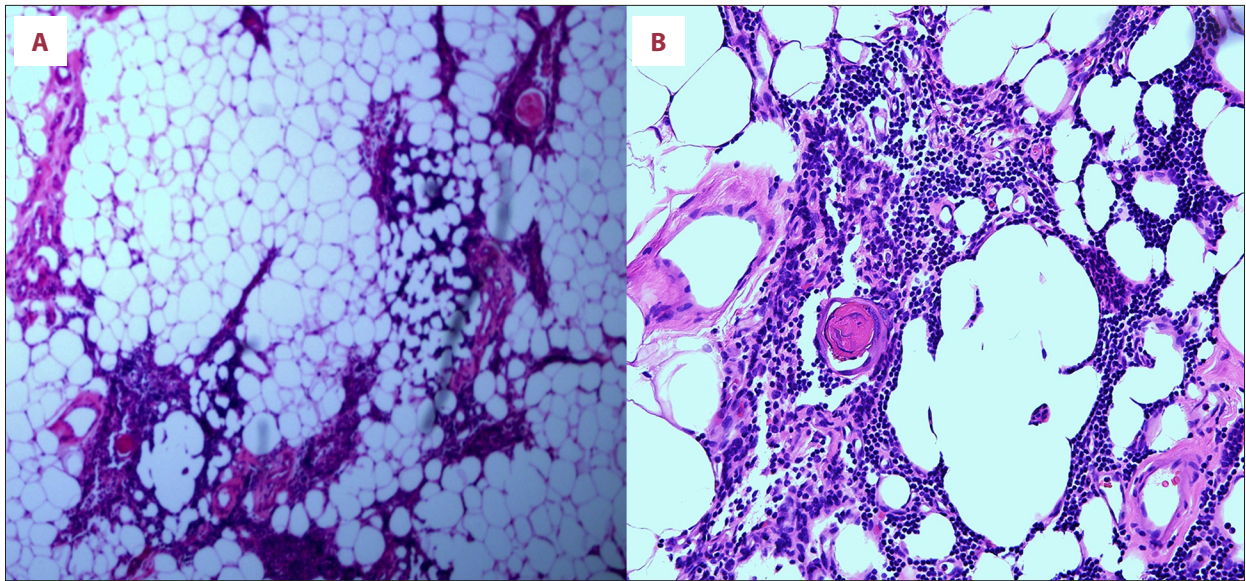


Figure 2. Hematoxylin and eosin stained section showing scattered variably sized islands of unremarkable thymic tissue within abundant mature adipose tissue. (A) Original magnification 40x. (B) Original magnification 200x.

the presence of thymolipoma in 10 out of 12 patients (83.3%) who received steroid preoperatively to control myasthenic symptoms compared to 28 out of 104 patients (26.9%) in a thymomatous myasthenia gravis group [2]. The prevalence of thymolipoma-myasthenia gravis association is more in the older age group with less tumor weight compared to thymolipoma alone, which tends to be more prevalent in younger age groups with weight often more than 1 kg [1].

The number of reported thymolipoma-myasthenia gravis association cases varies considerably in the literature from 2.8% to a maximum of 50%. The underlying pathogenesis of this association is still unclear. The exact cause of this association is not yet understood, however, obtaining a better understanding with further studies about the relation between the presence of thymic myoid cells and this alternation in myasthenia gravis patients is highly recommended as some of the theories suggested the presence of thymic myoid cells as a stimulus to the autoimmune response in myasthenia gravis patients [3,4].

Usually, thymolipoma patients are asymptomatic in 30% to 50% of the cases, and the tumors were discovered incidentally. When the size of the tumor is large, the compression symptoms may happen, including cough, dyspnea, chest pain, hoarseness, and cyanosis [1]. Chest computer tomography (CT) scan and magnetic resonance imaging (MRI) are the diagnostic radiological methods of mediastinal masses. In thymolipoma, a CT scan seldom reveals a mixture of soft tissue and fat [5]. Nevertheless, confirmation of the diagnosis can only be reached by histology evaluation either through CT guided fine needle aspiration cytology (FNAC) or principally after a complete surgical removal [2,6].

Surgical treatment of thymolipoma involves complete excision, which is usually curative, making the long-term follow up for a benign tumor unnecessary. However, for myasthenia gravis patients, extended thymectomy is the option to increase the chance of complete remission or improvement [1]. The outcomes of thymectomy in myasthenia gravis, in general, is more beneficial in non-thymomatous, young patients (<35 years old), with shorter preoperative symptoms (<24 months) [7]. With the difficulties in assessing the response of myasthenia gravis after thymectomy overall and more precisely in the rare thymolipoma-myasthenia gravis association, no reliable conclusion can be stated regarding the outcome after thymectomy. However, the only study compared the remission rate of myasthenia gravis after extended thymectomy for thymomatous, non-thymomatous, and thymolipoma groups concluded that the thymomatous group had a significantly lower complete remission rate [2].

Conclusions

In conclusion, thymolipoma is an uncommon benign thymic lesion, and its association with autoimmune myasthenia gravis disease is extremely rare. The diagnosis of thymolipoma should be kept in mind when dealing with older patients who received steroids preoperatively. Extended thymectomy is the surgical treatment of choice in this association for better disease control. However, the complete remission rate of myasthenia gravis symptoms needs further studies for a reliable conclusion.

Conflicts of interest

None.

References:

1. Rieker R, Schirmacher P, Schnabel P et al: Thymolipoma. A report of nine cases, with emphasis on its association with myasthenia gravis. *Surg Today*, 2010; 40(2): 132–36
2. Huang C, Li W, Lee P et al: Analysis of outcomes following surgical treatment of thymolipomatous myasthenia gravis: Comparison with thymomatous and non-thymomatous myasthenia gravis. *Interact Cardiovasc Thorac Surg*, 2013; 18(4): 475–81
3. Hayashi A, Takamori S, Tayama K et al: Thymolipoma: Clinical and pathological features. report of three cases and review of literature. *Kurume Med J*, 1997; 44(2): 141–46
4. Damadoglu E, Salturk C, Takir H et al: Mediastinal thymolipoma: An analysis of 10 cases. *Respirology*, 2007; 12(6): 924–27
5. Faerber EN, Balsara RK, Schidlow DV et al: Thymolipoma: Computed tomographic appearances. *Pediatr Radiol*, 1990; 20(3): 196–97
6. Shin HJ, Katz RL: Thymic neoplasia as represented by fine needle aspiration biopsy of anterior mediastinal masses. A practical approach to the differential diagnosis. *Acta Cytol*, 1998; 42: 855–64
7. Huang C, Hsu H, Huang B et al: Factors influencing the outcome of transsternal thymectomy for myasthenia gravis. *Acta Neurol Scand*, 2005; 112(2): 108–14
8. Huang C, Cheng C, Hsu H et al: Video-assisted thoracoscopic surgery versus sternotomy in treating myasthenia gravis: Comparison by a case-matched study. *Surg Today*, 2011; 41(3): 338–45