

# An Elderly Case of Acute Cerebellitis after Alleged Vaccination

**Kang Min Park**

**Si Eun Kim**

**Sung Eun Kim**

Department of Neurology,  
Inje University College of Medicine,  
Haeundae Paik Hospital, Busan, Korea

Acute cerebellitis (AC) is a benign and self-limiting inflammatory disease. It typically occurs as a primary infectious or post-infectious disorder. Although AC mostly presents in early childhood, it can appear in adult. A 66-year-old man admitted to our hospital because of limb and gait ataxia. Three weeks ago, he took an influenza vaccination. There was no abnormality on brain MRI with contrast enhancement, but Technetium-99m hexamethyl propylene amine oxime-single photon emission computed tomography (HMPAO-SPECT) showed markedly cerebellar asymmetry, suggesting hypoperfusion in the right cerebellum. Influenza vaccination can cause AC in the elderly and brain HMPAO-SPECT imaging is more useful than MRI in identifying patients with AC. **Journal of Movement Disorders 2012;5:21-23**

**Key Words:** Cerebellitis, Influenza, Vaccination.

Acute cerebellitis (AC) is a benign and self-limiting inflammatory disease. It typically occurs as a primary infectious or post-infectious disorder. Although AC mostly presents in early childhood, it can appear in adult. AC may follow immunizations such as hepatitis, smallpox, and measles vaccination.<sup>1</sup> To our knowledge, there is no report of AC after influenza vaccination in the elderly. We report an elderly case of AC after alleged influenza vaccination.

## Case

A 66-year-old man admitted to our hospital because of limb and gait ataxia. Three weeks ago, he took an influenza vaccination. He developed fever and confusion for several hours after vaccination. He was symptomatically treated under a diagnosis of acute encephalitis at other hospital. His mental status had been improved slowly, but he developed limb and gait ataxia.

He had no history of any medical or neurological illness. Vital sign was stable at admission. On the neurological examination at admission, he was alert and well oriented. Cranial nerve examination was normal with no nystagmus. Motor and sensory examinations revealed no abnormality. Deep tendon reflexes were normal and Babinski's sign was absent. Cerebellar function test showed remarkable dysmetria and dysdiadochokinesia especially, in the left upper and lower extremities. Gait ataxia was severe enough for him not to walk by himself.

Laboratory studies including electrolyte profile and liver function tests were within normal limits except for slightly elevated aspartate aminotransferase (47 IU/L) and alanine aminotransferase (92 IU/L). An erythrocyte sedimentation rate (24 mm/h) and C-reactive protein (0.89 mg/dL) were slightly increased. The serological tests for detection of Epstein-Barr virus, Varicella-zoster virus, Herpes simplex virus, Cytomegalovirus, and human immunodeficiency virus were normal. Venereal disease research laboratory test for neurosyphilis was also nonreactive. Cerebrospinal fluid examination revealed a cell count of 38 white blood cells with lymphocytes predominant, protein 72 mg/dL, glucose 37 mg/dL (serum glucose 95 mg/dL). There was no abnormality on brain MRI with contrast enhancement. Technetium-99m hexamethyl propylene amine oxime-single photon emission computed tomography (HMPAO-SPECT) showed markedly cerebellar asymmetry, suggesting hypoperfusion in

**Received** April 1, 2012

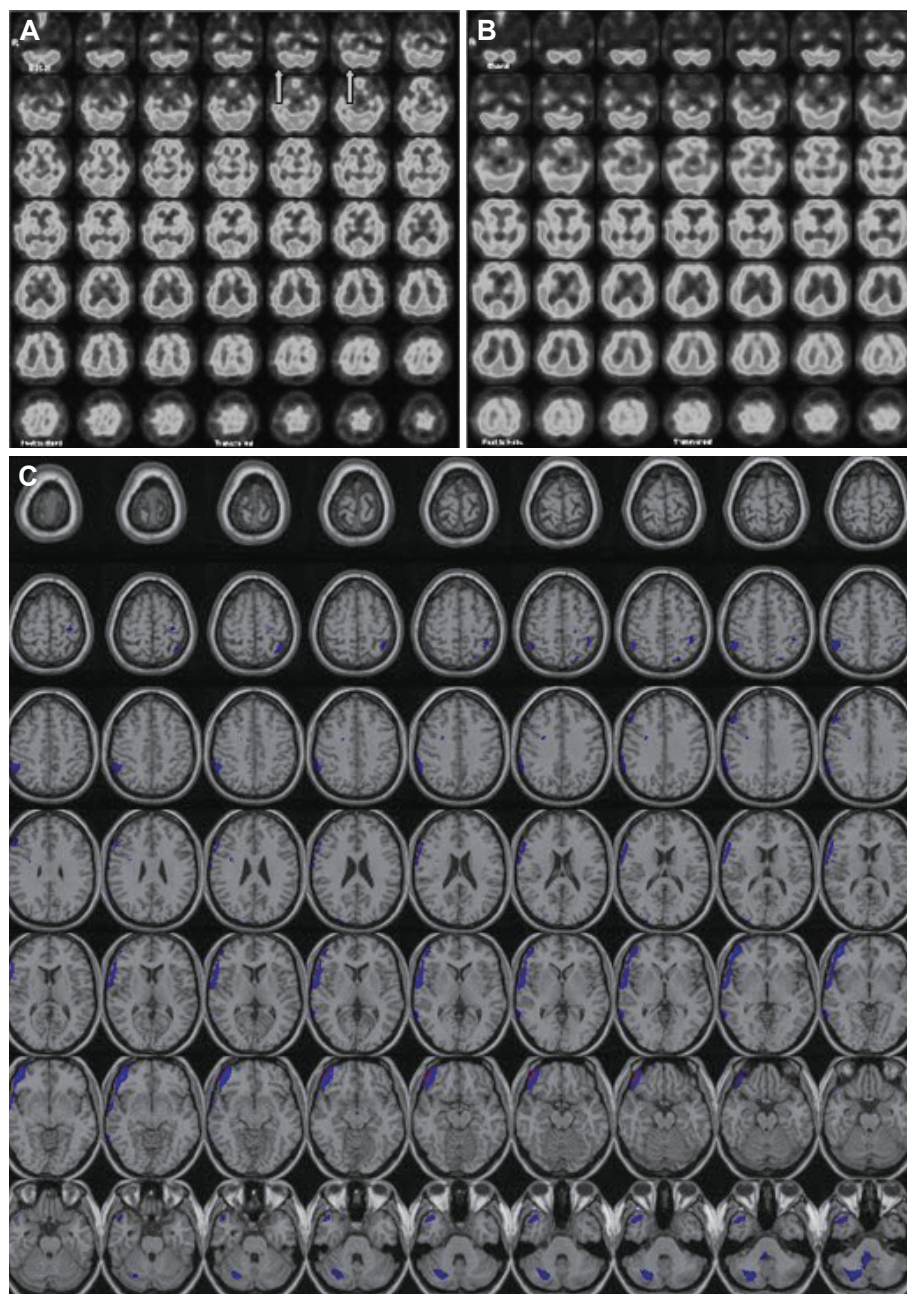
**Revised** April 30, 2012

**Accepted** April 30, 2012

### Corresponding author

Sung Eun Kim, MD, PhD  
Department of Neurology,  
Inje University College of Medicine,  
Haeundae Paik Hospital,  
875 Haeundae-ro, Haeundae-gu,  
Busan 612-030, Korea  
**Tel** +82-51-797-1190  
**Fax** +82-51-797-2080  
**E-mail** epidoc@inje.ac.kr

The authors have no financial conflicts of interest.



**Figure 1.** Tc-99m HMPAO Brain SPECT. Markedly asymmetric perfusion in the cerebellum, suggesting hypoperfusion in the right cerebellum (arrows), is observed on initial SPECT (A). On 4 months later follow up SPECT shows that asymmetric perfusion in the cerebellum is normalized (B). SISCOM images also shows hypoperfusion in the right cerebellum (blue) (C). HMPAO: hexamethyl propylene amine oxime, SPECT: single photon emission computed tomography, SISCOM: subtraction ictal SPECT coregistered to MRI.

the right cerebellum (Figure 1A). He was symptomatically treated with clonazepam, buspirone and piracetam. After 2 months later, he completely recovered. HMPAO-SPECT performed 4 months later demonstrated complete resolution of the cerebellar asymmetry (Figure 1B). We constructed the subtraction ictal SPECT coregistered to MRI (SISCOM) image by subtraction between two SPECTs, and SISCOM image also showed hypoperfusion in the right cerebellum (Figure 1C).

## Discussion

Acute cerebellitis is rare but well recognized complication

of the central nervous system characterized by cerebellar dysfunction, the frequency of which was estimated to be 0.4% of all patients evaluated for neurological problems at a child's hospital.<sup>1</sup> Most often, the main symptoms are headache, vomiting, and disturbance of consciousness varying from somnolence to coma.<sup>2</sup> Although the pathogenic mechanisms remains uncertain, direct invasion of an etiologic agent or autoimmune demyelinating process similar to acute disseminated encephalomyelitis and multiple sclerosis has been suggested.<sup>3</sup>

Varicella-zoster virus, Herpes simplex virus, Epstein-Barr virus, rotavirus, echovirus, Coxsackie virus, mumps, measles, Lyme disease, rubella, *Borrelia burgdorferi*, *Coxiella burnetii*,

Salmonella typhi, and Bordetella pertussis are known as causative agents of AC in child or young adult.<sup>1,2,4,5</sup> Influenza virus can also cause AC.<sup>6,7</sup> To our knowledge, AC after influenza vaccination in an elderly patient has not yet been reported. Only one case of AC after influenza vaccination has been reported, but the patient was 5 years of age.<sup>6</sup> Although AC is more common in children, adult cases of cerebellitis have been also reported, but causative agents of these cases are not influenza virus.<sup>8-11</sup> We were not able to determine the definite etiology of our case, close temporal relation between influenza vaccination and an evolution of symptom suggests that influenza vaccination may cause AC in an elderly patient.

Brain MRI offers great advantages in the imaging of various disease of the cerebellum. Brain MRI in AC demonstrated bilateral or unilateral diffuse cerebellar hemispheric abnormalities in T2-weighted images, and pial enhancement in contrast enhanced T1-weighted images.<sup>1</sup> However, brain MRI demonstrated no abnormality in the majority of AC patients.<sup>12</sup> In such cases, brain SPECT might demonstrate regional perfusion abnormalities despite of normal brain MRI findings.<sup>12</sup> Nagamitsu et al.<sup>13</sup> stress the importance that cerebellar hypoperfusion is a more sensitive marker than MRI in AC. The decreased cerebellar blood flow could be explained by a post-infectious demyelinating autoimmune response.<sup>1</sup> Whereas, Gruis et al.<sup>14</sup> reported on a case with increased cerebellar blood flow, reflecting the inflammatory component of cerebellitis.

In our case, brain HMPAO-SPECT showed marked cerebellar asymmetry, despite of normal brain MRI findings, and after the acute phase, the regional blood flow returned to be normal. In addition, SISCOM image showed hypoperfusion in the right cerebellum. Traditional side-by-side visual comparison of the SPECT images can be difficult to detect subtle abnormality. SISCOM has the potential to overcome many of the limitations associated with the traditional side-by-side inspection of the images.<sup>15</sup>

In fact, we don't know exactly why the left extremities showed dysmetria and dysidiadochokinesia despite of the right cerebellar hypoperfusion in the initial SPECT. However, one conceivable explanation is the possibility of bilateral manifestation with unilateral cerebellar pathology. On the literature,<sup>16</sup> the unilateral cerebellar infarction produced limb ataxia bilaterally. Furthermore, stimulation of the unilateral deep cerebellar nuclei in monkey showed a bilateral movement representation.<sup>17</sup> Although our patient demonstrated that the left extremities were more affected than the right extremities, the fundamental pathology on neuroimaging existed on one cerebellum. The SISCOM analysis for our patient showed defi-

nitely right cerebellar hypoperfusion on the initial SPECT. So, it is possible that unilateral cerebellar pathology could be manifested with bilateral cerebellar dysfunction such as our patient. Alternatively, we consider other possibilities such as diaschisis.

We conclude that influenza vaccination can cause AC in the elderly and brain SPECT imaging is more useful than MRI in identifying patients with AC, especially when MRI is normal.

## REFERENCES

1. De Bruecker Y, Claus F, Demaerel P, Ballaux F, Scirot R, Lagae L, et al. MRI findings in acute cerebellitis. *Eur Radiol* 2004;14:1478-1483.
2. Sawaishi Y, Takada G. Acute cerebellitis. *Cerebellum* 2002;1:223-228.
3. Hayashi T, Ichijima T, Kobayashi K. A case of acute cerebellar ataxia with an MRI abnormality. *Brain Dev* 1989;11:435-436.
4. San Pedro EC, Mountz JM, Liu HG, Deutsch G. Postinfectious cerebellitis: clinical significance of Tc-99m HMPAO brain SPECT compared with MRI. *Clin Nucl Med* 1998;23:212-216.
5. Ciardi M, Giacchetti G, Fedele CG, Tenorio A, Brandi A, Libertone R, et al. Acute cerebellitis caused by herpes simplex virus type 1. *Clin Infect Dis* 2003;36:e50-e54.
6. Saito H, Yanagisawa T. Acute cerebellar ataxia after influenza vaccination with recurrence and marked cerebellar atrophy. *Tohoku J Exp Med* 1989;158:95-103.
7. Hayase Y, Tobita K. Probable post-influenza cerebellitis. *Intern Med* 1997;36:747-749.
8. Hsieh PF, Lin WY, Chang MH. Temporary cerebellar hypoperfusion with good outcome in cerebellitis. *Neurol Res* 2003;25:430-432.
9. Ratzka P, Schlachetzki JC, Bähr M, Nau R. Varicella zoster virus cerebellitis in a 66-year-old patient without herpes zoster. *Lancet* 2006;367:182.
10. Ogata K, Yamada T, Hara H, Taniwaki T, Kira J. [An adult case of peripheral facial nerve palsy following acute cerebellitis associated with high antibody titers against varicella-zoster virus]. *Rinsho Shinkeigaku* 1998;38:1070-1072.
11. Adachi M, Kawanami T, Ohshima H, Hosoya T. Cerebellar atrophy attributed to cerebellitis in two patients. *Magn Reson Med Sci* 2005;4:103-107.
12. Park JW, Choi YB, Lee KS. Detection of acute Epstein Barr virus cerebellitis using sequential brain HMPAO-SPECT imaging. *Clin Neurol Neurosurg* 2004;106:118-121.
13. Nagamitsu S, Matsuishi T, Ishibashi M, Yamashita Y, Nishimi T, Ichikawa K, et al. Decreased cerebellar blood flow in postinfectious acute cerebellar ataxia. *J Neurol Neurosurg Psychiatry* 1999;67:109-112.
14. Gruis KL, Moretti P, Gebarski SS, Mikol DD. Cerebellitis in an adult with abnormal magnetic resonance imaging findings prior to the onset of ataxia. *Arch Neurol* 2003;60:877-880.
15. O'Brien TJ, So EL, Mullan BP, Hauser MF, Brinkmann BH, Bohnen NI, et al. Subtraction ictal SPECT co-registered to MRI improves clinical usefulness of SPECT in localizing the surgical seizure focus. *Neurology* 1998;50:445-454.
16. Immisch I, Quintern J, Straube A. Unilateral cerebellar lesions influence arm movements bilaterally. *Neuroreport* 2003;14:837-840.
17. Soteropoulos DS, Baker SN. Bilateral representation in the deep cerebellar nuclei. *J Physiol* 2008;586:1117-1136.