

Nevus Variations in the Jordanian Population: Effects of Age, Medical Conditions, Environment, Congenital, Inherited, and Genetic Factors

Safwan Al-Adwan¹, Khalid M Alqaisi^{1,2}, Ghassan Al Katheri³

¹Department of Cosmetic Science, Faculty of Allied Medical Sciences, Al-Ahliyya Amman University, Amman, 19328, Jordan; ²Department of Medical Laboratory Sciences, Faculty of Allied Medical Sciences, Al-Ahliyya Amman University, Amman, 19328, Jordan; ³Department of Pathology, Humboldt General Hospital, Winnemucca, Nevada, 89446, USA

Correspondence: Safwan Al-Adwan, Consultant Dermatologist and Aesthetic Specialist, Department of Cosmetic Science, Faculty of Allied Medical Sciences, Al-Ahliyya Amman University, Amman, 19328, Jordan, Email s.aladwan@ammanu.edu.jo

Background: Nevi is a common benign proliferation of melanin-producing cells. Many triggers can influence their transformation into either benign or malignant, thus it is important to understand these triggers and their incidence across different populations to take adequate prevention. Here, we aim to examine the different etiologies of nevi changes across the Jordanian population.

Methods: We carried out a cross-sectional observational study focusing on patients seeking dermatological consultation for normal nevi or nevi with minimal changes. Demographic and clinical variables were collected from the patient's case history. Nevi's characteristics were also recorded. A skilled dermatologist assessed nevi morphology and changes using the ABCDE criteria for potential signs of melanoma. Nevi biopsy samples were fixed in formalin and sent for histopathological analysis and were stained with hematoxylin and eosin (H&E).

Results: A total of 231 patients were enrolled, with a majority of females (85%) and a median age of 37. Past medical history was positive in 17% of the samples, with hypertension, endocrine diseases, and diabetes mellitus being the most common. The majority of patients (61%) had fewer than three nevi. Changes in nevus size, configuration, and color were reported in 10% of patients, with multiple changes observed in 36% of patients. Microscopic analysis revealed polypoidal intradermal melanocytic blue nevi as the most common histopathological finding (84%). Positive medical history and the number of nevi were significantly associated with nevi changes.

Conclusion: Our results report that the number of nevi, as well as medical history, is linked to changes in their appearance. Additionally, we provide a detailed account of the various types of observed changes and their occurrence rates.

Keywords: nevi changes, melanoma, medical history, genetic factors

Introduction

Nevus is a benign proliferation of melanocytes, a type of skin cell that produces melanin pigment. Even though the nevi are benign, they form a precursor for about 50% of malignant melanoma cases.^{1,2} Nevi are categorized based on histopathological appearance and dermoscopic examination into globular, reticular, structureless brown, and mixed patterns.³

As both nevi and melanoma arise from the same precursor cell lines, the association between the number of nevi and the risk of developing melanoma later is caused either by the underlying inherited susceptibility of the nevi to the proliferation of melanocytes and/or by environmental triggers that eventually lead to melanoma.⁴

There was a correlation between large nevi and skin-colored nevi with factors such as advancing age, higher skin reflectance, the extent of freckling, and the geographical location of residence.⁵ The development of atypical or dysplastic nevi was correlated with the presence of a large number of normal moles in children aged between 5 and 8 years, which turn into atypical appearance after puberty.^{6,7} However, this does not apply to the adult population, as there is no correlation between age and the dysplastic conversion of nevi.⁸

Through clinical examination, congenital nevi have been observed in approximately 1% to 2% of newborn infants.⁹ These types of lesions have been observed to be associated with an increased number of nevi during life. In addition, they were associated with an increased risk of developing melanoma.^{10,11}

An increase in the number of nevi has been observed in sun-exposed people in hot summer in certain areas such as the lower extremity and the trunk. This can also be linked to an increased risk of the development of melanoma in this population.⁴

As many factors influence the changes in nevi and some may increase the risk of developing melanoma, it is crucial to understand the underlying mechanisms of these factors and the populations that are at increased risk of being exposed to these triggers. In this study, we aim to investigate the environmental, genetic, demographic, and inherited factors that are related to changes in normal and abnormal changes in nevi across the Jordanian population.

Methods

Study Design and Population

This is a cross-sectional observational study for patients who were seeking the clinics of the primary author (Dr. Aladwan) for dermatological consultation presenting with normal nevi or nevi with minimal changes will be enrolled in the study. Patients were excluded from the study if they: (1) were below 18 years of age, (2) had infections at the site of nevi, (3) had nevi in critical locations near vital organs such as the eye, (4) had large nevi more than 7 cm in size, and (5) were not willing to participate in the study.

Ethical Statement

Before sample inclusion in the study, all eligible patients received comprehensive information regarding the objectives of the study, their case history, data privacy measures, follow-up procedures at the clinics, and any potential risks associated with participating in the study. Subsequently, the selected patients provided their informed consent by signing the consent form for the study.

This study was approved by the Institutional Review Board Committee (IRB) at Al-Ahliyya Amman University (IRB number: AA-9-4-21) and was conducted in accordance with the principles of the Declaration of Helsinki.

Data Collection and Primary Outcomes

Case histories obtained from the included samples included the following demographic and clinical variables: age, sex, medical, surgical, and drug histories. Nevi characteristics included the number of nevi, distribution of nevi, the average size of nevus, and observed changes in nevus.

Data collection pertaining to nevi morphology and the assessment of changes in nevi will be carried out by a skilled dermatologist to ensure accurate and reliable data. The evaluation will be guided by the ABCDEs of melanoma, which serve as a framework for initially identifying potential warning signs of melanoma. In the ABCDE system, the following criteria will be considered: A for geometric asymmetry in two axes, B for irregular border, C for the presence of at least two different colors within the lesion, D for maximum diameter exceeding 6 mm, and E for evolution or changes observed in the lesion over time.^{12–14}

Nevi Biopsy and Histopathological Assessment

For this part of the study, patients who express their willingness to have the nevus excised will be included. The procedure will be conducted by a skilled dermatologist at the clinic. Details regarding specific types of biopsies, procedural aspects, and post-biopsy site care can be found in Attachment 2. The choice of biopsy method will be determined based on the individual case and the patient's consent.

Following the biopsy, the samples were fixed with 10% neutral buffered Leica Formalin and sent to a specialized medical laboratory for histopathological analysis. Gross histology was assessed by a pathology consultant. Fixed biopsies were processed using the Auto-tissue processor ASP 6025 Leica, and embedded in the Embedding Center Histostar. The Leica RM 2255 Microtome was used for cutting, and the specimens were stained with hematoxylin and eosin (H&E).

DPX and cover-slides were used for mounting, and Sato Bar-Code Printer was used for Labeling. These stained sections were examined and interpreted by an experienced pathologist.

Statistical Analysis

Categorical variables are described using frequencies (percentages %), and continuous variables are described using mean \pm standard deviation (SD) if the data are normally distributed or median (range) if the data deviate from normality according to the Shapiro–Wilk test. To analyze the correlation between demographic, clinical, and histological variables with nevi changes, Wilcoxon (Mann–Whitney U) test was used for continuous variables, Chi-squared χ^2 was used for categorical variables, and the Fisher's exact test if the cell count was <5 . Statistical significance was considered at p-value <0.05 . All analyses were conducted using the R software package version 4.3.1.

Results

Sample Characteristics

A total of 231 patients were enrolled in the study, of which 196 (85%) were females. The median sample age was 37 (18–89), 45 (20%) patients fell in the age group between 24 and 29, while 40 (17%) patients fell in the age group between 30 and 35 years as shown in Table 1. Past medical history was positive in 40 (17%) of samples, which included hypertension in 12 (5%) patients, endocrine diseases in 7 (3%) patients, diabetes mellitus in 6 (3%) patients, lung diseases in 2 (1%) patients, cardiovascular diseases in 2 (1%) patients, and autoimmune diseases in 2 (1%) patients. Two patients had tumors, and single cases of hyperlipidemia, neurological, and gastrointestinal diseases were observed, and 191 (83%) patients had a normal medical history.

Of the enrolled samples, 65 (28%) had previous major surgeries with general anesthesia, 2 (1%) had major procedures with local anesthesia, and 5 (2%) had minor procedures. One patient (0.4%) had an aesthetic injection, and one patient (0.4%) had a major procedure. Drugs for chronic diseases were reported in 33 (14%) patients, 2 (1%) patients were taking drugs for infections, and 2 (1%) patients were taking drugs for gastrointestinal diseases. Single cases involved taking oral contraceptives, painkillers, and drugs for cardiovascular problems.

Gross and Microscopic Nevi Characteristics

Of the 231 samples enrolled, a total of 211 samples had data for nevi location, and 228 biopsy samples were taken for histopathological analysis. Most nevi were observed in the face (n=136, 59%), 27 (12%) in the neck, 18 (8%) in the

Table 1 Demographic and Clinical Characteristics of Included Samples

Variables	N = 231	%
Age groups (Years)		
18–23	23	10
24–29	45	19.5
30–35	40	17.3
36–41	40	17.3
42–47	35	15.2
48–53	24	10.4
54–59	14	6.1
60–65	6	2.6
66–71	3	1.3
84–89	1	0.4
Sex		
Male	35	15.2
Female	196	84.8

(Continued)

Table 1 (Continued).

Variables	N = 231	%
Medical history		
Normal patient	191	82.7
Diabetes Mellitus	6	2.6
Hypertension	12	5.2
Lung disease	2	0.9
Neurological disease	1	0.4
GIT disease	1	0.4
Cardiovascular disease	2	0.9
Tumors	2	0.9
Endocrine disease	7	3
Autoimmune disease	2	0.9
Hyperlipidemia	1	0.4
Two or more diseases	4	1.7
Surgical history		
Minor procedure	5	2.2
Major procedure	1	0.4
Major with general anesthesia	65	28.1
Major with local anesthesia	2	0.9
Injection aesthetic	1	0.4
No previous surgeries	157	68
Drug History		
Drugs for chronic disease	33	14.3
Drugs for infections	2	0.9
Oral contraceptive pills	1	0.4
Drugs for analgesia and pain killers	1	0.4
No drugs intake	190	82.6
Drugs for gastrointestinal disease	2	0.9
Drugs for cardiovascular	1	0.4
Drugs for multi-diseases	1	0.4

trunk, 9 (4%) in the back, 6 (3%) in the arms, 4 (2%) in the legs, while 2 (1%) in the thighs. Five nevi were observed in the scalp, while 2 (1%) in the head and 2 (1%) in the ears. Of the 231 evaluated samples, 140 (61%) patients had less than 3 nevi, 43 (19%) had 3–10 nevi, and 48 (21%) had more than 10 nevi. All assessed nevi had small size of less than 1.5 cm. The color of the nevi ranged between brown in 215 (93%) samples, black in 11 (5%) samples, and pink in 3 (1%) samples. [Table 2](#) shows the gross nevi characteristics of included samples.

The distribution of the nevi varied between 76 (33%) in the middle third of the face, 54 (23%) in the lower third, and 20 (9%) in the upper third of the face. Change in nevus size was reported in 22 (10%) patients, 11 (5%) reported configuration changes, and 11 (5%) reported changes in nevi color. Two patients reported nevi bleeding, while one patient reported nevi ulcerations. Multiple changes were reported in 84 (36%) patients.

Microscopic characteristics included polypoidal intradermal melanocytic blue nevi in 193 (84%) of samples, seborrheic keratosis in 15 (7%) of samples, compound junctional melanocytic nevi in 9 (4%) of samples, 3 (1%) patients showed squamous papilloma, 3 (1%) showed fibroepithelial polyps, while 2 (1%) showed focal dermal inflammation of the skin with small inclusion cysts with surrounding fibrosis and mild inflammation. One patient showed features of Acrokeratosis of Hopf, one patient had basal cell carcinoma, and one patient had acanthomatous changes with melanin incontinence (Hyperkeratosis with acanthosis) as shown in [Table 3](#).

Nevi changes showed a significant association with a previous medical history, in which 78% (n=31) of patients with positive medical history had nevi changes ([Figure 1A](#)). In addition, the nevi number was also significantly associated with nevi changes in which 49% (n=) of samples with observed changes had less than 3 nevi as shown in [Figure 1B](#).

Table 2 Gross Nevi Characteristics of Included Samples

Variables	N = 231	%
Site of nevi^a		
Face	136	58.9
Neck	27	11.7
Trunk	18	7.8
Back	9	3.9
Head	2	0.9
Scalp	5	2.2
Arms	6	2.6
Legs	4	1.7
Ear	2	0.9
Thigh	2	0.9
Distribution of nevi		
Upper third of the face	20	8.7
Middle third of the face	76	32.9
Lower third of the face	54	23.4
Neck	26	11.3
Chest	2	0.9
Back	9	3.9
Shoulders	5	2.2
Right upper arm	2	0.9
Left thigh	1	0.4
Right lower leg	1	0.4
Left lower leg	1	0.4
Sole	1	0.4
Abdomen	8	3.5
Underarm	2	0.9
Back of the scalp	3	1.3
Multi distribution	20	8.7
Number of nevi		
Less than 3	140	60.6
3–10	43	18.6
More than 10	48	20.8
Color of the nevus		
Black	11	4.8
Brown	215	93.1
Pink	3	1.3
Others	2	0.9
Observed changes in the nevus^b		
No observed changes	97	42
Ulceration	1	0.4
Bleeding	2	0.9
Change in size	22	9.5
Configuration	11	4.8
Change in color	11	4.8
Multiple changes	84	36.4

Notes: ^aN=211, ^bN=228.

Drug intake for chronic diseases accounted for 17% of the observed nevi changes. Both tumor cases had nevi changes in size and other associated changes. No significant differences were found between observed changes and other clinical factors (Table 4).

Table 3 Microscopic Characteristics

Histopathological Findings	N=228	%
Intradermal melanocytic nevus	193	83.5
Polypoidal intradermal melanocytic nevus, blue nevus		
Seborrheic keratosis	15	6.5
Squamous papilloma	3	1.3
Basal cell carcinoma	1	0.4
Fibroepithelial polyp	3	1.3
Compound junctional melanocytic nevus, Lentigo simplex	9	3.9
Skin with focal dermal inflammation	2	0.9
Small inclusion cyst with surrounding fibrosis and mild inflammation		
Features reminiscent of Acrokeratosis of Hopf	1	0.4
Skin with acanthomatous change, melanin incontinence, hyperkeratosis with acanthosis	1	0.4

When comparing patients with a positive medical history (n=40) to those with no previous medical history (n=191), there was a significant association with surgical history showing that 40% of patients with a positive medical history also had a history of major surgery with general anesthesia, while 72% (n=137) of patients with a negative medical history also had a negative surgical history (Table 5). In addition, 31 (78%) of patients with positive medical history are on medications for chronic diseases (p-value<0.001). Type of nevi changes was significantly different between the two groups, showing that 19 (48%) of patients with positive medical history had multiple nevi changes; however, ulcerations (n=1, 0.5%), color changes (n=10, 5.2%), and bleeding (n=2, 1.0%) were higher in patients with negative medical history (p-value=0.028) as shown in Table 5. Histopathological findings were significantly different between the two groups, showing that 166 (88%) patients with negative medical history showed polypoidal intradermal melanocytic blue nevi, while 6 (15%) of patients with positive medical history showed seborrheic keratosis (p-value=0.005).

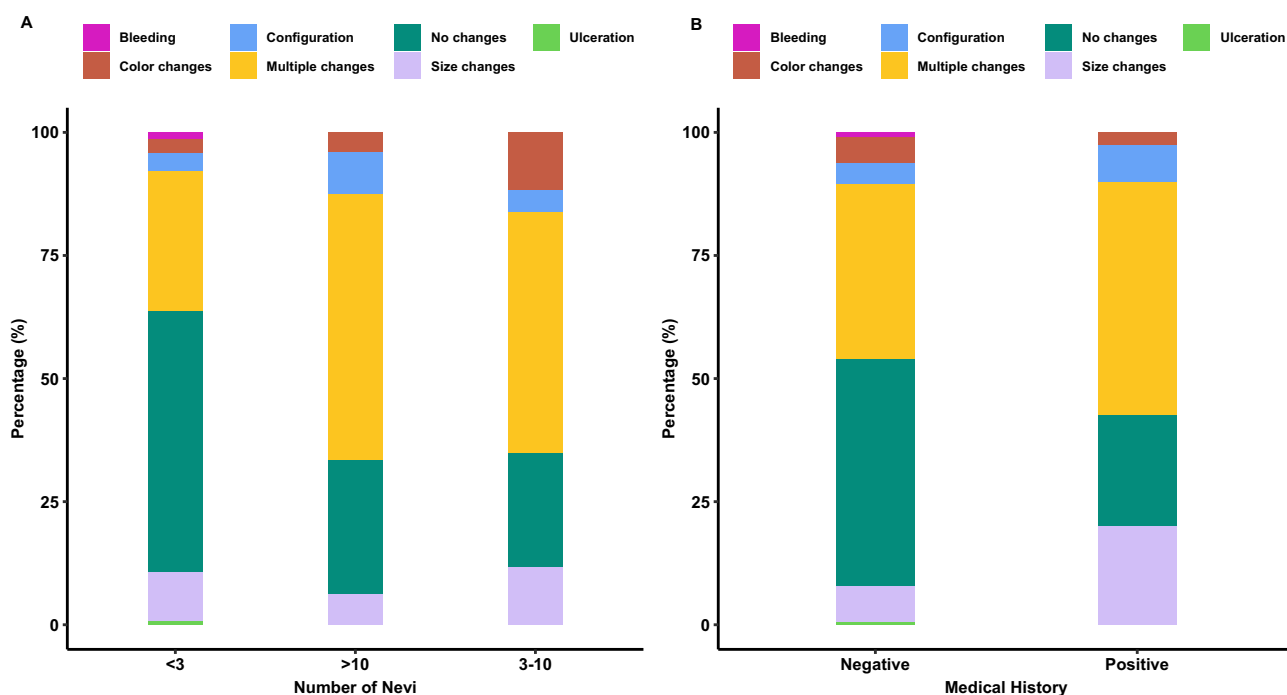


Figure 1 Bar plots illustrating the distribution of the observed nevi changes in the included samples based on (A) Bar charts showing the distribution of nevi changes across patients with positive medical history compared to patients with negative medical history. Positive medical history showed a significantly higher proportion of multiple nevi changes while negative medical history was significantly associated with no nevi changes. (B) Bar charts showing the distribution of nevi changes and number of nevi, patients with multiple nevi changes had a significantly higher number of nevi >10, while patients with no nevi changes had less than three nevi.

Table 4 Demographic, Clinical, and Histopathological Characteristics Associated with Nevus Changes

Variable	No changes, N = 97 ^a	Positive, N = 134 ^a	p-value ^b
Age			
18–23	9 (9.3%)	14 (10%)	
24–29	22 (23%)	23 (17%)	
30–35	16 (16%)	24 (18%)	
36–41	14 (14%)	26 (19%)	
42–47	19 (20%)	16 (12%)	
48–53	12 (12%)	12 (9.0%)	
54–59	3 (3.1%)	11 (8.2%)	
60–65	2 (2.1%)	4 (3.0%)	
66–71	0 (0%)	3 (2.2%)	
84–89	0 (0%)	1 (0.7%)	
Sex			0.4
Female	80 (82%)	116 (87%)	
Male	17 (18%)	18 (13%)	
Detailed Medical History			0.4
Autoimmune Diseases	0 (0%)	2 (1.5%)	
Cardiovascular Diseases	1 (1.0%)	1 (0.7%)	
DM	3 (3.1%)	3 (2.2%)	
DM + HTN	0 (0%)	3 (2.2%)	
Endocrine Diseases	1 (1.0%)	6 (4.5%)	
GIT Diseases	0 (0%)	1 (0.7%)	
HLD	0 (0%)	1 (0.7%)	
HTN	4 (4.1%)	8 (6.0%)	
HTN + Renal Dysfunction	0 (0%)	1 (0.7%)	
Lung Diseases	0 (0%)	2 (1.5%)	
Negative	88 (91%)	103 (77%)	
Neurological Diseases	0 (0%)	1 (0.7%)	
Tumors	0 (0%)	2 (1.5%)	
Medical History			0.006
Negative	88 (91%)	103 (77%)	
Positive	9 (9.3%)	31 (23%)	
Surgical History			0.2
Injection aesthetic	1 (1.0%)	0 (0%)	
Major Procedures	1 (1.0%)	0 (0%)	
Major with general anesthesia	27 (28%)	38 (28%)	
Major with local anesthesia	1 (1.0%)	1 (0.7%)	
Minor Procedures	0 (0%)	5 (3.7%)	
No previous surgeries	67 (69%)	90 (67%)	
Drug History			0.3
Drugs for cardiovascular	1 (1.0%)	0 (0%)	
Drugs for chronic disease	10 (10%)	23 (17%)	
Drugs for chronic disease + Supplements	0 (0%)	1 (0.7%)	
Drugs for GI disease	0 (0%)	2 (1.5%)	
Drugs for infections	1 (1.0%)	1 (0.7%)	
No drugs intake	85 (88%)	105 (78%)	
Oral contraceptive pills	0 (0%)	1 (0.7%)	
Pain killers	0 (0%)	1 (0.7%)	

(Continued)

Table 4 (Continued).

Variable	No changes, N = 97 ^a	Positive, N = 134 ^a	p-value ^b
Number of Nevi			<0.001
<3	74 (76%)	66 (49%)	
>10	13 (13%)	35 (26%)	
3–10	10 (10%)	33 (25%)	
Distribution of nevi			>0.9
Abdomen	3 (3.1%)	5 (3.7%)	
Back	3 (3.1%)	6 (4.5%)	
Chest	1 (1.0%)	1 (0.7%)	
Left lower leg	0 (0%)	1 (0.7%)	
Lower third of the face	23 (24%)	31 (23%)	
Middle third of the face	34 (35%)	42 (31%)	
Multiple sites	9 (9.3%)	13 (9.7%)	
Neck	14 (14%)	12 (9.0%)	
Right lower leg	0 (0%)	1 (0.7%)	
Right upper arm	0 (0%)	2 (1.5%)	
Scalp	1 (1.0%)	1 (0.7%)	
Shoulders	1 (1.0%)	4 (3.0%)	
Sole	0 (0%)	1 (0.7%)	
Underarm	1 (1.0%)	1 (0.7%)	
Upper third of the face	7 (7.2%)	13 (9.7%)	
Color of the nevus			0.5
Black	4 (4.1%)	7 (5.2%)	
Brown	90 (93%)	125 (93%)	
Others	2 (2.1%)	0 (0%)	
Pink	1 (1.0%)	2 (1.5%)	
Histopathology Findings			0.3
Acrokeratosis of Hopf	0 (0%)	1 (0.7%)	
Basal cell carcinoma	0 (0%)	1 (0.7%)	
Fibroepithelial polyp	3 (3.2%)	0 (0%)	
Hyperkeratosis with acanthosis	0 (0%)	1 (0.7%)	
Lentigo simplex	4 (4.3%)	5 (3.7%)	
Polypoidal intradermal melanocytic blue nevi	82 (87%)	111 (83%)	
Seborrheic keratosis	4 (4.3%)	11 (8.2%)	
Small inclusion cyst with fibrosis and inflammation	0 (0%)	2 (1.5%)	
Squamous papilloma	1 (1.1%)	2 (1.5%)	

Notes: ^an (%). ^bPearson's chi-squared test; Fisher's exact test.

Discussion

The prevalence of abnormally appearing nevi has increased over the past few years. This has been related to many factors in which some of which can be managed by the appropriate precautions, and some are genetic and inherited making it harder to prevent. In this cross-sectional study, we aim to make early predictions regarding changes in any type of nevus based on various factors, including age, sex, marital status, medical condition, chronic disease, environmental influences, genetic predisposition, congenital factors, and inherited traits.

Our cohort consisted of 231 patients in which the majority of them were females. Medical history, demographic and histopathological data were analyzed and processed. Gross and microscopic characteristics of the nevi were evaluated to study the distribution across different body parts and the abnormal changes.

One of the changes that were observed is change in the size of nevi, which was reported in 22 patients. Other changes that were observed are the nevi color and configuration changes, which were reported in 11 patients for each. Despite the

Table 5 Demographic, Clinical, and Histopathological Characteristics Associated with Patients with Positive versus Negative Medical History

Characteristic	Negative, N = 191 ^a	Positive, N = 40 ^a	p-value ^b
Age Group			
18–23	22 (12%)	1 (2.5%)	
24–29	42 (22%)	3 (7.5%)	
30–35	37 (19%)	3 (7.5%)	
36–41	34 (18%)	6 (15%)	
42–47	29 (15%)	6 (15%)	
48–53	18 (9.4%)	6 (15%)	
54–59	7 (3.7%)	7 (18%)	
60–65	2 (1.0%)	4 (10%)	
66–71	0 (0%)	3 (7.5%)	
84–89	0 (0%)	1 (2.5%)	
Sex			0.2
Female	165 (86%)	31 (78%)	
Male	26 (14%)	9 (23%)	
Surgical History			0.007
Injection aesthetic	1 (0.5%)	0 (0%)	
Major Procedures	1 (0.5%)	0 (0%)	
Major with general anesthesia	49 (26%)	16 (40%)	
Major with local anesthesia	0 (0%)	2 (5.0%)	
Minor Procedures	3 (1.6%)	2 (5.0%)	
No previous surgeries	137 (72%)	20 (50%)	
Drug History			<0.001
Drugs for cardiovascular	0 (0%)	1 (2.5%)	
Drugs for chronic disease	2 (1.0%)	31 (78%)	
Drugs for chronic disease + Supplements	0 (0%)	1 (2.5%)	
Drugs for GI disease	1 (0.5%)	1 (2.5%)	
Drugs for infections	1 (0.5%)	1 (2.5%)	
No drugs intake	186 (97%)	4 (10%)	
Oral contraceptive pills	0 (0%)	1 (2.5%)	
Pain killers	1 (0.5%)	0 (0%)	
Number of Nevi			0.8
<3	117 (61%)	23 (58%)	
>10	38 (20%)	10 (25%)	
3–10	36 (19%)	7 (18%)	
Distribution of nevi			
Abdomen	8 (4.2%)	0 (0%)	
Back	9 (4.7%)	0 (0%)	
Chest	2 (1.0%)	0 (0%)	
Left lower leg	1 (0.5%)	0 (0%)	
Lower third of the face	43 (23%)	11 (28%)	
Middle third of the face	64 (34%)	12 (30%)	
Multiple sites	18 (9.4%)	4 (10%)	
Neck	23 (12%)	3 (7.5%)	
Right lower leg	0 (0%)	1 (2.5%)	
Right upper arm	2 (1.0%)	0 (0%)	
Scalp	1 (0.5%)	1 (2.5%)	
Shoulders	5 (2.6%)	0 (0%)	
Sole	1 (0.5%)	0 (0%)	
Underarm	2 (1.0%)	0 (0%)	
Upper third of the face	12 (6.3%)	8 (20%)	

(Continued)

Table 5 (Continued).

Characteristic	Negative, N = 191 ^a	Positive, N = 40 ^a	p-value ^b
Color of the nevus			0.4
Black	9 (4.7%)	2 (5.0%)	
Brown	179 (94%)	36 (90%)	
Others	1 (0.5%)	1 (2.5%)	
Pink	2 (1.0%)	1 (2.5%)	
Type of observed changes in the nevus			0.028
Bleeding	2 (1.0%)	0 (0%)	
Color changes	10 (5.2%)	1 (2.5%)	
Configuration	8 (4.2%)	3 (7.5%)	
Multiple changes	68 (36%)	19 (48%)	
No changes	88 (46%)	9 (23%)	
Size changes	14 (7.3%)	8 (20%)	
Ulceration	1 (0.5%)	0 (0%)	
Observed Changes			0.006
No changes	88 (46%)	9 (23%)	
Positive	103 (54%)	31 (78%)	
Histopathology Findings			0.005
Acrokeratosis of Hopf	0 (0%)	1 (2.6%)	
Basal cell carcinoma	0 (0%)	1 (2.6%)	
Fibroepithelial polyp	3 (1.6%)	0 (0%)	
Hyperkeratosis with acanthosis	0 (0%)	1 (2.6%)	
Lentigo simplex	7 (3.7%)	2 (5.1%)	
Polypoidal intradermal melanocytic blue nevi	166 (88%)	27 (69%)	
Seborrheic keratosis	9 (4.8%)	6 (15%)	
Small inclusion cyst with fibrosis and inflammation	2 (1.1%)	0 (0%)	
Squamous papilloma	2 (1.1%)	1 (2.6%)	

Notes: ^an (%). ^bPearson's chi-squared test; Fisher's exact test.

fact that these changes are frequently occurring in the general population, the pathogenesis of their development remains unclear. A study by Rivers et al reported that such changes were increased for people who are in close proximity to the equator, which applies to the Jordanian population that was studying which is considered relatively close to the equator.¹⁰

In Rivers et al's study, they analyzed the atypical nevi, skin-colored and large nevi. They reported that the presence of large and atypical nevi is significantly influenced by the geographic location and, consequently, the level of solar radiation exposure. This also applies to nevi that resemble congenital nevi, implying that many nevi considered to be congenital are acquired during the early stages of life.¹⁰

In addition to these changes, we also reported that two of the patients had bleeding nevi and one had an ulcerated nevus. The majority of the patients in our cohort had multiple changes rather than a single change.

For the microscopic findings, the majority of the nevi were blue nevi followed by seborrheic keratosis and compound junctional melanocytic nevi. Blue nevi are considered by many dermatologists as hamartomas that occur as a result of the migration of melanocytes from the neural crest to the skin dermis.¹⁵ Seborrheic keratosis type is considered the most common benign epidermal tumor and has been reported to be associated with many factors such as age, genetic makeup, and exposure to ultraviolet radiation.^{16,17} The compound junctional type is an abnormal yet benign proliferation of melanocytes. It is very common across the general population and can sometimes be misdiagnosed as melanoma in situ.^{18,19} The occurrence of such nevi has been associated with similar factors as other lesions.

Few patients have shown squamous papilloma, fibroepithelial polyps, acrokeratosis verruciformis of Hopf, basal cell carcinoma, as well as acanthosis with hyperkeratosis. Despite the unclear pathogenesis of these changes, some factors identified in the literature have been associated with their development, such as sun exposure,^{20,21} genetic makeup, as well

as geographic factors, such as latitude.²² Moreover, these can be further exacerbated by the long-term exposure to arsenic resulting from the continuous consumption of contaminated water, food, and medications, as well as through the utilization of ionizing radiation for treating skin diseases or childhood cancers, especially in case of basal cell carcinoma.^{23–25}

More precisely, the number of nevi has been significantly correlated with abnormal changes in our cohort, and those who had an increased number of nevi had been observed to have nevi changes. A study conducted by Holly et al that supports our findings aimed to investigate the correlation between the number of melanocytic nevi and cutaneous melanoma. The study's findings indicate that individuals with a higher number of nevi are more prone to melanoma, suggesting the existence of a distinct group at greater risk, which could be closely monitored for early detection of malignant melanoma. Additionally, the report revealed that a history of blistering sunburns, previous skin cancer diagnosis, and having red or blond hair at the age of 20 was also independently linked to an elevated risk of developing cutaneous melanoma.²⁶ It is important to note that the increasing number of nevi screening tests and biopsies may be associated with the increase in the abnormally appearing nevi, which in turn may affect the findings. A study by Banky et al showed that the initial number of dysplastic nevi showed a positive correlation with the occurrence of nevi changes and melanoma.²⁷

Our findings also suggest that positive medical history has also been associated with nevi changes. Age and sex were not significantly associated with nevi changes in our cohort. However, some studies in the literature suggest a positive relationship between age and nevi changes, in which the incidence of new, changed, and regressed nevi has decreased with age and the incidence of melanoma has increased with age.²⁷ Family,^{28,29} personal and natural history has been found to be associated with changes as well.^{30,31} Despite that, literature studies suggest that a small proportion of melanoma patients have developed from pre-existing nevi; thus, the association of nevi progression to melanoma needs to be further evaluated.³² In nevi, multiple tumor suppressors like p53 remain functional, and senescence-associated factors are actively expressed. This leads to cell senescence and a halt in the cell cycle.³³ However, melanoma rarely exhibits a loss of p53 function, the decreased or absent presence of PTEN, coupled with an activated PI3k/Akt signaling pathway, is a common occurrence in nevi. This particular scenario can disrupt the senescence status, potentially allowing the progression of nevi into dysplastic nevi or melanoma.³⁴

The strength of our study is that the included cohort had different underlying etiologies, which made it easier to understand and investigate the correlation between these etiologies and the incidence of changes detected in nevi. However, in order to be able to draw more robust conclusions, studying these correlations on a larger cohort size is recommended. In addition, as the majority of the patients were females, and our findings have shown no association between sex and nevi changes, there may be a risk of bias, thus including both genders equally in the study is suggested to reduce any potential risk of bias in the findings. In addition, we implemented a cross-sectional design, which comes with constraints, such as their incapacity to confirm causal relationships, their vulnerability to biases, and their absence of chronological data. This study provides statistical findings regarding nevi changes and abnormalities in the Jordanian population; hence, it can be used for epidemiological purposes rather than clinical decision-making. However, it is worth mentioning that our findings should be interpreted with caution and future prospective randomized trials are warranted to build up a clinical significance.

This cross-sectional study is the first to our knowledge that has been conducted on the Jordanian population in which we studied the different potential risk factors for nevi changes. As these changes may be normal or abnormal and may lead to benign or malignant outcomes, it is critical to understand how different factors play a role in their development, as well as understand their incidence across different populations in order to take the appropriate precautions. In conclusion, our findings reported that nevi changes have been associated with their number, medical, and family history, and not with age or sex. We also reported the different types of changes that were observed and their incidence. However, our findings should be interpreted with caution due to several limitations. First, we implement a cross-sectional study design that can be limited to inability to establish causality, susceptibility to bias, and their lack of temporal information. Our results suggest that factors such as the number of nevi, medical history, and family history are influential in the changes observed in nevi. These discoveries hold significant implications, particularly for health-care providers and dermatologists. They can utilize this knowledge to enhance their risk evaluations, particularly for patients with a higher nevus count or relevant medical and family backgrounds. This could lead to more frequent screenings for individuals at elevated risk. Nevertheless, it is essential to underscore the need for future longitudinal studies to further contribute to improved prevention and management of nevi changes. This, in turn, has the potential to alleviate the burden of skin-related health concerns and enable the application of these findings in clinical settings more effectively.

Acknowledgement

This research project was fully sponsored by the Deanship of Scientific Research, Al-Ahliyya Amman University, Jordan (Grant number: 2/39/2020-2021).

Disclosure

The authors report no conflicts of interest in this work.

References

- Baxter LL, Pavan WJ. The etiology and molecular genetics of human pigmentation disorders. *Wiley Interdiscip Rev Dev Biol*. 2013;2(3):379. doi:10.1002/WDEV.72
- Dermoscopic features of common nevi: a review. Available from: <https://pubmed.ncbi.nlm.nih.gov/22481577/>. Accessed July 04, 2023.
- Zalaudek I, Manzo M, Savarese I, Docimo G, Ferrara G, Argenziano G. The morphologic universe of melanocytic nevi. *Semin Cutan Med Surg*. 2009;28(3):149–156. doi:10.1016/J.SDER.2009.06.005
- Dos I, Silva S, Abramsky T, et al. Overseas sun exposure, nevus counts, and premature skin aging in young English women: a population-based survey. *J Invest Dermatol*. 2009;129(1):50–59. doi:10.1038/JID.2008.190
- Kelly JW, Rivers JK, MacLennan R, et al. Sunlight: a major factor associated with the development of melanocytic nevi in Australian schoolchildren. *J Am Acad Dermatol*. 1994;30(1):40–48. doi:10.1016/S0190-9622(94)70005-2
- Naeyaert JM, Brochez L. Clinical practice. Dysplastic nevi. *N Engl J Med*. 2003;349(23):2233–2240. doi:10.1056/NEJMCP023017
- Silva JH, de Sá BC, de Ávila ALR, Landman G, Neto JPD. Atypical mole syndrome and dysplastic nevi: identification of populations at risk for developing melanoma - review article. *Clinics*. 2011;66(3):493–499. doi:10.1590/S1807-59322011000300023
- Stierner U, Augustsson A, Rosdahl I, Suurkula M. Regional distribution of common and dysplastic naevi in relation to melanoma site and sun exposure. A case-control study. *Melanoma Res*. 1992;1(5–6):367–375. doi:10.1097/00008390-199201000-00008
- Sigg C, Pelloni F, Schnyder UW. Frequency of congenital nevi, nevi spili and café-au-lait spots and their relation to nevus count and skin complexion in 939 children. *Dermatologica*. 1990;180(3):118–123. doi:10.1159/000248009
- Rivers JK, Frederiksen PC, Dibdin C. A prevalence survey of dermatoses in the Australian neonate. *J Am Acad Dermatol*. 1990;23(1):77–81. doi:10.1016/0190-9622(90)70190-S
- Kroon S, Clemmensen OJ, Hastrup N. Incidence of congenital melanocytic nevi in newborn babies in Denmark. *J Am Acad Dermatol*. 1987;17(3):422–426. doi:10.1016/S0190-9622(87)70223-0
- Deb S, Sarkar R, Samanta AB. A brief review of nevus depigmentosus. *Pigm Inter*. 2014;1(2):56. doi:10.4103/2349-5847.147041
- Lin WM, Luo S, Muzikansky A, et al. Outcome of patients with de novo versus nevus-associated melanoma. *J Am Acad Dermatol*. 2015;72(1):54–58. doi:10.1016/J.JAAD.2014.09.028
- Hosler GA, Moresi JM, Barrett TL. Nevi with site-related atypia: a review of melanocytic nevi with atypical histologic features based on anatomic site. *J Cutan Pathol*. 2008;35(10):889–898. doi:10.1111/J.1600-0560.2008.01041.X
- Melanocytic nevi and malignant melanoma. Available from: <https://pubmed.ncbi.nlm.nih.gov/3830485/>. Accessed July 04, 2023.
- Karadag AS, Parish LC. The status of the seborrheic keratosis. *Clin Dermatol*. 2018;36(2):275–277. doi:10.1016/J.CLINDERMATOL.2017.09.011
- Barthelmann S, Butsch F, Lang BM, et al. Seborrheic keratosis. *J Dtsch Dermatol Ges*. 2023;21(3):265–277. doi:10.1111/DDG.14984
- Early melanoma. Histologic terms. Available from: <https://pubmed.ncbi.nlm.nih.gov/1805653/>. Accessed July 04, 2023.
- Okamura JM, Barr RJ, Cantos KA. Benign atypical junctional melanocytic hyperplasia associated with intradermal nevi: a common finding that may be confused with melanoma in situ. *Mod Pathol*. 2000;13(8):857–860. doi:10.1038/MODPATHOL.3880152
- “Mohsin A. Acrokeratosis verruciformis of Hopf; 2004. Available from: <https://pubmed.ncbi.nlm.nih.gov/?term=Mohsin+Ali.+Acrokeratosis+verruciformis+of+Hopf.+In%3A+http%2F%2Fwww.+emedicine.com%2Fderm%2Ftopic7.htm.+March+2%2C+2004>. Accessed July 06, 2023.
- Tanese K. Diagnosis and management of basal cell carcinoma. *Curr Treat Options Oncol*. 2019;20(2). doi:10.1007/S11864-019-0610-0
- Lomas A, Leonardi-Bee J, Bath-Hextall F. A systematic review of worldwide incidence of nonmelanoma skin cancer. *Br J Dermatol*. 2012;166(5):1069–1080. doi:10.1111/J.1365-2133.2012.10830.X
- Shirley S-H T, Bolger PM. Dietary arsenic intakes in the United States: FDA total diet study, September 1991–December 1996. *Food Addit Contam*. 1999;16(11):465–472. doi:10.1080/026520399283759
- Boonchai W, Green A, Ng J, Dicker A, Chenevix-Trench G. Basal cell carcinoma in chronic arsenicism occurring in Queensland, Australia, after ingestion of an asthma medication. *J Am Acad Dermatol*. 2000;43(4):664–669. doi:10.1067/MJD.2000.107939
- Karagas MR, Tosteson TD, Blum J, Morris JS, Baron JA, Klaue B. Design of an epidemiologic study of drinking water arsenic exposure and skin and bladder cancer risk in a U.S. population. *Envir Health Persp*. 1998;106(Suppl 4):1047–1050. doi:10.1289/EHP.98106S41047
- Holly EA, Kelly JW, Shpall SN, Chiu SH. Number of melanocytic nevi as a major risk factor for malignant melanoma. *J Am Acad Dermatol*. 1987;17(3):459–468. doi:10.1016/S0190-9622(87)70230-8
- Banky JP, Kelly JW, English DR, Yeatman JM, Dowling JP. Incidence of new and changed nevi and melanomas detected using baseline images and dermoscopy in patients at high risk for melanoma. *Arch Dermatol*. 2005;141(8):998–1006. doi:10.1001/ARCHDERM.141.8.998
- Multiple primary malignancies in patients with cutaneous melanoma. Available from: <https://pubmed.ncbi.nlm.nih.gov/907999/>. Accessed July 06, 2023.
- Multiple primary cutaneous melanomas. Available from: <https://pubmed.ncbi.nlm.nih.gov/1130805/>. Accessed July 06, 2023.
- Pigmentary traits, ethnic origin, benign nevi, and family history as risk factors for cutaneous malignant melanoma. Available from: <https://pubmed.ncbi.nlm.nih.gov/6582314/>. Accessed July 06, 2023.
- Ford D, Bliss JM, Swerdlow AJ, et al. Risk of cutaneous melanoma associated with a family history of the disease. The International Melanoma Analysis Group (IMAGE). *Int J Cancer*. 1995;62(4):377–381. doi:10.1002/IJC.2910620403

32. Tsao H. The transformation rate of moles (melanocytic nevi) into cutaneous melanoma: a population-based estimate. *Arch Dermatol.* 2003;139(3):282–288. doi:10.1001/ARCHDERM.139.3.282
33. Terzian T, Torchia EC, Dai D, et al. p53 prevents progression of nevi to melanoma predominantly through cell cycle regulation. *Pigment Cell Melanoma Res.* 2010;23(6):781–794. doi:10.1111/J.1755-148X.2010.00773.X
34. Sung WW, Chang CH. Nevi, dysplastic nevi, and melanoma: molecular and immune mechanisms involving the progression. *Tzu Chi Med J.* 2021;34(1):1–7. doi:10.4103/TCMJ.TCMJ_158_20

Clinical, Cosmetic and Investigational Dermatology

Dovepress

Publish your work in this journal

Clinical, Cosmetic and Investigational Dermatology is an international, peer-reviewed, open access, online journal that focuses on the latest clinical and experimental research in all aspects of skin disease and cosmetic interventions. This journal is indexed on CAS. The manuscript management system is completely online and includes a very quick and fair peer-review system, which is all easy to use. Visit <http://www.dovepress.com/testimonials.php> to read real quotes from published authors.

Submit your manuscript here: <https://www.dovepress.com/clinical-cosmetic-and-investigational-dermatology-journal>