

This article is licensed under the Creative Commons Attribution-NonCommercial 4.0 International License (CC BY-NC) (<http://www.karger.com/Services/OpenAccessLicense>). Usage and distribution for commercial purposes requires written permission.

Single Case

Kidney Injury due to Ureteral Obstruction Caused by Compression from Infected Simple Hepatic Cyst

Naoya Sawada^a Tetsu Endo^a Kenichiro Mikami^a Go Igarashi^a
Juichi Sakamoto^b Hiroshi Tono^b Shinsaku Fukuda^a

^aDepartment of Gastroenterology and Hematology, Hirosaki University Graduate School of Medicine, Hirosaki, Japan; ^bDepartment of Internal Medicine, Hirosaki Municipal Hospital, Hirosaki, Japan

Keywords

Simple hepatic cysts · Ureteral obstruction · Ultrasound-guided percutaneous drainage · Sclerotherapy · Minocycline hydrochloride

Abstract

Simple hepatic cysts are common and most often asymptomatic. In symptomatic cases, hemorrhage, rupture, and infection are major complications. However, urinary tract obstruction caused by a simple hepatic cyst is rare. We treated an 82-year-old Japanese man with an infected giant hepatic cyst causing right hydronephrosis who had a past history of left nephrectomy for renal cell carcinoma. The patient underwent ultrasound-guided percutaneous drainage and sclerotherapy with minocycline hydrochloride for the infected hepatic cyst. Right hydronephrosis was relieved, and renal dysfunction improved with regression of the hepatic cyst after treatment. This is the first report of hydronephrosis due to ureteral obstruction caused by compression from a hepatic cyst.

© 2017 The Author(s)
Published by S. Karger AG, Basel

Introduction

Simple hepatic cysts are common and benign lesions. They are usually asymptomatic and have no effect on liver function, and are diagnosed based on incidental findings on abdominal imaging such as ultrasonography (US) and computed tomography (CT). However, they cause symptoms when they are complicated by infection, rupture, intracystic hemorrhage, obstructive jaundice, and/or compression of vascular systems [1–3].

However, ureteral obstruction due to compression from a benign lesion of the liver is very rare [4]. We describe the case of a patient with an infected giant hepatic cyst that obstructed the ureteral tract, who was successfully treated with cystic drainage and sclerotherapy.

Case Report

An 82-year-old man presented to his general practitioner with anorexia, abdominal distension, pain, and fever. His past medical history consisted of left nephrectomy for renal cell carcinoma at 66 years of age. He had been found to have simple hepatic cysts at 55 years of age, and received a follow-up examination from his general practitioner with CT. Plain CT scanning and US revealed enlargement of a simple hepatic cyst measuring 20 cm in diameter, right hydronephrosis, and gallstones in the compressed gallbladder (Fig. 1). Laboratory analysis showed severe inflammation and renal dysfunction. Thus, he was referred and admitted to our hospital for further evaluation and treatment. Laboratory data on admission showed increased serum C-reactive protein (CRP) and creatinine levels: 34.0 and 1.61 mg/dL, respectively (Table 1). Liver function tests and serum tumor marker levels were within the normal range, except for a slight elevation in alkaline phosphatase (385 IU/L, reference range: 115–359). Urinalysis showed no signs of urinary tract infection, and blood culture was negative. Although CT showed gallstones, acute cholecystitis was negative due to almost normal liver function tests. Therefore, we diagnosed the patient with an infected hepatic cyst complicated by urinary tract obstruction, and we prescribed intravenous drip infusion of cefoperazone sodium and sulbactam sodium (1 g, twice a day). Despite intravenous drip infusion of antibiotics, the patient's fever persisted. Thus, we inserted a drainage tube into the largest hepatic cyst with suspected infection under ultrasound guidance. About 3,800 mL of yellow, turbid fluid was drained. Cystography did not show any communication between the intrahepatic bile ducts. Then, 400 mg of minocycline hydrochloride in 40 mL of saline was injected for conglutination. The catheter was clamped and reopened after 24 h. *Streptococcus parasanguinis* was isolated from the cyst fluid. Cystic fluid carbohydrate antigen 19-9 (CA19-9) level was 264,338 U/mL (normal range for serum CA19-9 level: 0–35). However, neoplastic cells were not detected in the cystic fluid. We injected minocycline hydrochloride 2 more times, on days 4 and 12, after catheter insertion. After drainage, abdominal symptoms and fever resolved, and serum CRP and creatinine levels improved (Fig. 2). The amount of daily drainage gradually decreased from approximately 1,000 mL to about 100 mL. Follow-up CT scan and abdominal US showed prominent regression of the hepatic cyst and relief of the ureteral obstruction (Fig. 3). Thus, we removed the catheter 19 days after insertion. Regarding his gallstones, magnetic resonance cholangiopancreatography

(MRCP) also revealed a common bile duct stone. Thus, we treated him by endoscopic retrograde cholangiopancreatography (ERCP), sphincterotomy, and stone removal. ERCP did not show any communication between the intrahepatic bile ducts. His asymptomatic gallstones were followed up without cholecystectomy due to his age. The patient was then discharged in excellent general condition 1 month after admission. He has since shown an uneventful course without reenlargement of the hepatic cyst.

Discussion

Simple hepatic cysts are most often asymptomatic and are increasingly being diagnosed because of improved imaging techniques. They are estimated to have a prevalence of 2.5–4.7% in the general population and 11.3% in patients referred to a hospital, with increasing frequency with advancing age [5, 6]. Infection of hepatic cysts occurs in 1–3% of patients with polycystic liver disease and autosomal dominant polycystic kidney disease [7]. Bacterial organisms can invade a hepatic cyst through the bile ducts or a hematogenous route [8]. In terms of microbiological findings, 77% of patients with an infected hepatic cyst show positive cyst aspiration culture, with *Escherichia coli* being the most common isolated pathogen [9]. Besides *E. coli*, *Klebsiella pneumoniae*, *Enterococcus faecium*, *Enterobacter cloacae*, *Pseudomonas aeruginosa*, *Haemophilus parainfluenzae*, and others have been isolated from cyst aspiration culture in patients with an infected hepatic cyst [9]. In our case, a culture of cystic fluid was positive for *S. parasanguinis*, which presumably came from a hematogenous route, because *S. parasanguinis* is an indigenous bacterium in the oral cavity, and there was no communication between the intrahepatic bile ducts despite bearing a common bile duct stone.

Cystic fluid CA19-9 levels were markedly elevated in our patient, while serum CA19-9 levels were within the normal range. Cystic fluid CA19-9 may be produced from a biliary-type epithelium that covers the cystic lumen [10]. Serum and cyst fluid CA19-9 levels are elevated in patients not only with cystadenocarcinoma but also with infected hepatic cysts [10, 11]. In our patient, there was no nodular lesion in the cyst, and cytology of the cystic fluid was negative; thus, we concluded that cystadenocarcinoma was unlikely.

Management of symptomatic hepatic cysts consists of surgery or percutaneous treatment [12]. In terms of surgical treatment, cyst deroofing, cystectomy, cystoenterostomy, and liver resection have been performed [13]. As for percutaneous treatment, ultrasound-guided percutaneous drainage followed by administration of a sclerosing agent such as ethanol, minocycline hydrochloride, or monoethanolamine oleate has been successful with minimal invasion, and the recurrence rate is low [14].

Ureteral obstruction can result from mechanical blockade or functional defects, and it can cause hydronephrosis leading to impairment of renal function. Therefore, it is important to resolve hydronephrosis promptly. In our case, in particular, the patient had only the right kidney due to his history of left nephrectomy for renal cell carcinoma; thus, it was absolutely necessary to maintain his renal function by relieving the hydronephrosis. Mechanical causes of ureteral obstruction are congenital, acquired intrinsic defect, and acquired extrinsic defect. In adults, ureteral obstruction is due mainly to acquired defects such as a tumor, calculi, or inflammation. Various acquired extrinsic defects have been reported such as pregnant

uterus, retroperitoneal fibrosis, aortic aneurysm, and carcinoma of the uterus, prostate, or colon [15]. To our knowledge, however, there have been no reports of ureteral obstruction due to a hepatic cyst in the literature. There is one report of hydronephrosis due to a giant hemangioma of the liver [4]. In our case, the presence of hepatic cysts was known for 27 years, but infection might rapidly increase the size of a hepatic cyst following ureteral compression.

In conclusion, we have reported a case of an infected simple hepatic cyst causing urinary tract obstruction leading to hydronephrosis that resolved by ultrasound-guided percutaneous drainage and sclerotherapy with minocycline hydrochloride. Although ureteral obstruction due to compression with a hepatic cyst is very rare, the mass effect of an enlarged hepatic cyst should be considered as a possible cause of hydronephrosis, and it should be promptly treated with drainage to relieve urinary tract compression.

Statement of Ethics

The authors have no ethical conflicts to disclose.

Disclosure Statement

The authors declare no conflicts of interest for this article.

References

- 1 Musielak MC, Singh R, Hartman E, Bernstein J: Simple hepatic cyst causing inferior vena cava thrombus. *Int J Surg Case Rep* 2014;5:339–341.
- 2 Miyamoto M, Oka M, Izumiya T, Nagaoka T, Ishihara Y, Ueda K, Enomoto S, Yanaoka K, Ariei K, Tamai H, Shimizu Y, Ichinose M: Nonparasitic solitary giant hepatic cyst causing obstructive jaundice was successfully treated with monoethanolamine oleate. *Intern Med* 2006;45:621–625.
- 3 Miliadis L, Giannakopoulos T, Boutsikos G, Terzis I, Kyriazanos ID: Spontaneous rupture of a large non-parasitic liver cyst: a case report. *J Med Case Rep* 2010;4:2.
- 4 Aguilar A, Pozuelo O, Castells M, Vargas C: Hydronephrosis: a rare complication of hepatic haemangiomas. *BJU Int* 2002;90:621.
- 5 Caremani M, Vincenti A, Benci A, Sassoli S, Tacconi D: Ecographic epidemiology of non-parasitic hepatic cysts. *J Clin Ultrasound* 1993;21:115–118.
- 6 Caremani M, Vincenti A, Benci A, Sassoli S, Tacconi D: The occurrence of asymptomatic and symptomatic simple hepatic cysts. A prospective, hospital-based study. *Clin Radiol* 2005;60:1026–1029.
- 7 Grunfeld JP, Albouze G, Jungers P, Landais P, Dana A, Droz D, Moynot A, Lafforgue B, Boursztyn E, Franco D: Liver changes and complications in adult polycystic kidney disease. *Adv Nephrol Necker Hosp* 1985;14:1–20.
- 8 Yoshida H, Onda M, Tajiri T, Mamada Y, Tanai N, Mineta S, Hirakata A, Futami R, Arima Y, Inoue M, Hatta S, Kishimoto A: Infected hepatic cyst. *Hepatogastroenterology* 2003;50:507–509.
- 9 Lantinga MA, Drenth JP, Gevers TJ: Diagnostic criteria in renal and hepatic cyst infection. *Nephrol Dial Transplant* 2015;30:744–751.
- 10 Wijnands TF, Lantinga MA, Drenth JP: Hepatic cyst infection following aspiration sclerotherapy: a case series. *J Gastrointest Liver Dis* 2014;23:441–444.

- 11 Yanai H, Tada N: A simple hepatic cyst with elevated serum and cyst fluid CA19-9 levels: a case report. *J Med Case Rep* 2008;2:329.
- 12 Mazza OM, Fernandez DL, Pekolj J, Pfaffen G, Sanchez Claria R, Molmenti EP, de Santibanes E: Management of nonparasitic hepatic cysts. *J Am Coll Surg* 2009;209:733–739.
- 13 Garcea G, Rajesh A, Dennison AR: Surgical management of cystic lesions in the liver. *ANZ J Surg* 2013;83:516–522.
- 14 Blonski WC, Campbell MS, Faust T, Metz DC: Successful aspiration and ethanol sclerosis of a large, symptomatic, simple liver cyst: case presentation and review of the literature. *World J Gastroenterol* 2006;12:2949–2954.
- 15 Seifter JL: Urinary tract obstruction; in Kasper DL, Fauci AS, Hauser SL (eds): *Harrison's Principles of Internal Medicine*, ed 19. New York, McGraw-Hill, 2015, pp 1871–1874.

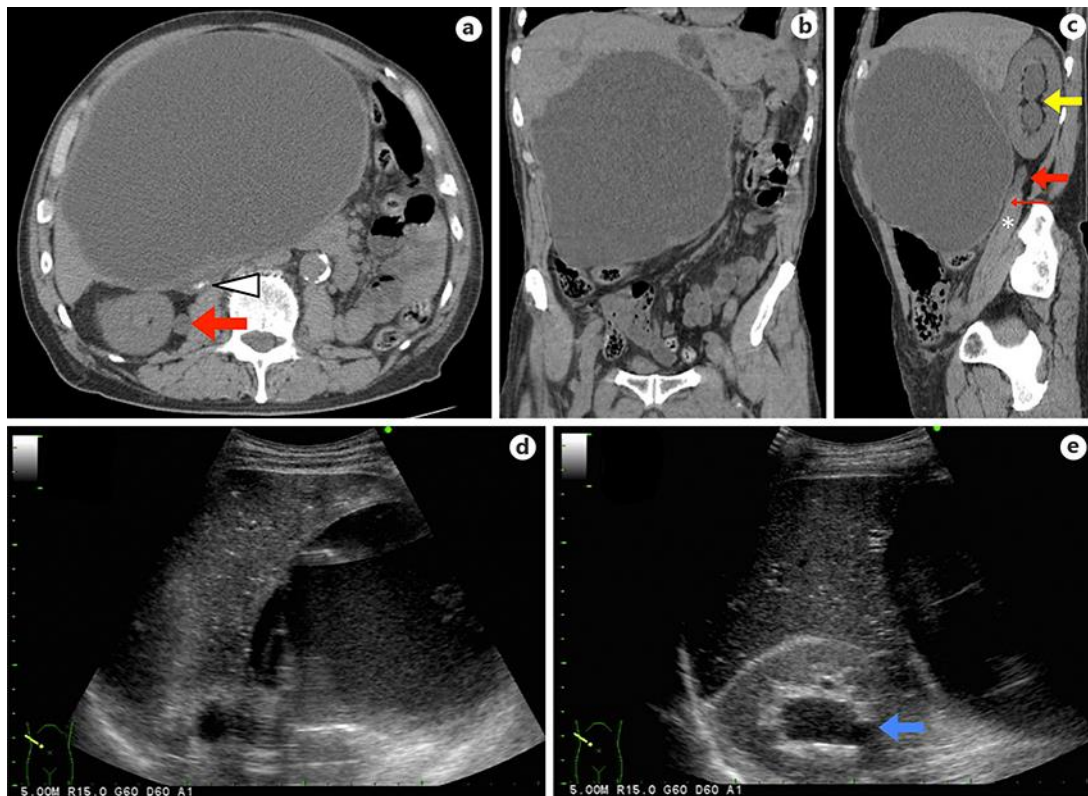


Fig. 1. Plain CT transverse (a), coronal (b), and sagittal (c) sections showing a 20-cm cystic lesion in the right lobe of the liver and dilatation of the right pelvis (yellow arrow) and proximal ureter (red arrow) due to compression of the ureter (thin red arrow) wedged between the hepatic cyst and iliopsoas muscle (asterisk). Gallstones were indicated in the compressed gallbladder (arrowhead). Abdominal US showed a large cystic lesion with homogeneous contents without a septum or calcifications (d), and the right kidney with hydronephrosis (blue arrow) (e).

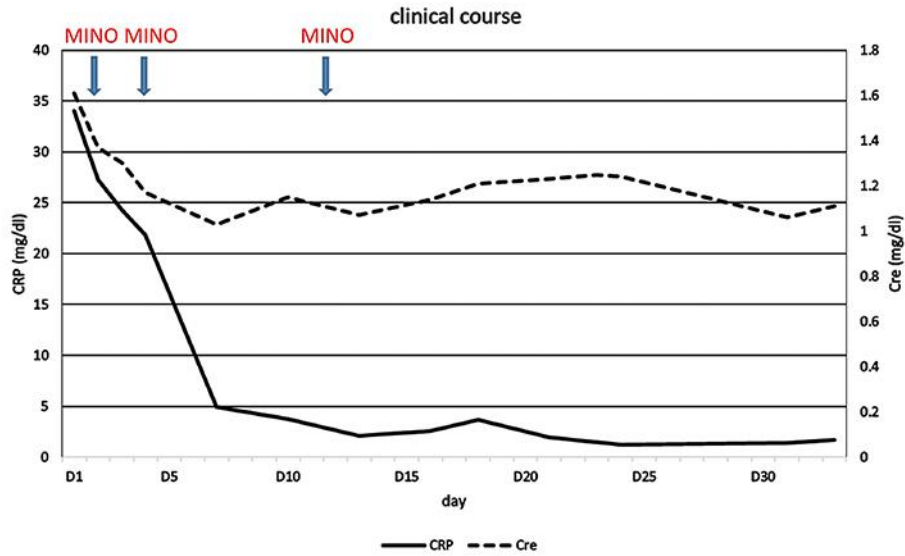


Fig. 2. Changes in the levels of serum CRP and creatinine during the clinical course. CRP, C-reactive protein; Cre, creatinine; MINO, minocycline hydrochloride. After drainage, serum CRP and creatinine levels improved.

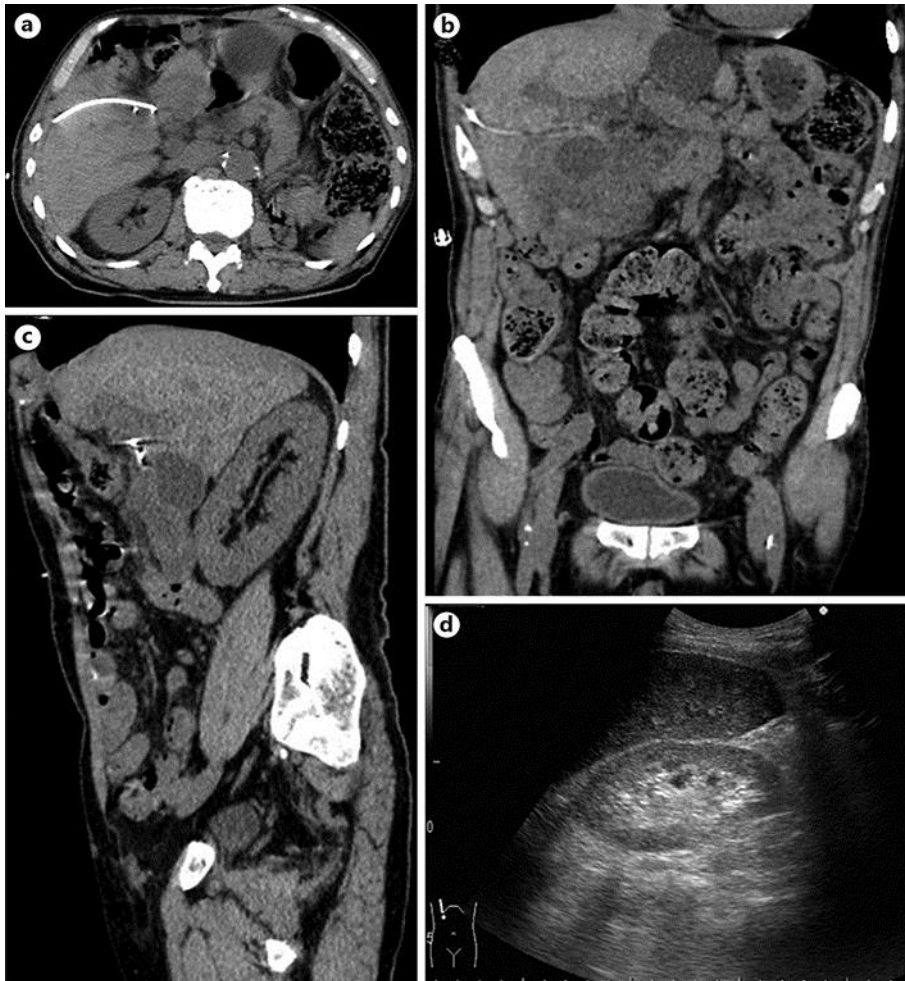

Fig. 3. CT performed 18 days after catheter insertion showed marked regression of the hepatic cyst (a, b) and relief of the ureteral obstruction (c). d Abdominal US showed relief of right hydronephrosis.

Table 1. Laboratory data on admission

	Value	Reference range
White blood cell count, / μ L	5,490	3,500–8,500
Hemoglobin, g/dL	12.1	13.5–17.0
Platelet count, 10^4 / μ L	20.6	15.0–35.0
Total protein, g/dL	6.6	6.7–8.3
Albumin, g/dL	2.9	3.5–5.5
Blood urea nitrogen, mg/dL	31	8–22
Creatinine, mg/dL	1.61	0.6–1.1
Sodium, mmol/L	136	138–146
Potassium, mmol/L	3.6	3.6–4.9
Chloride, mmol/L	100	99–100
Calcium, mg/dL	8.6	8.7–10.3
Glucose, mg/dL	112	70–109
Aspartate aminotransferase, U/L	29	13–33
Alanine aminotransferase, U/L	30	8–42
Alkaline phosphatase, U/L	385	115–359
Lactate dehydrogenase, U/L	143	119–229
Total bilirubin, mg/dL	1.0	0.3–1.2
γ -Glutamyltranspeptidase, U/L	32	10–47
Choline esterase, U/L	122	168–470
Creatine kinase, U/L	31	62–287
Amylase, U/L	40	37–125
C-reactive protein, mg/dL	34.055	0.000–0.300
Prothrombin time, %	60	70–120
International normalized ratio	1.34	
Activated partial thromboplastin time, s	51.7	26.0–36.0
Fibrinogen, mg/dL	934	150–450
FDP, μ g/mL	11.8	0.0–5.0
D-dimer, μ g/mL	1.8	0.0–0.4
CA19-9, U/mL	35	0–35

FDP, fibrin and fibrinogen degradation products.