



Narrative review: pathogenesis, diagnosis, and treatment of sleep-related painful erection

Yutao Wang¹, Jianzhong Zhang², Hongjun Li³

¹Department of Urology, the First Affiliated Hospital of China Medical University, Shenyang, China; ²Department of Urology, Beijing Friendship Hospital, Capital Medical University, Beijing, China; ³Department of Urology, Chinese Academy of Medical Sciences, Peking Union Medical College, Peking Union Medical College Hospital, Beijing, China

Contributions: (I) Conception and design: Y Wang, H Li; (II) Administrative support: H Li; (III) Provision of study materials or patients: Y Wang; (IV) Collection and assembly of data: J Zhang; (V) Data analysis and interpretation: Y Wang, J Zhang; (VI) Manuscript writing: All authors; (VII) Final approval of manuscript: All authors.

Correspondence to: Hongjun Li. Department of Urology, Chinese Academy of Medical Sciences, Peking Union Medical College, Peking Union Medical College Hospital, No. 9 Dongdan Santiao, Dongcheng District, Beijing 100000, China. Email: lihongjun@pumch.cn.

Objective: Through critical analysis and comprehensive review of the limited literature, this paper can help clinicians better identify the pathophysiology of sleep-related painful erections (SRPE) and provide direction for future treatment research.

Background: Patients with SRPE will be awakened by painful erections during sleep, which affects their sleep process and general health. At present, literatures of experimental and clinical research on SRPE disease are limited, as well as long-term reports on its pathogenesis and clinical management.

Methods: We use the PubMed database to obtain sleep-related peer erection literature. The search terms used include sleep, painful, penis and erection. After rigorous screening, the search returned 21 references published between 1987 and 2021.

Conclusions: The main cause of SRPE is obstructive sleep apnea (OSA) syndrome, psychological and spiritual factors, androgen elevation, neuroendocrine regulation and threshold of pain in the REM phase. The combination of multiple medications is the most effective approach to treat sleep-pain-related erections. The combination of CPAP, REM inhibitors and Baclofen has significant effect on SRPE caused by OSA syndrome. This article provides effective support and strategies for doctors to manage SRPE patients through a comprehensive analysis of the pathogenesis mechanism and clinical treatment strategies of SRPE.

Keywords: Sleep-related painful erections (SRPE); pathogenesis; diagnosis; treatment

Submitted Nov 05, 2021. Accepted for publication Dec 16, 2021.

doi: 10.21037/tau-21-1045

View this article at: <https://dx.doi.org/10.21037/tau-21-1045>

Introduction

Sleep-related painful erection (SRPE) is a rare condition which sees patients experiencing frequent erections during rapid eye movement (REM) sleep causing deep penile pain and interrupted sleep. Nocturnal spontaneous erections can be classified into physiological and pathological erections. Nocturnal physiological erections are considered to occur 3–5 times during REM without pain. SRPE is a pathological sleep erection that differs from physiological nocturnal

penile tumescence (NPT), which is characterized by penile pain during REM period and relief after urination (1), and classified as an REM parasomnia by the International Classification of Sleep Disorders by the American Academy of Sleep Medicine (2). As this condition harms the patient's sleep state and physical and mental health, it is critical to explore SRPE and reduce the burden of disease and improve the quality of life of patients. As presently there is no systematic guidance for this condition, this article reviews the mechanisms, diagnosis, and treatment of SRPE

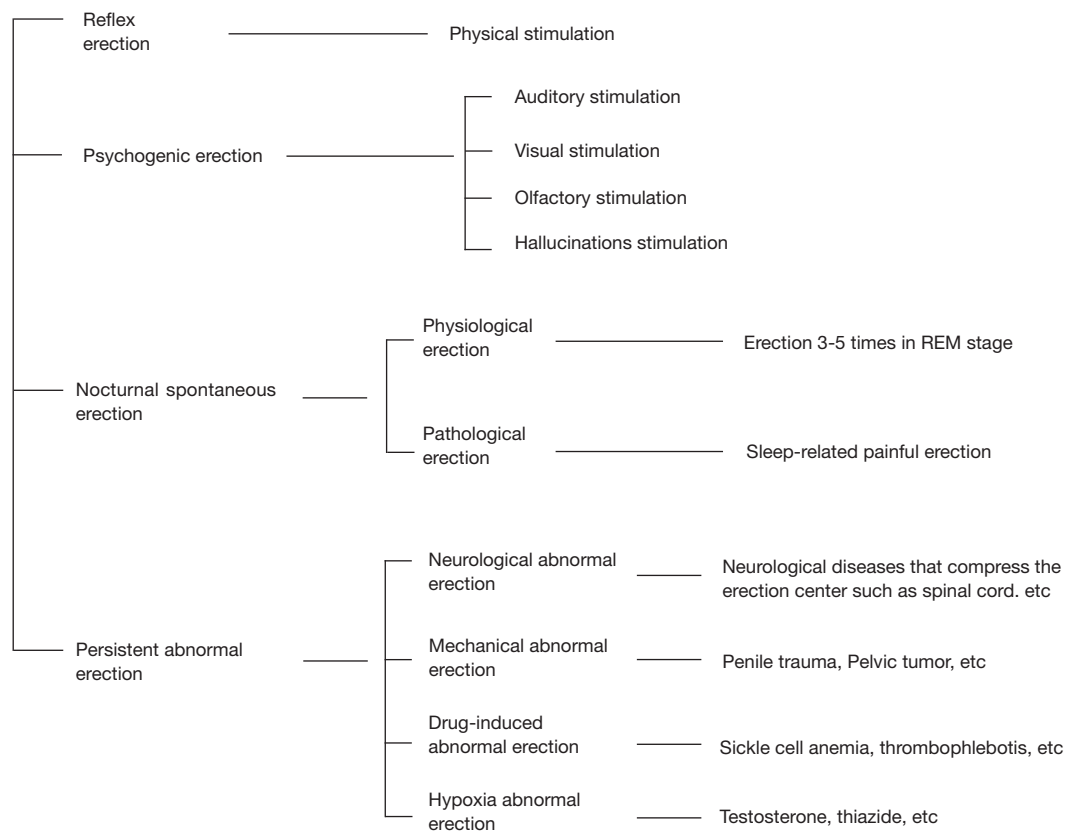


Figure 1 Classification of penile erections.

to help gain a better understanding for both physicians and patients. We present the following article in accordance with the Narrative Review reporting checklist (available at <https://dx.doi.org/10.21037/tau-21-1045>).

Underlying pathological mechanism of sleep related painful erection

Twenty-one sleep related painful erection reference were taken into this section (Table S1). To better understand abnormal penile erection, it is necessary to first consider normal physiologic erection. Penile physiologic erection is caused by relaxation of the smooth muscles of the penile artery and cavernous body activated by the parasympathetic nerve pathway and accompanied by inhibition of the spinal reflex caused by sympathetic nerve excitement (3,4). Penile erection results from interactions of the central nervous system and local factors and is regulated by psychological and hormonal factors (5). Nitric oxide (a neurotransmitter

and molecular signal sensor) and other mediators released by nerves or endothelium play essential roles (4,6).

Penile erection can be classified as reflex erection caused by mechanical stimulation (6), psychogenic erection caused by psychological stimulation (7), nocturnal spontaneously erection, and persistent abnormal erection. NPT is an everyday physiological occurrence which is not caused by sexual stimulation and can physiologically spontaneously occur during REM sleep (8). Men achieve erections three to five times during eight hours of sleep, and each erection may last for at least 30 minutes, regardless of age (9). The detail classification of penile erection is shown in Figure 1.

We summarized the pathogenesis of SRPEs and proposed the pathogenesis concept of “O-PAINT” where “O” represents Obstructive Sleep Apnea (OSA) Syndrome, “P” represents Psychological and spiritual factors, “A” is for Androgen Elevation, “I” is for Compartment Syndrome caused by ischemia, “N” is for Neuroendocrine regulation, and “T” is for Threshold of pain in the REM phase.

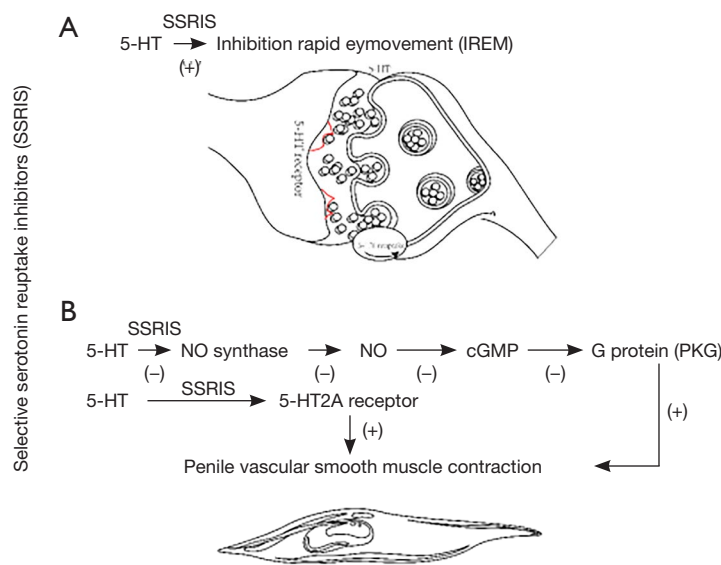


Figure 2 Center and periphery regulation mechanism of 5-HT in sleep related painful erection. SSRIs, Selective serotonin reuptake inhibitors; 5-HT, 5-hydroxytryptamine.

OSA syndrome

Researchers (10-13) have found patients with OSA have different levels of SRPE, which has become the core concept of SRPE widely accepted by scholars. OSA is characterized by frequent episodes of partial or complete collapse of the upper airway during sleep, followed by hypoxia and activation of sympathetic nerves. The apnea event is terminated by awakening, followed by an increase in pulse and blood pressure (14). Hypoxia causes an increase in blood flow to tissues and organs, especially to the cavernous body of the penis, which becomes the physiological mechanism for erections. Continuous positive airway pressure may treat apnea and reduce symptoms, and the mechanism may be mediated by intermittent changes of the autonomic system and blood-gas exchange related to OSAS, interfering with the autonomic nervous system and eventually causing SRPE (10).

Abnormal androgen elevation

Testosterone plays a crucial role in developing and maintaining male sexual characteristics and is an essential participant in nocturnal physiological erections. Changes in testosterone at night are related to sleep, with the level of testosterone during sleep being higher than during wakefulness (15). Testosterone regulates the release of nitric oxide from the nitrenergic nerve fibers in the cavernous nerve

and other non-nitrenergic processes in the cavernous body and central nervous system (16). In contrast, the erectile response to sexual stimulation while awake is independent of the testosterone system (17). Buvat *et al.* showed that androgens regulate the expression levels of nitric oxide synthase and phosphodiesterase 5 (PDE-5) by regulating the NO-cGMP erection signal pathway (18). Therefore, high nocturnal serum testosterone levels are needed for penile erection and may mediate or encourage SRPE via positive regulation of NO.

Nerve and neuroendocrine disorder

In REM sleep, 5-hydroxytryptamine (5-HT) levels are low at the central nerve-neural junction. Selective serotonin reuptake inhibitors (SSRIs) are used to inhibit the REM stage in SRPE patients and improve their symptoms. In addition, SSRIs increase the content of 5-HT in peripheral hematomas. 5-HT inhibits NO synthase, reduces NO synthesis, reduces the content of second messenger cGMP, and reduces the activation level of the G protein pathway, resulting in contraction of vascular smooth muscle (*Figure 2A*) (19,20). 5-HT also directly acts on the 5-HT_{2A} receptors of vascular smooth muscle cells to contract vascular smooth muscle (*Figure 2B*). Therefore, 5-HT neurotransmitter disorders play an important role in the pathogenesis of SRPE (21).

Szücs *et al.* found the posterior cerebral artery of an SRPE patient was compressed on the lateral basilar border of the hypothalamus corresponding to the anatomical position of the preoptic area of the hypothalamus through a cranial MRI examination (22). Central neurotransmitters and neuropeptides act on multiple brain regions to promote the secretion of neurotransmitters to cause or inhibit penile erection (23). One study found that REM-initiating neurons (cholinergic and gamma-aminobutyric neurons) were significantly active during REM, while REM-off neurons (adrenergic and serotonin neurons) which were active during REM, remained silent. Recent studies found that SRPE patients with an abnormal REM stage often complain of gastrointestinal symptoms and nerve-ending abnormalities (small fiber neuropathy). For these reasons, it can be speculated that during REM sleep in patients with SRPE, cholinergic neurons produce more acetylcholine and cause a penile erection. Therefore, neuroendocrine regulation disorder is also a pathogenesis of SRPE.

Psychological and spiritual abnormalities

A study found that the function and anatomy of the penis have no apparent effect on SRPE, and in the reported cases, neurological and neurophysiological examinations were found to be normal (12). Some researchers speculate that SRPE is psychogenic in nature, as repeated awakening and insomnia are related to lack of sleep and anxiety (24). Others speculate that almost all extragonadal endocrine diseases may affect sexual function. Endocrine diseases may be caused by mental and physical involvement, and hormones directly or indirectly regulate the process of erection (25). Meanwhile, mental disorders such as nighttime awakening, anxiety, and irritability often coexist with SRPE, with a high incidence. Psychological is a symptom or manifestation of SRPE, and may also be a trigger or aggravating factor, resulting in a vicious cycle. Therefore, since mental health has significant adverse effects on SRPE patients, special attention must be paid to patients' mental and psychological changes in SRPE diagnosis and treatment, so the improvement of psychological and spiritual status should also become a target of our treatment (13).

Reduced pain threshold in the REM phase

During sleep in healthy adults, non-rapid eye movement (NREM) and REM sleep switch at 90–110-minute intervals. In the first third of the night, light sleep alternates with

slow-wave sleep but as sleep progresses, slow-wave sleep decreases, and REM sleep increases. In the final third of the night, light sleep almost entirely alternates with REM sleep (26). During autonomic nerve function and penile erection, rhythmic changes can be observed in the over-frequency range of 1 to 2 hours (27). During REM sleep and wakefulness, there are many neuronal networks in the ventricular septum, and these neurons coordinate with erection-related activities (28). The relationship between pain and sleep is mutual, as pain may interrupt or disrupt sleep, while poor sleep quality increases pain perception, and the reduction in sleep time and the specific loss of REM sleep can produce hyperalgesia the following morning. Medications and conditions that reduce sleep and REM sleep time may also increase pain (29). Dai *et al.* observed that postoperative pain after male circumcision is very common, especially in the SRE stage (30), and interrupted REM sleep relieved SRE-related incision pain. A study of migraines during sleep found that the decrease in pain threshold was related to increased sleep pressure, and lack of adequate rest may be a factor inducing hyperalgesia (31).

Compartment syndrome caused by ischemia

When the urinary bladder is overfilled at night, the erectile center is stimulated, causing a continuous erection. The inflammation caused by overfilling of the bladder hinders deep venous return, causing continuous erection and pain. Prostatitis, urethritis, and thrombophlebitis can also cause such consequences, and the obstruction of deep venous return leads to penile compartment syndrome, characterized by constant high pressure in a fixed space which impedes microvascular circulation. The pathophysiological feature of penile compartment syndrome is continuous cavernous smooth muscle relaxation and contraction failure accompanied by increased hypoxia in the cavernous body, increased pCO₂, and acidosis (32). Symptoms include evident stiffness of the cavernous body, disordered venous blood outflow, and persistent painful erection, which may cause the trabeculae of the cavernous body of the penis to be exposed to ischemic blood when persistent.

Diagnosis of SRPE

Clinical characteristics

Patients with SRPE often have the clinical characteristics of repeated waking during REM sleep accompanied by painful

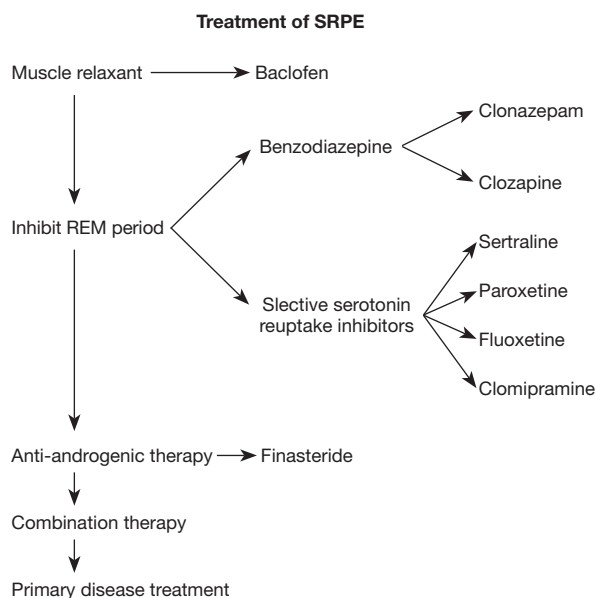


Figure 3 Treatment strategy of SRPE. SRPE, Sleep-related painful erection; REM, rapid eye movement.

erections. Due to the lack of literature support, the effective duration of treatment for the disease is usually 1–3 months, and long-term observation is rare; erections monitored during waking, during intercourse, and during NREM are painless; it is generally believed that the sexual refractory period after ejaculation can make re-erections difficult, and daytime intercourse and ejaculation can inhibit nocturnal erections, but this rule is not followed in SRPE. According to current reports, there is no obvious relationship between the occurrence of SRPE and sexual intercourse, and only one report found the even presence of SRPE after sexual intercourse (1); each episode of pain lasts from minutes to hours; after being awake or urinating, the symptoms may partially abate; the frequency of episodes ranges from one per hour to several times per night; there is no history of sleep disorders or abnormalities; physical examination and auxiliary examinations of the urinary system and nervous system are unremarkable; no evidence of urinary tract infection; serum prostate-specific antigen and testosterone are within the normal range; the disease occurs at all ages, with an average age of onset of 40 years; there are psychological symptoms such as anxiety, nervousness, irritability, and daytime fatigue; color Doppler ultrasound of the penis, prostate, and kidneys show no abnormalities; the International Erectile Function Score and Nocturnal Penile Erectile Measurements indicates varying degrees of erectile

dysfunction; and the intensity of penile erection during pain is grade III–IV (33).

Differential diagnosis of SRPE

SRPE needs to be differentiated from priapism, which is a persistent, often painful penile erection that lasts more than 4 hours and has nothing to do with sexual stimulation. Priapism is classified as ischemic penile priapism, non-ischemic penile priapism, and recurrent penile priapism (34).

In ischemic penile priapism, the cavernous body is stiff, the glans and cavernous body are relaxed, and there is interstitial pressure and damage to the microvessels leading to penile fascial compartment syndrome. Color Doppler ultrasound reveals no blood flow in the cavernous arteries, while body fluid blood gas analysis reveals $pO_2 < 30$ mmHg, $pCO_2 > 60$ mmHg, and $pH < 7.25$ (34). Compared with patients with SRPE, stuttering priapism episodes of ischemia are for the most transient and self-remitting but this priapism is considering harboring of major ischemic priapism. Nearly 30% of patients suffering of stuttering priapism evolve to major episodes of ischemic priapism (34).

Non-ischemic penile priapism is most often caused by penile, perineal, or pelvic trauma, with laceration of cavernous arterioles leading to the formation of arteriole-sinus fistulas, and is often delayed by a few days.

Recurrent priapism is characterized by long-term periodic erection episodes that are sometimes painful, usually occurring during sleep or sexual stimulation, and may subside spontaneously. It is a common complication of sickle cell disease, caused by microvascular occlusion secondary to hemolysis and stasis (35–37).

Treatment

Although SPRE is a rare disease or symptom, the harm it causes merits attention. As understanding of the pathogenesis of SRPE is not systematically complete, there is currently no comprehensive treatment plan or guidance. While treatment principles generally correspond to the pathophysiological mechanism related to SRPE, due to the complexity and diversity of the pathogenesis, the objective is to deal with the cause and the symptoms. Current treatment strategies for SRPE are summarized in *Figure 3*, and can be seen to focus on both etiological treatment and symptom control. However, as the present understanding of the underlying mechanism and comprehension of SRPE is

unclear, the purpose and principles of treatment are mainly to control symptoms and improve patients' quality of life.

Treatment protocol to control symptoms of SRPE

General therapy

Muscle relaxants

Muscle relaxants are the first choice for SRPE treatment, with medications such as baclofen, and pregabalin often used. Baclofen is a γ -aminobutyric acid receptor agonist that alleviates the sleep process, and for erections in children, has an analgesic effect. Szücs *et al.* conducted a 10-year follow-up of 14 SRPE patients treated with baclofen at 10–75 mg, and found 41.6% of patients had complete resolution of their pain, while 58.4% experienced symptoms after withdrawal (22). These researchers suggest that baclofen and other muscle relaxants can serve as short-acting first-line treatments.

REM inhibitors

Benzodiazepines such as diazepam as clonazepam have also been employed in the treatment of SPRE (38–40). Kuhadiya *et al.* (41) describe a 77-year-old patient treated with 1 mg clonazepam once per night for 1 year who achieved good clinical results. Commonly used antidepressants including clomipramine, paroxetine, fluvoxamine, clozapine, amitriptyline, and sertraline are also used, having anticholinergic, antihistamine, and other antidepressant effects, as well as inhibiting REM sleep (38,40).

Anti-androgen therapy

Anti-androgen therapy is only applicable when there is no longer a desire to pursue sexual activity on behalf of the patient or when the previously mentioned medications are ineffective. Commonly used medications such as estradiol, finasteride, bicalutamide tablets, and goserelin acetate sustained-release implants are associated with primary adverse reactions including low libido and erectile dysfunction, as the level of antiandrogenic therapy required often suppresses testosterone levels below the castration level (1.6 nmol/L). Vreugdenhil *et al.* found vicalutamide and progesterone were not effective and caused both low libido and erectile dysfunction (13).

Anti-depressive therapy

Studies have shown that antidepressants, in addition to inhibiting REM in patients with SRPE, also improve anxiety and stress (42). van Driel *et al.* and Rourke *et al.* found that monoamine oxidase inhibitors, benzodiazepines, tricyclic antidepressants, and SSRIs all inhibited REM and

were effective for SRPE (40,43).

Combination therapy

Currently, the strategy of combined therapy is used in the treatment of SRPE. While baclofen is commonly used to relieve the pain symptoms of SRPE patients, in those with primary disease it is not ideal (13). Clinical studies by Van Driel and Moreira *et al.* (40,44) found that the use of monoamine oxidase inhibitors, benzodiazepines, tricyclic antidepressants, and selective serotonin reuptake inhibition alleviated symptoms of SRPE to varying degrees. Other researchers also believe that combination therapy should be the primary treatment strategy for SRPE (10). Zhang *et al.* reported a patient with OSA syndrome who received significant relief after combined treatment for one week. They found that improvement of ventilation alone is not enough, and the combined suppression of REM period and use of antidepressant could further improve the clinical symptoms of patients at different stages, further suggesting the need for combination therapy for SRPE (42).

Etiological treatment

Improve symptoms of respiratory obstruction

When there are symptoms of airway obstruction, the first treatment principle is to improve ventilation. Continuous positive airway pressure to treat respiratory symptoms can improve SRPE symptoms in a short period. Zhang *et al.* found that CPAP combined with tamsuloxine (0.2 mg/day, 0.8 mg/day) and escitalopram (20 mg/day) for one month had a significant effect on SRPE patients with OSA (42). The principle may be that positive pressure ventilation therapy improves sympathetic and parasympathetic neurotransmitter disorders caused by hypoxia. When the patient cannot tolerate positive pressure ventilation, an oral appliance was effective in improving ventilation (45). The principle of the oral appliance is to indirectly change the positions of the tongue, soft palate, and airway by moving the mandible forward and downward. Uvulopalatopharyngoplasty can also treat primary disease (46).

Locally improve inflammation and urine retention in the bladder

When patients have cystitis, prostatitis, and urethritis, the primary disease can be treated with antibiotics first, and anticoagulant medications can relieve the local obstruction of deep vein reflux to relieve the symptoms of SRPE (47).

Conclusions

Current understanding of the pathogenesis of SRPE can be summarized as abnormal androgen elevation, neuroendocrine disorders, psychological and mental abnormalities, lower pain threshold in REM-stage, and obstructive sleep breathing syndrome. According to literature reports, multiple drugs are applied to provide relief for SRPE patients including baclofen and clonazepam. However, the long-term use of baclofen is not advisable, and a combination of multiple drug treatments is the main strategy for these patients.

For these reasons, prospective cohort observation studies of currently proposed treatment methods and further investigation of the regulation of central and peripheral nerve signal pathways and pathological regulation mechanisms of SRPE are urgently required.

Acknowledgements

We thank the authors of the studies referenced in this article for their work.

Funding: None.

Footnote

Reporting Checklist: The authors have completed the Narrative Review reporting checklist. Available at <https://dx.doi.org/10.21037/tau-21-1045>

Conflicts of Interest: All authors have completed the ICMJE uniform disclosure form (available at <https://dx.doi.org/10.21037/tau-21-1045>). The authors have no conflicts of interest to declare.

Ethical Statement: The authors are accountable for all aspects of the work in ensuring that questions related to the accuracy or integrity of any part of the work are appropriately investigated and resolved.

Open Access Statement: This is an Open Access article distributed in accordance with the Creative Commons Attribution-NonCommercial-NoDerivs 4.0 International License (CC BY-NC-ND 4.0), which permits the non-commercial replication and distribution of the article with the strict proviso that no changes or edits are made and the original work is properly cited (including links to both the

formal publication through the relevant DOI and the license). See: <https://creativecommons.org/licenses/by-nc-nd/4.0/>.

References

1. Barnhoorn PC, Gianotten WL, van Driel MF. Sleep-Related Painful Erections Following Sexual Intercourse. *Arch Sex Behav* 2018;47:815-7.
2. Sateia MJ. International classification of sleep disorders-third edition: highlights and modifications. *Chest* 2014;146:1387-94.
3. Argiolas A, Melis MR. Central control of penile erection: role of the paraventricular nucleus of the hypothalamus. *Prog Neurobiol* 2005;76:1-21.
4. Burnett AL. The science and practice of erection physiology: story of a revolutionary gaseous molecule. *Trans Am Clin Climatol Assoc* 2019;130:51-9.
5. Priviero FB, Leite R, Webb RC, et al. Neurophysiological basis of penile erection. *Acta Pharmacol Sin* 2007;28:751-5.
6. Andersson KE. Mechanisms of penile erection and basis for pharmacological treatment of erectile dysfunction. *Pharmacol Rev* 2011;63:811-59.
7. Basson R. Human sexual response. *Handb Clin Neurol* 2015;130:11-8.
8. Corona G, Isidori AM, Aversa A, et al. Endocrinologic Control of Men's Sexual Desire and Arousal/Erection. *J Sex Med* 2016;13:317-37.
9. Schmidt MH, Schmidt HS. Sleep-related erections: neural mechanisms and clinical significance. *Curr Neurol Neurosci Rep* 2004;4:170-8.
10. Abouda M, Jomni T, Yangui F, et al. Sleep-Related Painful Erections in a Patient With Obstructive Sleep Apnea Syndrome. *Arch Sex Behav* 2016;45:241-5.
11. Ferré A, Vila J, Jurado MJ, et al. Sleep-related painful erections associated with obstructive sleep apnea syndrome. *Arch Sex Behav* 2012;41:1059-63.
12. Vreugdenhil S, Weidenaar AC, de Jong IJ, et al. Sleep-Related Painful Erections-A Case Series of 24 Patients Regarding Diagnostics and Treatment Options. *Sex Med* 2017;5:e237-43.
13. Vreugdenhil S, Weidenaar AC, de Jong IJ, et al. Sleep-Related Painful Erections: A Meta-Analysis on the Pathophysiology and Risks and Benefits of Medical Treatments. *J Sex Med* 2018;15:5-19.
14. Ralls F, Cutchen L. A contemporary review of obstructive sleep apnea. *Curr Opin Pulm Med* 2019;25:578-93.

15. Andersen ML, Tufik S. The effects of testosterone on sleep and sleep-disordered breathing in men: its bidirectional interaction with erectile function. *Sleep Med Rev* 2008;12:365-79.
16. Montorsi F, Oettel M. Testosterone and sleep-related erections: an overview*. *J Sex Med* 2005;2:771-84.
17. Gooren LJ, Saad F. Recent insights into androgen action on the anatomical and physiological substrate of penile erection. *Asian J Androl* 2006;8:3-9.
18. Buvat J, Montorsi F, Maggi M, et al. Hypogonadal men nonresponders to the PDE5 inhibitor tadalafil benefit from normalization of testosterone levels with a 1% hydroalcoholic testosterone gel in the treatment of erectile dysfunction (TADTEST study). *J Sex Med* 2011;8:284-93.
19. Angulo J, Peiró C, Sanchez-Ferrer CF, et al. Differential effects of serotonin reuptake inhibitors on erectile responses, NO-production, and neuronal NO synthase expression in rat corpus cavernosum tissue. *Br J Pharmacol* 2001;134:1190-4.
20. Kayki-Mutlu G, Koch WJ. Nitric Oxide and S-Nitrosylation in Cardiac Regulation: G Protein-Coupled Receptor Kinase-2 and β -Arrestins as Targets. *Int J Mol Sci* 2021;22:521.
21. Lau DH, Thompson CS, Mumtaz FH, et al. Serotonin induces a biphasic response in rabbit cavernosal smooth muscle: relevance to the erectile process. *Urol Int* 2007;79:255-61.
22. Szücs A, Janszky J, Barsi P, et al. Sleep-related painful erection is associated with neurovascular compression of basal forebrain. *J Neurol* 2002;249:486-7.
23. Sanna F, Bratzu J, Argiolas A, et al. Oxytocin induces penile erection and yawning when injected into the bed nucleus of the stria terminalis: Involvement of glutamic acid, dopamine, and nitric oxide. *Horm Behav* 2017;96:52-61.
24. Calvet U. Painful nocturnal erection. *Sleep Med Rev* 1999;3:47-57.
25. Balercia G, Boscaro M, Lombardo F, et al. Sexual symptoms in endocrine diseases: psychosomatic perspectives. *Psychother Psychosom* 2007;76:134-40.
26. Voss U. Functions of sleep architecture and the concept of protective fields. *Rev Neurosci* 2004;15:33-46.
27. Schulz H, Salzarulo P. Forerunners of REM sleep. *Sleep Med Rev* 2012;16:95-108.
28. Gulia KK, Kayama Y, Koyama Y. Assessment of the septal area neuronal activity during penile erections in rapid eye movement sleep and waking in the rats. *J Physiol Sci* 2018;68:567-77.
29. Roehrs T, Hyde M, Blaisdell B, et al. Sleep loss and REM sleep loss are hyperalgesic. *Sleep* 2006;29:145-51.
30. Dai AJ, Li M, Wang LL, et al. Improvement of Erection Related Incision Pain in Circumcision Patients using Interrupted Rapid Eye Movement Sleep: A Randomized Controlled Study. *Urol J* 2018;15:126-31.
31. Engstrøm M, Hagen K, Bjørk MH, et al. Sleep quality, arousal and pain thresholds in migraineurs: a blinded controlled polysomnographic study. *J Headache Pain* 2013;14:12.
32. Shigehara K, Namiki M. Clinical Management of Priapism: A Review. *World J Mens Health* 2016;34:1-8.
33. Ferini-Strambi L, Oldani A, Zucconi M, et al. Sleep-related painful erections: clinical and polysomnographic features. *J Sleep Res* 1996;5:195-7.
34. Salonia A, Eardley I, Giuliano F, et al. European Association of Urology guidelines on priapism. *Eur Urol* 2014;65:480-9.
35. Broderick GA. Priapism and sickle-cell anemia: diagnosis and nonsurgical therapy. *J Sex Med* 2012;9:88-103.
36. Broderick GA, Kadioglu A, Bivalacqua TJ, et al. Priapism: pathogenesis, epidemiology, and management. *J Sex Med* 2010;7:476-500.
37. Burnett AL, Sharlip ID. Standard operating procedures for priapism. *J Sex Med* 2013;10:180-94.
38. Mellado M. A case of sleep-related painful erections with chronic daytime genital discomfort. *Urologia* 2015;82:184-6.
39. Steiger A, Benkert O. Examination and treatment of sleep-related painful erections--a case report. *Arch Sex Behav* 1989;18:263-7.
40. van Driel MF, Beck JJ, Elzevier HW, et al. The treatment of sleep-related painful erections. *J Sex Med* 2008;5:909-18.
41. Kuhadiya ND, Desai A, Reisner M. Sleep-related painful erections in an elderly man successfully treated using clonazepam. *J Am Geriatr Soc* 2014;62:407-8.
42. Zhang J, Xiao Y, Li H. Sleep-related painful erection in a patient with obstructive sleep apnea syndrome. *Int J Impot Res* 2019;31:150-1.
43. Rourke KF, Fischler AH, Jordan GH. Treatment of recurrent idiopathic priapism with oral baclofen. *J Urol* 2002;168:2552; discussion 2552-3.
44. Moreira DM, Pimentel M, da Silva Moreira BF, et al. Recurrent priapism in the young patient treated with baclofen. *J Pediatr Urol* 2006;2:590-1.
45. Chang HP, Chen YF, Du JK. Obstructive sleep apnea treatment in adults. *Kaohsiung J Med Sci* 2020;36:7-12.

46. Sheen D, Abdulateef S. Uvulopalatopharyngoplasty. *Oral Maxillofac Surg Clin North Am* 2021;33:295-303.
47. Hu Y, Niu X, Wang G, et al. Chronic prostatitis/chronic pelvic pain syndrome impairs erectile function through increased endothelial dysfunction, oxidative stress,

apoptosis, and corporal fibrosis in a rat model. *Andrology* 2016;4:1209-16.

(English Language Editor: B. Draper)

Cite this article as: Wang Y, Zhang J, Li H. Narrative review: pathogenesis, diagnosis, and treatment of sleep-related painful erection. *Transl Androl Urol* 2021;10(12):4422-4430. doi: 10.21037/tau-21-1045