



# Comparison of serratus anterior plane block with epidural and paravertebral block in critically ill trauma patients with multiple rib fractures

Paul I Bhalla ,<sup>1</sup> Stuart Solomon,<sup>1</sup> Ray Zhang,<sup>1</sup> Cordelie E Witt ,<sup>2,3</sup> Arman Dagal,<sup>1</sup> Aaron M Joffe<sup>1</sup>

<sup>1</sup>Department of Anesthesiology and Pain Medicine, Harborview Medical Center, Seattle, Washington, USA

<sup>2</sup>Department of Surgery, University of Washington, Seattle, Washington, USA

<sup>3</sup>Harborview Injury Prevention and Research Center, University of Washington, Seattle, Washington, USA

## Correspondence to

Dr Paul I Bhalla; pbhalla@uw.edu

This paper was presented at American Society of Anesthesiologists Annual Meeting 2018.

Received 7 October 2020  
Accepted 10 December 2020

## ABSTRACT

**Background** Pain from rib fractures is associated with significant pulmonary morbidity. Epidural and paravertebral blocks (EPVBs) have been recommended as part of a multimodal approach to rib fracture pain, but their utility is often challenging in the trauma intensive care unit (ICU). The serratus anterior plane block (SAPB) has potential as an alternative approach for chest wall analgesia.

**Methods** This retrospective study compared critically injured adults sustaining multiple rib fractures who had SAPB (n=14) to EPVB (n=25). Patients were matched by age, body mass index, American Society of Anesthesiology Physical Status, whether the patient required intubation, number of rib fractures and injury severity score. Outcome measures included hospital length of stay, ICU length of stay, preblock and post block rapid shallow breathing index (RSBI) in intubated patients, pain scores and morphine equivalent doses administered 24-hour preblock and post-block in non-intubated patients, and mortality.

**Results** There were no demographic differences between the two groups after matching. Nearly all of the patients who received either SAPB or EPVB demonstrated a reduction in RSBI or pain scores. The preblock RSBI was higher in the serratus anterior plane block group, but there was no difference between any of the other outcome measures.

**Discussion** This retrospective study of our institutional data suggests no difference in efficacy between the serratus anterior plane block and neuraxial block for traumatic rib fracture pain in critically ill patients, but the sample size was too small to show statistical equivalence. Serratus anterior plane block is technically easier to perform with fewer theoretical contraindications compared with traditional neuraxial block. Further study with prospective comparative trials is warranted.

**Level of evidence** Retrospective matched cohort; Level IV.

## BACKGROUND

Inadequately treated chest wall pain in patients with rib fractures is associated with chest wall splinting and increased risk of hypoventilation, atelectasis and pneumonia.<sup>1,2</sup> Provision of analgesia in this setting is challenging. Reliance on opioids is undesirable due to the potential to exacerbate hypoventilation, sedation and hyperalgesia. Non-opioid medications used as part of a multimodal strategy include acetaminophen, non-steroidal anti-inflammatory drugs,

gabapentinoids and ketamine; however, their utility is limited in the context of multiorgan failure, traumatic brain injury, delirium or prolonged periods of severe pain.

The potential benefit of regional over opioid-based analgesia for blunt chest wall trauma has been reported.<sup>3-5</sup> The Eastern Association for the Surgery of Trauma conditionally recommends epidural analgesia and multimodal analgesia for patients with blunt thoracic trauma, while noting that paravertebral block may provide equivalent pain relief to epidural block.<sup>6</sup> In practice, clinicians may be reluctant to perform epidural or paravertebral blocks (EPVBs) due to coagulopathy, active infection, hemodynamic instability, positioning limitations resulting from other injuries or the presence of neurologic or spine injuries.<sup>7</sup> Furthermore, recognition of EPVB-related complications such as nerve injury or epidural hematoma is impaired in sedated and critically ill patients.

The serratus anterior plane block (SAPB) uses ultrasound guidance to place local anesthetic into the fascial plane between serratus anterior and latissimus dorsi muscles, or between serratus anterior muscle and underlying rib.<sup>8</sup> Clinical and MRI studies have documented spread of the injectate resulting in a block of the lateral cutaneous branch of the intercostal nerves from T2 through T10 dermatomes. The efficacy of SAPB has been reported in thoracic and chest wall surgery in breast surgery and for rib fracture pain.<sup>9-13</sup>

SAPB has been used in our institution since 2016 for analgesia for rib fracture pain. It has grown in popularity compared with EPVB as it is technically easier to perform and theoretically safer due to the anatomical avoidance of major neurovascular structures. However, there are no studies directly comparing SAPB to EPVB in critically ill trauma patients with multiple rib fractures. As a preliminary step towards designing a prospective trial, we performed a retrospective assessment of the efficacy and safety of SAPB placed in critically injured adults admitted to our hospital with multiple rib fractures by comparing the analgesic and ventilatory benefit of SAPB to an individually matched cohort who received the traditional standard of EPVB.

## METHODS

The study design is a retrospective matched cohort. All patients included were cared for at Harborview Medical Center (HMC). HMC is

© Author(s) (or their employer(s)) 2021. Re-use permitted under CC BY-NC. No commercial re-use. See rights and permissions. Published by BMJ.

**To cite:** Bhalla PI, Solomon S, Zhang R, et al. *Trauma Surg Acute Care Open* 2021;**6**:e000621.

a regional level one trauma hospital in Seattle, Washington, with a blunt trauma admission rate of 4000–4500 per year, including approximately 600 patients with greater than three rib fractures. Our study population included patients  $\geq 18$  years of age who were cared for in the intensive care unit (ICU) between 1 April 2017 and 30 September 2017 and received an SAPB for rib fracture pain.

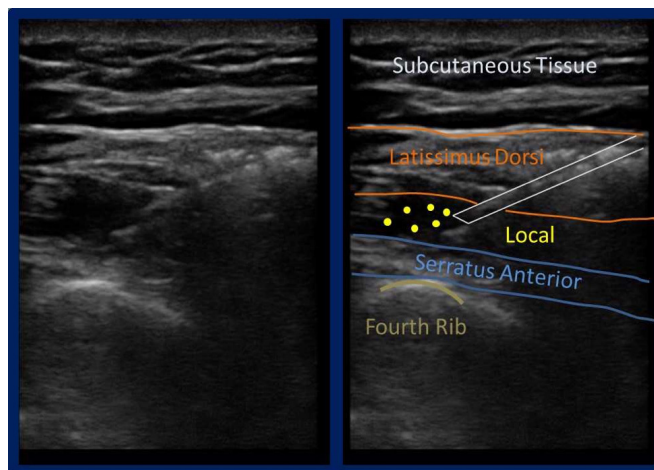
All patients were cared for in the trauma/surgical ICU and referred to the acute pain service (APS) in accordance with a local rib fracture management protocol.<sup>14</sup> The pain control portion of this protocol suggests initial commencement of multimodal systemic analgesia followed by APS referral if uncontrolled pain persists or ventilatory parameters have not improved. The decision to offer regional analgesia for pain control is at the discretion of the attending acute pain physician, based on potential risks and benefits. Traditionally, EPVB has been offered for treatment of pain related to traumatic rib fractures, but since 2016, SAPB has also been used when EPVB is contraindicated or technically infeasible.

A retrospective chart review was performed in order to identify cases where SAPB was performed for pain due to multiple rib fractures in the ICU. The terms ‘serratus’, ‘anterior’, ‘block’ and ‘rib fractures’ were searched within our electronic medical record to identify these patients. Cases were filtered for ICU admission. Demographics including age, BMI, American Society of Anesthesiology Physical Status, Injury Severity Score (ISS), chest Abbreviated Injury Score (AIS), number of rib fractures, intubation status at time of block, ICU and hospital LOS, and all-cause mortality were obtained.

After obtaining this dataset, we matched a cohort of 114 critically ill trauma patients from our existing institutional trauma registry who had received an epidural for bilateral rib fracture pain or paravertebral block for unilateral rib fracture pain between 2014 and 2017. We chose to include both paravertebral and epidural procedures together given the evidence for similar efficacy and outcomes in this population and in patients undergoing thoracotomy.<sup>15–16</sup> In order to reduce comparison heterogeneity as much as possible, patients were individually matched to our SAPB cohort based first on intubation status, then followed by the presence of thoracostomy tube, age, chest AIS, ISS and total number and laterality of rib fractures. At least one EPVB patient was matched for each SAPB patient and, in some instances, there were multiple matches for each SAPB patient. A total of 25 patients receiving EPVB were able to be appropriately matched.

To evaluate the efficacy of SAPB and EPVB procedures in non-intubated patients, we compared patients’ self-reported numerical pain scores (0–10) and opioid use, measured in morphine equivalent doses of all opioids received in the 24 hours before and after the procedure was performed. For intubated patients, we compared the preprocedure and postprocedure rapid shallow breathing index (RSBI), defined as the respiratory rate divided by the tidal volume in milliliters. RSBI is commonly used as a measure of extubation readiness and an indirect measure of analgesia.<sup>17</sup> These parameters were measured during a spontaneous breathing trial (SBT) per standard local ICU protocol. In addition, for all patients regardless of intubation status, we compared hospital and ICU LOS, and all-cause mortality.

We used Wilcoxon-Mann-Whitney test to compare population and outcome means for significant differences and Pearson’s  $\chi^2$  test for categorical variables. We also used the Two One-Sided T-Test (TOSTT) to compare means for equivalence between SAPB and EPVB groups.



**Figure 1** Serratus anterior plane block; needle between fascial planes of the latissimus dorsi and the serratus anterior muscles.

### SAPB procedure

SAPBs are performed in our ICU with the patient supine and ipsilateral shoulder abducted to allow access to the midaxillary chest wall. An ultrasound machine (M-Turbo, Sonosite, Bothell, Washington) with a 13–6 MHz 38 mm linear probe is used to identify the fourth rib. The probe is then moved laterally toward the midaxillary line at the fourth rib and adjusted in order to identify the latissimus dorsi and serratus muscles in short axis view (figure 1). A 19-gauge 50 mm block needle (Halyard Health, Alpharetta, Georgia) is introduced using an in-plane technique. The needle-tip is directed to lie between the serratus anterior muscle and the underlying rib. Twenty-five milliliters of 0.2% ropivacaine is injected into the plane under continuous ultrasound guidance. A catheter is inserted through the needle, and a continuous infusion of 10 mL per hour of ropivacaine 0.2% is delivered via an infusion pump (CADD-Solis Infusion System, Smith Medical, Minneapolis, Minnesota, USA).

### RESULTS

There was no significant difference in demographic characteristics between SAPB and EPVB populations after matching (table 1). The SAPB group had higher numerical ISS, but this was not statistically significant. A total of 14 SAPBs were performed.

**Table 1** Patient demographics and injury characteristics comparison of outcomes for intubated and non-intubated patients

	SAPB (n=14)	EPVB (n=25)	P value*
Patient demographics and injury characteristics			
Age	57.9±21.1	57.5±16.4	0.69
BMI	27.0±5.1	29.4±7.1	0.27
ASA	2±0.8	2.3±0.6	0.26
Intubated	9 (64)	15 (60)	0.79
Number of rib fractures	8.0±3.4	7.8±2.6	0.93
Chest AIS	3.6±0.6	3.5±0.6	0.55
Total ISS	36.9±11.2	31.7±12.6	0.16

Results are presented as mean±SD or n (%) as appropriate.

\*Where appropriate, the Wilcoxon-Mann-Whitney test and Pearson’s  $\chi^2$  test p value to compare the means between populations was reported; significant p value <0.05.

AIS, Abbreviated Injury Scale; ASA, American Society of Anesthesiologists Physical Status; BMI, body mass index; EPVB, epidural or paravertebral block; ISS, Injury Severity Score; SAPB, serratus anterior plane block.

**Table 2** Comparison of outcomes for intubated patients

	SAPB (n=9)	EPVB (n=15)	P value*
Comparison of outcomes for intubated patients (n=24)			
LOS	22.9±10.9	25.2±6.9	0.77
ICU LOS	12.8±9.2	14.4±7.1	0.59
Preblock RSBI	98.1±40.3	64.4±41.2	0.05
Change in RSBI	40.8±33.9	15.8±33.0	0.08
Mortality	2 (22)	0 (0)	0.06

Results are presented as mean±SD or n (%) as appropriate.

Change in RSBI is expressed as a difference between preblock and postblock RSBI.

\*Where appropriate, the Wilcoxon-Mann-Whitney test and Pearson's  $\chi^2$  test p value to compare the means between populations was reported; significant p value <0.05.

EPVB, epidural or paravertebral block; ICU, intensive care unit; LOS, length of stay; RSBI, rapid shallow breathing index; SAPB, serratus anterior plane block.

These patients were matched to 25 patients who received EPVB. A catheter was left in place for continuous analgesia in 13 of the 14 SAPB block procedures. One catheter was replaced after being dislodged intraoperatively but was counted as one demographic data point in the results.

The outcomes for intubated SAPB and EPVB patients are shown in [table 2](#). For the nine SAPB blocks performed on intubated patients, eight resulted in a decrease in RSBI after the block. Three patients were extubated within 6 hours of block placement. The patient who did not experience a decrease in RSBI continued to fail SBTs due to delirium. There was a significant difference in pre-RSBI score between the SAPB and EPVB populations, with the SAPB subgroup having a higher RSBI score. For the remaining outcome variables, there was no significant difference between intubated groups. Analysis using TOSTT did not demonstrate significant equivalence for change in RSBI (delta 30 breaths/min/L) between EPVB and SAPB patients.

The outcomes for non-intubated SAPB and EPVB patients are shown in [table 3](#). All five SAPB patients had clinically relevant decreases in their pain after the block. Four had a decrease in 24-hour MED after the block, with a mean MED decrease of 34.5 (SD 40.5). The patient who did not have a decrease in MED was not given any opioids 24 hours before or after the block for medical reasons. Again, there was no significant difference in outcomes between SAPB and EPVB for non-intubated groups. Analysis using TOSTT did not

**Table 3** Comparison of outcomes for non-intubated patients

	SAPB (n=5)	EPVB (n=10)	P value*
Comparison of outcomes for non-intubated patients (n=15)			
LOS	13.6±5.9	9.40±3.8	0.13
ICU LOS	2.2±1.1	3.9±2.5	0.16
Preblock pain score	8.0±1.4	7.1±1.7	0.24
Change in pain score	3.8±1.6	3.2±1.6	0.50
Preblock MED use	85.8±91.0	138.4±89.1	0.18
Change in MED use	34.5±40.5	65.6±24.7	0.10
Mortality	0 (0)	1 (10)	0.46

Results are presented as mean±SD or n (%) as appropriate. Pain score is self-reported by patient. MEDs are calculated as 24-hour use before and after block.

\*Where appropriate, the Wilcoxon-Mann-Whitney test and Pearson's  $\chi^2$  test p value to compare the means between populations was reported; significant p value <0.05.

EPVB, epidural or paravertebral block; LOS, length of stay; MED, morphine equivalent dose (mg); SAPB, serratus anterior plane block.

demonstrate significant equivalence for change in numerical rating of pain (delta 2) or MED (delta 30 mg) between EPVB and SAPB patients.

## DISCUSSION

We observed improvement in pain control, opioid use and measures of respiratory function that appear to be not significantly different to that seen in a matched cohort receiving EPVB in critically ill trauma patients with multiple rib fractures. However, tests for equivalence of the primary outcomes (change in RSBI in intubated and change in MED and pain score in non-intubated patients) between patients receiving EPVB and SAPB were not significant, indicating that these preliminary data are underpowered to detect statistical difference or equivalence.

Importantly, many of the SAPBs were performed in patients who had relative contraindications to placement of EPVB, including the presence of spine fractures, an inability to appropriately position the patient, a continuing need for anticoagulation or severe critical illness. Unique to this study, the feasibility of SAPB was demonstrated in intubated as well as non-intubated patients. No complications from SAPB were noted in any of our patients.

Patients who received an SAPB in our study had a higher preblock RSBI, with analgesic efficacy that improved RSBI, reduced respiratory splinting and even facilitated successful extubation within hours of the block in some patients. In terms of technical feasibility, our experience is that SAPB is faster and easier to perform than EPVB procedures, mainly due to the need for lateral decubitus positioning for EPVB procedures that can be difficult in intubated, mechanically ventilated ICU patients. While more study is needed, given the growing safety profile and technical ease of fascial plane blocks, they may become a useful diagnostic tool to assess how pain is contributing to a patient's respiratory compromise when considering surgical fixation of segmental rib fractures.

There are several limitations to this study. It is a small, exploratory analysis of retrospective data meant to demonstrate the potential for SAPB efficacy in an often complex and clinically challenging patient population; given the small sample size, it is impossible to recommend SAPB over EPVB without further study. The optimal technique for performance of SAPB and the dose of local anesthetic to be recommended for the SAPB is not known; it has been shown that volume has a bigger influence than choice of plane.<sup>18</sup> It is unknown whether continuous catheter infusions are superior to a single bolus or intermittent boluses of local anesthetic for rib fracture pain. This is unlikely to have had a large influence on our analysis as we only examine data 24 hours after block placement.

The safety and efficacy of SAPB have yet to be directly compared prospectively with neuraxial or opioid analgesia alone. The initial data reported here is heterogeneous given the small sample size and complex nature of traumatic rib fractures in the ICU but may be used to inform a prospective, randomized controlled trial with adequate power to compare the SAPB with neuraxial or multimodal-opioid analgesia alone.

This matched cohort highlights a novel use of a recently described ultrasound-guided block to provide significant analgesia to ICU patients with multiple rib fractures. It is easier to perform and theoretically safer than EPVB. If the efficacy of SAPB is not significantly different to thoracic epidural and paravertebral blocks, the risk-benefit profile of performing SAPB may compare favorably with that of EPVB techniques in this population.

**Acknowledgements** The authors would like to thank the Perioperative & Pain Initiatives in Quality Safety Outcome center at the University of Washington, Seattle, Washington, for its support on data acquisition for this project.

**Contributors** PB helped write the introduction, discussion and abstract, guided the data collection and helped with editing and formatting. SS collected and organized data, created the figure, drafted the overall manuscript and contributed to edits. He also submitted the project to the University of Washington IRB Committee for determination of consent requirement waiver and HIPAA waiver, which was approved. RZ helped with data collection and case matching, drafting of the methods and results section, and overall editing. AJ had the initial idea for the case matching, advised on the data collection and case matching and contributed to major edits of the manuscript. CEW provided trauma registry data, helped with data matching and helped edit the document. AD helped write and edit the document and provided expertise on the interpretation and writing of the results.

**Funding** The authors have not declared a specific grant for this research from any funding agency in the public, commercial or not-for-profit sectors.

**Competing interests** None declared.

**Patient consent for publication** Not required.

**Ethics approval** This study obtained ethics approval from University of Washington, Seattle, WA Institutional Review Board (IRB) STUDY00003775. Informed consent was not required as this was a retrospective study based on chart reviews.

**Provenance and peer review** Not commissioned; externally peer reviewed.

**Open access** This is an open access article distributed in accordance with the Creative Commons Attribution Non Commercial (CC BY-NC 4.0) license, which permits others to distribute, remix, adapt, build upon this work non-commercially, and license their derivative works on different terms, provided the original work is properly cited, appropriate credit is given, any changes made indicated, and the use is non-commercial. See: <http://creativecommons.org/licenses/by-nc/4.0/>.

#### ORCID iDs

Paul I Bhalla <http://orcid.org/0000-0003-0041-875X>

Cordelie E Witt <http://orcid.org/0000-0001-6643-4483>

#### REFERENCES

- Duch P, Møller MH. Epidural analgesia in patients with traumatic rib fractures: a systematic review of randomised controlled trials. *Acta Anaesthesiol Scand* 2015;59:698–709.
- Chapman BC, Herbert B, Rodil M, Salotto J, Stovall RT, Biffi W, Johnson J, Burlew CC, Barnett C, Fox C, *et al*. RibScore: a novel radiographic score based on fracture pattern that predicts pneumonia, respiratory failure, and tracheostomy. *J Trauma Acute Care Surg* 2016;80:95–101.
- Bulger EM, Edwards T, Klotz P, Jurkovich GJ. Epidural analgesia improves outcome after multiple rib fractures. *Surgery* 2004;136:426–30.
- Wu CL, Jani ND, Perkins FM, Barquist E. Thoracic epidural analgesia versus intravenous patient-controlled analgesia for the treatment of rib fracture pain after motor vehicle crash. *J Trauma* 1999;47:564–7.
- Gage A, Rivara F, Wang J, Jurkovich GJ, Arbabi S. The effect of epidural placement in patients after blunt thoracic trauma. *J Trauma Acute Care Surg* 2014;76:39–46.
- Galvagno SM, Smith CE, Varon AJ, Hasenboehler EA, Sultan S, Shaefer G, To KB, Fox AD, Alley DER, Dittillo M, *et al*. Pain management for blunt thoracic trauma: a joint practice management guideline from the eastern association for the surgery of trauma and trauma anesthesiology Society. *J Trauma Acute Care Surg* 2016;81:936–51.
- Bulger EM, Edwards WT, de Pinto M, Klotz P, Jurkovich GJ. Indications and contraindications for thoracic epidural analgesia in multiply injured patients. *Acute Pain* 2008;10:15–22.
- Blanco R, Parras T, McDonnell JG, Prats-Galino A, Galino AP. Serratus plane block: a novel ultrasound-guided thoracic wall nerve block. *Anaesthesia* 2013;68:1107–13.
- Madabushi R, Tewari S, Gautam SK, Agarwal A, Agarwal A. Serratus anterior plane block: a new analgesic technique for post-thoracotomy pain. *Pain Physician* 2015;18:E421–4.
- Jadon A. Serratus Anterior Plane Block for Pain Relief in Multiple Fractured Ribs (Mfrs): Injection of Local Anaesthetic above the Serratus or below the Serratus? - A Case Report. *J Anesth Crit Care* 2017;7:00254.
- Bossolasco M, Bernardi E, Fenoglio LM. Continuous serratus plane block in a patient with multiple rib fractures. *J Clin Anesth* 2017;38:85–6.
- Fu P, Weyker PD, Webb CAJ. Case report of serratus plane catheter for pain management in a patient with multiple rib fractures and an inferior scapular fracture. *AA Case Rep* 2017;8:132–5.
- Wong W. Serratus anterior plane block for rib fracture pain in the geriatric population. *Chest* 2019;155:108A.
- Witt CE, Bulger EM. Comprehensive approach to the management of the patient with multiple rib fractures: a review and introduction of a bundled rib fracture management protocol. *Trauma Surg Acute Care Open* 2017;2:e000064.
- Malekpour M, Hashmi A, Dove J, Torres D, Wild J. Analgesic choice in management of rib fractures: paravertebral block or epidural analgesia? *Anesth Analg* 2017;124:1906–11.
- Yeung JHY, Gates S, Naidu BV, Wilson MJA, Gao Smith F, Smith FG. Paravertebral block versus thoracic epidural for patients undergoing thoracotomy. *Cochrane Database Syst Rev* 2016;2:CD009121.
- Meade M, Guyatt G, Cook D, Griffith L, Sinuff T, Kergl C, Mancebo J, Esteban A, Epstein S. Predicting success in weaning from mechanical ventilation. *Chest* 2001;120:4005–24.
- Biswas A, Castanov V, Li Z, Perlas A, Krusselbrink R, Agur A, Chan V. Serratus plane block: a cadaveric study to evaluate optimal injectate spread. *Reg Anesth Pain Med* 2018;43:1.