

## A Glance at Methods for Cleft Palate Repair

Sima Tavakolinejad<sup>1</sup>; Alireza Ebrahimzadeh Bidskan<sup>1</sup>; Hami Ashraf<sup>2</sup>; Daryoush Hamidi Alamdari<sup>3,\*</sup>

<sup>1</sup>Department of Anatomy and Cell Biology, School of Medicine, Mashhad University of Medical Sciences, Mashhad, IR Iran

<sup>2</sup>Student Research Committee, Faculty of Medicine, Mashhad University of Medical Sciences, Mashhad, IR Iran

<sup>3</sup>Biochemistry and Nutrition Research Center, Faculty of Medicine, Mashhad University of Medical Sciences, Mashhad, IR Iran

\*Corresponding Author: Daryoush Hamidi Alamdari, Biochemistry and Nutrition Research Center, Faculty of Medicine, Mashhad University of Medical Sciences, Mashhad, IR Iran. Tel: +98-9151017650, E-mail: Hamidiad@mums.ac.ir

Received: October 20, 2013; Revised: January 13, 2014; Accepted: January 21, 2014

**Context:** Cleft palate is the second most common birth defect and is considered as a challenge for pediatric plastic surgeons. There is still a general lack of a standard protocol and patients often require multiple surgical interventions during their lifetime along with disappointing results.

**Evidence Acquisition:** PubMed search was undertaken using search terms including 'cleft palate repair', 'palatal cleft closure', 'cleft palate + stem cells', 'cleft palate + plasma rich platelet', 'cleft palate + scaffold', 'palatal tissue engineering', and 'bone tissue engineering'. The found articles were included if they defined a therapeutic strategy and/or assessed a new technique.

**Results:** We reported a summary of the key-points concerning cleft palate development, the genes involving this defect, current therapeutic strategies, recently novel aspects, and future advances in treatments for easy and fast understanding of the concepts, rather than a systematic review. In addition, the results were integrated with our recent experience.

**Conclusions:** Tissue engineering may open a new window in cleft palate reconstruction. Stem cells and growth factors play key roles in this field.

**Keywords:** Cleft Palate; Cleft Lip; Platelet-Derived Growth Factor; Transforming Growth Factor; Mesenchymal Stem Cells; Embryonic Stem Cells; Platelet-Rich Plasma

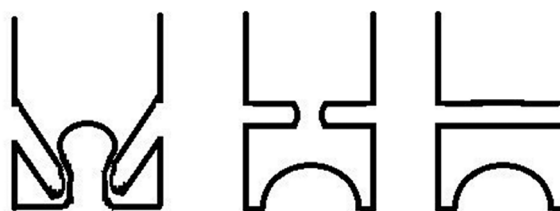
### 1. Context

#### 1.1. Cleft Palate Development Scenario

Palate is a structure that separates oral and nasal cavities from each other. Palatogenesis happens during weeks 8-12 in human intrauterine life (embryonic days E12-E15 in mice). The palate gets divided into primary and secondary palates. During palatogenesis, fusion of two maxillary outgrowths, named palatal shelves, forms the majority of palate. These shelves appear as protrusions on the lateral walls of the oronasal cavity, growing vertically and downward around the tongue. After a while, the palatal shelves elevate to a horizontal position and fuse on midline above the tongue to form the palate (Figure 1) (1).

Interruption in the palatogenesis process for any reason may lead to cleft palate (CP) which is characterized by a defect in oronasal separation. This malformation is a very frequent congenital defect in human and it may or may not be accompanied by cleft lip (CL) (2). Khazaei et al. reported 1.0 CP along with CL (CPL) per 1000 live births in Iran, which is lower compared to other countries (3). Both genetic and environmental factors could have roles in orofacial clefts, CP and/or CL incidence. Many genes

and signaling pathways are involved in palatogenesis, impaired action of each could lead to orofacial clefts; further information presented in Table 1. Genes can be categorized into four groups: 1) Genes expressed in a particular area or period of palate development; 2) Genes with biological activities without direct involvements, like receptors for retinoic acid and folic acid; 3) Homeobox genes which determine the identity of embryonic regions along the anterior-posterior axis; 4) Genes involved



**Figure 1.** Palatal Shelves Grow Vertically and Downward First, After a While They Turn Upward and Fuse in Midline, Above the Tongue, to Separate Oral and Nasal Cavities

**Table 1.** Some Genes Incorporating in Palatogenesis and Cleft Palate and/or Cleft Lip Formation <sup>a</sup>

Gene	Mechanism of CP and/or CL Formation	Reference
<b>Bmp signaling</b>	Disruption of type I Bmp receptor in the maxillary mesenchyme and throughout the oral epithelium resulted in CL and CP.	(8, 9)
<b>PDGF signaling</b>	PDGF and its receptors had specific roles in promoting tissue-tissue interactions to control cell migration and proliferation. Some deletions in this group resulted in CP.	(10)
<b>Wnt signaling</b>	Expression of multiple Wnts was essential for fusion of facial prominences. Onset of the cleft was linked to disruptions in various Wnt genes.	(11)
<b>TGFβ3</b>	TGFβ3 is expressed by epithelial cells of medial edge in palatal shelves just prior to fusion of them; it probably regulates the breakdown of epithelia which lie between the palatal shelves. If TGFβ3 did not expressed CP would be developed.	(12)
<b>FOXE1</b>	FOXE1 was expressed in the secondary palate epithelium. mice with a null mutation in FOXE1 had CP.	(13)
<b>VAX1</b>	Single nucleotide polymorphisms in VAX1 was overrepresented in patients with CL and CP, making variants in VAX1 strong candidates for etiopathogenesis of CL and CP. Mouse Vax1 knockouts showed CP.	(14)
<b>Noggin</b>	Loss of noggin function resulted in apoptosis in the palatal epithelium and reduced cell proliferation of the anterior palatal mesenchyme, resulting in CP in the anterior region.	(15)
<b>Genes encoding Adamts9 and Adamts20</b>	Simultaneous disruption of these genes resulted in CP with defects in early outgrowth, elevation and approximation of the palatal shelves.	(16)
<b>Msx1</b>	Lacking Msx1 exhibited specific cell proliferation defects in the anterior region, resulting in CP in those regions.	(17)
<b>Mn1</b>	Lacking Mn1 showed growth deficits in the middle and posterior regions of the palatal shelves, resulting in CP in these regions.	(18)
<b>Shox2</b>	Lacking Shox2 exhibited a cleft within the anterior palate.	(19)
<b>Tbx22</b>	Lacking Tbx22 displayed cleft palate, with the severity varying from a complete CP to submucous CP, as a result of difficulties in palatal shelves elevation.	(20)
<b>Osr1 and Osr2</b>	These genes encoded zinc-finger transcription factors; they targeted disruption of Osr2, causing cell proliferation reduction in the medial side of the developing palatal shelves and with disrupted mediolateral patterning.	(21)
<b>Fgfr2</b>	A targeted point mutation in Fgfr2 led to ligand-independent activation of the receptor, resulting in increased palatal shelf mesenchyme proliferation in the lateral half of the shelf and delayed elevation, leading to CP.	(22)

<sup>a</sup> Abbreviations: BMP, bone morphogenic protein; CP, cleft palate; CL, cleft lip; PDGF, platelet-derived growth factor; Wnt, wingless type; TGFβ3, transforming growth factor ; FOXE1, forkhead box protein E1; VAX1, Ventral anterior homeobox 1; MSX1, Msh homeobox 1; SHOX2, Short stature homeobox 2; TBX22, T-box transcription factor; OSR1, Odd-Skipped-Related 1; OSR2, Odd-Skipped-Related 2; FGFR2, Fibroblast growth factor receptor 2.

in deactivation and excretion of xenobiotics as those in P-450 cytochrome system (4). Environmental factors like folic acid deficiency (4), toxins in the living area (5), teratogens such as phenytoin (6), corticosteroids and retinoic acid (7), and also consanguinity (5) may affect the gene expression pattern and cause CP and/or CL. Further research is required toward understanding the exact molecular events.

## 2. Evidence Acquisition

PubMed search was undertaken using search terms including 'cleft palate repair', 'palatal cleft closure', 'cleft palate + stem cells', 'cleft palate + plasma-rich platelet', 'cleft palate + scaffold', 'palatal tissue engineering', and 'bone tissue engineering'. The found articles were included if they defined a therapeutic strategy and/or assessed a new technique. We tried to gather the newest articles about cleft palate repair.

### 2.1. Current Therapeutic Strategies

The ability to speak and feed normally is the essential goal of CP treatment. In addition, the treatment procedure should consider the normal facial appearance. Patients with CP, CL or both (CPL), often require long extensive treatments which may cause financial burden, morbidity and other medical complications (23). LeMonnier presented the first surgical CP repair. He incised the cleft edges and placed sutures leading to suppuration and then healing across the defect. Later, VonLangenbeck introduced the use of mucoperiosteal flaps to close clefts involving the hard palate (24). After that, a wide range of surgical techniques has been described to repair clefts, all with relative advantages and disadvantages, and all based on bone grafting (25). One of the major problems in cleft repair is bony reconstruction of alveolar and hard palate defects. Surgical repair by utilizing autogenous bone grafts is the current standard of care; Tibia, mandi-

ble, iliac, cranium and ribs are common donor sites (26). Bone grafts classified as primary, secondary, and tertiary, are based on the timing of the grafting procedure (26). This procedure has several disadvantages, mostly related to the donor site; morbidity after the bone graft harvest is the major problem. Complications are seen early and/or late in the donor site which include postoperative pain, wound infection, bleeding, altered sensation, local tissue injury, poor mobility, and possibly of fracture of the donor bone. Late complications include chronic pain, un-aesthetic scarring, gait disturbance, and paresthesia (26). Furthermore, bone graft harvest ultimately yields a very limited quantity of bone. This bone can also be absorbed; thus, full integration into the host site is not achieved (27). Reports show 41-73% success rate of primary alveolar cleft repair. Unfortunately, patients with persistent alveolar defects require secondary bone grafting (28). Meyer et al. reported only 82% successful secondary alveolar bone grafting rate after a long-term follow-up cohort study (29). Moreover, grafted bone needs to be very tenacious to support tooth eruption and to tolerate physical stress from muscles of mastication. To solve the problems of donor site morbidity, investigators have presented allogeneic and synthetic materials for grafting. However, there is still a risk of infection in addition to immune response elicitation and problems with structural integrity (27). Furthermore, the surgical repair of CPs has some unwanted consequences. Disturbance of facial growth is the common result (30). Midface retrusion makes other therapies necessary to establish a normal occlusion and improves facial appearance (31). In addition, postoperative development of an oronasal fistula in the grafted area still remains a significant problem of the palatal reconstruction surgery. Reports have mentioned an incidence ranging from 11% to 23%, with the most likely site being the junction of the hard and soft palates (32-35). Depending on size, fistulas may lead to hypernasal speech, nasal regurgitation, and food trapping. Patients with bilateral clefts appeared to have a 2- to 3-fold higher incidence of postoperative fistula development compared with unilateral clefts (36, 37). Another surgical approach for palatal cleft repair is using buccal fat pad applied for treatment of CP less than 20 mm in length, located in the posterior two-thirds of the palate (38). Buccal fat pad has been used in both primary palatal cleft repair and treatment of postoperative fistula (39-42). Use of buccal fat pad may result in a reduction of palatal scarring, which may limit the subsequent maxillary growth disturbance (27). Fujimura et al. evaluated the utility of combining the pedicled buccal fat covered with lyophilized dermis in adult patients with the successful treatment of oronasal fistula (43).

## 2.2. Using Scaffolds for Cleft Palate Repair

A scaffold provides a solid framework in a desirable site for cell growth, also allowing cell attachment and mi-

gration. Surgeons may use an empty scaffold to induce host cell migration, or they may employ it as a carrier for cells in cell therapy (44). Scaffolds for engineering bone should be biocompatible and should not stimulate the immune reaction. They should also be absorbable and the absorption rate must be almost same as bone formation rate. Moreover, a scaffold should be able to allow bone cells to migrate and proliferate. Finally, it must be physically stable and easy to manufacture and sterilize and should be handy to use. It should allow the cell-cell interaction and diffusion of nutrients and metabolites (45). Chemical and topographic surface properties of the scaffold can effect cell adhesion, proliferation and migration (46). Recently, it was shown that the presence of nano-structures in polymer-based composite scaffolds could be more effective for osteoblasts in comparison with micro-structures (47). Therefore, many materials have usually been used as bone tissue engineering scaffolds; collagen (48, 49), hyaluronic acid (50), and hydroxyapatite (51, 52) are some common examples. These materials may be used either alone or in combination with other different substances. Recently, mesoporous bioactive glass has been developed as a scaffold with excellent osteogenic properties for bone regeneration (53). Biodegradation and biocompatibility of novel poly (epsilon-caprolactone)/nano-fluoridated hydroxyapatite (PCL-FHA) scaffolds were investigated as well. The osteoblast-like cells were attached to and proliferated on PCL-FHA (54). In addition, acellularized dermal matrix (AlloDerm) has been applied for repair of palatal fistulas. AlloDerm can significantly reduce the fistula recurrence rates (55-57). Platelet rich fibrin (PRF) has been also examined as a scaffold for human osteoblast carrier. Metabolic activity and proliferation of human osteoblasts were supported to a significantly high extent using PRF membranes, in vitro (49). Scaffolds are provided in various forms including porous solid meshes, foams, and injectable gel networks. Injectable gels are desirable because they can be applied for irregular shaped defects; they can be utilized in a noninvasive procedure, and just by simple mixing they are combined with therapeutic agents or cells (58).

## 2.3. Applying Stem Cells to Engineered Palates

Tissue engineering is a novel technique which applies stem cells and/or differentiated cells, scaffolds and signaling molecules to achieve clinical therapeutic goals. Characteristics of an optimal cell source include availability in large quantities, no immune rejection, no graft versus host disease, no tumorigenicity, predictable differentiation potential of stem cells, and integration into the surrounding tissues (59). Embryonic stem cells (ESCs) are a source that may be used in tissue engineering. These cells exhibit long-term proliferation in vitro and the ability to differentiate into any cell type in the human body (44), but there is a concern about their tumorigenic properties (60). Mesenchymal stem cells (MSCs) are considered as a

suitable choice for bone tissue engineering (61). There are different sources for MSCs, including umbilical cord blood (UCB-MSCs), Wharton's jelly (UC-MSCs), bone marrow (BMMSCs) (61), and adipose tissue (ADSCs) (62, 63). Autologous BMMSCs possess a high proliferative potential and the ability to differentiate into osteoblastic cells and they can induce bone formation (64, 65). Furthermore, UC-MSCs are an available source of cells for bone tissue engineering and could have broad application prospects in tissue repair (61). Different kinds of stem cells have been applied for tissue regeneration in CP and alveolar cleft in different studies. Among them, there are experimental and clinical studies which suggested that tissue-engineered bone may provide an acceptable alternative for CP repair (66).

### 2.3.1. Experimental Studies

De Kok et al. evaluated MSC-based alveolar bone regeneration in a canine alveolar defect model using both autologous and allogeneic BMMSCs. Cells were loaded onto hydroxyapatite/tricalcium phosphate matrices. Allogeneic BMMSCs. Cells were loaded onto hydroxyapatite/tricalcium phosphate matrices. Histomorphometrical analysis showed new bone formed within the pores of the matrices loaded with autogenic BMMSCs or allogenic BMMSCs in equivalent amount. There was histological evidence showing no immunological response to neither autologous nor allogeneic BMMSCs. Analysis of circulating antibody levels against BMMSCs also supported the hypothesis that MSCs did not induce a systemic response by the host. After nine weeks, the labeled cells were present within the lacunae of newly formed bone, proposing that autologous and allogeneic BMMSCs have the capacity to regenerate bone within craniofacial defects (67). Conejero et al. used osteogenically differentiated rat fat-derived stem cells, seeded onto poly-L-lactic acid scaffold, to repair rat palatal bone defect models. They demonstrated the feasibility of using these cells for healing such defects, and also proved bone formation in the treated area (63). Kim et al. recruited periodontal ligament stem cells (PDLSCs) and bone marrow stem cells (BMSCs) to regenerate alveolar bone in the dog canine peri-implant defect model. They found these cells effective and BMSCs were more impressive than PDLSCs in bone formation (68). Ou et al. investigated restoration of the alveolar cleft with engineered bone, constructed by sponge collagen protein combined with autologous BMMSCs, in the dog alveolar cleft model. Twelve weeks after implantation, 3-dimensional CT and histological examination showed acceptable bone formation in the experimental model compared to the control. It was concluded that these materials can restore the defect of alveolar bone effectively and they can be used clinically to treat alveolar cleft (69). Mylonas et al. compared the efficiency of bioglass and synthetic hydroxyapatite/tricalcium phosphate granular scaffolds loaded by allogeneic BMMSCs for alveolar bone

repairmen in a dog model. No difference was shown in the newly formed bone percent area using these scaffolds, although both exhibited desirable results (70). Recently, Pourebrahim et al. did a survey to compare bone regeneration of tissue engineered bone from canine ADSCs and autogenous bone graft in the bilateral maxillary alveolar cleft model in dog. For osteogenic differentiation of the undifferentiated cells, they were seeded into a hydroxyapatite/beta-tricalcium phosphate scaffold, overwhelmed in specific osteogenic medium for 21 days. This material was applied on one side and corticocancellous tibial autograft was added on the other side. Bone regeneration was evaluated by histomorphometry on days 15 and 60 after implantation. There was a significant difference between the tissue-engineered side and autografted side, with bone autograft superiority (66).

### 2.3.2. Clinical Studies

Behnia et al. evaluated the effect of recombinant platelet derived growth factor and in vitro osteogenic differentiated human bone marrow mesenchymal stem cells (hBMMSCs) in the secondary alveoloplasty. They reported significant improvement in bone regeneration three months after the operation, suggesting an enhancement effect of recombinant platelet derived growth factor with hMSCs on regeneration capacity of the cells (71). Gimbel et al. compared donor site pain in both tissue engineering minimally invasive iliac crest bone graft and traditional iliac crest bone graft techniques for alveolar bone defect repair, to determine if a tissue engineering technique with similar bone healing results offered any decreased morbidity. Their results exhibited closure of alveolar cleft defects with an absorbable collagen sponge and bone marrow stem cells eventuated in reduced donor site morbidity and decreased the donor site pain intensity and frequency (72). However, bone marrow aspiration is an undeniable part of BMSCs extraction; so, BMSCs application fails to totally obviate the donor site morbidity (73).

### 2.4. Synthetic Adjuvant in Engineered Palates

The BMP signaling molecules family has been used to induce osteoblastic differentiation. The recombination technology now allows production of large, pure quantities of rhBMP-2 which can be used widely in clinics and laboratories. In a proper environment, rhBMP-2 can cause bone formation by inducing stem cells to differentiate into bone forming cells (74). Mayer et al. evaluated rhBMP-2 in maxillary alveolar clefts in 24 adults, skeletally mature Foxhound dogs. Bilateral clefts were created artificially, 1 cm in bony width. There were three treatment groups: (1) rhBMP-2 combined with the copolymer poly(lactide-co-glycolide) and autogenous blood, (2) poly(lactide-co-glycolide) and autogenous blood, (3) autograft from the posterior iliac crest; and an untreated group as control. Radiographical and histological assessments were performed two and four months after

the treatment. The results showed more bone regeneration in the autograft group at two months, but after four months there were no significant differences between this group and the rhBMP-2 group (75). After that, Chin et al. demonstrated clinically the feasibility of using rhBMP-2 to repair alveolar clefts without the use of autogenous graft tissue. Their results were shown constructed alveolus bone, performed as normal bone clinically. In addition, histological assessment proved that it was a normal and vital bone (76). Herford et al. examined bony regeneration of premaxillary clefts by using rhBMP-2 within a collagen sponge carrier in clinic. Computed tomographic studies, before and four months after the operation, revealed that such defects can have complete osseous regeneration induced by rhBMP-2 (77). Nguyen et al. also compared the therapeutic benefits of absorbable collagen sponge, absorbable collagen sponge plus rhBMP-2, hydroxyapatite-tricalcium phosphate scaffold, hydroxyapatite-tricalcium phosphate scaffold plus rhBMP-2, and control group on surgically created defects in rats. Radiomorphometrical and histomorphometrical assessments at four, eight, and 12 weeks showed an increase in bone formation in animals treated with hydroxyapatite-tricalcium phosphate plus rhBMP-2 ( $P < 0.05$ ; four weeks) compared with the empty scaffold (28). Alonso et al. did a survey to compare the effect of a combination of a resorbable collagen matrix along with rhBMP-2 with traditional iliac crest bone graft for closure of alveolar defects. The authors concluded that rhBMP-2 therapy had satisfactory bone healing effects and it could reduce tissue morbidity (78). Furthermore, a novel technique which encased rhBMP-2 in a demineralized bone matrix scaffold (BMP/DBM) was developed as an alternative to autografting for secondary alveolar cleft reconstruction. Excellent results were achieved clinically (79). Recently, Woo et al. reported adverse events after the use of rhBMP-2 as an alternative to autogenous bone graft in oral and maxillofacial surgical procedures. They found that 66.3% of patients with reconstruction of mandible after fracture or cancer or alveolar cleft repair by means of rhBMP-2 reported local reactions, graft failure, infections and other wound complications and 30.1% required additional surgery to address the reported adverse events (80). Such reports make it necessary to use natural materials instead of synthetic ones.

### 2.5. Platelet-Rich Plasma Usage as a Natural Adjuvant in Engineered Palates

In regenerative medicine, tissue repair is strongly dependent on formation of new blood vessels and capillaries. Platelet-rich plasma (PRP) is a blood product with a high platelet concentration and the rationale beyond using platelets in tissue engineering is the release of bioactive factors which collaborate in tissue regeneration. Platelets contain a number of growth factors such as platelet-derived, vascular endothelial, beta-type transforming,

epidermal, fibroblast and insulin-like I, which promote angiogenesis and synthesis of the extracellular matrix (81-83). As one of the main components in tissue regeneration, we successfully applied PRP to treat nonhealing wounds (82), vesicovaginal fistulas (83), and stress urinary incontinence (81). In one CP case, we injected autologous PRP which is described in details in the following section. There are a few reports about using PRP into grafts for alveolar clefts treatment as a source of growth factors for osteogenic differentiation. Osteoregeneration efficacy of autologous bone grafting in PRP has been clinically tested by Oyama et al. They reported higher volume ratio of bone regeneration in PRP-applied cases than control cases who did not receive PRP in their treatments. It was suggested that PRP could enhance bone regeneration and may be beneficial in CP and CL patients' treatment procedures (84). Ouyang et al. evaluated the effect of PRP as an adjunct to bovine porous bone mineral (BPBM) graft in treatment of periodontal intra bony defects clinically. Their results showed a significant favorable clinical improvement in treating such defects by PRP and BPBM application simultaneously (85). Hibi et al. applied autologous MSCs combined with PRP for an alveolar cleft osteoplasty of a nine-year-old female patient. Results showed promising bone regeneration and bridging of the cleft after six months (86). Lee et al. designed a longitudinal survey to evaluate the outcomes of secondary autogenous bone graft combined with PRP in the alveolar cleft. The study considered two groups including 35 alveolar clefts in 30 patients with grafted autogenous bone and PRP and 36 clefts in 30 patients with grafted autogenous bone alone. The density and resorption of the grafted bone was assessed at one week, and one, three, six, and 12 months postoperatively. The authors suggested that PRP may improve bone remodeling in the early phase; however, PRP seemed to have no effect on bone resorption following secondary bone graft in long term (87). Rullo et al. reported a case of alveolar cleft bone grafting along with PRP application. They observed satisfactory results both on bone and soft tissue regeneration (88). In a clinical study, Luaces-Rey et al. compared alveolar reconstruction in secondary alveoloplasty with or without PRP. They evaluated the treatment results in two groups of patients. In one group, secondary alveoloplasty was performed using autogenous bone graft and in the second group PRP was added to the autogenous bone grafting procedure. Digital orthopantomography was performed immediately after the operation and again three and six months later. In contrast to the previous study, the data showed no significant differences between the two groups regarding bone regeneration amount (89). However, Marukawa et al. obtained more favorable results in a similar study. There was a significant reduction in postoperative bone resorption, particularly in the PRP group (90).

## 3. Results

In this mini-review, we reported a summary of the key

points concerning cleft palate development, genes involving this defect, current therapeutic strategies, recently novel aspects, and future advances in treatments for easy and fast understanding of the concepts, rather than a systematic review. In addition, the results have been integrated with our recent experience.

## 4. Conclusions

According to the literature review as well as our unpublished experiences, we proposed a novel technique for CP management. On the basis of our hypothesis, a CP treatment could be improved by PRP injection around the defected margins. The injection may be repeated after a while in larger defects. Since we provided a mini-review study, we did not explain all the aspects in details which was the limitation of our study. The strong point of our study was brief and understandable explanations in each part which helped reader find out the whole subject in a short time.

### 4.1. Case Report

In a one-year-old female case, a fistula was developed after bone autografting for CP treatment. The procedure needed to be repeated after 6-12 months. Meanwhile, for increasing the success rate, we suggested to inject hPRP (human Plasma-Rich Platelet) along fistula borders before surgery. Three injections were done at two-month intervals. After the third injection, a reduction was observed in the fistula size. In addition, free margins turned thick and well vascularized; tissue grafting was performed successfully. Unfortunately, another fistula appeared on another site of palate after a while. The patient was a candidate for tissue grafting from tongue or buccal area, an invasive procedure, six months later. We decided to continue less invasive PRP application. Again, three injections were done. Surprisingly, sufficient tissue was generated two months after the third injection and the fistula was closed with no more graft needed. The present experience drove us to the hypothesis that PRP can not only reduce the size of defect, but it can also increase angiogenesis as an important factor for tissue grafting (unfortunately there was no publishable picture available). Furthermore, the surgical interference is still the gold standard treatment procedure for CP, so we strongly recommend our technique for small defects; in wider defects we recommend it before surgery to enhance angiogenesis and reduce graft failure rate.

## Acknowledgements

This article was the outcome of the thesis of Sima Tavakolinejad, Ph.D. student in anatomy (proposal code: 900679).

## Authors' Contributions

Study concept and design: Sima Tavakolinejad, Dary-

oush Hamidi Alamdari and Alireza Ebrahimzadeh Bidskan. Analysis and interpretation of data: Hami Ashraf and Sima Tavakolinejad. Drafting of the manuscript: Sima Tavakolinejad. Critical revision of the manuscript for important intellectual content: Daryoush Hamidi Alamdari, Hami Ashraf and Alireza Ebrahimzadeh Bidskan.

## Funding/Support

This study was supported in part by the Vice Chancellor of research, Mashhad University of Medical Sciences, grant No. 900679.

## References

1. Bush JO, Jiang R. Palatogenesis: morphogenetic and molecular mechanisms of secondary palate development. *Development*. 2012;**139**(2):231-43.
2. Farina A, Wyszynski DF, Pezzetti F, Scapoli L, Martinelli M, Carinci F, et al. Classification of oral clefts by affection site and laterality: a genotype-phenotype correlation study. *Orthod Craniofac Res*. 2002;**5**(3):185-91.
3. Khazaei S, Shirani AM, Khazaei M, Najafi F. Incidence of cleft lip and palate in Iran. A meta-analysis. *Saudi Med J*. 2011;**32**(4):390-3.
4. Bianchi F, Calzolari E, Ciulli L, Cordier S, Gualandi F, Pierini A, et al. [Environment and genetics in the etiology of cleft lip and cleft palate with reference to the role of folic acid]. *Epidemiol Prev*. 2000;**24**(1):21-7.
5. Mirfazeli A, Kaviyani N, Hosseinpour KR, Gosalipour MJ. Incidence of cleft lip and palate in gorgan - northern iran: an epidemiological study. *Oman Med J*. 2012;**27**(6):461-4.
6. Diehl SR, Erickson RP. Genome scan for teratogen-induced clefting susceptibility loci in the mouse: evidence of both allelic and locus heterogeneity distinguishing cleft lip and cleft palate. *Proc Natl Acad Sci U S A*. 1997;**94**(10):5231-6.
7. Lau EC, Li ZQ. Protection of mice from teratogen-induced cleft palate by exogenous methionine. *Proc Soc Exp Biol Med*. 1995;**209**(2):141-5.
8. Liu W, Sun X, Braut A, Mishina Y, Behringer RR, Mina M, et al. Distinct functions for Bmp signaling in lip and palate fusion in mice. *Development*. 2005;**132**(6):1453-61.
9. Li L, Lin M, Wang Y, Cserjesi P, Chen Z, Chen Y. Bmpr1a is required in mesenchymal tissue and has limited redundant function with Bmpr1b in tooth and palate development. *Dev Biol*. 2011;**349**(2):451-61.
10. Ding H, Wu X, Bostrom H, Kim I, Wong N, Tsoi B, et al. A specific requirement for PDGF-C in palate formation and PDGFR-alpha signaling. *Nat Genet*. 2004;**36**(10):1111-6.
11. Juriloff DM, Harris MJ, McMahon AP, Carroll TJ, Lidral AC. Wnt9b is the mutated gene involved in multifactorial nonsyndromic cleft lip with or without cleft palate in A/WySn mice, as confirmed by a genetic complementation test. *Birth Defects Res A Clin Mol Teratol*. 2006;**76**(8):574-9.
12. Pelton RW, Saxena B, Jones M, Moses HL, Gold LI. Immunohistochemical localization of TGF beta 1, TGF beta 2, and TGF beta 3 in the mouse embryo: expression patterns suggest multiple roles during embryonic development. *J Cell Biol*. 1991;**115**(4):1091-105.
13. Moreno LM, Mansilla MA, Bullard SA, Cooper ME, Busch TD, Machida J, et al. FOXE1 association with both isolated cleft lip with or without cleft palate, and isolated cleft palate. *Hum Mol Genet*. 2009;**18**(24):4879-96.
14. Hallonet M, Hollemann T, Pieler T, Gruss P. Vax1, a novel homeobox-containing gene, directs development of the basal forebrain and visual system. *Genes Dev*. 1999;**13**(23):3106-14.
15. He F, Xiong W, Wang Y, Matsui M, Yu X, Chai Y, et al. Modulation of BMP signaling by Noggin is required for the maintenance of palatal epithelial integrity during palatogenesis. *Dev Biol*. 2010;**347**(1):109-21.
16. Enomoto H, Nelson CM, Somerville RP, Mielke K, Dixon LJ, Powell K, et al. Cooperation of two ADAMTS metalloproteases in closure

- of the mouse palate identifies a requirement for versican proteolysis in regulating palatal mesenchyme proliferation. *Development*. 2010;**137**(23):4029-38.
17. Zhang Z, Song Y, Zhao X, Zhang X, Fermin C, Chen Y. Rescue of cleft palate in *Mx1*-deficient mice by transgenic *Bmp4* reveals a network of BMP and Shh signaling in the regulation of mammalian palatogenesis. *Development*. 2002;**129**(17):4135-46.
  18. Liu W, Lan Y, Pauws E, Meester-Smoor MA, Stanier P, Zwarthoff EC, et al. The *Mn1* transcription factor acts upstream of *Tbx22* and preferentially regulates posterior palate growth in mice. *Development*. 2008;**135**(23):3959-68.
  19. Yu L, Gu S, Alappatt S, Song Y, Yan M, Zhang X, et al. *Shox2*-deficient mice exhibit a rare type of incomplete clefting of the secondary palate. *Development*. 2005;**132**(19):4397-406.
  20. Pauws E, Moore GE, Stanier P. A functional haplotype variant in the *TBX22* promoter is associated with cleft palate and ankyloglossia. *J Med Genet*. 2009;**46**(8):555-61.
  21. Gao Y, Lan Y, Ovitt CE, Jiang R. Functional equivalence of the zinc finger transcription factors *Osr1* and *Osr2* in mouse development. *Dev Biol*. 2009;**328**(2):200-9.
  22. Snyder-Warwick AK, Perlyn CA, Pan J, Yu K, Zhang L, Ornitz DM. Analysis of a gain-of-function *FGFR2* Crouzon mutation provides evidence of loss of function activity in the etiology of cleft palate. *Proc Natl Acad Sci U S A*. 2010;**107**(6):2515-20.
  23. Marazita ML, Murray JC, Lidral AC, Arcos-Burgos M, Cooper ME, Goldstein T, et al. Meta-analysis of 13 genome scans reveals multiple cleft lip/palate genes with novel loci on 9q21 and 2q32-35. *Am J Hum Genet*. 2004;**75**(2):161-73.
  24. Levi B, Brugman S, Wong VW, Grova M, Longaker MT, Wan DC. Palatogenesis: engineering, pathways and pathologies. *Organogenesis*. 2011;**7**(4):242-54.
  25. Moreau JL, Caccamese JF, Coletti DP, Sauk JJ, Fisher JP. Tissue engineering solutions for cleft palates. *J Oral Maxillofac Surg*. 2007;**65**(12):2503-11.
  26. Batra P, Sharma J, Duggal R, Parkash H. Secondary bone grafting in cleft lip and palate with eruption of tooth into the graft: a case report. *J Indian Soc Pedod Prev Dent*. 2004;**22**(1):8-12.
  27. Panetta NJ, Gupta DM, Slater BJ, Kwan MD, Liu KJ, Longaker MT. Tissue engineering in cleft palate and other congenital malformations. *Pediatr Res*. 2008;**63**(5):545-51.
  28. Nguyen PD, Lin CD, Allori AC, Schachar JS, Ricci JL, Saadeh PB, et al. Scaffold-based rhBMP-2 therapy in a rat alveolar defect model: implications for human gingivoperiosteoplasty. *Plast Reconstr Surg*. 2009;**124**(6):1829-39.
  29. Meyer S, Molsted K. Long-term outcome of secondary alveolar bone grafting in cleft lip and palate patients: a 10-year follow-up cohort study. *J Plast Surg Hand Surg*. 2013;**47**(6):503-8.
  30. De La Pedraja J, Erbella J, McDonald WS, Thaller S. Approaches to cleft lip and palate repair. *J Craniofac Surg*. 2000;**11**(6):562-71.
  31. Waite PD, Waite DE. Bone grafting for the alveolar cleft defect. *Semin Orthod*. 1996;**2**(3):192-6.
  32. Amaratunga NA. Occurrence of oronasal fistulas in operated cleft palate patients. *J Oral Maxillofac Surg*. 1988;**46**(10):834-8.
  33. Cohen SR, Kalinowski J, LaRossa D, Randall P. Cleft palate fistulas: a multivariate statistical analysis of prevalence, etiology, and surgical management. *Plast Reconstr Surg*. 1991;**87**(6):1041-7.
  34. Emory RE, Jr, Clay RP, Bite U, Jackson IT. Fistula formation and repair after palatal closure: an institutional perspective. *Plast Reconstr Surg*. 1997;**99**(6):1535-8.
  35. Landheer JA, Breugem CC, van der Molen AB. Fistula incidence and predictors of fistula occurrence after cleft palate repair: two-stage closure versus one-stage closure. *Cleft Palate Craniofac J*. 2010;**47**(6):623-30.
  36. Lu Y, Shi B, Zheng Q, Hu Q, Wang Z. Incidence of palatal fistula after palatoplasty with levator veli palatini repositioning according to Sommerlad. *Br J Oral Maxillofac Surg*. 2010;**48**(8):637-40.
  37. Mak SY, Wong WH, Or CK, Poon AM. Incidence and cluster occurrence of palatal fistula after furrow palatoplasty by a single surgeon. *Ann Plast Surg*. 2006;**57**(1):55-9.
  38. Ashtiani AK, Fatemi MJ, Pooli AH, Habibi M. Closure of palatal fistula with buccal fat pad flap. *Int J Oral Maxillofac Surg*. 2011;**40**(3):250-4.
  39. Hai HK. Repair of palatal defects with unlined buccal fat pad grafts. *Oral Surg Oral Med Oral Pathol*. 1988;**65**(5):523-5.
  40. Hudson JW, Anderson JG, Russell RM, Jr, Anderson N, Chambers K. Use of pedicled fat pad graft as an adjunct in the reconstruction of palatal cleft defects. *Oral Surg Oral Med Oral Pathol Oral Radiol Endod*. 1995;**80**(1):24-7.
  41. Robiony M. The use of silicone sheet to improve buccal fat pad healing in palatal reconstruction. *J Plast Reconstr Aesthet Surg*. 2010;**63**(10):e729-32.
  42. Levi B, Kasten SJ, Buchman SR. Utilization of the buccal fat pad flap for congenital cleft palate repair. *Plast Reconstr Surg*. 2009;**123**(3):1018-21.
  43. Fujimura N, Nagura H, Enomoto S. Grafting of the buccal fat pad into palatal defects. *J Craniomaxillofac Surg*. 1990;**18**(5):219-22.
  44. Sharma B, Elisseff JH. Engineering structurally organized cartilage and bone tissues. *Ann Biomed Eng*. 2004;**32**(1):148-59.
  45. Liu X, Ma PX. Polymeric scaffolds for bone tissue engineering. *Ann Biomed Eng*. 2004;**32**(3):477-86.
  46. Salgado AJ, Coutinho OP, Reis RL. Bone tissue engineering: state of the art and future trends. *Macromol Biosci*. 2004;**4**(8):743-65.
  47. Saranya N, Saravanan S, Moorthi A, Ramyakraishna B, Selvarugan N. Enhanced osteoblast adhesion on polymeric nano-scaffolds for bone tissue engineering. *J Biomed Nanotechnol*. 2011;**7**(2):238-44.
  48. Krishnamoorthy G, Sehgal PK, Mandal AB, Sadulla S. Novel collagen scaffolds prepared by using unnatural D-amino acids assisted EDC/NHS crosslinking. *J Biomater Sci Polym Ed*. 2013;**24**(3):344-64.
  49. Gassling V, Hedderich J, Acil Y, Purcz N, Wiltfang J, Douglas T. Comparison of platelet rich fibrin and collagen as osteoblast-seeded scaffolds for bone tissue engineering applications. *Clin Oral Implants Res*. 2013;**24**(3):320-8.
  50. Kang SW, Kim JS, Park KS, Cha BH, Shim JH, Kim JY, et al. Surface modification with fibrin/hyaluronic acid hydrogel on solid-free form-based scaffolds followed by BMP-2 loading to enhance bone regeneration. *Bone*. 2011;**48**(2):298-306.
  51. Guda T, Walker JA, Pollot BE, Appleford MR, Oh S, Ong JL, et al. In vivo performance of bilayer hydroxyapatite scaffolds for bone tissue regeneration in the rabbit radius. *J Mater Sci Mater Med*. 2011;**22**(3):647-56.
  52. Sellgren KL, Ma T. Perfusion conditioning of hydroxyapatite-chitosan-gelatin scaffolds for bone tissue regeneration from human mesenchymal stem cells. *J Tissue Eng Regen Med*. 2012;**6**(1):49-59.
  53. Wu C, Zhou Y, Fan W, Han P, Chang J, Yuen J, et al. Hypoxia-mimicking mesoporous bioactive glass scaffolds with controllable cobalt ion release for bone tissue engineering. *Biomaterials*. 2012;**33**(7):2076-85.
  54. Johari N, Fathi MH, Golozar MA, Erfani E, Samadikuchaksaraei A. Poly(epsilon-caprolactone)/nano fluoridated hydroxyapatite scaffolds for bone tissue engineering: in vitro degradation and biocompatibility study. *J Mater Sci Mater Med*. 2012;**23**(3):763-70.
  55. Steele MH, Seagle MB. Palatal fistula repair using acellular dermal matrix: the University of Florida experience. *Ann Plast Surg*. 2006;**56**(1):50-3.
  56. Clark JM, Saffold SH, Israel JM. Decellularized dermal grafting in cleft palate repair. *Arch Facial Plast Surg*. 2003;**5**(1):40-4.
  57. Cole P, Horn TW, Thaller S. The use of decellularized dermal grafting (AlloDerm) in persistent oro-nasal fistulas after tertiary cleft palate repair. *J Craniofac Surg*. 2006;**17**(4):636-41.
  58. Gutowska A, Jeong B, Jasionowski M. Injectable gels for tissue engineering. *Anat Rec*. 2001;**263**(4):342-9.
  59. Logeart-Avramoglou D, Anagnostou F, Bizios R, Petite H. Engineering bone: challenges and obstacles. *J Cell Mol Med*. 2005;**9**(1):72-84.
  60. Kuroda T, Yasuda S, Sato Y. Tumorigenicity studies for human pluripotent stem cell-derived products. *Biol Pharm Bull*. 2013;**36**(2):189-92.
  61. Diao Y, Ma Q, Cui F, Zhong Y. Human umbilical cord mesenchymal stem cells: osteogenesis in vivo as seed cells for bone tissue engineering. *J Biomed Mater Res A*. 2009;**91**(1):123-31.
  62. Tobita M, Uysal AC, Ogawa R, Hyakusoku H, Mizuno H. Periodon-

- tal tissue regeneration with adipose-derived stem cells. *Tissue Eng Part A*. 2008;**14**(6):945-53.
63. Conejero JA, Lee JA, Parrett BM, Terry M, Wear-Maggitti K, Grant RT, et al. Repair of palatal bone defects using osteogenically differentiated fat-derived stem cells. *Plast Reconstr Surg*. 2006;**117**(3):857-63.
  64. Haynesworth SE, Goshima J, Goldberg VM, Caplan AI. Characterization of cells with osteogenic potential from human marrow. *Bone*. 1992;**13**(1):81-8.
  65. Goshima J, Goldberg VM, Caplan AI. The osteogenic potential of culture-expanded rat marrow mesenchymal cells assayed in vivo in calcium phosphate ceramic blocks. *Clin Orthop Relat Res*. 1991;**262**:298-311.
  66. Pourebrahim N, Hashemibeni B, Shahnasari S, Torabinia N, Mousavi B, Adibi S, et al. A comparison of tissue-engineered bone from adipose-derived stem cell with autogenous bone repair in maxillary alveolar cleft model in dogs. *Int J Oral Maxillofac Surg*. 2013;**42**(5):562-8.
  67. De Kok IJ, Peter SJ, Archambault M, van den Bos C, Kadiyala S, Aukhil I, et al. Investigation of allogeneic mesenchymal stem cell-based alveolar bone formation: preliminary findings. *Clin Oral Implants Res*. 2003;**14**(4):481-9.
  68. Kim SH, Kim KH, Seo BM, Koo KT, Kim TI, Seol YJ, et al. Alveolar bone regeneration by transplantation of periodontal ligament stem cells and bone marrow stem cells in a canine peri-implant defect model: a pilot study. *J Periodontol*. 2009;**80**(11):1815-23.
  69. Ou XR, Jian XC, Lin G. [An investigation of restoration of alveolar cleft with engineered bone]. *Zhonghua Zheng Xing Wai Ke Za Zhi*. 2007;**23**(1):29-31.
  70. Mylonas D, Vidal MD, De Kok IJ, Moriarity JD, Cooper LF. Investigation of a thermoplastic polymeric carrier for bone tissue engineering using allogeneic mesenchymal stem cells in granular scaffolds. *J Prosthodont*. 2007;**16**(6):421-30.
  71. Behnia H, Khojasteh A, Soleimani M, Tehranchi A, Atashi A. Repair of alveolar cleft defect with mesenchymal stem cells and platelet derived growth factors: a preliminary report. *J Craniomaxillofac Surg*. 2012;**40**(1):2-7.
  72. Gimbel M, Ashley RK, Sisodia M, Gabbay JS, Wasson KL, Heller J, et al. Repair of alveolar cleft defects: reduced morbidity with bone marrow stem cells in a resorbable matrix. *J Craniofac Surg*. 2007;**18**(4):895-901.
  73. Bueno DF, Kerkis I, Costa AM, Martins MT, Kobayashi GS, Zucconi E, et al. New source of muscle-derived stem cells with potential for alveolar bone reconstruction in cleft lip and/or palate patients. *Tissue Eng Part A*. 2009;**15**(2):427-35.
  74. Wozney JM, Rosen V, Celeste AJ, Mitsock LM, Whitters MJ, Kriz RW, et al. Novel regulators of bone formation: molecular clones and activities. *Science*. 1988;**242**(4885):1528-34.
  75. Mayer M, Hollinger J, Ron E, Wozney J. Maxillary alveolar cleft repair in dogs using recombinant human bone morphogenetic protein-2 and a polymer carrier. *Plast Reconstr Surg*. 1996;**98**(2):247-59.
  76. Chin M, Ng T, Tom WK, Carstens M. Repair of alveolar clefts with recombinant human bone morphogenetic protein (rhBMP-2) in patients with clefts. *J Craniofac Surg*. 2005;**16**(5):778-89.
  77. Herford AS, Boyne PJ, Rawson R, Williams RP. Bone morphogenetic protein-induced repair of the premaxillary cleft. *J Oral Maxillofac Surg*. 2007;**65**(11):2136-41.
  78. Alonso N, Tanikawa DY, Freitas Rda S, Canan L, Jr, Ozawa TO, Rocha DL. Evaluation of maxillary alveolar reconstruction using a resorbable collagen sponge with recombinant human bone morphogenetic protein-2 in cleft lip and palate patients. *Tissue Eng Part C Methods*. 2010;**16**(5):1183-9.
  79. Francis CS, Mobin SS, Lypka MA, Rommer E, Yen S, Urata MM, et al. rhBMP-2 with a demineralized bone matrix scaffold versus autologous iliac crest bone graft for alveolar cleft reconstruction. *Plast Reconstr Surg*. 2013;**131**(5):1107-15.
  80. Woo EJ. Adverse events reported after the use of recombinant human bone morphogenetic protein 2. *J Oral Maxillofac Surg*. 2012;**70**(4):765-7.
  81. Shirvan MK, Alamdari DH, Mahboub MD, Ghanadi A, Rahimi HR, Seifalian AM. A novel cell therapy for stress urinary incontinence, short-term outcome. *Neurourol Urodyn*. 2013;**32**(4):377-82.
  82. Ravari H, Hamidi-Almadari D, Salimifar M, Bonakdaran S, Parizadeh MR, Koliakos G. Treatment of non-healing wounds with autologous bone marrow cells, platelets, fibrin glue and collagen matrix. *Cytotherapy*. 2011;**13**(6):705-11.
  83. Shirvan MK, Alamdari DH, Ghoreifi A. A novel method for iatrogenic vesicovaginal fistula treatment: autologous platelet rich plasma injection and platelet rich fibrin glue interposition. *J Urol*. 2013;**189**(6):2125-9.
  84. Oyama T, Nishimoto S, Tsugawa T, Shimizu F. Efficacy of platelet-rich plasma in alveolar bone grafting. *J Oral Maxillofac Surg*. 2004;**62**(5):555-8.
  85. Ouyang XY, Qiao J. Effect of platelet-rich plasma in the treatment of periodontal intrabony defects in humans. *Chin Med J (Engl)*. 2006;**119**(18):1511-21.
  86. Hibi H, Yamada Y, Ueda M, Endo Y. Alveolar cleft osteoplasty using tissue-engineered osteogenic material. *Int J Oral Maxillofac Surg*. 2006;**35**(6):551-5.
  87. Lee C, Nishihara K, Okawachi T, Iwashita Y, Majima HJ, Nakamura N. A quantitative radiological assessment of outcomes of autogenous bone graft combined with platelet-rich plasma in the alveolar cleft. *Int J Oral Maxillofac Surg*. 2009;**38**(2):117-25.
  88. Rullo R, Festa VM, Guida L, Laino G. Bone grafting with platelet-rich plasma in alveolar cleft. Case report. *Minerva Stomatol*. 2007;**56**(1-2):63-71.
  89. Luaces-Rey R, Arenaz-Bua J, Lopez-Cedrun-Cembranos JL, Herrero-Patino S, Sironvalle-Soliva S, Iglesias-Candal E, et al. Is PRP useful in alveolar cleft reconstruction? Platelet-rich plasma in secondary alveoloplasty. *Med Oral Patol Oral Cir Bucal*. 2010;**15**(4):e619-23.
  90. Marukawa E, Oshina H, Iino G, Morita K, Omura K. Reduction of bone resorption by the application of platelet-rich plasma (PRP) in bone grafting of the alveolar cleft. *J Craniomaxillofac Surg*. 2011;**39**(4):278-83.