



Ocular complications of SAVI: A unique case of bilateral uveitis and retinal vasculitis

Matteo Menean^{a,b}, Alessandro Marchese^{a,b}, Giulio Modorati^{a,b}, Rosa Favale^c,
Francesco Boscia^c, Francesco Bandello^{a,b}, Elisabetta Miserocchi^{a,b,*}

^a Division of Head and Neck, Ophthalmology Unit, IRCCS San Raffaele Scientific Institute, Milan, Italy

^b School of Medicine, Vita-Salute San Raffaele University, Milan, Italy

^c Department of Ophthalmology and Translational Biomedicine and Neurosciences (DiBrain), University of Bari, Bari, Italy

ARTICLE INFO

Keywords:

SAVI
Uveitis
Interferonopathy
Vasculitis
STING

ABSTRACT

Purpose: To describe a case of bilateral panuveitis in a patient with Stimulator of Interferon Genes (STING)-Associated Vasculitis with Onset in Infancy (SAVI).

Observations: A 45-year-old patient diagnosed with SAVI presented bilateral panuveitis and uncontrolled secondary intraocular hypertension due to structural complications from uveitis. Multimodal imaging revealed the presence of intraretinal fluid and bilateral vasculitis. The patient was started with systemic methotrexate.

Conclusions and importance: This case is essential to characterize ocular involvement in patients with SAVI. Awareness of these ocular manifestations is crucial for timely management and improvement of visual prognosis.

1. Introduction

Stimulator of interferon Genes (STING)-Associated Vasculitis with Onset in Infancy (SAVI) is an autoinflammatory disorder characterized by systemic involvement and poor long-term prognosis.^{1,2} SAVI is caused by a heterozygous gain-of-function mutation in STING1 gene, which encodes for a stimulator of the interferon (IFN) genes protein involved in the inflammatory cascade. The mutated STING1 protein results in a constitutive activation of type 1 IFN response, with a consequent abnormal stimulation of proinflammatory cytokines. SAVI typically manifests in childhood, and severely affects skin vasculature and pulmonary system, with a heterogeneity of systemic symptoms. Currently, no specific therapy has been established, despite JAK-inhibitors exhibited a remarkable degree of efficacy.

Skin and lungs are the most commonly affected organs with interstitial lung disease, skin vasculitis and nodular granulomatous dermatitis.³ Along with known skin and pulmonary involvement, different organs could be potentially affected with a variety of associated clinical presentations. Nonetheless, our understanding of ocular involvement in SAVI is still limited. Few case series described ocular inflammation including scleritis, episcleritis and keratitis in interferonopathies and glaucoma was reported in one case of SAVI.⁴ Moreover, occlusive vasculopathy has been recently described in two patients affected by

SAVI.^{4,5} Of note, none of these two cases presented signs of retinal vasculitis at fluorescein angiography (FA). After conducting a literature review on January 14th 2024 utilizing PubMed and Google Scholar using the key words “SAVI”, “STING-associated vasculitis with onset in infancy”, “uveitis”, “vasculitis”, “eye” and “ocular” we did not find any prior reports of SAVI-associated uveitis or vasculitis. Herein, we present and characterize a case of a patient with SAVI presenting with bilateral panuveitis and retinal vasculitis.

2. Case report

2.1. Ocular and medical history

A 45-year-old Caucasian male was referred for evaluation of progressive bilateral visual loss and ocular pain lasting one month. He was diagnosed with SAVI at the age of 40 through a skin biopsy and further genetic investigations confirmed the diagnosis with detection of p. V155M mutation.

Patient's external examination showed multiple cicatricial skin lesions, complete alopecia, and nasal cartilages deformation with an important saddle nose deformity causing chronic naso-lacrimal obstruction.

A severe interstitial lung disease with secondary chronic shortness of breath and recurrent pulmonary infections was confirmed on chest CT

* Corresponding author. Department of Ophthalmology, University Vita-Salute, IRCCS Ospedale San Raffaele, Milan, Italy.

E-mail address: miserocchi.elisabetta@hsr.it (E. Miserocchi).

<https://doi.org/10.1016/j.ajoc.2024.102046>

Received 11 October 2023; Received in revised form 15 January 2024; Accepted 27 March 2024

Available online 10 April 2024

2451-9936/© 2024 Published by Elsevier Inc. This is an open access article under the CC BY-NC-ND license (<http://creativecommons.org/licenses/by-nc-nd/4.0/>).

Abbreviations

SAVI	Stimulator of interferon Genes (STING)-Associated Vasculitis with Onset in Infancy
JAK	Janus Kinase

scan.

The patient was treated with JAK 1/2 inhibitor (baricitinib), low dose corticosteroids and oxygen support to relieve the pulmonary insufficiency.

2.2. Ocular examination

At our first examination, his best corrected visual acuity (BCVA) was 20/30 in the right eye and 20/50 in the left eye. Intraocular pressure (IOP) was 48 mmHg and 34 mmHg, respectively. Cicatricial conjunctivitis with meibomian gland obstruction and mild conjunctival injection was observed in both eyes, with trichiasis in the left upper eyelid. Slit lamp examination showed granulomatous keratic precipitates with 2+ cells and flare in the anterior chamber of both eyes (Fig. 1). Gonioscopy revealed an open angle with diffuse peripheral anterior synechiae. Dilated fundus examination showed diffuse signs of retinal vasculitis with perivascular sheathing and cuffing in both eyes and a blunted macular reflex in the left eye, suggesting the presence of macular edema. A symmetric area of retinal pigment epithelium (RPE) and choriocapillaris rarefaction was observed in the inferonasal region of the retina in both eyes (Fig. 2).

Structural optical coherence tomography (OCT) revealed the presence of intraretinal fluid and a small serous retinal detachment under

the fovea in the left eye. The choroid exhibited normal thickness and structure at enhanced depth imaging (EDI) (Fig. 3). Early FA showed diffuse peripheral vascular abnormalities in the right eye. Late FA revealed bilateral symmetric and diffuse mid-peripheral leakage with a fern-like pattern compatible with retinal vasculitis and optic disc leakage suggesting bilateral papillitis. Dye pooling due to macular edema was observed in the left eye (Fig. 3).

Systemic methotrexate with 10 mg subcutaneous weekly methotrexate was added to JAK inhibitor therapy. Maximal medical anti-glaucoma therapy was instituted to reduce the IOP values in both eyes, and a topical steroid therapy was initiated. Extensive systemic work-up for the most common infectious (tuberculosis, syphilis, Lyme disease, herpetic virus serology) and non-infectious causes (rheumatoid arthritis, HLA-B27 associated uveitis, Behçet disease, Birdshot chorioretinopathy) of uveitis has been performed and resulted negative. The patient was lost to ophthalmologic and rheumatologic follow-up at our institute. The referring ophthalmologist reported an improvement of the intraocular inflammation at 2-month follow-up, but still a suboptimal control of IOP.

3. Discussion

We present a challenging case of SAVI-associated uveitis and retinal vasculitis, which sheds light on the potential ocular complications of this systemic autoinflammatory disease. SAVI was recently described in 2014 as a systemic vasculitis and included among other type I interferonopathies.⁶ Most vasculitis conditions exhibit ocular involvement; nonetheless, reports regarding ocular involvement of SAVI are exceedingly scarce and poorly detailed.⁴ The hereby presented report depicts the features of uveitis and retinal vasculitis in a patient affected by SAVI and presents multimodal imaging characterization of retinal vasculitis. Specifically, we describe a case of bilateral non granulomatous

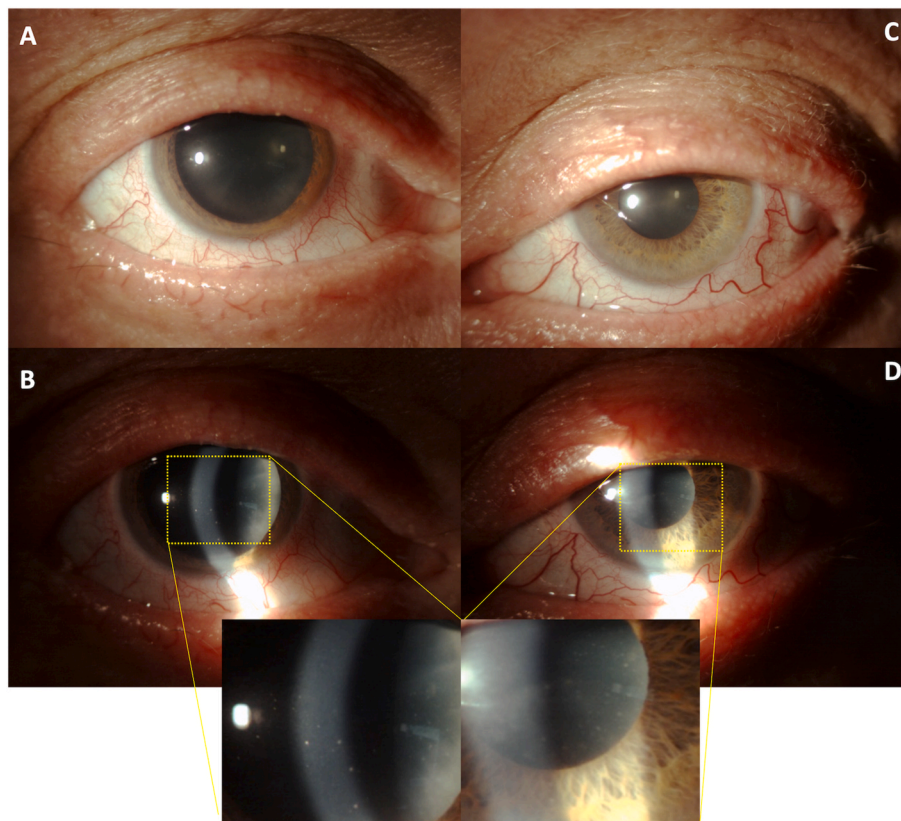


Fig. 1. Anterior segment slit lamp examination shows bilateral anterior uveitis. Conjunctival hyperemia (OD > OS) (A and C) and granulomatous keratic precipitates (B and D) are present in both eyes. Trichiasis is present in the left upper eyelid. (C).

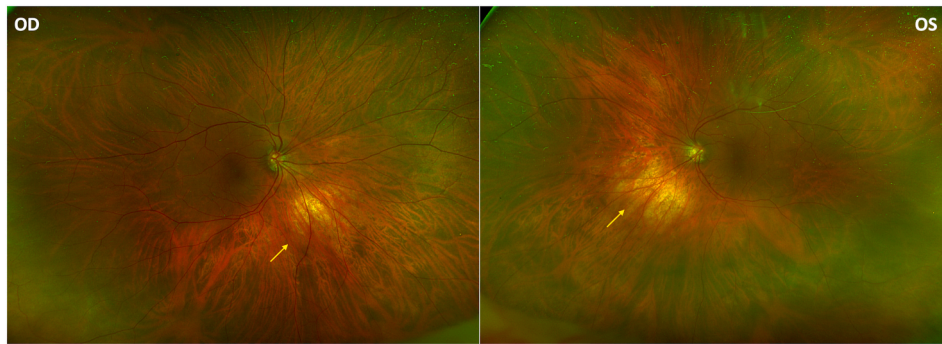


Fig. 2. Fundus ultrawide-field multicolor imaging. Fundus imaging reveals a myopic fundus with choroidal vessels easily visible, a tilted disc and a symmetric area of retinal pigment epithelium and choriocapillaris rarefaction in the inferonasal region of the retina (yellow arrows) in both eyes. A blunted macular reflex is present in the left eye. (For interpretation of the references to color in this figure legend, the reader is referred to the Web version of this article.)

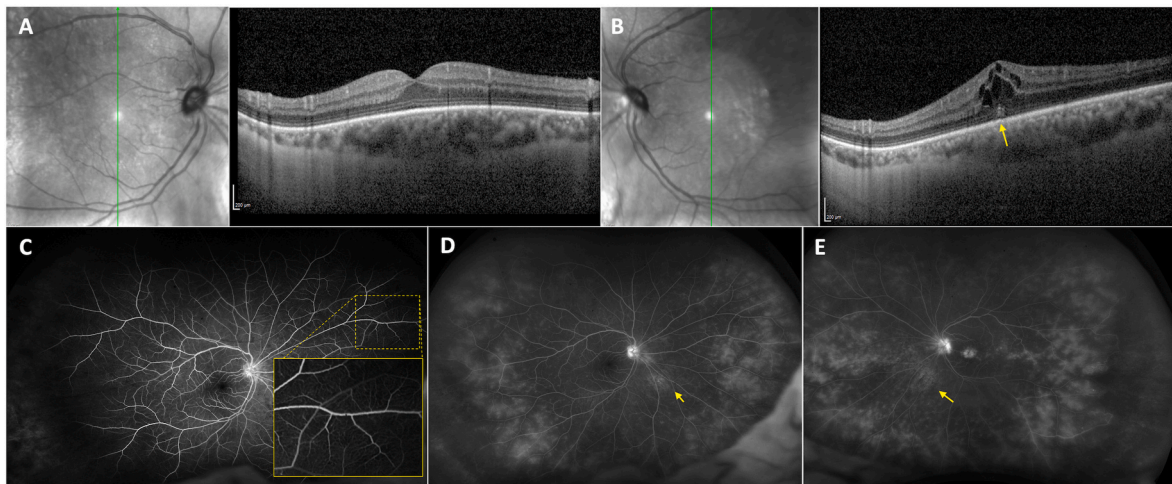


Fig. 3. Structural optical coherence tomography (OCT) and fundus fluorescein angiography. A-B. Structural OCT reveals intraretinal fluid in the left eye (B), with the presence of a small sub-foveal neuroepithelium detachment (yellow arrow). C. Early fluorescein angiography reveals diffuse peripheral microvascular abnormalities in the right eye (yellow dotted square). Early FA frames in the left eye have not been acquired due to patient's nausea and vomit after fluorescein injection D and E. Late fluorescein angiography reveals mid-peripheral vascular leakage with a fern-like pattern and a hot disc in both eyes (OS > OD). Fluorescein pooling confirms the presence of macular edema in the left eye. A mild window defect can be observed in both eyes in the inferonasal region, corresponding to the region of retinal atrophy at fundus examination (yellow arrows). (For interpretation of the references to color in this figure legend, the reader is referred to the Web version of this article.)

panuveitis with macular edema and bilateral retinal vasculitis and secondary glaucoma. Additionally, a symmetric area of RPE and choriocapillaris rarefaction has been observed.

Although no standard of care has been established, previous experiences report efficacy of JAK inhibitors in the management of SAVI.⁴ We decided to strengthen the immunosuppressive therapy by adding weekly methotrexate. Combination therapy with low dose methotrexate was rapidly effective in controlling intraocular inflammation of the anterior chamber.

Type 1 interferonopathies are characterized by a constitutive activation of type 1 IFN and generally present as autoinflammatory syndromes.⁴ Among type 1 interferonopathies, ocular involvement has been already depicted. Particularly, autosomal dominant retinal vasculopathy with cerebral leukoencephalopathy and systemic manifestations (RVCL-S) mainly affects capillaries and small arteries of the retina and brain.⁷ In RVCL-S, the fluorescein angiography and fundus findings resemble our presented case, presenting fluorescein leakage and telangiectasias.

The pathogenesis of retinal vasculitis in SAVI is still unknown. Recently, two children were found with retinal vasculopathy, and the authors speculated about the IFN-mediated formation of microthrombi as cause of the occlusive vasculopathy.⁵ Additionally, the FA pattern reported in these two children was remarkably different compared to

our FA findings. The first case presented by Cooray et al. exhibited vessel tortuosity, dilation and intra and extra retinal exudates, without signs of leakage or vasculitis. The second case presented bilateral tractional retinal detachment (RD), and findings at FA might be due to the tractional RD itself.⁵ In contrast to these cases, we observed a vasculitis in an inflammatory setting. We speculated it is caused by the excess of type I interferon (IFN)-inducible gene products and downstream inflammatory cytokines, with endothelium reactivity and loss of blood-retinal barrier. The uncontrolled amount of pro-inflammatory cytokines justifies the presence of retinal vasculitis and panuveitis, with anterior segment involvement. Nonetheless, we cannot exclude a genetic component mimicking a dystrophic pattern, justifying the bilateral symmetric triangular area of RPE and choriocapillaris rarefactions. Most importantly, we believe that SAVI could exhibit heterogeneous features of ocular involvement, with inflammation playing a pivotal role.

4. Conclusion

We report and characterize an intriguing case of SAVI-associated uveitis and retinal vasculitis complicated by macular edema and secondary glaucoma. Further studies will elucidate and characterize the relationship between genotype and this novel inflammatory phenotypic manifestation of this extremely rare disease. Intraocular inflammation

should be considered a red flag in patients with SAVI and ophthalmologic examination should be recommended, to diagnose and promptly treat sight-threatening conditions.

Patient consent

Consent to publish the case report was not obtained. This report does not contain any personal information that could lead to the identification of the patient.

Funding

No funding or grant support.

Authorship

All authors attest that they meet the current ICMJE criteria for Authorship and contributed significantly to the creation of the manuscript.

CRediT authorship contribution statement

Matteo Menean: Conceptualization, Data curation, Formal analysis, Investigation, Writing – original draft, Writing – review & editing. **Alessandro Marchese:** Conceptualization, Data curation, Supervision, Validation. **Giulio Modorati:** Formal analysis, Investigation, Methodology, Resources, Supervision, Validation, Visualization. **Rosa Favale:** Investigation, Visualization. **Francesco Boscia:** Methodology, Project administration, Validation. **Francesco Bandello:** Conceptualization, Data curation, Formal analysis, Supervision, Validation, Visualization. **Elisabetta Miserocchi:** Conceptualization, Data curation, Formal analysis, Software, Supervision, Validation, Visualization, Writing – original draft, Writing – review & editing.

Declaration of competing interest

Matteo Menean, Alessandro Marchese, Giulio Modorati, Rosa Favale, Francesco Boscia, Elisabetta Miserocchi: nothing to disclose.

Francesco Bandello consultant for: Allergan Inc (Irvine, California, USA), Bayer Shering-Pharma (Berlin, Germany), Hoffmann-La-Roche (Basel, Switzerland), Novartis (Basel, Switzerland), Sanofi-Aventis (Paris, France), Thrombogenics (Heverlee, Belgium), Zeiss (Dublin, USA), Boehringer-Ingelheim, Fidia Sooft, Ntc Pharma, Sifi.

Acknowledgements

None.

References

- Frémont ML, Hadchouel A, Berteloot L, et al. Overview of STING-associated vasculopathy with onset in infancy (SAVI) among 21 patients. *J Allergy Clin Immunol Pract.* 2021;9(2). <https://doi.org/10.1016/j.jaip.2020.11.007>.
- Dai YF, Liu XY, Zhao ZP, He JX, Yin QQ. Stimulator of interferon genes-associated vasculopathy with onset in infancy: a Systematic review of case reports. *Front Pediatr.* 2020;8. <https://doi.org/10.3389/fped.2020.577918>.
- Staels F, Betrains A, Doubel P, et al. Adult-onset ANCA-associated vasculitis in SAVI: extension of the phenotypic spectrum, case report and review of the literature. *Front Immunol.* 2020;11. <https://doi.org/10.3389/fimmu.2020.575219>.
- Cetin Gedik K, Lamot L, Romano M, et al. The 2021 EULAR and ACR points to consider for diagnosis and management of autoinflammatory type I interferonopathies: CANDLE/PRAAS, SAVI and AGS. *Ann Rheum Dis.* 2022. Published online.
- Cooray S, Henderson R, Solebo AL, Ancliffe P, Eleftheriou D, Brogan PA. Retinal vasculopathy in STING-associated vasculitis of infancy (SAVI). *Rheumatology.* 2021; 60(10). <https://doi.org/10.1093/rheumatology/keab297>.
- Liu Y, Jesus AA, Marrero B, et al. Activated STING in a vascular and pulmonary syndrome. *N Engl J Med.* 2014;371(6). <https://doi.org/10.1056/nejmoa1312625>.
- Richards A, Van Den Maagdenberg AMJM, Jen JC, et al. C-terminal truncations in human 3'-5' DNA exonuclease TREX1 cause autosomal dominant retinal vasculopathy with cerebral leukodystrophy. *Nat Genet.* 2007;39(9). <https://doi.org/10.1038/ng2082>.