



Magnetic compression anastomosis via EUS-guided hepaticogastrostomy for recanalization of complete common hepatic bile duct transection

Yingluk Sritunyarat, MD,¹ Thawee Ratanachu-Ek, MD,² Siriboon Attasaranya, MD,^{1,2}
Wiriaporn Ridditid, MD,¹ Rungsun Rerknimitr, MD¹

The magnetic compression anastomosis technique provides a minimally invasive method to create an anastomosis by using the attractive force between 2 magnets. Recently, the magnetic compression anastomosis has

been applied to both malignant and benign biliary strictures.^{1,2} We report herein a novel endoscopic technique for the treatment of complete transection of the common hepatic bile duct after liver resection.

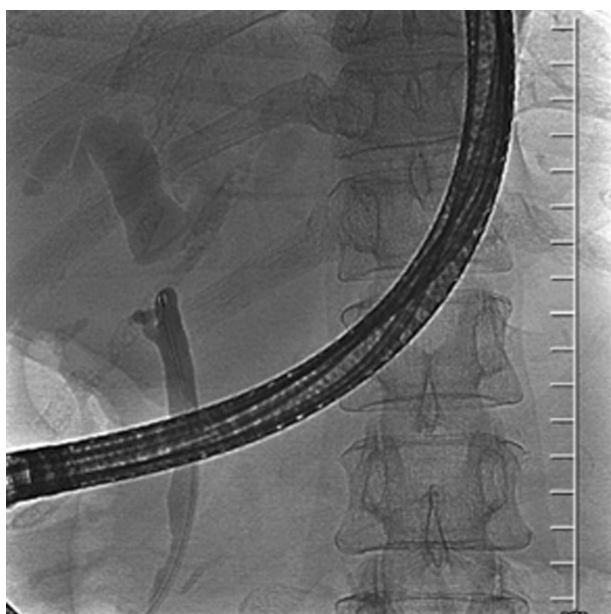

Figure 1. ERCP revealed complete common hepatic bile duct transection.



Figure 2. A custom-made gold-plated neodymium magnet, 3 mm in diameter, was loaded onto a 10F stent pusher. A side hole was created on the pusher using a surgical blade to facilitate over-the-guidewire insertion.

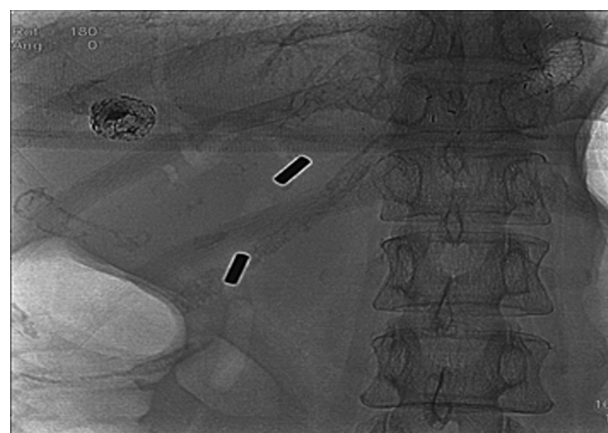


Figure 3. The second magnet was placed just below the transection site as close to the first magnet as possible, leaving only a 1.5-cm gap between the magnets.

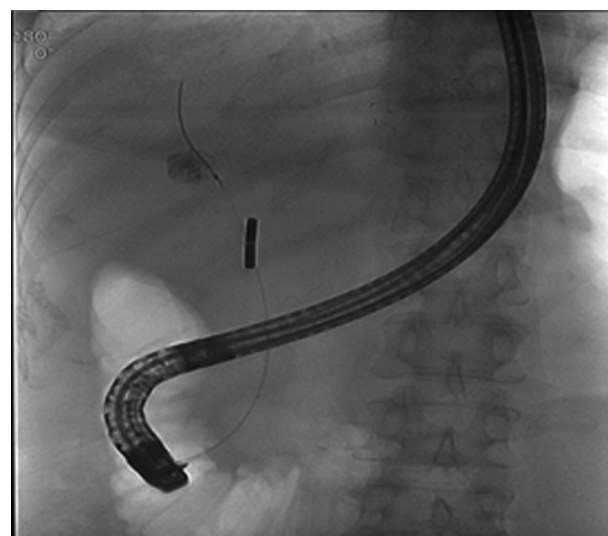


Figure 4. One week later, the 2 magnets were approximated at the transection site. ERCP was then performed with successful passage of a 0.035-inch Jagwire (Boston Scientific, Marlborough, Mass, USA) across the previously transected duct.

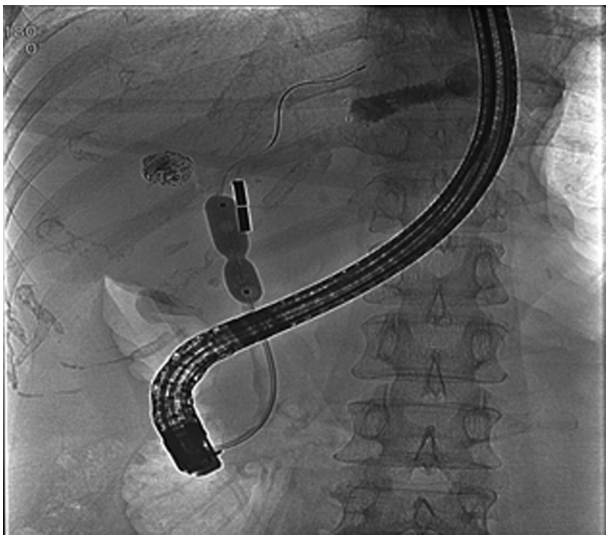


Figure 5. An 8-mm balloon dilator was used over the guidewire to dilate the stricture site.

A 49-year-old woman who had undergone liver resection (Video 1, segment 5, 6, available online at www.giejournal.org; Figs. 1-7) for hepatocellular carcinoma 1 year prior presented with progressive painless jaundice. Abdominal CT showed dilated common hepatic and intrahepatic bile ducts. Subsequent ERCP revealed complete common hepatic bile duct transection. EUS-guided hepaticogastrostomy was performed and a 7F, 15-cm double-pigtail plastic stent was inserted into the hepaticogastrostomy tract through segment 2 of the liver. However, the patient developed a liver abscess 2 months later. The hepaticogastric plastic stent was then exchanged for a 10- × 60-mm fully covered self-expandable metal biliary stent to ensure adequate biliary drainage. Cholangiogram again demonstrated a complete transection of the common hepatic bile duct.

To internalize biliary drainage via the natural transpapillary route, we decided to use the magnetic compression anastomosis technique. A custom-made gold-plated neodymium magnet, 3 mm in diameter, was loaded onto a 10F stent pusher. A side hole was created on the pusher using a surgical blade to facilitate over-the-guidewire insertion. First, the hepaticogastrostomy tract was cannulated using a swing-tip catheter through the fully covered metal stent. The daughter magnet then was introduced into the hepaticogastrostomy tract and detached using a Savary-Gilliard guidewire (Cook Medical, Bloomington, Ind, USA). Thereafter, the magnet was pushed forward to the transection site by a sphincterotome. Once the magnet was at the desired site just above the transected duct, transpapillary biliary cannulation followed by another 3-mm parent magnet insertion was performed. The second magnet was placed just below the transection site as close to the first magnet as possible, leaving only a 1.5-cm gap between the magnets.

An exploratory abdominal x-ray 1 week later confirmed satisfactory approximation between the 2 magnets. ERCP

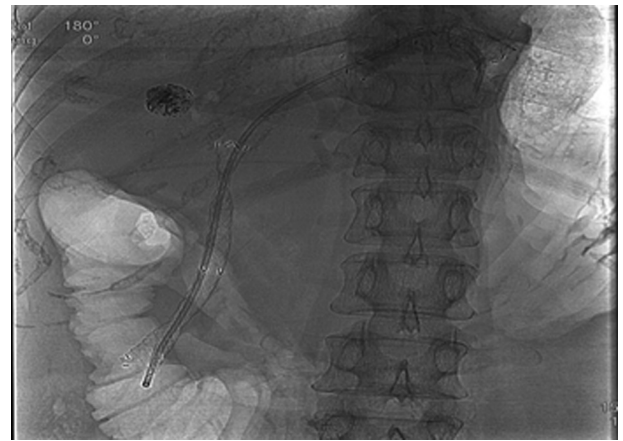


Figure 6. A 10- × 80-mm fully covered self-expanding metal stent with an interlocking 7F, 15-cm double-pigtail plastic stent was then placed across the stricture site.

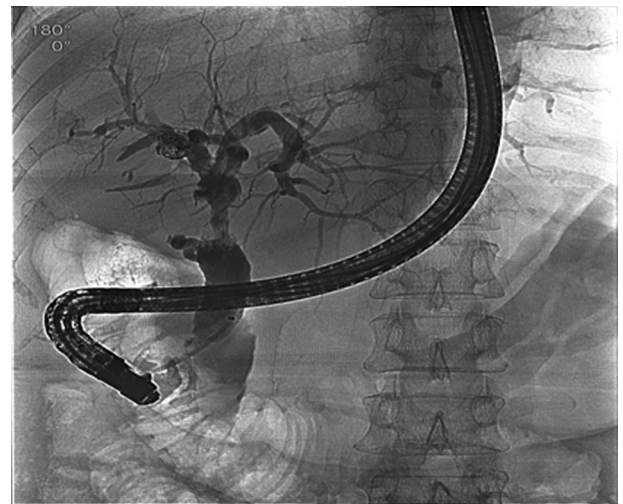

Figure 7. A cholangiogram after stent removal demonstrated complete recanalization of the common hepatic duct with good bile flow through the transection site.

was then performed with successful passage of a 0.035-inch Jagwire across the previously transected duct. An 8-mm balloon dilator was used over the guidewire to dilate the stricture site. Once the transected bile ducts were recanalized, the 2 magnets were immediately removed as they were spontaneously attracted to the metal tip of the duodenoscope. A 10- × 80-mm fully covered self-expandable metal stent with an interlocking 7F, 15-cm double-pigtail plastic stent was then placed across the stricture site. Both stents were left in place for 8 weeks. A cholangiogram after stent removal demonstrated complete recanalization of the common hepatic duct with good bile flow through the transection site. The patient remained asymptomatic at the 4-month follow-up visit.

The common routes of magnet delivery in the magnetic compression anastomosis technique are percutaneous via

percutaneous transhepatic biliary drainage tract and peroral using ERCP. However, percutaneous drain compromises the patient's quality of life and carries a significant infection risk. Magnetic compression anastomosis via an EUS-guided hepaticogastrostomy tract offers a novel noninvasive incisionless alternate option.³

DISCLOSURE

All authors disclosed no financial relationships.

REFERENCES

1. Jang SI, Kim JH, Won JY, et al. Magnetic compression anastomosis is useful in biliary anastomotic strictures after living donor liver transplantation. *Gastrointest Endosc* 2011;74:1040-8.
2. Li Y, Sun H, Yan X, et al. Magnetic compression anastomosis for the treatment of benign biliary strictures: a clinical study from China. *Surg Endosc* 2020;34:2541-50.
3. Jang SI, Cho JH, Lee DK. Magnetic compression anastomosis for the treatment of post-transplant biliary stricture. *Clin Endosc* 2020;53:266-75.

Gastrointestinal Endoscopy Excellence Center, Department of Medicine, Faculty of Medicine, Chulalongkorn University and King Chulalongkorn Memorial Hospital, Thai Red Cross Society, Bangkok, Thailand (1), Rajavithi Surgery Endoscopy Department, Faculty of Medicine, Rajavithi Hospital, Bangkok, Thailand (2).

Copyright © 2021 American Society for Gastrointestinal Endoscopy. Published by Elsevier Inc. This is an open access article under the CC BY-NC-ND license (<http://creativecommons.org/licenses/by-nc-nd/4.0/>).

<https://doi.org/10.1016/j.vgie.2021.05.003>

Submit to *VideoGIE*

VideoGIE is now indexed in PubMed Central.

VideoGIE is an Open Access, online-only journal indexed in PubMed Central. Submit video cases of endoscopic procedures used in the study, diagnosis, and treatment of digestive diseases.

VideoGIE publishes the following article types:

- **Case Reports:** Reports of the diagnosis and management of digestive diseases using a single case.
- **Case Series:** Reports of the diagnosis and management of digestive diseases using 3 or more cases.
- **Tools and Techniques:** Educational videos demonstrating the use of a particular endoscopic tool or technique. The goal of this section is to help trainees, endoscopy nurses, and technicians learn how best to use the tools of endoscopy for high-quality care.

All manuscripts must be submitted online at <http://www.editorialmanager.com/vgie>