

Flatline on the alternate vector... Is this subcutaneous implantable cardiac defibrillator lead fractured?



Louisa O'Neill, MD, PhD, Kris Gillis, MD, PhD, Jean-Yves Wielandts, MD, PhD, Gabriela Hilfiker, MD, Sebastien Knecht, MD, PhD, Mattias Duytschaever, MD, PhD, Rene Tavernier, MD, PhD, Jean-Benoit Le Polain De Waroux, MD, PhD

From the Department of Cardiology, AZ Sint-Jan Hospital, Bruges, Belgium.

Introduction

In February 2021 the United States Food and Drug Administration (FDA) issued a Class I recall of Boston Scientific's Emblem subcutaneous implantable cardiac defibrillator (S-ICD) model 3501 electrode (Boston Scientific, Marlborough, MA) following 27 cases of lead fracture.¹ These fractures may be detected by non-physiological artefacts or high impedance alerts according to device programming.² A flatline on the alternate vector (AVFL) on in-office check has further been highlighted by Boston Scientific as an important early (and possible sole) indicator of potential electrode body fracture. It is important to note, however, that not all AVFL are clinically relevant. We present 2 cases of AVFL and outline relevant investigations for further clarification.

Case report

Case 1

A 57-year-old man underwent primary prevention S-ICD insertion for ischemic cardiomyopathy with low ejection fraction. One year post-implant, the patient presented for an unscheduled visit following several beeping alarms. Device interrogation revealed 2 episodes of inappropriate therapy owing to noise oversensing on the secondary vector (Figure 1). Further analysis demonstrated a flatline in the alternate vector. To further clarify, the Boston Scientific Automated Screening Tool (AST) was applied, with surface electrodes positioned directly above the S-ICD sensing electrodes. This demonstrated a normal voltage signal in the alternate vector configuration, suggesting an underlying lead integrity issue. Beeping alarms were triggered by excessive shock impedance. Finally, chest radiography confirmed

KEYWORDS Alternate vector flatline; Automated screening tool; Device complication; Lead fracture; Subcutaneous implantable cardiac defibrillator (Heart Rhythm Case Reports 2021;7:758–761)

Conflict of Interest: Over the past 2 years, JBLPDW received nonsignificant compensation for proctoring and teaching activities from Boston Scientific. AZ Sint-Jan cardiology department reports an ISR grant from Boston Scientific for research activities. **Address reprint requests and correspondence:** Dr Louisa O'Neill, Department of Cardiology, AZ Sint-Jan Hospital, Bruges, Belgium. E-mail address: louisa.oneill@azsintjan.be.

KEY TEACHING POINTS

- Boston Scientific Model 3501 subcutaneous implantable cardiac defibrillator (S-ICD) electrodes are prone to fracture in a typical manner.
- Accordingly, several important indicators of such fracture have been identified, including a flatline on the alternate vector, which should prompt further scrutiny.
- Not all alternate flatlines indicate lead fracture. Device history, surface 12-lead electrocardiography, and the automatic S-ICD screening tool can be used to help differentiate genuine from pseudo lead fractures.

a complete lead fracture. On extraction, complete transection was seen immediately distal to the proximal sensing ring (Figure 1).

Case 2

A 55-year-old man with ischemic cardiomyopathy and severe left ventricular impairment underwent primary prevention S-ICD implantation. Three months later he presented to the Emergency Department with acute dyspnea, ultimately attributed to emotional stress; however, a device check on presentation demonstrated an AVFL (Figure 2). In this case, chest radiography was unchanged from implant, with no evidence of lead fracture. Review of 12-lead electrocardiograms (ECG) on this presentation and at implant demonstrated low-amplitude R waves in lead III with progressive diminution over time (Figure 2). Using the advanced view of the AST, the extremely low amplitude of the filtered S-ECG in the alternate vector was confirmed (measured amplitude 0.042 mv / S-ICD sensing floor = 0.08 mv), thus explaining the apparent flatline on device readout. Given these findings and the absence of other features indicative of a lead integrity breach, the AVFL was deemed a "pseudo-fracture"

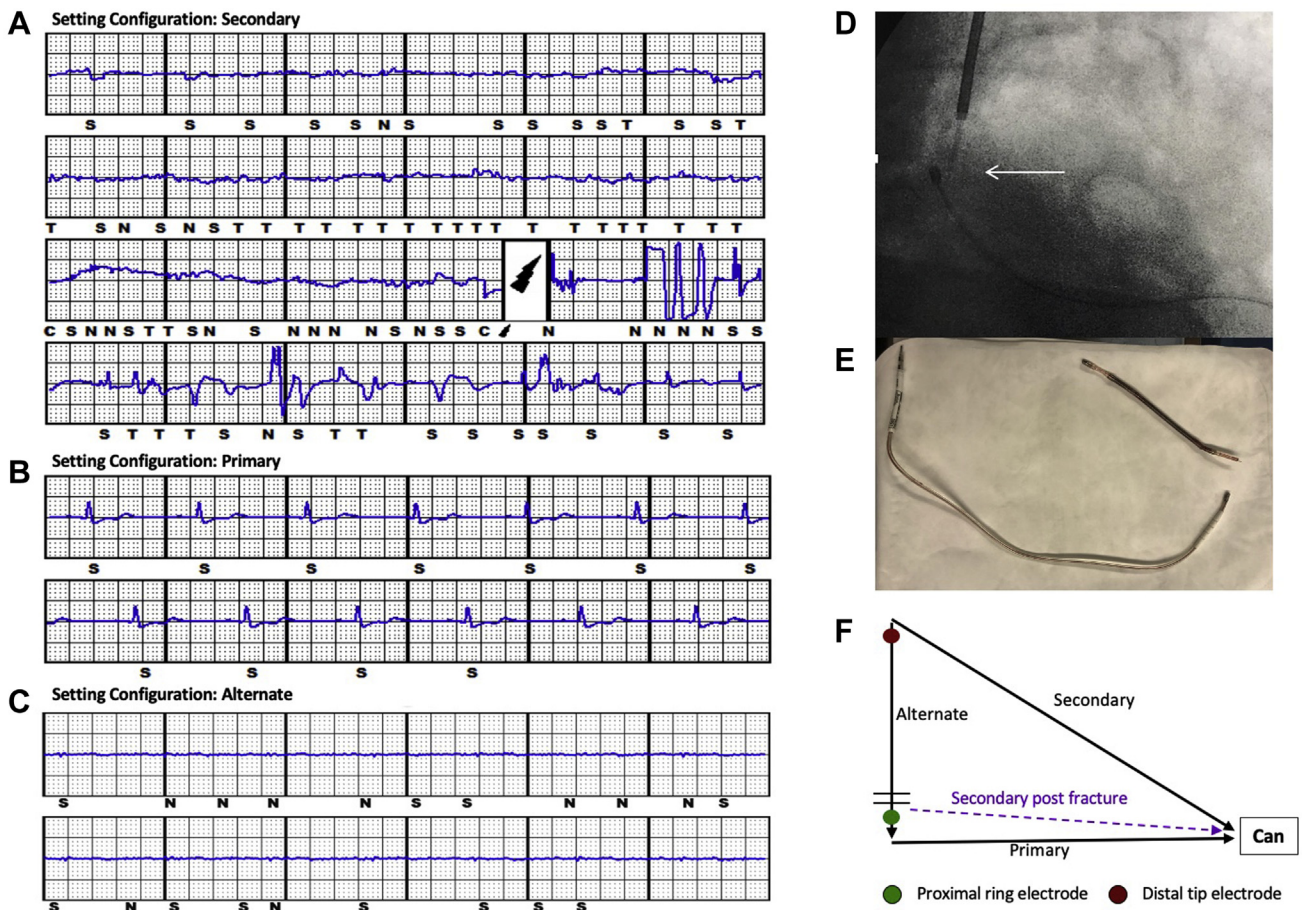


Figure 1 A: Mechanical precursor artifacts on the secondary vector in case 1 owing to lead fracture affecting the distal sense conductor and resulting in an inappropriate shock. B,C: In-office capture of all sensing vectors demonstrated a normal signal on the the primary vector (B), which is unaffected in lead fracture, and a flatline on the alternate vector (C). D: Complete lead transection was seen on radiograph in a typical location distal to the proximal sense ring (white arrow). E: The lead was appropriately explanted. F: The 3 programmable sensing vectors are displayed, with the location of the fracture indicated by the transverse lines distal to the proximal sensing ring (green dot). After fracture, the secondary vector (dashed line) will closely mimic the primary owing to the “electrical repositioning” of the lead.

consequent on low-voltage R waves secondary to underlying cardiomyopathy.

Discussion

Implantable cardiac defibrillators represent a cornerstone therapy in the prevention of sudden cardiac death. The entirely subcutaneous or S-ICD system was developed to reduce lead-related morbidity associated with traditional transvenous systems and carries a class I, IIa, and IIb recommendation for prevention of sudden cardiac death.³ Approximately 90,000 patients are recipients of this system worldwide.⁴ Implantation complication rates are low⁵ and the recently published Praetorian trial demonstrated noninferiority of the S-ICD, compared to the transvenous system.⁶

Since 2017 approximately 47,000 model 3501 EMBLEM S-ICD electrodes have been implanted, with a survival probability of 99.4% at 33 months.⁴ In 2020 Huynh and colleagues⁷ reported a first case of lead fracture in this model, occurring after a mechanical fall. Subsequently Gutleben and colleagues⁸ described complete lead transection, without

trauma, in a young patient. In February 2021 the FDA issued a Class I recall following 27 reports of similar lead fracture in this model. According to information from Boston Scientific, all fractures occurred immediately distal to the proximal sensing ring, corresponding to a notch created during lead assembly, allowing for connection of conductors to the proximal sensing ring. Owing to the arrangement of conductors within the electrode, fatigue fractures at this point affect the distal sense conductor first, followed by both defibrillation conductors on propagation of the fracture through the body of the lead (Figure 3). The quoted occurrence rate is 0.2% at 41 months with a risk of life-threatening harm of 0.004% at 10 years.² One report of patient death exists; however, although the lead fracture was correctly diagnosed in this case, no corrective action was performed.

Detection

Clinical manifestations of S-ICD lead fracture vary according to programmed sensing configuration (Figure 1). In systems programmed to secondary (distal sense electrode – S-ICD active case) or alternate (distal sense electrode – proximal

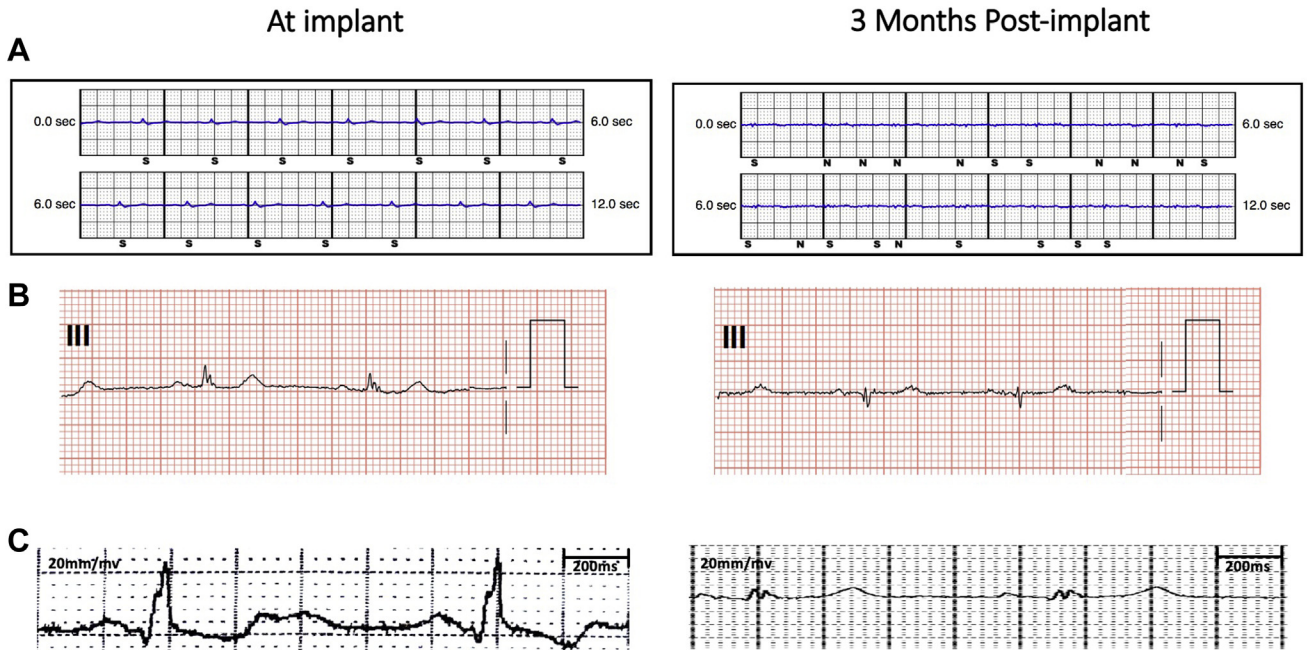


Figure 2 A: Alternate vector device readout in case 2 demonstrating low-amplitude R waves postimplant with diminution to a flatline at 3 months. Irregular noise (N) markers indicate irregular morphologies, not matching waveform appraisal, with rejection of sensed events by the certification algorithm. B: Lead III on the electrocardiogram (ECG) provides an approximate view of the alternate vector signals, with low-amplitude R waves at implant reducing further at the 3-month time point. C: Alternate vector recording using the Boston Scientific Automated Screening Tool (Boston Scientific, Marlborough, MA) demonstrating appropriately sensed S-ECG (measured amplitude 0.35 mV) at preimplant screening, and extremely low amplitude R waves (0.042 mV) reflecting the alternate vector flatline at 3 months postimplant.

ring) configurations, the initial fracture of the distal sense conductor may manifest as mechanical “precursor” artefacts on episode electrograms, potentially resulting in oversensing

and inappropriate shocks (Figure 1). These episodes have been demonstrated up to 2 months before fracture propagation to the high-voltage conductors. However, they need to

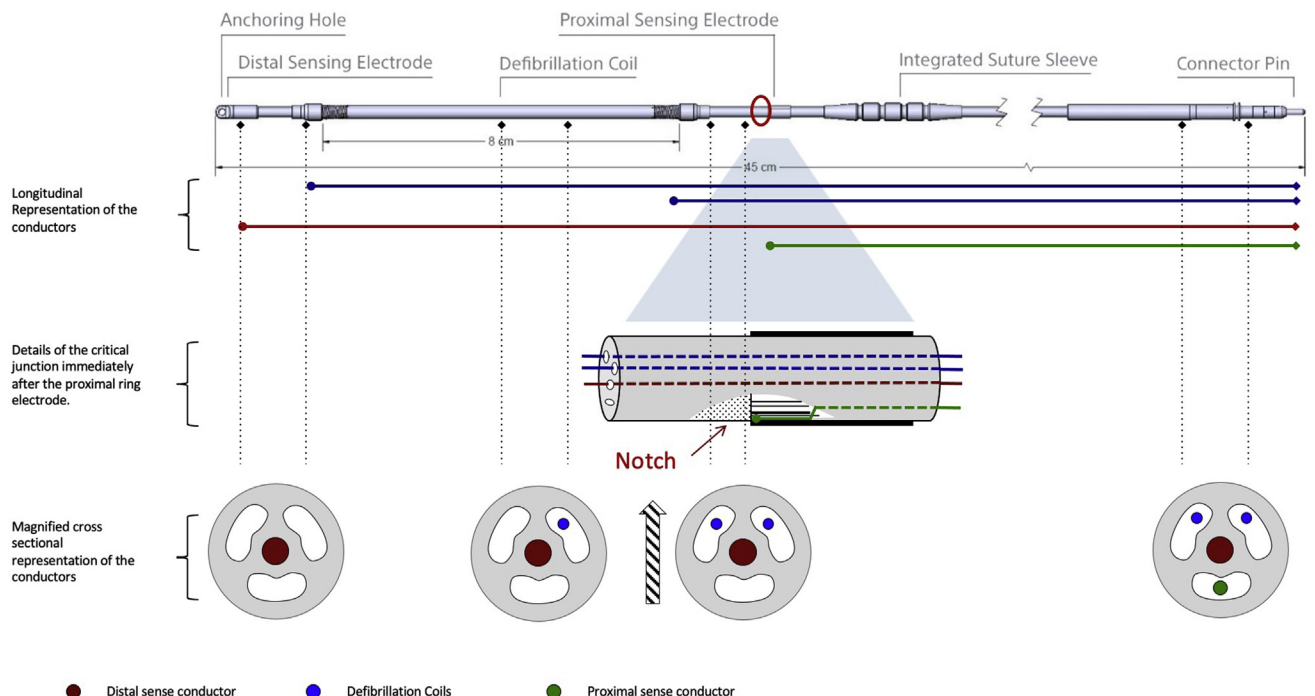


Figure 3 Arrangement of conductors within the lead and location of notch corresponding to typical fracture location immediately distal to the proximal ring electrode. Fractures at this point will propagate inward (hatched arrow), affecting the distal sense conductor (red) first, followed by the defibrillation coils (blue). The proximal sense conductor will not be affected by fractures of this nature, reflected by a normal cardiac signal in the primary sensing configuration.

be relatively sustained and trigger a charge of the capacitors to be recorded. For systems programmed to the most common primary sensing configuration (proximal sense ring – S-ICD active case), a fracture in the distal sense conductor is not detectable on episode electrograms and the first indication of fracture occurs with involvement of the defibrillation coils, signaled by high impedance alerts. Importantly, owing to the loss of the distal sense conductor, on in-office interrogation the alternative vector will appear as a flatline while secondary vector signals will appear morphologically similar to those of the primary vector.

Follow-up and management

Boston Scientific has recommended close monitoring for the above features through in-office checks at 3 month intervals and weekly remote monitoring on the LATITUDE system.² The importance of reviewing stored episodes for precursor artefacts, of capture of all sensing vectors to assess for AVFL, and of prompt investigation of high impedance alerts is emphasized. Posteroanterior and lateral chest radiography is essential to assess lead integrity, and prompt replacement is recommended for leads demonstrating compromised integrity, indicated by any of the above features. Prophylactic replacement of the 3501 electrode is not recommended for leads without evidence of fracture, however.

Alternate vector flatlines

While enhanced vigilance regarding the model 3501 lead is essential, this case series emphasizes that not all AVFL represent lead fracture. Lead fracture can be confirmed on radiography, as in our first patient, who had a visible lead transection on radiography, accompanied by inappropriate shocks and impedance alarms. In our second case the flatline occurred in combination with a normal radiograph. Normal radiography of the lead, however, does not exclude a fracture, as early fatigue cracks affecting only the distal sense conductor may not be immediately apparent on chest radiograph. Without further investigation, therefore, a flatline on device check, even in the presence of a normal chest radiograph, may trigger inappropriate extraction of an uncompromised lead. Although rarely present in isolation, a flatline on the alternate vector may also represent the only manifestation of an early lead fracture. Along with the recommendations provided by Boston Scientific, in the absence of noise precursors on stored episodes or a high shock impedance, we suggest looking at body surface recordings for further clarification. Review of the conventional 12-lead ECG, in particular lead III, provides an approximate estimate of the alternate vector signal and is useful in this instance. Furthermore, the advanced view of the AST can confirm

the ECG findings through measurement of the QRS amplitude after application of the same filters and bandpass as the S-ICD, therefore delivering a view more closely resembling the alternate S-ECG as used by the device. In the situation of an AVFL, a normal QRS amplitude on any body surface recording using a similar derivation is highly suggestive of a true fracture. In contrast, if low or absent R waves are present, then a pseudo-fracture, resulting from intrinsic cardiac activation that is orthogonal to the bipolar recording, is more likely.

Conclusion

S-ICD lead fracture has been reported in 27 Boston Scientific Emblem model 3501 electrodes and carries the potential for inappropriate shocks and failed therapy. While the overall event probability appears low, the potential severity of the problem warrants heightened vigilance and ongoing reporting of fractures. Company recommendations for monitoring are based on detection of typical features on device check; however, not all of these signal lead fracture. We highlight a case of an alternate vector flatline in an uncompromised lead and suggest 12-lead ECG assessment of intrinsic cardiac activation, supplemented with use of the S-ICD automated screening tool, to help differentiate real from pseudo-fractures in patients with this finding.

References

1. Boston Scientific Recalls EMBLEM S-ICD Subcutaneous Electrode (Model 3501) Due to Risk of Fractures | FDA [Internet]. <https://www.fda.gov/medical-devices/medical-device-recalls/boston-scientific-recalls-emblem-s-icd-subcutaneous-electrode-model-3501-due-risk-fractures>.
2. Important Medical Device Advisory - EMBLEMTM S-ICD Subcutaneous Electrode (Model 3501) with a potential for electrode body fracture (Boston Scientific Field Action Reference: 92384167-FA). [Internet]. 2020 [cited 2021 May 28]. https://www.bostonscientific.com/content/dam/bostonscientific/quality/dlt/reg-code-228/2020Dec_BSC_EmblemElectrode3501_PhysLtr_Final.pdf.
3. Priori SG, Blomström-Lundqvist C. 2015 European Society of Cardiology Guidelines for the management of patients with ventricular arrhythmias and the prevention of sudden cardiac death summarized by co-chairs. *Eur Heart J* 2015; 36:2757–2759.
4. Rhythm Management Product Performance Report Q1 Edition RESONATE™ Family of ICDs AND CRT-Ds ACCOLADE™ Family of Pacemakers INGEVITY™ + Pacing Lead Boston Scientific CRM Product Performance Report. 2021. <https://www.bostonscientific.com/content/dam/bostonscientific/quality/ppr/2021/q1/Q1%202021%20CRM%20Product%20Performance%20Report%20rev%20B.pdf>.
5. Burke MC, Gold MR, Knight BP, et al. Safety and efficacy of the totally subcutaneous implantable defibrillator: 2-year results from a pooled analysis of the IDE study and EFFORTLESS registry. *J Am Coll Cardiol* 2015;65:1605–1615.
6. Knops RE, Olde Nordkamp LRA, Delnoy P-PHM, et al. Subcutaneous or transvenous defibrillator therapy. *N Engl J Med* 2020;383:526–536.
7. Huynh H, Siroky GP, Lam P, Mohammad A, Mehta D. Partial fracture of a subcutaneous ICD lead from mechanical trauma. *J Clin Cardiol Cardiovasc Interv* 2019; 3:1–22.
8. Gutleben KJ, Nelovic V, Pujdak K, Werner M, Osmani I, Kähler J. Fracture of an S-ICD lead after two prior transvenous lead-related complications with conventional defibrillators. *Pacing Clin Electrophysiol* 2020;43:1491–1494.