

Available online at www.sciencedirect.com

ScienceDirect

journal homepage: www.elsevier.com/locate/radcr

Case Report

Rapid orbital lipolysis associated with critical illness and colectomy[☆]

Joy Li, AB^a, Aikta Rajput, BS^b, David Kosoy, BS^b, Sari Umekawa, MD^c, Anuj Rajput, MD^d, Jessica Chang, MD^e, Vishal Patel, MD, PhD^{f,*}

^aUniversity of Southern California, Keck School of Medicine, Los Angeles, CA, USA

^bSt. George's University, University Centre, Grenada

^cThe Queen's Medical Center, Department of Pulmonary Critical Care, Honolulu, HI, USA

^dLos Angeles Imaging and Interventional Consultants at PIH Health, Department of Radiology, Whittier, CA, USA

^eUniversity of Southern California, Keck School of Medicine, Department of Ophthalmology, Los Angeles, CA, USA

^fUniversity of Southern California, Keck School of Medicine, Department of Radiology, Los Angeles, CA, USA

ARTICLE INFO

Article history:

Received 30 May 2021

Revised 2 June 2021

Accepted 2 June 2021

Keywords:

Orbital lipolysis

Enophthalmos

Cachexia

Catabolism

ABSTRACT

Orbital lipolysis typically develops in the setting of a chronic catabolic state. The acute development and rapid progression of orbital lipolysis are much less commonly described. In this report, we present a rare case of a 64-year-old male who progressed from normal orbital fat content to marked orbital lipolysis in less than one month following episodes of undifferentiated shock, colonic perforation, and total colectomy. We outline the clinical course, describe the characteristic imaging findings, and provide a review of the cellular mechanisms underlying lipolysis. Our case suggests that multiple concurrent illnesses can combine to produce an extreme metabolic demand that may contribute to the uncommon development of rapidly-progressing orbital lipolysis.

© 2021 The Authors. Published by Elsevier Inc. on behalf of University of Washington.

This is an open access article under the CC BY-NC-ND license

(<http://creativecommons.org/licenses/by-nc-nd/4.0/>)

Introduction

Orbital lipolysis refers to the disappearance of orbital fat. This is most commonly described in severely emaciated patients, such as those with anorexia nervosa [1–3]. During such periods of starvation, changing hormonal and neural statuses trigger processes such as lipolysis, which results in the breakdown of triacylglycerols and mobilization of free fatty acids that may be used by tissues as sources of energy [4]. In this report, we

present the unusual case and imaging findings of a patient with orbital lipolysis in the setting of persistent cachexia following bowel perforation and total colectomy.

Case report

A 64-year-old homeless male with no known prior medical history was transported to our emergency department after

[☆] Competing Interests: The authors have declared that no competing interests exist.

* Corresponding author.

E-mail address: vishal.patel@med.usc.edu (V. Patel).

<https://doi.org/10.1016/j.radcr.2021.06.001>

1930-0433/© 2021 The Authors. Published by Elsevier Inc. on behalf of University of Washington. This is an open access article under the CC BY-NC-ND license (<http://creativecommons.org/licenses/by-nc-nd/4.0/>)

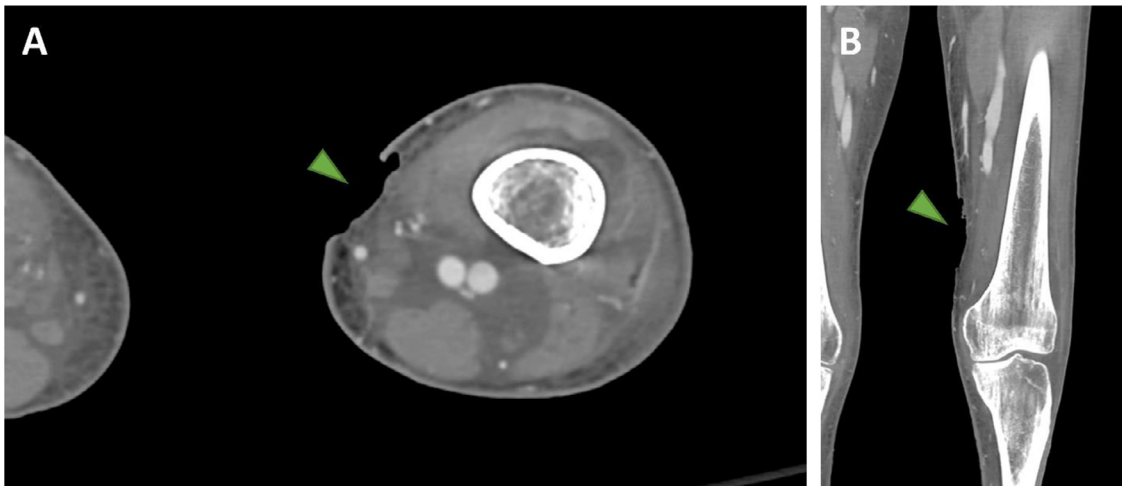


Fig. 1 – Axial (A) and coronal (B) contrast-enhanced CT of the left lower extremity presented on soft-tissue windows demonstrates a 6.2 cm skin ulceration in the medial distal left thigh (green arrowheads) with adjacent skin thickening and diffuse subcutaneous and soft tissue edema.

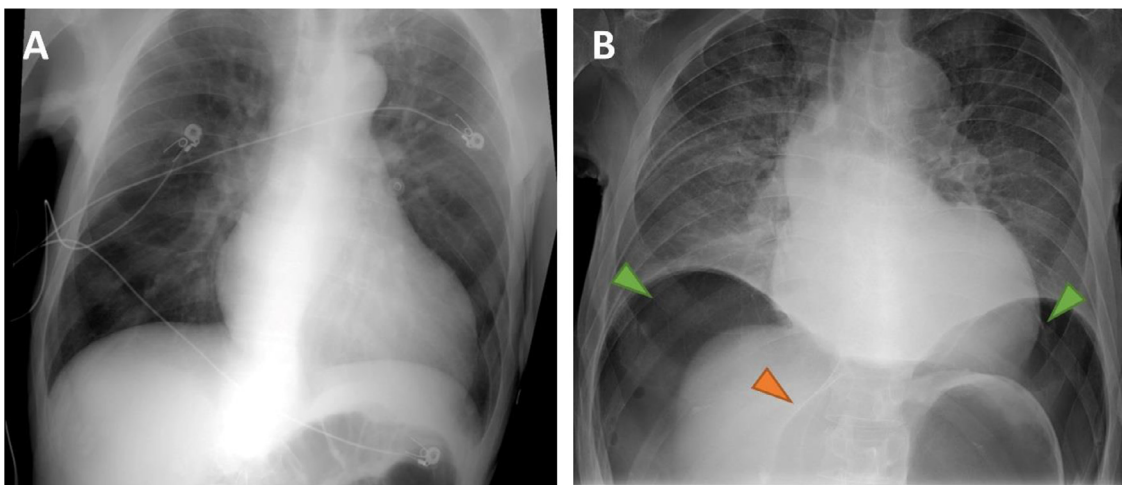


Fig. 2 – Chest radiograph obtained upon admission (A) demonstrates only mild central vascular congestion. In comparison, a chest radiograph obtained after the onset of acute abdominal pain and hypotension on hospital day 14 (B) demonstrates significant free air below the diaphragm (green arrowheads) and the falciform ligament sign (orange arrowhead) consistent with pneumoperitoneum.

being discovered by bystanders with a maggot-infested open wound of the left lower extremity (Fig. 1). Upon initial evaluation, the patient was hypotensive and hypothermic, and laboratory workup revealed Gram-negative bacteremia with acute prerenal azotemia superimposed upon suspected chronic renal failure. The patient was diagnosed with undifferentiated shock requiring fluid resuscitation, temporary vasopressor support, and a two-week course of intravenous antibiotics.

On hospital day 14, the patient reported significant abdominal pain and experienced two episodes of acute hypotension, hypoglycemia, and unresponsiveness requiring resuscitation. A chest radiograph obtained at this time revealed a large volume of pneumoperitoneum (Fig. 2). Emergent exploratory laparotomy was performed which revealed two perforations of the transverse colon, a nonviable ascending colon, and a mass

of the sigmoid colon that was later confirmed pathologically to be adenocarcinoma. A total colectomy was performed and an end ileostomy was created.

While in the surgical intensive care unit, the patient was unable to be weaned from the ventilator and grew persistently cachectic despite the provision of adequate nutrition via both the nasogastric and parenteral routes. Ultimately, on hospital day 32, the patient was terminally extubated and expired shortly thereafter.

During the inpatient course, CT scans of the head were performed for episodes of acute encephalopathy on hospital day 2 and hospital day 28. While no intracranial abnormality was detected on either scan, the latter study was notable for a marked reduction in orbital fat and development of enophthalmos over the 26-day interval (Fig. 3). These findings were

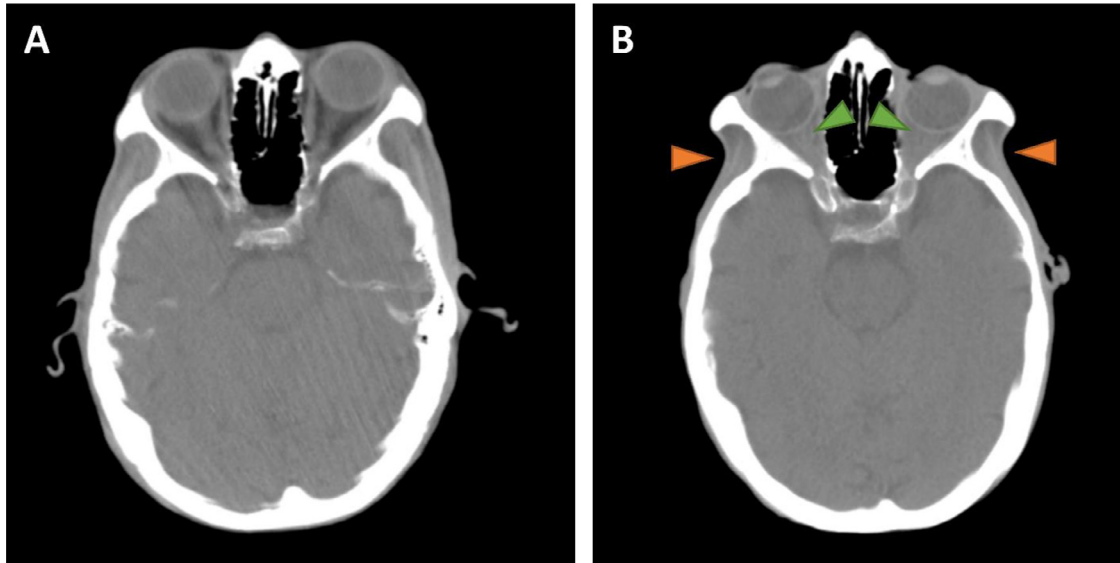


Fig. 3 – Head CT performed on hospital day 2 (A) is presented on soft-tissue window and demonstrates a normal volume of retrobulbar orbital fat, subcutaneous fat, and a normal temporalis muscle. In contrast, a head CT performed on hospital day 28 (B) following a complicated hospital course including multiple resuscitations, bowel perforation, and total colectomy reveals a marked interval reduction in orbital fat resulting in enophthalmos (green arrowheads) and significant volume loss in the temporal fossae (orange arrowheads).

interpreted as secondary to a persistent cachectic state consistent with orbital lipolysis. Additional supportive secondary findings on the second head CT examination included subcutaneous fat and temporal wasting.

Discussion

Orbital lipolysis is most commonly described in the literature as occurring in markedly emaciated patients with anorexia nervosa [1–3]. The proposed mechanism is disturbances in electrolyte and fluid balance resulting in increased lipid peroxidation and lipolysis [3,5].

Lipids are stored in adipose tissue in the form of triacylglycerols (TAGs) and may be broken down during periods of starvation to provide caloric needs for metabolism. The breakdown of TAGs results in the release of free fatty acids (FFAs) into circulation, which subsequently may be utilized as substrates for energy production by skeletal muscle and other tissues [4,6]. This process is regulated by a number of hormonal and neural signals including insulin, glucagon, and catecholamines [7–9].

In the appropriate neuroendocrine state, TAG is hydrolyzed into diacylglycerol, which subsequently is broken down into monoacylglycerol. Monoacylglycerol is then further broken down into glycerol and FFAs. Thus, the catabolism of each TAG molecule results in the liberation of one molecule of glycerol and three FFA molecules. Rising serum levels of glycerol and FFAs, an indication that lipolysis has been induced, may first be observed after approximately 24 hours of starvation [10].

Lipolysis releases preformed mediators of oxidative stress which, along with byproducts of the oxidative metabolism of

FFA, may lead to endothelial cell inflammation through the production of intracellular reactive oxygen species [11]. Accelerated production of these lipolysis products may lead to injury of the endothelium and subsequent increased permeability of blood vessel walls [5]. This process is hypothesized to underlie the diffuse enhancement typically seen on neuroimaging in patients with orbital lipolysis [3].

On CT and MR imaging, the characteristic feature of orbital lipolysis is loss of the normal retrobulbar fat. This results in enophthalmos without globe deformity. On CT, there is typically stranding of the remaining retrobulbar fat with enhancement on post contrast imaging. MRI similarly demonstrates inflammatory changes in the retrobulbar fat with loss of normal T1-weighted signal, postcontrast enhancement, and increased T2-weighted signal consistent with edema. This edema and enhancement are the imaging manifestations of the endothelial damage and vessel permeability induced by increased lipid peroxidation. The imaging appearance is characteristic, and the differential diagnosis is fairly limited, but should include scirrhous orbital metastases, typically from breast carcinoma. The clinical history and diffuse bilateral involvement are helpful in differentiating these entities.

Conclusion

The dramatic reduction in our patient's retrobulbar and subcutaneous fat volumes over such a short interval demonstrates and supports the effects of prolonged starvation with lipid peroxidation as a means of utilizing systemic energy reserves. Aside from the total colectomy, the patient had multiple risk factors for induction of a catabolic state including a

diminished capacity to care for himself, an undiagnosed malignancy, and lower extremity skin necrosis with bacteremia. As such, it is doubtful that even early initiation of supportive nutrition would have resulted in a significantly different outcome. Ultimately, the presence of lipid peroxidation and lipolysis may be used as signs of long-term undernutrition in a variety of patients ranging from the chronically debilitated to the anorexic.

Patient consent statement

This patient is now deceased; however, during his presentation, he signed conditions of admission, which at our institution state an agreement to undergo procedures and treatments including imaging examinations, an agreement to have trainees participate in patient care, and an agreement to have photographs, video, and other images used for training and education purposes. In addition, we have suppressed all personally-identifiable information from the report, including all 18 HIPAA identifiers.

REFERENCES

- [1] Demaerel P, Daele MC, De Vuysere S, Wilms G, Baert AL. Orbital fat edema in anorexia nervosa: a reversible finding. *AJNR Am J Neuroradiol* 1996;17(9):1782–4.
- [2] Okamoto K, Ito J, Ishikawa K, Sakai K, Tokiguchi S. Change in signal intensity on MRI of fat in the head of markedly emaciated patients. *Neuroradiology* 2001;43(2):134–138.
- [3] Demaerel P, Dekimpe P, Muls E, Wilms G. MRI demonstration of orbital lipolysis in anorexia nervosa. *Eur Radiol* 2002;12(Suppl 3):S4–6.
- [4] Finn PF, Dice JF. Proteolytic and lipolytic responses to starvation. *Nutrition* 2006;22(7-8):830–44.
- [5] Rutledge JC, Woo MM, Rezai AA, Curtiss LK, Goldberg JJ. Lipoprotein lipase increases lipoprotein binding to the artery wall and increases endothelial layer permeability by formation of lipolysis products. *Circ Res* 1997;80(6):819–828.
- [6] Zechner R, Strauss JG, Haemmerle G, Lass A, Zimmermann R. Lipolysis: pathway under construction. *Curr Opin Lipidol* 2005;16:333–40.
- [7] Large V, Peroni O, Letexier D, Ray H, Beylot M. Metabolism of lipids in human white adipocyte. *Diabetes Metab* 2004;30:294–309.
- [8] Spiegelman BM, Flier JS. Obesity and the regulation of energy balance. *Cell* 2001;104:531–43.
- [9] Flier JS. Obesity wars: molecular progress confronts an expanding epidemic. *Cell* 2004;116:337–50.
- [10] Horowitz JF, Coppack SW, Paramore D, Cryer PE, Zhao G, Klein S. Effect of short-term fasting on lipid kinetics in lean and obese women. *Am J Physiol* 1999;276:E278–E284.
- [11] Wang L, Gill R, Pedersen TL, Higgins LJ, Newman JW, Rutledge JC. Triglyceride-rich lipoprotein lipolysis releases neutral and oxidized FFAs that induce endothelial cell inflammation. *J Lipid Res* 2009;50(2):204–13.