

# Disseminated coccidioidomycosis mimicking cicatricial alopecia



Fiona H. Lynch, MB BCh BAO, Connor J. Maly, BS, Rashmi Unwala, MD, Janis E. Blair, MD,  
David J. DiCaudo, MD, and Aaron R. Mangold, MD  
*Scottsdale, Arizona*

**Key words:** cicatricial alopecia; coccidioidomycosis; fungal infections.

## INTRODUCTION

Coccidioidomycosis is a fungal infection that is endemic to the semiarid regions of the southwestern United States, particularly Arizona and California.<sup>1,2</sup> It is primarily a pulmonary infection, acquired via the inhalation of fungal spores. Cutaneous manifestations of coccidioidomycosis are common and can occur via 3 pathogenic mechanisms: reactive eruptions, primary cutaneous infection, and secondary dissemination to the skin.<sup>2</sup>

Reactive skin manifestations tend to occur early in the disease course and include generalized exanthem, Sweet syndrome, erythema nodosum, interstitial granulomatous dermatitis, and an erythema multiforme–like eruption.<sup>2-4</sup> Primary cutaneous infection is rare and occurs via inoculation of fungus directly into the skin from the environment. Secondary dissemination occurs via hematogenous spread from the lungs (the primary area of infection, in most cases) to other organs such as the skin, bones, and meninges. The skin is one of the most common sites of secondary dissemination. Disseminated cutaneous infection is characterized by the presence of fungal spherules in the skin. Immunosuppressed patients, as well as certain ethnic and racial groups, such as African Americans and Filipinos, have an increased propensity for severe disease and secondary dissemination.<sup>5,6</sup> Disseminated cutaneous coccidioidomycosis has a highly variable clinical and histologic appearance.<sup>5</sup> Here, we report a unique case of disseminated infection mimicking cicatricial alopecia.

## CASE REPORT

A 38-year-old white man with Crohn's disease treated with adalimumab presented to the

### Abbreviation used:

Ig: immunoglobulin

dermatology department for evaluation of an area of scalp irritation that had been present for 1 month and was at times tender and itchy. One year prior, he had been seen in the emergency department with hot and cold sweats and an erythema multiforme–like rash. A chest radiograph done at the time showed air-space opacifications suggestive of a right lower-lobe pneumonia. He was treated with a prednisone taper and hydroxyzine hydrochloride. There was no further investigation or treatment, and his symptoms quickly resolved.

On examination, there was a 1.5- to 2-cm area of adherent yellow-brown crust overlying an indurated fluctuant plaque on the vertex of the scalp without alopecia. There was associated cervical lymphadenopathy. A swab was sent for bacterial and fungal cultures, which were positive for methicillin-susceptible *Staphylococcus aureus*. He was treated for bacterial cellulitis with oral cefadroxil and 4% chlorhexidine gluconate shampoo. Despite a 17-day course of cefadroxil and the addition of topical Liquor Carbonis Detergens 20%, his scalp lesion persisted.

At the 6-month follow-up, the scalp lesion was not improved. Over the next 3 months, the patient was given oral doxycycline, topical clindamycin lotion, intralesional Kenalog (Bristol-Myers Squibb Company, Princeton, NJ), and clobetasol shampoo. The plaque continued to enlarge, areas of scarring alopecia developed, and tufts of hair were appreciated (Figs 1 and 2). A punch biopsy and tissue culture

From the Mayo Clinic Arizona, Scottsdale.

Dr Rashmi Unwala is currently affiliated with the Cleveland Clinic, Ohio.

Funding sources: None.

Conflicts of interest: None disclosed.

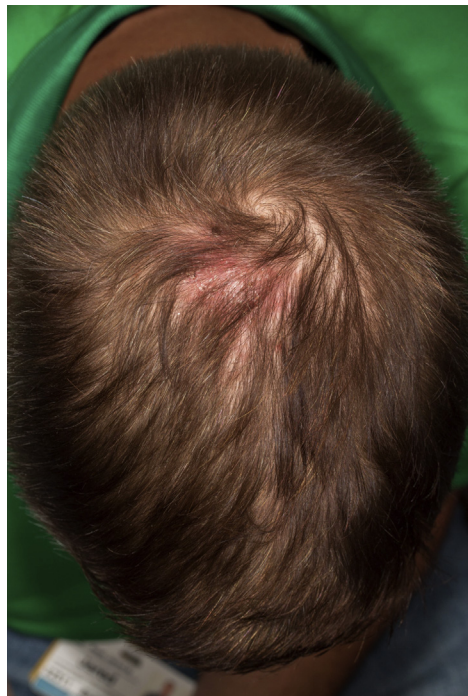Correspondence to: Fiona H. Lynch, MB BCh BAO, 5 The Maples, Clonskeagh, D14 F821, Ireland. E-mail: [fionahlynch@gmail.com](mailto:fionahlynch@gmail.com).

JAAD Case Reports 2019;5:957-9.

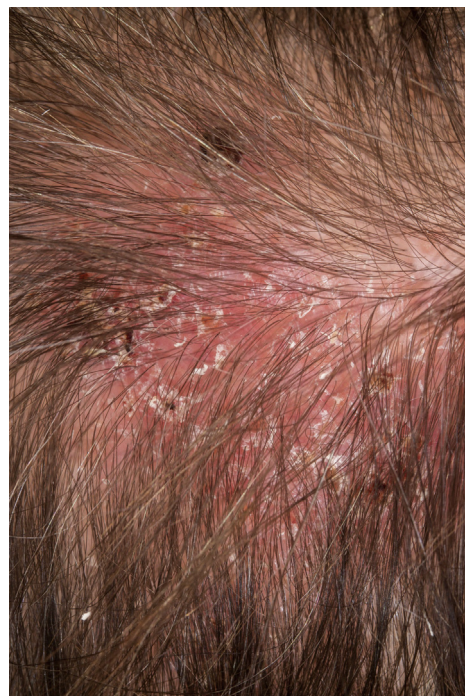2352-5126

© 2019 by the American Academy of Dermatology, Inc. Published by Elsevier, Inc. This is an open access article under the CC BY-NC-ND license (<http://creativecommons.org/licenses/by-nc-nd/4.0/>).

<https://doi.org/10.1016/j.jidcr.2019.08.024>



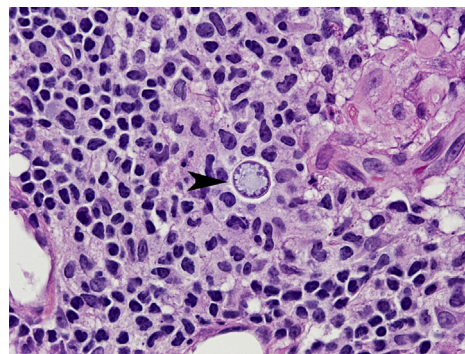
**Fig 1.** Erythematous scaly plaque on the vertex of the scalp.



**Fig 2.** Close up of erythematous scaly plaque.

for bacteria, atypical mycobacteria, and fungus were performed. His immunosuppressive therapies were temporarily stopped. Histopathology showed epidermal erosion, a dense mixed inflammatory infiltrate, and rare fungal spherules within granulomatous inflammation (Fig 3). Tissue culture results were positive for *Coccidioides posadasii/immitis* and coagulase-negative *Staphylococcus*. Mycobacterial culture result was negative. Serum *Coccidioides* immunoglobulin (Ig) G and IgM were positive by enzyme immunoassay, and *Coccidioides* antibody titer was 1:64 by complement fixation.

Computed tomography of the chest showed a 17-mm cavitating nodule in the right lower lobe with surrounding satellite lesions, consistent with pulmonary coccidioidomycosis. Computed tomography of the neck, abdomen, and pelvis did not show any other extrapulmonary disease. The patient was treated with fluconazole 400 milligrams by mouth daily. His scalp lesions markedly improved within weeks of therapy and resolved after 1 year of treatment. He restarted his biologic agent. He became intolerant to fluconazole after approximately 1 year of therapy because of cutaneous adverse effects. At this point, his *Coccidioides* antibody titer results remained positive. To increase the potency of the azole and alleviate his adverse effects, he was switched to posaconazole 300 mg daily. He continues to take this medication for the



**Fig 3.** *Coccidioides* spherule (arrowhead) surrounded by a granulomatous dermal inflammatory infiltrate (hematoxylin-eosin; original magnification,  $\times 600$ ).

prophylaxis of further disseminated infection in the setting of impaired cellular immunity due to adalimumab.

## DISCUSSION

Disseminated cutaneous coccidioidomycosis is a protean disease. In a review of 104 biopsy-proven cases, the clinical descriptors of lesions included papular, nodular, plaque, pustular, ulcerative, verrucous, vesicular, and cystic lesions that favored the head, neck, and upper portion of the torso.<sup>5</sup> Cutaneous coccidioidomycosis has been reported to mimic mycosis fungoides,<sup>7</sup> lepromatous leprosy,<sup>8</sup> cutaneous sarcoidosis,<sup>9</sup> and

tuberculosis.<sup>1</sup> To our knowledge, it has not been previously reported to clinically mimic cicatricial alopecia. Histopathologically, disseminated cutaneous coccidioidomycosis is defined by the presence of fungal spherules in the dermis, with varying degrees and types of granulomatous inflammation.<sup>5</sup> In our patient, the high degree of inflammation likely led to secondary destruction of the hair follicle and subsequent cicatricial alopecia. The differential diagnosis included infectious (bacterial, fungal, and atypical mycobacteria) and cicatricial inflammatory diseases (folliculitis decalvans, dissection cellulitis, and erosive pustular dermatosis of the scalp). Timely diagnosis of cutaneous coccidioidomycosis requires careful history taking and a high level of clinical suspicion where there is a history of travel to an endemic area. Serologic testing is useful in the diagnosis.<sup>10</sup> Positive test results for *Coccidioides* IgM and IgG are indicative of a recent or active infection, and both results usually return to negative once the infection has resolved.<sup>10</sup> By virtue of his tumor necrosis factor  $\alpha$  inhibitor, this patient had cellular immunodeficiency. Patients with cellular immunodeficiency specifically are at increased risk of disseminated coccidioidomycosis infection.<sup>11</sup> Cessation of adalimumab was therefore crucial to gaining initial control of his infection. Azoles such as fluconazole are recommended as first-line agents in the treatment of disseminated soft tissue infection.<sup>10</sup> However, they are fungistatic, not fungicidal, and latent coccidioid infection is presumed after their use. Thus, if a tumor necrosis factor  $\alpha$  inhibitor is to be restarted, azole therapy

should be continued to prevent reactivation of latent infection. Our patient continues to take posaconazole to facilitate his concomitant chronic immunosuppressive therapy.

#### REFERENCES

1. DiCaudo DJ. Coccidioidomycosis: a review and update. *J Am Acad Dermatol.* 2006;55(6):929-942.
2. DiCaudo DJ. Coccidioidomycosis. *Semin Cutan Med Surg.* 2014; 33(3):140-145.
3. DiCaudo DJ, Connolly SM. Interstitial granulomatous dermatitis associated with pulmonary coccidioidomycosis. *J Am Acad Dermatol.* 2001;45(6):840-845.
4. DiCaudo DJ, Ortiz KJ, Mengden SJ, Lim KK. Sweet syndrome (acute febrile neutrophilic dermatosis) associated with pulmonary coccidioidomycosis. *Arch Dermatol.* 2005;141(7):881-884.
5. Carpenter JB, Feldman JS, Leyva WH, DiCaudo DJ. Clinical and pathologic characteristics of disseminated cutaneous coccidioidomycosis. *J Am Acad Dermatol.* 2010;62(5):831-837.
6. Crum NF, Lederman ER, Stafford CM, Parrish JS, Wallace MR. Coccidioidomycosis: a descriptive survey of a reemerging disease. Clinical characteristics and current controversies. *Medicine (Baltimore).* 2004;83(3):149-175.
7. Crum NF. Disseminated coccidioidomycosis with cutaneous lesions clinically mimicking mycosis fungoides. *Int J Dermatol.* 2005;44(11):958-960.
8. Hobbs ER, Hempstead RW. Cutaneous coccidioidomycosis simulating lepromatous leprosy. *Int J Dermatol.* 1984;23(5): 334-336.
9. Newlon HR, Lambiase MC. Disseminated cutaneous coccidioidomycosis masquerading as lupus pernio. *Cutis.* 2010;86(1): 25-28.
10. Galgiani JN, Ampel NM, Blair JE, et al. 2016 Infectious Diseases Society of America (IDSA) clinical practice guideline for the treatment of coccidioidomycosis. *Clin Infect Dis.* 2016;63(6): e112-e146.
11. Blair JE, Wack EE, Mertz LE, Galgiani JE. Approach to management of coccidioidomycosis in patients receiving inhibitors of tumor necrosis factor- $\alpha$ . *Infect Dis Clin Pract.* 2017;25(4): 184-192.