

Access this article online

Quick Response Code:



Website:

<http://www.braincirculation.org>

DOI:

10.4103/bc.bc_8_19

Anesthetic challenges in pediatric moyamoya disease: A report of two cases

Vidhu Bhatnagar, S. N. Kulkarni, Ajay Sharma, Sandeep Basawaraj Dolla

Abstract:

Moyamoya disease (MMD), a rare cause of pediatric stroke, is a cerebrovascular occlusive disorder resulting from progressive stenosis of the distal intracranial carotid arteries and their proximal branches. In response to brain ischemia, there is the development of basal collateral vessels, which gives rise to the characteristic angiographic appearance of moyamoya (puff of smoke). If left untreated, the disease can result in overwhelming permanent neurological and cognitive deficits. Whereas MMD refers to the idiopathic form, moyamoya syndrome refers to the condition in which children with moyamoya also have a recognized clinical disorder. The classic pediatric presentation in moyamoya is recurrent transient ischemic attacks (TIAs) and/or completed/repeated ischemic strokes. Surgical revascularization, including direct and indirect techniques, remains the mainstay of treatment and has been shown to improve long-term outcome in children with MMD. Various risk factors identified for perioperative complications are as follows: history of TIAs, severity of disease, intraoperative hypotension, hypercapnia and hypovolemia, and substantial reduction in hematocrit intraoperatively. Thus, providing perianesthetic care to pediatric patients undergoing revascularization procedure for MMD is like walking a tightrope, and we present two such cases handled successfully.

Keywords:

Cerebral revascularization, intracranial hemorrhages, ischemic attack, moyamoya disease, stroke, transient

Introduction

Moyamoya disease (MMD) is a cerebrovascular arteriopathy of unknown origin characterized by progressive stenosis and eventually occlusion of the distal intracranial internal carotid arteries (ICAs), the proximal branches of the anterior cerebral artery (ACA), and the middle cerebral artery (MCA). There is a parallel development of collateral vessels from the leptomeninges as well as both the external and intracranial ICAs, so as to perfuse the ischemic brain distal to the occlusion. These dilated basal collateral vessels which arise from the intracranial

ICAs, supplying the optic nerves, pituitary gland, anterior perforated substance, dura, and other skull base structures, lead to the characteristic angiographic appearance similar to a puff of smoke.^[1] MMD was first described in the Japanese literature in 1957 by Takeuchi and Shimizu as a case of “hypoplasia of the bilateral ICAs,” and Suzuki and Takaku coined the term “moyamoya” signifying “something hazy, like a puff of cigarette smoke” to describe the angiographic appearance that would both describe and define the illness in 1969.^[1] The risk of cerebral ischemia is increased due to altered cerebral blood flow (CBF) autoregulation, and the blood pressure limits of autoregulation are unidentified in pediatric patients. The lower limit of autoregulation may vary according to the

This is an open access journal, and articles are distributed under the terms of the Creative Commons Attribution-NonCommercial-ShareAlike 4.0 License, which allows others to remix, tweak, and build upon the work non-commercially, as long as appropriate credit is given and the new creations are licensed under the identical terms.

For reprints contact: reprints@medknow.com

How to cite this article: Bhatnagar V, Kulkarni SN, Sharma A, Dolla SB. Anesthetic challenges in pediatric moyamoya disease: A report of two cases. *Brain Circ* 2020;6:47-51.

Department of
Anesthesiology and
Critical Care, INHS Asvini,
Mumbai, Maharashtra,
India

Address for correspondence:

Dr. Vidhu Bhatnagar,
Department of
Anaesthesiology and
Critical Care, INHS Asvini,
Near RC Church, Colaba,
Mumbai - 400 005,
Maharashtra, India.
E-mail: vizardvids@yahoo.co.in

Submission: 27-03-2019

Revised: 26-05-2019

Accepted: 09-07-2019

Published: 18-02-2020

severity of disease and age of the patient. Whereas MMD refers to the idiopathic form, moyamoya syndrome refers to the condition in which children with moyamoya also have a recognized clinical disorder.^[2] Children afflicted with MMD may present with transient ischemic attacks (TIAs), slow cognitive decline, headaches, dizziness, seizures, monoparesis, hemiparesis, visual impairment, sensory impairment, or even cerebral infarction. Surgical revascularization has shown to improve long-term outcome in children with MMD.^[2-4]

Perioperative ischemic complication incidence has been reported to be 5%–20% in surgical series of moyamoya patients.^[5] To add to the anguish, monitoring methods to reduce the risk of perioperative ischemia are not identified as yet, and strict adherence to the maintenance of adequate cerebral perfusion perioperatively can lead to a successful outcome. We present two pediatric cases of MMD who underwent surgical revascularization in two different sittings on both sides and had a respectable recovery leading to halt in progression of the disease and an improved quality of life.

Case Reports

Case report 1

A 13-month-old male child, weighing 8 kg, presented to the pediatric outpatient department with a history of child's gait being unstable and weakness of the right lower limb for the past 3 months. The child was diagnosed as a case of MMD on the basis of magnetic resonance imaging (MRI) of the brain and was posted for encephaloduromyosynangiosis (EDMS) plus multiple burr holes on the left side.

On preanesthetic examination (PAE), the baby's heart rate (HR) was 126/min, noninvasive blood pressure (NIBP) was 84/36 mmHg, respiratory rate (RR) was 18/min, and a room air saturation (SpO₂) was 98%. The systemic examination was within normal limits (WNL) except motor examination which revealed power of IV/V in the right lower limb (LL) and upper limb (UL). Blood and urine studies were WNL. Imaging (MRI brain with contrast and MR angiography) displayed an old small ischemic infarct involving the left parietal cortex with attenuation and narrowing of cavernous and supraclinoid ICA bilaterally as well as horizontal portion of MCA bilaterally with increased prominence and enhancement of lenticulostriate and thalamoperforating arteries bilaterally favoring a diagnosis of MMD [Figure 1]. The child was on mini aspirin since confirmation of diagnosis. The patient was accepted in the American Society of Anesthesiologists (ASA) physical grading of III, and informed consent was obtained from the parents. Preoperatively, instructions were given for nil by mouth 6 h prior for solids and

4 h prior for the mother's milk. Intravenous (iv) fluids were to be given at the rate of 48 ml/h (1.5 times the maintenance fluids) of plasmalyte to prevent dehydration. On arrival to the operating room (OR), standard monitors were applied (HR, NIBP, SpO₂, and electrocardiography [ECG]). The baby was induced with iv midazolam 0.25 mg, iv fentanyl 2.5 mcg, iv propofol 10 mg, and iv atracurium 4.0 mg and endotracheally intubated with a 4.0 size internal diameter endotracheal tube (ETT) uncuffed, fixed at 12 cm mark from incisors. A throat pack was given so as to prevent unnecessary movement of ETT, while the skull was being handled by a surgeon. Postinduction, invasive monitoring (central venous access of the right-sided internal jugular vein with 2.5 Fr double-lumen central venous catheter [CVC] and right radial artery cannulation with 22G intracath) was instituted under ultrasonography (USG) guidance. Temperature monitoring and urine output monitoring were also added. General anesthesia (GA) was maintained with O₂/air/sevoflurane (50:50: minimum alveolar concentration [MAC] 0.6). The surgery went on for 3 h, and intraoperatively, iv propofol 50 mg in divided doses, iv fentanyl 5 + 5 mcg, and atracurium 7.5 mg were administered. Antiepileptic drug and iv 120 mg of paracetamol (PCM) were given before closure started. Surgery was uneventful. On completion of surgery, child was extubated after adequate recovery regained and shifted to pediatric intensive care unit (PICU) for monitoring. Postsurgery, no new neurological deficit was observed; the motor power in the right UL and LL was the same as presurgery status. The child was operated on the other side after an interval of 3 months and had uneventful surgery with a complete recovery. Postsurgery, the child started walking unaided and nutritional status also improved. Blood loss in both surgeries was <100 ml.

Case report 2

A 7-year-old male child, weighing 22 kg, a diagnosed case of MMD on the basis of MRI brain, was posted for EDMS plus multiple burr holes on the left side. On PAE, the patient's HR was 92/min, NIBP was 98/48 mmHg, and RR was 16/min with a room air SpO₂ of 99%. Systemic examination was WNL except that the motor power of the left UL and LL was IV/V, whereas on the right UL and LL, it was III/V. The parents gave a history of multiple strokes since the age of 4 years. All blood and urine reports were WNL; MRI brain revealed areas of altered signal intensity with restriction of diffusion involving the right temporal, occipital, parietal, and posterior frontal regions suggestive of ischemia; chronic lacunar infarcts were present in the left frontal and right occipital white matter. MR angiography of the brain vessels demonstrated supraclinoid segment of both ICAs revealing severe stenosis distal to the origin of ophthalmic arteries. The blood flow,

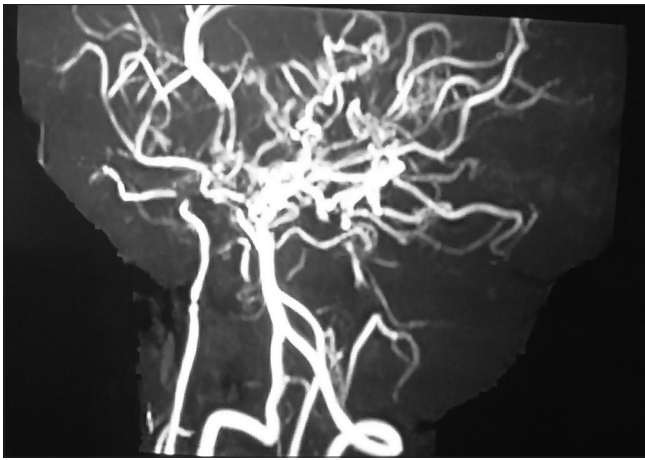


Figure 1: Cerebral angiography displaying attenuation and narrowing of cavernous and supraclinoid internal carotid artery bilaterally. There is increased prominence and enhancement of lenticulostriate and thalamo-perforating arteries bilaterally, which have developed for collateral circulation

distal to the supraclinoid segment of both ICAs was being supplied through collaterals from posterior communicating arteries to the region of ACA and MCA territories. Multiple lenticulostriate, thalamoperforating, leptomeningeal, and dural collaterals were noted along the circle of Willis in the suprasellar, interpeduncular, ambient, and quadrigeminal cisterns extending into thalami and lentiform nuclei bilaterally [Figure 2]. The child was on aspirin for the past 3 years. Child was accepted in ASA physical grading III. Informed consent was obtained from the parents. Preoperatively, instructions were given for nil by mouth 6 h prior for solids and iv fluids 90 ml/h (1.5 times the maintenance fluids) of plasmalyte, during the night to be administered so as to prevent dehydration. On arrival to OR, standard monitors were applied (HR, NIBP, SpO₂, and ECG). The child was induced with iv midazolam 0.5 mg, iv fentanyl 20 mcg, iv propofol 20 mg, and iv atracurium 10.0 mg and endotracheally intubated with cuffed ETT 6.0 size internal diameter, fixed at 17 cm mark from incisors. Invasive monitoring (4.5 Fr triple-lumen CVC inserted in the right internal jugular vein and fixed at 9 cm mark and right radial artery cannulation with 22G intracath) was instituted under USG guidance. Temperature monitoring was added, and the patient catheterized for urine output monitoring. GA was maintained with O₂/air/sevoflurane (50:50: MAC 0.6). The surgery went on for 3 h, and intraoperatively, iv propofol 50 mg in divided doses, iv fentanyl 50 mcg, iv mannitol 20 gms, and atracurium 10 mg were administered. Antiepileptic drug and iv 330 mg of PCM were given before closure started. Blood loss was < 100 ml, and urine output was 250 ml. Surgery was uneventful, and postclosure, the patient was reversed and extubated after adequate recovery and shifted to PICU. The patient had a repeat incident of stroke involving the left side 1 month postsurgery. He was taken up for EDMS plus multiple burr holes on

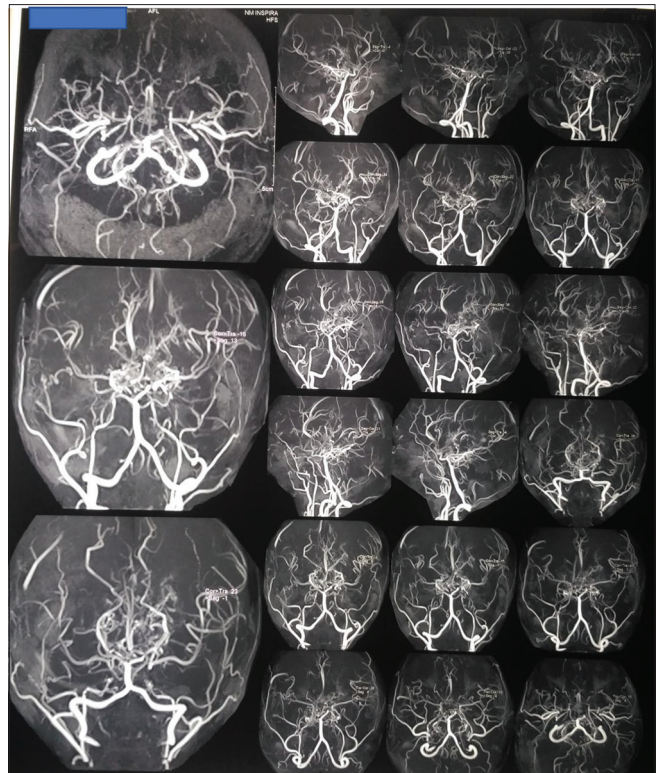


Figure 2: Surgery: encephaloduromyosynangiosis plus multiple burr holes on the left side (patient 1)

the right side after 1 month of the stroke. Surgery on the right side was uneventful, and recovery was good. Physiotherapy enabled the child to start walking on his own within 2 months after the second surgery.

Discussion

Initially, MMD was considered to be restricted to ethnic race of Japanese, but as understanding into pathophysiology and etiology increased, a varied number of cases were discovered worldwide. More than 6,000 cases have been reported; although majority are from Japan, cases from Korea, China, India, and the United States have also been added to the list.^[6-8] Females are affected more than males, and familial occurrence accounts for about 15% of patients. There is bimodal presentation of MMD: pediatric age group and fourth decade of life. Pediatric MMD frequently presents with cerebral ischemia (80%).^[6,7] There is an alteration in CBF autoregulation in MMD patients, thereby making them prone to ischemic episodes. However, diagnosis of TIAs becomes difficult in small children due to undeveloped verbal skills. Crying, blowing, or hyperventilation may induce hypocapnic vasoconstriction or vasospasm in an already compromised cerebral circulation leading to ischemic episodes.^[8,9] MMD is characterized by unilateral or bilateral stenosis of the intracranial segment of ICA and the proximal parts of ACA or MCA. As a response to ischemia and hypoxia, leptomeningeal,

thalamoperforating, dural, and parenchymal collaterals develop, and the appearance on MRI angiography seems like “a puff of smoke.”^[1] Sickle cell anemia, neurofibromatosis-1, Down syndrome, congenital heart defects, antiphospholipid syndrome, renal artery stenosis, and thyroiditis may be associated with MMD.^[2] Both our patients presented with weakness of limbs owing to ischemia and/or repeated strokes. Family history was negative for seizure disorder or chronic medical condition including sickle cell disease or trait and neurofibromatosis in both the children.

The risk factors for ischemic perioperative complications could be a history of TIAs, previous stroke/s, severity of disease, intraoperative hypotension, hypovolemia, significant reduction in hematocrit or increase in viscosity due to hemoconcentration, and intraoperative hypo- or hypercapnia.^[2-4] Essentially, perioperative management of MMD in pediatric patients is an art of balancing the optimal anesthetic state with the surgical stress and provision of a calm, relaxed patient postoperatively with adequate postoperative analgesia. Thus, a fine balance to maintain normoxia, normoventilation, normocarbia, normothermia, and normovolemia (5N) seems to be extremely important to prevent any ischemic episode perioperatively in children.^[10,11]

Revascularization procedures, direct and indirect, are currently performed to increase the perfusion to the hypoxic brain. Improvement in symptoms and positive angiographic follow-ups in all age groups point toward favorable outcomes postsurgery.^[12] Pediatric cases usually benefit from indirect revascularization procedures. There is a paucity of guidelines for

perianesthetic management of children with MMD, and institutes follow their own guidelines. In our institute, we follow the following steps: a thorough PAE is performed; preoperative hydration is maintained; children are befriended in prior preoperative settings as an attempt to prevent crying, coughing, or hyperventilation and they are accompanied by a parent while taking them inside the OR; and titrated sedation is used. Intraoperatively a strict balance of fluid intake and output is maintained along with normocarbia and normothermia. Optimal perioperative analgesia was instituted (opioid and PCM iv). The burr hole site was infiltrated with local anesthetic, prior to extubation.

Both the children went for indirect revascularization surgery in two sittings, and an uneventful recovery was seen each time [Figures 3 and 4]. The younger child did not suffer from any other neurological deficit postfirst surgery and had a beautiful recovery after both the surgeries as seen on 6-month follow-up. The elder child had a recurrence of stroke after the first surgery, but the recovery was uneventful postsecond surgery. Good physiotherapy allowed a decent recovery in the power grades giving a good quality of life postsurgery.

Conclusion

Early diagnosis of MMD and optimal intervention changes the prognosis, life expectancy, and quality of life in pediatric patients. Cerebral angiography is the gold standard for diagnosing MMD. There seems to be no definitive medical treatment to reverse or stabilize the course of MMD. However, both direct and indirect approaches of cerebral revascularization give good recovery. A tight balance between adequate anesthetic state and surgical stress intraoperatively and a good postoperative analgesic regimen increase the chances of successful postoperative recovery. There is a requirement

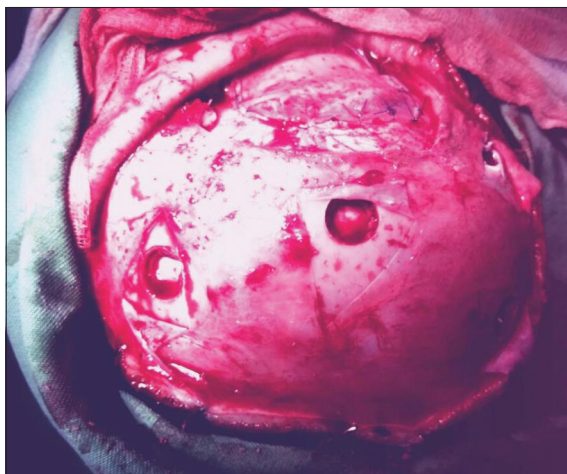


Figure 3: Magnetic resonance angiography of the brain vessels demonstrating supraclinoid segment of both internal carotid arteries with severe stenosis distal to the origin of ophthalmic arteries; flow distal to the supraclinoid segment of both internal carotid artery being supplied through posterior communicating arteries bilaterally to the anterior cerebral artery and middle cerebral arteries. Multiple collaterals are noted along the circle of Willis in suprasellar, interpeduncular, ambient, and quadrigeminal cisterns extending into thalami and lentiform nuclei bilaterally

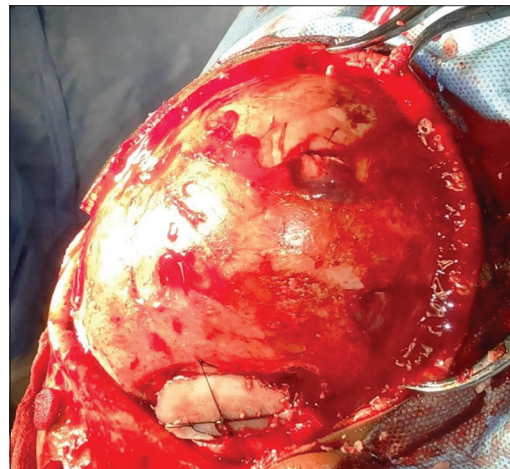


Figure 4: Surgery: encephalodurosynangiosis plus multiple burr holes on the left side (patient 2)

of understanding the pathophysiology and charting a good perioperative plan at institutional level, keeping in view paucity of guidelines for the management of pediatric patients with MMD.

Declaration of patient consent

The authors certify that they have obtained all appropriate patient consent forms. In the form the patient(s) has/have given his/her/their consent for his/her/their images and other clinical information to be reported in the journal. The patients understand that their names and initials will not be published and due efforts will be made to conceal their identity, but anonymity cannot be guaranteed.

Financial support and sponsorship

Nil.

Conflicts of interest

There are no conflicts of interest.

References

1. Suzuki J, Takaku A. Cerebrovascular "moyamoya" disease. Disease showing abnormal net-like vessels in base of brain. *Arch Neurol* 1969;20:288-99.
2. Gosalakal JA. Moyamoya disease: A review. *Neurol India* 2002;50:6-10.
3. Lehman R, Mink J. Altered mental status. *Clin Pediatr Emerg Med* 2008;9:68-75.
4. Hogan AM, Kirkham FJ, Isaacs EB, Wade AM, Vargha-Khadem F. Intellectual decline in children with moyamoya and sickle cell anaemia. *Dev Med Child Neurol* 2005;47:824-9.
5. Sawant P, Sharma S, Rangwala U. Anaesthetic management of children with Moya Moya disease. *Pediatr Anesth Crit Care J* 2015;3:61-5.
6. Khan N, Schuknecht B, Boltshauser E, Capone A, Buck A, Imhof HG, *et al.* Moyamoya disease and moyamoya syndrome: Experience in Europe; choice of revascularisation procedures. *Acta Neurochir (Wien)* 2003;145:1061-71.
7. Hallemeier CL, Rich KM, Grubb RL Jr., Chicoine MR, Moran CJ, Cross DT 3rd, *et al.* Clinical features and outcome in North American adults with Moyamoya phenomenon. *Stroke* 2006;37:1490-6.
8. Han DH, Kwon OK, Byun BJ, Choi BY, Choi CW, Choi JU, *et al.* A co-operative study: Clinical characteristics of 334 Korean patients with moyamoya disease treated at neurosurgical institutes (1976-1994). The Korean Society for Cerebrovascular Disease. *Acta Neurochir (Wien)* 2000;142:1263-73.
9. Asumal KB, Akhtar N, Syed NA, Shafiqat S, Baig SM. Moyamoya disease: An elusive diagnosis. *J Pak Med Assoc* 2003;53:160-2.
10. Houkin K, Kuroda S, Ishikawa T, Abe H. Neovascularization (angiogenesis) after revascularization in moyamoya disease. Which technique is most useful for moyamoya disease? *Acta Neurochir (Wien)* 2000;142:269-76.
11. Kim SK, Seol HJ, Cho BK, Hwang YS, Lee DS, Wang KC. Moyamoya disease among young patients: Its aggressive clinical course and the role of active surgical treatment. *Neurosurgery* 2004;54:840-4.
12. Goda M, Isono M, Ishii K, Kamida T, Abe T, Kobayashi H. Long-term effects of indirect bypass surgery on collateral vessel formation in pediatric moyamoya disease. *J Neurosurg* 2004;100:156-62.