



Case report

Prosthetic valve endocarditis caused by *Candida lusitanae*, an uncommon pathogen: a case report

Ross G Michel^{1*}, Gary T Kinasewitz¹, Douglas A Drevets², Jeremy H Levin¹ and Douglas W Warden³

Address: ¹Division of Pulmonary/Critical Care Medicine and Infectious Diseases, University of Oklahoma Health Sciences Center, Oklahoma City, Oklahoma, USA, ²Division of Infectious Diseases, University of Oklahoma Health Sciences Center, Oklahoma City, Oklahoma, USA and ³Department of Pathology, University of Oklahoma Health Sciences Center, Oklahoma City, Oklahoma, USA

Email: RGM - Ross-Michel@ouhsc.edu; GTK - Gary-Kinasewitz@ouhsc.edu; DAD - Douglas-Drevets@ouhsc.edu; JHL - Jeremy-Levin@ouhsc.edu; DWW - Douglas-Warden@ouhsc.edu

* Corresponding author

Published: 14 May 2009

Received: 12 August 2008

Journal of Medical Case Reports 2009, 3:7611 doi: 10.1186/1752-1947-3-7611

Accepted: 22 January 2009

This article is available from: <http://jmedicalcasereports.com/jmedicalcasereports/article/view/7611>

© 2009 Michel et al; licensee Cases Network Ltd.

This is an Open Access article distributed under the terms of the Creative Commons Attribution License (<http://creativecommons.org/licenses/by/3.0>), which permits unrestricted use, distribution, and reproduction in any medium, provided the original work is properly cited.

Abstract

Introduction: *Candida lusitanae* was originally described as a human pathogen in 1979 and typically affects immunocompromised patients.

Case presentation: We describe a case of prosthetic valve endocarditis with *Candida lusitanae* in an immunocompetent 62-year-old woman following aortic valve replacement. *In vitro* testing demonstrated that our isolate was sensitive to amphotericin B, caspofungin and fluconazole.

Conclusion: The infection was lethal despite aggressive medical and surgical management and sterilization of blood cultures. The outcome of our case illustrates the need to recognize *Candida lusitanae* fungemia as a life-threatening infection in a patient with a prosthetic aortic valve.

Introduction

Candida species are the most frequent causes of fungal endocarditis. Mortality from *Candida* endocarditis has been reported at a rate of 50-80% [1]. *Candida albicans* is the most frequently isolated species, followed by *C. parapsilosis*, *C. glabrata* and *C. tropicalis*. *C. lusitanae*, originally described as a human pathogen in 1979, typically affects immunocompromised patients and accounts for less than 5% of all invasive *Candida* infections [2,3]. Infections including meningitis, osteomyelitis and peritonitis have been reported, but the most common presentation of this pathogen is fungemia in patients undergoing chemotherapy

for cancer [4-6]. Prosthetic valve endocarditis with this organism has been described only once previously [7]. Although resistance to amphotericin B has been reported, a recent susceptibility study has shown that the majority of *C. lusitanae* isolates are flucytosine resistant and amphotericin-B susceptible [8]. In contrast, *in vitro* testing of the isolate in this case demonstrated sensitivity to amphotericin B, caspofungin and fluconazole.

Case presentation

A 62-year-old Caucasian woman presented with a two-month history of intermittent fever. Her past medical

Table 1. MICs and minimum fungicidal concentrations for *Candida lusitanae* isolate from May 2005

Agent	Parameter, value (mcg/mL)
Amphotericin B	MIC 0.50
	MFC 0.50
Caspofungin	MIC 0.06
	MFC ND
Fluconazole	MIC 0.25
	MFC ND

Note: Susceptibility of blood culture isolate to Caspofungin performed by the Fungus Testing Lab, UTHSC, San Antonio, TX. All other susceptibilities of blood culture isolate were determined by Microbiology Laboratory at OU Medical Center, Oklahoma City, OK.

MFC = minimum fungicidal concentration. **ND** = Not done.

history included hypertension, dyslipidemia, coronary artery disease and mild chronic kidney disease. She was found to have *Enterococcus faecalis* endocarditis of her native, bicuspid, aortic valve. She was treated with vancomycin, gentamicin and penicillin and subsequently underwent aortic valve replacement (AVR) with a Saint Jude valve in October of 2004. Her postoperative course was complicated by evacuation of a mediastinal hematoma, splenectomy and a partial colectomy with diverting colostomy for hemorrhagic colitis. The patient had been discharged and re-admitted multiple times and was ultimately transferred to the Oklahoma University Medical Center in May 2005.

Upon transfer, the patient complained of dyspnea, orthopnea and lower-extremity swelling. She was afebrile and hemodynamically stable. Her physical examination revealed jugular venous distention, a III/VI systolic murmur in the right second intercostal space, and bilateral lower-extremity edema to the knees. No peripheral stigmata of endocarditis were identified.

Nine blood cultures obtained over a five-day period were positive for *Candida lusitanae*. Susceptibility testing was performed on the initial isolate only and revealed sensitivity to amphotericin B, caspofungin and fluconazole (Table 1). Transesophageal echocardiography revealed multiple vegetations on a partially dehiscent mechanical aortic valve (Figure 1) with severe aortic valvular regurgitation and a left ventricular ejection fraction of 50% (Figure 2). Therapy with caspofungin was initiated prior to obtaining results of susceptibility testing on the initial isolate and was continued based on the minimal inhibitory concentration (MIC). The patient eventually underwent repeat AVR with coronary artery bypass grafting. Vegetations were noted on her removed prosthetic valve (Figures 3 and 4). Her post-operative course was complicated by a chest hematoma which was evacuated. Despite eventual clearance of her fungemia, the patient died from multi-organ failure in June 2005.

Discussion

It remains unknown whether the source of our patient's fungemia was her abdominal surgery or a central venous catheter infection. Transesophageal echocardiography was helpful in identifying prosthetic valve infection and dysfunction. MIC testing of the initial fungal isolate demonstrated susceptibility to multiple antifungals. Potential biofilm formation on the prosthetic valve could have resulted in a discrepancy between the MIC derived from the blood isolate and the isolate at the site of infection, although the latter was not submitted for testing. Aggressive surgical management and antifungal treatment led to clearance of our patient's fungemia. Nevertheless, the infection resulted in a lethal outcome as in the previously described case [7]. The shared outcome of our case with that of the previous case clearly illustrates

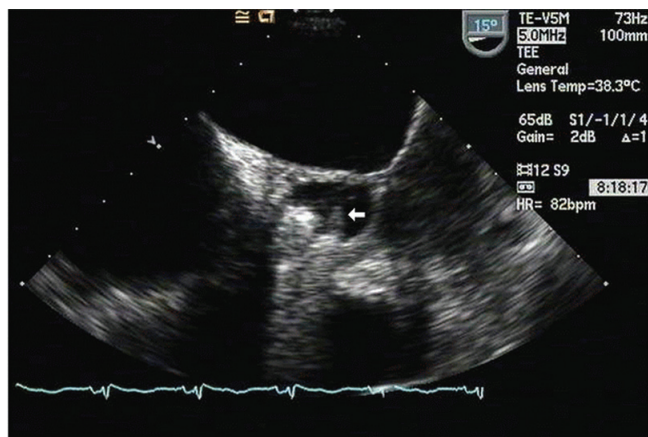


Figure 1. Trans-esophageal echocardiographic image of prosthetic aortic valve vegetations. White arrow indicates largest fungal vegetation identified in this case.

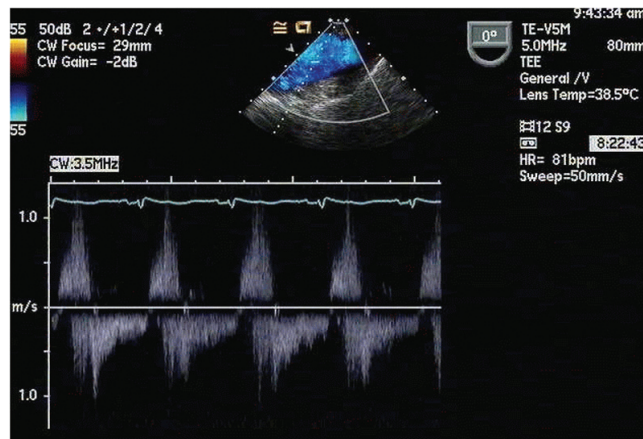


Figure 2. Infected prosthetic aortic valve regurgitation. Trans-esophageal echocardiography was helpful in identification of the prosthetic valve infection and dysfunction.

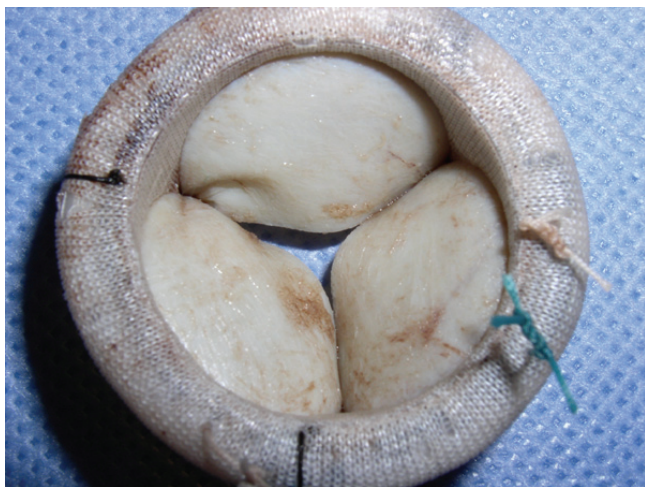

Figure 3. Infected prosthetic aortic valve. Notice the irregularities on the leaflet surfaces of the removed prosthetic valve.

the need to recognize *Candida lusitanae* fungemia as a life-threatening infection in a patient with a prosthetic aortic valve.

Conclusion

We describe a case of prosthetic valve endocarditis with *Candida lusitanae* following AVR in an immunocompetent patient. To our knowledge, this is only the second reported case of prosthetic valve endocarditis due to this uncommon *Candida* species. *In vitro* testing demonstrated that our isolate was sensitive to amphotericin B, caspofungin



Figure 4. Prosthetic aortic valve vegetation. Black arrow indicates a vegetation on the removed prosthetic valve.

and fluconazole. As in the previously described case, this infection was lethal despite aggressive medical and surgical management and sterilization of blood cultures.

Consent

Written informed consent was obtained from the patient's next-of-kin for publication of this case report and accompanying images. A copy of the written consent is available for review by the Editor-in-Chief of this journal.

Competing interests

The authors declare that they have no competing interests.

Author's contributions

All authors have made substantial contributions to the case presentation and discussion, have been involved in drafting the manuscript or revising it critically for important intellectual content and have given final approval of the version to be published.

References

1. Benjamin DK Jr, Miro JM, Hoen B, Steinbach WJ, Fowler VG Jr, Olaison L, Habib G, Abrutyn E, Perfect J, Zass A, Corey GR, Eykyn S, Thuny F, Jimenez-Exposito MJ, the Ice-md Study Group: **Candida Endocarditis: Contemporary Cases from the International Collaboration of Infectious Endocarditis Merged Database.** *Scand J Infect Dis* 2004, **36**:453-455.
2. Pappagianis D, Collins MS, Hector R, Remington J: **Development of Resistance to Amphotericin B in *Candida lusitanae* infecting a human.** *Antimicrob Agents Chemother* 1979, **16**:123-126.
3. Ostrosky-Zeichner L, Pappas P: **Invasive Candidiasis in the intensive care unit.** *Crit Care Med* 2006, **34**(3):857-862.
4. Hadfield TL, Smith MB, Winn RE, Rinaldi MG, Guerra C: **Mycoses caused by *Candida lusitanae*.** *Rev Infect Dis* 1987, **9**:1006-1012.
5. Blinkhorn RJ, Adelstein D, Spagnuolo PJ: **Emergence of a New Opportunistic Pathogen, *Candida lusitanae*.** *J Clin Microbiol* 1989, **27**:236-240.
6. Hawkins JM, Baddour LM: ***Candida lusitanae* Infections in the Era of Fluconazole Availability.** *Clin Infect Dis* 2003, **36**:e14-e18.
7. Wendt B, Hagland L, Razavi A, Rath R: ***Candida lusitanae*: an uncommon cause of prosthetic valve endocarditis.** *Clin Infect Dis* 1998, **26**:769-770.
8. Favel A, Michel-Nguyen A, Datry A, Challier S, Leclerc F, Chastin C, Fallague K, Regli P: **Susceptibility of clinical isolates of *Candida lusitanae* to five systemic antifungal agents.** *J Antimicrob Chemother* 2004, **53**:526-529.