

THORACOLUMBAR BURST FRACTURE: LOAD SHARING CLASSIFICATION AND POSTERIOR INSTRUMENTATION FAILURE

Osmar Avanzi¹, Elcio Landim², Robert Meves³, Maria Fernanda Caffaro⁴, Felipe de Albuquerque Araujo Luyten⁵, Antonio Alexandre Faria⁵

ABSTRACT

Objectives: To assess the relationship between sagittal collapse, posterior instrumentation failure and the McCormack classification among patients with thoracolumbar burst fractures who had undergone posterior arthrodesis more than one level above and one level below the fracture. *Methods:* This was a retrospective review based on the medical records and radiographs of 26 patients who underwent operations between January 1990 and December 2006. The parameters assessed were: worsening of kyphosis (Cobb), neurological dysfunction (Frankel) and

failure of surgical treatment (implant breakage or loosening). *Results:* No relationship was found between sagittal collapse and the scoring in the McCormack classification ($r = 0.221$; $P = 0.322$). There was also no relationship between failure of the posterior implant and the scoring in this classification ($p = 0.85$). *Conclusion:* Our findings suggest that this classification is not applicable to patients who underwent arthrodesis more than one level above and one level below the fracture.

Keywords – Spinal fractures; Thoracic vertebrae; Lumbar vertebrae; Treatment outcome; Human; Weight-bearing

INTRODUCTION

Thoracolumbar fracture is the most common skeletal injury of the axial skeleton and accounts for around 90% of all spinal fractures^(1,2). Because of the rigidity of the costovertebral joints of the thoracic spine, the fulcrum of movement at the time of the trauma is in the thoracolumbar segment of the spine, which is where the fractures occur in the great majority of cases. Neurological symptoms may affect up to 40% of the patients, thereby explaining the high morbidity associated with these lesions⁽¹³⁾. In around 50% of these patients, these injuries result from falling from a height, while 45% are due to traffic accidents and 5% are caused by direct trauma⁽⁴⁾.

Several classifications in the literature describe the types of fracture at the thoracolumbar transition^(5,18). Holdsworth⁽⁶⁾ and Denis⁽¹¹⁾ published a classification of thoracolumbar fractures based on columns. Burst fractures characteristically present skeletal injury in the anterior and middle column, which from the bone point of view, correspond to the vertebral body. Typically, axial tomography shows a fragment of the vertebral body that has migrated into the vertebral canal⁽¹²⁾.

McCormack *et al*⁽¹⁷⁾ developed the system known as the load sharing classification, which indicates the severity of skeletal injury represented by the fracture of the vertebral body, according to the distance between the fragments of the vertebral body, the degree of kyphosis correction following surgery via the posterior route and

1 – PhD. Adjunct Professor in the Department of Orthopedics and Traumatology, School of Medical Sciences, Santa Casa de São Paulo.

2 – Senior Consultant in the Spine Group, Department of Orthopedics and Traumatology, School of Medical Sciences, Santa Casa de São Paulo.

3 – PhD. Assistant Professor in the Department of Orthopedics and Traumatology, School of Medical Sciences, Santa Casa de São Paulo.

4 – PhD. Professor and Instructor in the Department of Orthopedics and Traumatology, School of Medical Sciences, Santa Casa de São Paulo.

5 – Resident Physicians in the Department of Orthopedics and Traumatology, School of Medical Sciences, Santa Casa de São Paulo.

Work performed in the Department of Orthopedics and Traumatology, School of Medical Sciences, Santa Casa de São Paulo (DOT-FCMSCMSP) (Director: Prof. Dr. Osmar Avanzi).

Correspondence: Robert Meves, Rua Dr. Cesário Mota Júnior 112, 01277-900 São Paulo, SP, Brazil – E-mail: robertmeves@hotmail.com

We declare that there is no conflict of interests in this article

the collapse of the vertebral body in the sagittal plane. These authors considered that the greater the scoring for the fracture was, the greater the risk of failure of the posterior implant following short arthrodesis (i.e. one level above and one level below the fracture) would be, with the use of pedicle screws. For this reason, they also indicated anterior arthrodesis in patients with scores greater than or equal to seven.

In practice, many surgeons intuitively advocate carrying out anterior arthrodesis subsequent to posterior arthrodesis when there is major skeletal injury to the vertebral body, even after longer instrumentation. However, there is a lack of studies analyzing the relationship between the classification of McCormack *et al*⁽¹⁷⁾ and sagittal collapse in patients who have undergone surgical treatment involving longer levels of arthrodesis (i.e. greater than one level above and one level below the fractured vertebra)^(4,19).

In this light, we conducted a retrospective study to investigate the applicability of the classification of McCormack *et al*⁽¹⁷⁾, following long posterior arthrodesis in such patients.

METHODS

After approval by the Ethics Committee for Research on Human Beings of our institution, a retrospective study was conducted based on data from the medical files, radiographs and axial tomography relating to patients with recent (< 10 days) thoracolumbar burst fractures, as defined by Denis^(11,12), who had undergone operations between January 1990 and December 2006 by means of metallic instrumentation and posterior arthrodesis. We included patients with burst fractures located in the thoracolumbar region that involved only one level, with follow-up greater than six months. We excluded cases of fractures caused by firearms or pathological conditions, and those treated conservatively. The severity of the skeletal injuries was scored in accordance with McCormack *et al*⁽¹⁷⁾ (Table 1).

Table 1 – McCormack classification (load sharing)

Score	1 point	2 points	3 points
Sagittal collapse	30%	>30%	60%
Dislocation	1 mm	2 mm	> 2 mm
Correction	3 degrees	9 degrees	10 degrees
Total	3 points	6 points	9 points

Source: McCormack T, Karakovic E, Gaines RW. The load sharing classification of spine fractures. *Spine* 1994;19(15):1741-4.

Radiographic measurements of kyphosis before and after the operation were made using the Ulmar method⁽²⁰⁾, and measurements of the narrowing of the vertebral canal were made using the mean sagittal diameter⁽¹³⁾. The severity of the neurological dysfunction was categorized using the Frankel scale⁽²¹⁾, as type A (absence of muscle strength and sensitivity), type B (sensitivity preserved), type C (sensitivity preserved with muscle strength that was non-functional for the patient), type D (sensitivity preserved with functional muscle strength) and type E (normal neurological examination).

The statistical analysis was performed based on the SPSS software (Statistical Package for the Social Sciences), version 13.0. The significance level of 5% (0.050) was used to apply the statistical tests.

RESULTS

Twenty-two patients (13 males and 9 females) fulfilled the inclusion criteria for this study. Seven patients presented an initial neurological deficit: two with Frankel C, three with D, one with B and one with A.

The level most affected by fractures was L1, in 12 patients, followed by L2 in four, L3 in three, T12 in two and L4 in one. The post-traumatic kyphosis ranged from 3° to 37° (mean of 17° ± 8.2) before the operation.

The percentages to which the canal was affected ranged from 9 to 70% (mean of 42.2% ± 14.5). Twelve patients underwent hybrid instrumentation with hooks and screws, three with pedicle screws and seven with segmental instrumentation (Hartchill or Harri-Luque). Instrumentation failure occurred in two patients who underwent two levels of arthrodesis above and one level below the fracture (Box 1).

Box 1 – Distribution of the patients according to the arthrodesis levels above and below the fracture and cases of posterior instrumentation failure

Type of arthrodesis	Number of patients	Implant failure
2 and 1	8	2
2 and 2	6	0
3 and 2	8	0
Total	22	2

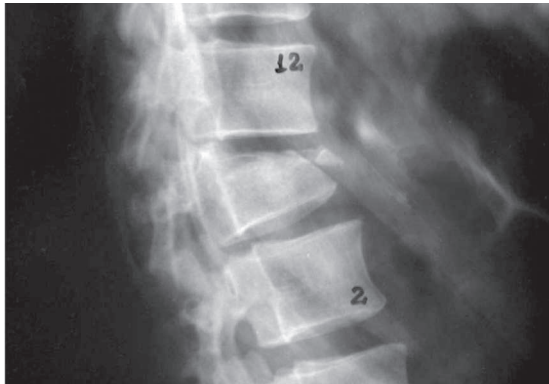Source: S.A.M.E.

Radiographic consolidation of the arthrodesis occurred in all the patients by the end of the follow-up, even in those with implant failure (Figures 1 to 3). Regarding the neurological state, there was an improvement of at least one grade on the Frankel scale in five patients (Box 2).

Box 2 – Patient distribution according to Frankel

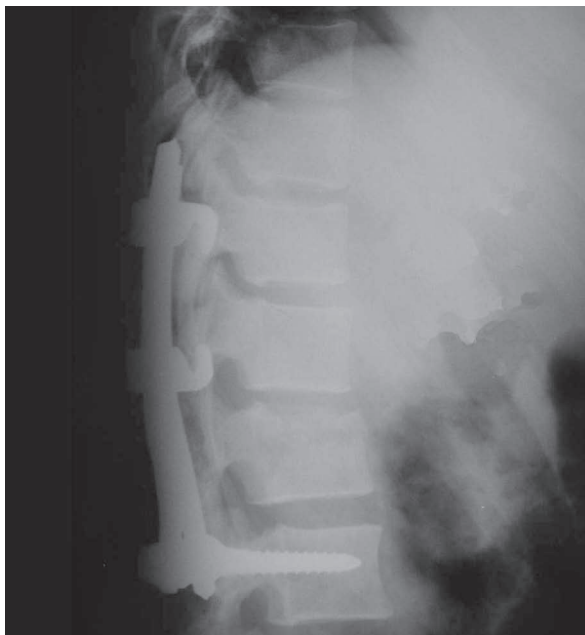Frankel	A	B	C	D	E
A		1			
B			1		
C				2	
D				2	1
E					15

Source: S.A.M.E.



Source: S.A.M.E.

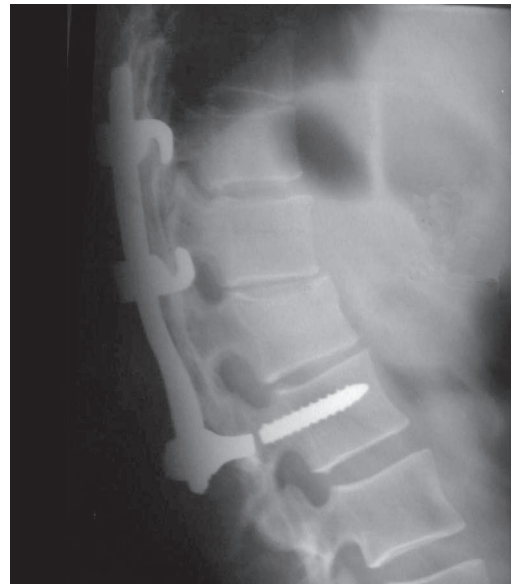
Figure 1 – Initial radiograph (lateral view) on patient with L1 burst fracture who was neurologically intact



Source: S.A.M.E.

Figure 2 – Radiograph from immediate postoperative period

We observed that there was no association between posterior instrumentation failure and the mean score in the McCormack classification (Table 2).



Source: S.A.M.E.

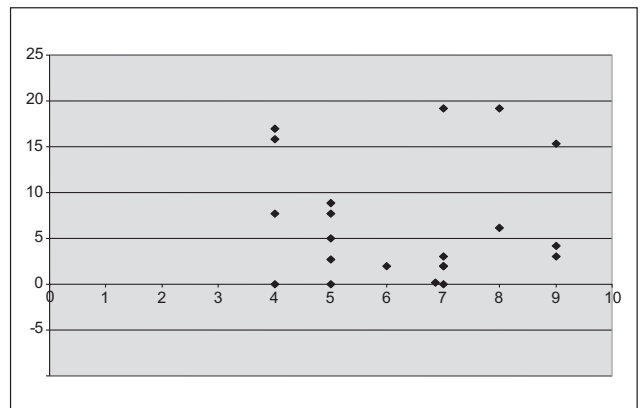
Figure 3 – Note the implant failure, causing pain at the protuberance of the implant

Table 2 – Association between sagittal collapse and McCormack classification

	Implant failure	n	Mean	Standard deviation	Significance (p)
Score	yes	2	4.5	0.71	0.85
	no	20	6.7	1.63	

Source: S.A.M.E. Mann-Whitney test.

We also observe that there was no correlation between sagittal collapse and the scoring in the McCormack classification (Figure 4).



Source: S.A.M.E. Spearman correlation. R = 0.221; P = 0.322.

Figure 4 – Correlation between the scoring in the McCormack classification and sagittal collapse

DISCUSSION

Thoracolumbar burst fractures are often seen in patients who have suffered traffic accidents or falls from a height. In developing countries, falls from a height still account for the great majority of cases^(4,11,2224). Demographic data reported in several studies in the literature have indicated the individuals who typically have such injuries: young men with fractures of the thoracolumbar spine^(5,13,2527). Post-traumatic kyphosis with or without neurological dysfunction signifies significant morbidity for the patient and a socioeconomic repercussion for society^(1,10).

Several classifications have been described in the literature, with the aims of categorizing these fractures in greater detail, defining instability or helping to choose the best treatment option⁽¹³¹⁶⁾. However, Holdsworth^(6,7) and Denis⁽¹²⁾ explained the basic characteristic of these fractures: comminution of the vertebral body with bone fragments that have migrated into the vertebral canal. This image, which is seen through axial tomography, is the classic appearance considered for analysis on the clinical and radiographic outcomes in the great majority of the published papers^(11,12,28).

The classification of McCormack *et al*⁽¹⁷⁾ indicates the severity of the skeletal injury according to the severity of the wedging and comminution of the vertebral body, with the aim of predicting cases of instrumentation failure subsequent to posterior short arthrodesis that included one vertebral level above and one level below the fractured vertebra using pedicle screws. Sasso *et al*⁽¹⁹⁾ and Parker *et al*⁽¹⁸⁾ described the validity of the method for indications of associated anterior arthrodesis, in cases with scores greater than or equal to seven, in order to avoid posterior short instrumentation failure. Aligizakis *et al*⁽¹⁾ extrapolated the applicability of the method in order to predict sagittal collapse and patient function following conservative treatment of these fractures.

It has been shown in the literature that anterior arthrodesis is often associated with posterior arthrodesis when there is major comminution of the vertebral body^(4,11,12,25), independent of the levels chosen above and below the fractured vertebra. Nonetheless, there is a lack of analysis on the applicability of this classification for this group of patients.

Our findings, which were from patients who had been treated with arthrodesis on more than one level above and at least one level below the injured ver-

tebra, suggest that there was no correlation between sagittal collapse (worsening of kyphosis) and the severity of fractures, according to the criteria of McCormack *et al*⁽¹⁷⁾. These findings suggest that the classification of McCormack *et al*⁽¹⁷⁾ is not applicable to patients who undergo operations consisting of longer posterior arthrodesis. The instrumentation failures that occurred were breakage in one patient (Figures 1 to 3) and loosening in another. No instrumentation failures were seen in cases with strategies with two levels above and two levels below the fracture, or three levels above and two levels below the fracture (Box 2).

Certain limitations of this study should be borne in mind. This was a retrospective study, with inherent difficulty in controlling for the variables, such as the strategy of posterior instrumentation. The various types of instrumentation (segmental, third-generation hybrid and with the use of pedicle screws) and the levels of posterior arthrodesis diminished the numbers of our sample, with regard to validation and definitive statistical conclusions from the results. For this reason, the statistical differences in outcomes between the different techniques and levels of arthrodesis of the segmental instrumentation used in this case series were not evaluated. Furthermore, the outcome used was radiographic, which means that failure did not necessarily represent worse functional results. Nonetheless, our study is the first to emphasize that instrumentation strategies with arthrodesis longer than one level above and one level below the fracture need to be analyzed in a manner that differs from the McCormack classification.

Randomized controlled studies with larger case series may help to define the best instrumentation strategy in these patients, with the aim of avoiding instrumentation failure. Division into groups according to the scoring in the classification of McCormack *et al*⁽¹⁷⁾ may also define groups that are more homogeneous, in order to analyze the clinical and radiographic outcomes in future studies on these patients.

CONCLUSION

Our findings suggest that there is no relationship between instrumentation failure, sagittal collapse and scoring in the McCormack classification, among patients with thoracolumbar burst fractures who undergo arthrodesis longer than one level above and one level below the fracture.

REFERENCES

1. Aligizakis A, Katonis P, Stergiopoulos K, Galanakis I, Karabekios S, Hadjipavlou A. Functional outcome of burst fractures of the thoracolumbar spine managed non-operatively, with early ambulation, evaluated using the load sharing classification. *Acta Orthop Belg.* 2002;68(3):279-87.
2. Haher TR, Felmy W, Baruch H, Devlin V, Welin D, O'Brien M, et al. The contribution of the three columns of the spine to rotational stability. A biomechanical model. *Spine (Phila Pa 1976).* 1989;14(7):663-9.
3. Aebi M, Etter C, Kehl T, Thalgot J. Stabilization of the lower thoracic and lumbar spine with the internal spinal skeletal fixation system. Indications, techniques, and first results of treatment. *Spine (Phila Pa 1976).* 1987;12(6):544-51.
4. Defino HL, Rodriguez-Fuentes AE. Treatment of fractures of the thoracolumbar spine by combined anteroposterior fixation using the Harms method. *Eur Spine J.* 1998;7(3):187-94.
5. Watson-Jones R. *Fractures and joint injuries.* 3rd ed. Baltimore, Williams & Wilkins; 1943.
6. Holdsworth FW. Fractures, dislocations, and fracture-dislocations of the spine. *J Bone Joint Surg Br.* 1963;45(1):6-20.
7. Holdsworth F. Fractures, dislocations, and fracture-dislocations of the spine. *J Bone Joint Surg Am.* 1970;52(8):1534-51.
8. Kelly RP, Whitesides TE Jr. Treatment of lumbodorsal fracture-dislocations. *Ann Surg.* 1968;167(5):705-17.
9. Bedbrook GM. Treatment of thoracolumbar dislocation and fractures with paraplegia. *Clin Orthop Relat Res.* 1975;(112):27-43.
10. Lucas JT, Ducker TB. Motor classification of spinal cord injuries with mobility, morbidity and recovery indices. *Am Surg.* 1979;45(3):151-8.
11. Denis F. The three column spine and its significance in the classification of acute thoracolumbar spinal injuries. *Spine (Phila Pa 1976).* 1983;8(8):817-31.
12. Denis F. Spinal instability as defined by the three-column spine concept in acute spinal trauma. *Clin Orthop Relat Res.* 1984;(189):65-76.
13. McAfee PC, Yuan HA, Lasda NA. The unstable burst fracture. *Spine (Phila Pa 1976).* 1982;7(4):365-73.
14. Ferguson RL, Allen BL Jr. A mechanistic classification of thoracolumbar spine fractures. *Clin Orthop Relat Res.* 1984;(189):77-88.
15. Gertzbein SD. Spine update. Classification of thoracic and lumbar fractures. *Spine (Phila Pa 1976).* 1994;19(5):626-8.
16. Magerl F, Aebi M, Gertzbein SD, Harms J, Nazarian S. A comprehensive classification of thoracic and lumbar injuries. *Eur Spine J.* 1994;3(4):184-201.
17. McCormack T, Karaikovic E, Gaines RW. The load sharing classification of spine fractures. *Spine (Phila Pa 1976).* 1994;19(15):1741-4.
18. Parker JW, Lane JR, Karaikovic EE, Gaines RW. Successful short-segment instrumentation and fusion for thoracolumbar spine fractures: a consecutive 41/2-year series. *Spine (Phila Pa 1976).* 2000;25(9):1157-70.
19. Sasso RC, Renkens K, Hanson D, Reilly T, McGuire RA Jr, Best NM. Unstable thoracolumbar burst fractures: anterior-only versus short-segment posterior fixation. *J Spinal Disord Tech.* 2006;19(4):242-8.
20. Ulmar B, Gühring M, Schmälzle T, Weise K, Badke A, Brunner A. Inter- and intra-observer reliability of the Cobb angle in the measurement of vertebral, local and segmental kyphosis of traumatic lumbar spine fractures in the lateral X-ray. *Arch Orthop Trauma Surg.* 2010 Apr 28. [Epub ahead of print].
21. Frankel HL, Hancock DO, Hyslop G, Melzak J, Michaelis LS, Ungar GH, et al. The value of postural reduction in the initial management of closed injuries of the spine with paraplegia and tetraplegia. I. Paraplegia. 1969;7(3):179-92.
22. Wang XY, Dai LY, Xu HZ, Chi YL. The load-sharing classification of thoracolumbar fractures: an in vitro biomechanical validation. *Spine (Phila Pa 1976).* 2007;32(11):1214-9.
23. Scholl BM, Theiss SM, Kirkpatrick JS. Short segment fixation of thoracolumbar burst fractures. *Orthopedics.* 2006;29(8):703-8.
24. Avanzi O, Chih LY, Meves R. Avaliação do tratamento cirúrgico da fratura toracolumbar com material de terceira geração. *Rev Bras Ortop.* 2002;37(6):226-32.
25. Avanzi O, Chih LY, Meves R, Silber MF. Avaliação do tratamento cirúrgico tardio na fratura toracolombar tipo tipo explosão. *Coluna.* 2002;1(2):88-93.
26. Meves R, Avanzi O. Correlation between neurological deficit and spinal canal compromise in 198 patients with thoracolumbar and lumbar fractures. *Spine (Phila Pa 1976).* 2005;30(7):787-91.
27. Meves R, Avanzi O. Correlation among canal compromise, neurologic deficit, and injury severity in thoracolumbar burst fractures. *Spine (Phila Pa 1976).* 2006;31(18):2137-41.
28. Avanzi O, Chih LY, Meves R, Silber MF. Avaliação tomográfica do fragmento retropulsado nas fraturas toracolombares tipo explosão. *Coluna.* 2006;5(4):247-52.