

Onyx™ embolization for an angiographically progressive traumatic pseudoaneurysm of the middle meningeal artery: A case report and literature review

XIN-YU LU^{1,2} and XIN ZHANG²

¹Department of Neurosurgery, People's Hospital Affiliated to Jiangsu University, Zhenjiang, Jiangsu 212001;

²Department of Neurosurgery, Jinling Hospital, School of Medicine, Nanjing University, Nanjing, Jiangsu 210002, P.R. China

Received July 30, 2018; Accepted February 27, 2019

DOI: 10.3892/etm.2019.7403

Abstract. Traumatic pseudoaneurysm of the middle meningeal artery (MMA) is a rare entity that is typically associated with a high risk of rupture and mortality. Only few such cases of pseudoaneurysms have been reported in the medical literature and therefore, the optimal management of this condition remains undetermined. The present study reported on a female patient (age, 20 years) with angiographically progressive pseudoaneurysm of the MMA after head injury. The pseudoaneurysm was successfully embolized with the liquid, non-adhesive embolic agent Onyx™. The mechanism of formation of traumatic pseudoaneurysms, their imaging characteristics and the optimal treatment plan were discussed.

Introduction

Traumatic pseudoaneurysm of the middle meningeal artery (MMA) is a rare condition and usually a hidden complication of head injury. It accounts for <1% of all intracranial aneurysms (1). Histologically, these aneurysms are not true aneurysms, as the latter are characterized by dilatation of all layers of the blood vessel wall, while a pseudoaneurysm is formed by traumatic rupture of the arterial wall, resulting in hematoma formation outside the artery (2). The wall of the pseudoaneurysm is composed of the surrounding fibrous tissue and cerebral structures (2,3). The fragility of the pseudoaneurysm wall makes it particularly susceptible to rupture, resulting in a high risk of mortality (3). Therefore, appropriate and timely management is imperative in such cases. However, a major limiting factor is that the natural course of pseudoaneurysms is not well understood and their detection during emergency

computerized tomography (CT) scans is challenging owing to the lack of typical signs (4). Furthermore, there are no definite management guidelines for these lesions (5,6).

Onyx™ is a liquid, non-adhesive embolic agent, which is ideal for slow, targeted injections. It has been used in intracranial aneurysms and arteriovenous malformations (7-9). With technological progress, its use has been expanded to and established in the management of cerebral pseudoaneurysm (10,11).

The present study reports on a case of traumatic pseudoaneurysm of the MMA with angiographic changes progressing for a period of one week, which was successfully embolized using Onyx™. The available literature on this subject was also reviewed, and the neuroradiological signs of the pseudoaneurysm and the feasibility of Onyx™ in the treatment of this condition were discussed.

Case report

A 20-year-old female patient presented at the emergency department of a local hospital with an acute head injury sustained in a motor vehicle collision, following which she remained unconscious for ~10 min on October 14th, 2014. On admission, the patient was conscious; her Glasgow Coma Scale score was 14/15 with no localizing neurological signs. Initial cranial CT scan revealed an ~17-ml epidural hematoma in the left temporal region along with left temporal bone fracture (Fig. 1). Since there was no mass effect or midline shift, the patient was treated conservatively with hemostatic drugs and mannitol, following which she remained clinically stable. Repeated CT on the same day and the next day indicated no increase in the size of the hematoma. After medical treatment for two weeks, a gradual improvement in the signs and symptoms of the patient was noted. At 1 month after the head injury, follow-up by serial brain CT indicated a near-complete resorption of the hematoma and the patient was discharged from hospital. However, a routine follow-up CT scan performed at 38 days after the head injury revealed a hyperdense nodule in the left temporal region (Fig. 2A). CT revealed a hyperdense nodule with strong homogeneous contrast enhancement, which was suspected to be vascular in nature (Fig. 2B). Three-dimensional CT angiography indicated a traumatic pseudoaneurysm of the left external carotid

Correspondence to: Dr Xin Zhang, Department of Neurosurgery, Jinling Hospital, School of Medicine, Nanjing University, 305 East Zhongshan Road, Nanjing, Jiangsu 210002, P.R. China
E-mail: Njzhangxin2016@163.com

Key words: pseudoaneurysm, middle meningeal artery, Onyx™, traumatic brain injury

artery with no communication with the main intracranial arteries (Fig. 2C). The patient underwent digital subtraction angiography (DSA) three days later. The DSA confirmed the diagnosis and revealed two pseudoaneurysms arising from the posterior branch of the left MMA (Fig. 3). The patient and her family members were reluctant to accept surgery at the local hospital; therefore, the patient was referred to Jinling Hospital (School of Medicine, Nanjing University, Nanjing, China).

After 1 week, cerebral angiography was repeated to evaluate the pseudoaneurysms and to determine the treatment plan. The angiogram revealed that, while the proximal pseudoaneurysm had decreased in size, the distal one had enlarged (Fig. 4A). Due to its progressive nature, there was a high risk of rupture; therefore, immediate embolization was planned, and informed consent was obtained.

The procedure was performed under general anesthesia. Access was obtained via a transfemoral approach by standard techniques. The left external carotid artery and the branch of the left MMA were selectively catheterized using an Echelon™ 10 microcatheter. The microcatheter was flushed with 4 ml saline and its dead space was then filled with 0.3 ml of dimethyl sulfoxide (DMSO). Under constant fluoroscopic guidance, ONYX™ 34 was injected to embolize the posterior branch of the MMA as previously reported (Fig. 4B) (12).

After embolization, selective angiography indicated that the left external carotid artery and the left MMA were normal except for the posterior branch, and the pseudoaneurysm was no longer visible. Repeated CT performed on the next day revealed that the hyperdense nodule, which was present pre-operatively, had disappeared and there were no signs of any new hemorrhage. The patient was discharged from hospital on the third post-operative day with no neurological deficit. Follow-up DSA performed six months following the head injury revealed no signs of recurrence of the pseudoaneurysm (Fig. 5).

Discussion

Traumatic pseudoaneurysm is a rare entity, accounting for ~1% of all aneurysms (1). In most cases, pseudoaneurysms are formed due to a tear in the arterial wall after head injury (13). Approximately 85% of all traumatic pseudoaneurysms are located in the temporal region and the remaining ones occur either in the occipital or the frontal region (14). Traumatic pseudoaneurysm of the MMA was first described by Schulze in 1957 (15). An estimated 70-90% of traumatic pseudoaneurysms of the MMA arise in association with a fracture of the skull bone overlying the temporal part of the MMA (16). In the current case, an anterior fracture line passing through the temporal part of the MMA was clearly discernible and two pseudoaneurysms occurred in the posterior branch of the left MMA. Besides direct trauma to the arterial wall, traction of the MMA may occur during closed head trauma. Cases of pseudoaneurysms of the MMA ostensibly caused by traction of the MMA have been reported in patients with no documented bone fracture on the same side (3,13,17).

Almost all MMA pseudoaneurysms reportedly rupture within 30 days of formation, resulting in high mortality and morbidity (17,18). Therefore, the requirement for early diagnosis and timely management of pseudoaneurysms cannot be overemphasized.

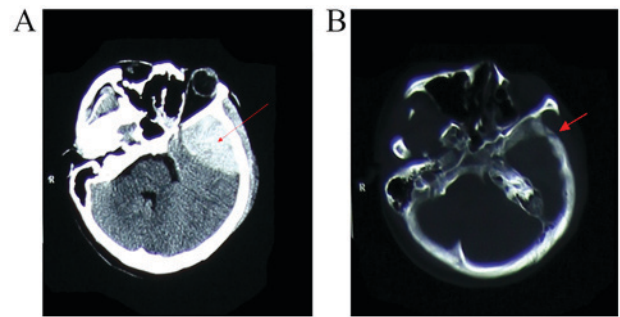


Figure 1. Brain computed tomogram on admission, revealing (A) an epidural hematoma in the left temporal lobe (arrow) and (B) a fracture line through the temporal bone (arrow).

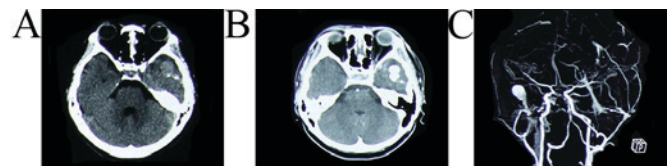


Figure 2. (A) CT scan performed on day 38 post-head injury revealing a hyperdense nodule in the left temporal parenchyma. (B) On contrast-enhanced CT, the hyperdense lesion displayed as an intense, homogeneous enhancement. (C) Three-dimensional CT angiogram indicating a pseudoaneurysm of the left external carotid artery branch. CT, computed tomography.

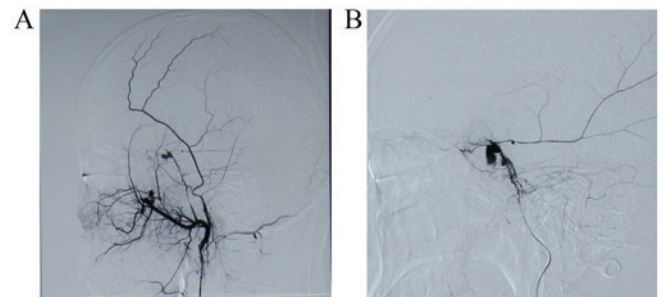


Figure 3. Cerebral angiogram obtained 42 days post-head injury revealing two pseudoaneurysms located at the posterior branch of the left MMA. (A) Initial diagnostic cerebral angiography was performed by 5F single-curve catheter in the external carotid artery. (B) Microcatheter angiography confirmed the diagnosis of MMA. MMA, middle meningeal artery.

Prior to the availability of DSA, no specific imaging modalities for diagnosis of traumatic pseudoaneurysms were available. Wang *et al* (19) suggested four indicators for the diagnosis of traumatic pseudoaneurysm of the MMA based on CT findings: i) Basal skull fracture in the temporal region on the sequential bone window; ii) hypodense nodule within an acute hematoma; iii) a well-organized and encapsulated hematoma with a hypodense nodule; and iv) strong and homogenous enhancement of the hypodense nodule within the organized and encapsulated hematoma. However, none of the above indications were observed in the serial CT scans of the present case. In contrast to the results of Wang *et al* (19), in the present case, the pseudoaneurysm appeared as a hyperdense nodule in the left temporal part on non-contrast CT, and this nodule exhibited a strong and homogenous enhancement on contrast CT. The hyperdense nodule was confirmed to be a pseudoaneurysm by three-dimensional CT angiography, and

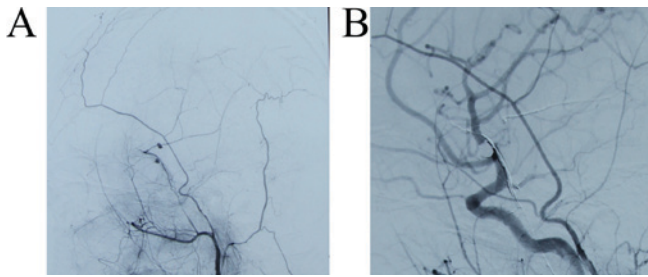


Figure 4. (A) Repeated cerebral angiography was performed on day 49 post-head injury, revealing a decrease in the size of the proximal pseudoaneurysm; however, the distal pseudoaneurysm had become enlarged. (B) The two pseudoaneurysms were successfully embolized with Onyx, after which the pseudoaneurysms, including the afferent and efferent limbs, became undetectable.

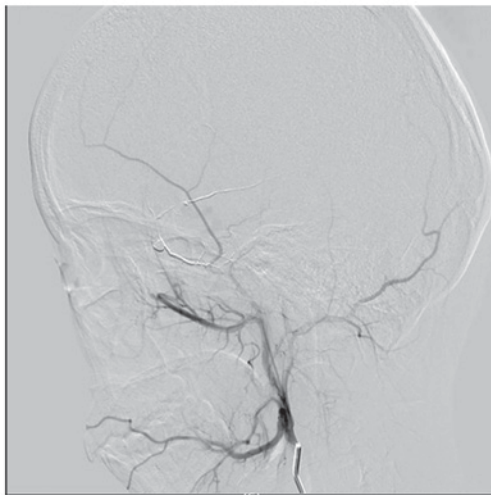


Figure 5. Follow-up angiogram obtained six months post-head injury indicating no signs of recurrence of the pseudoaneurysm.

later by DSA. Thus, strong and homogenous enhancement of hyperdense nodule in a hematoma may be an indicator of pseudoaneurysm. It has also been suggested that enlarging parenchymal hematoma and atypical hematoma evolution on CT scan should lead to angiographic validation (20). Several other studies suggested that CT angiography is a useful and effective tool to confirm the diagnosis of pseudoaneurysm (4,19).

Digital subtraction angiography is usually considered the gold standard for the diagnosis of traumatic pseudoaneurysm. In the case of the present study, the specific characteristics of traumatic pseudoaneurysm were evidenced by DSA. The typical characteristics of traumatic pseudoaneurysm observed on angiography are as follows: Elliptical or irregular-shaped aneurysmal sac without neck, peripheral location at a distance from a branching point, and delayed and slow filling and emptying of contrast agent during the procedure (18). In the present case, initial angiography at the patient's local hospital revealed the pseudoaneurysm of MMA; however, the patient was reluctant to receive open surgery to clip the pseudoaneurysm, and therefore, conservative therapy was adopted. However, repeat angiography performed one week later revealed an increase in the size of the pseudoaneurysm. Similar pseudoaneurysm

progressions have been reported in other studies (5,21). One of the possible mechanisms of the progression of pseudoaneurysm is that the initial tear in the meningeal artery is small and tends to get sealed off by clot and subsequently, the size of clot increases due to further leakage of blood, resulting in recanalization and formation of a false lumen. Thus, the pseudoaneurysm gradually aggravates and may rupture spontaneously (5,21).

A review of literature revealed gaps in the current knowledge of the pathophysiology of pseudoaneurysms compared with that of other vascular malformations in the brain (3,22,23). In addition, there are no definitive treatment guidelines for the management of affected patients (5,6). Certain studies have documented spontaneous resolution of aneurysms without treatment, which suggests that pseudoaneurysm may be followed up conservatively with periodic conventional angiography (6,24). In the present case, conservative treatment and observation were performed for one week; however, repeat DSA revealed that one of the two pseudoaneurysms had worsened, while the other had slightly reduced. In another similar report, Lee *et al* (5) presented a case with progressive traumatic pseudoaneurysm arising from the MMA, and the lesion was finally treated with endovascular embolization. Furthermore, the friable pseudoaneurysmal walls are prone to rupture, and may result in mortality. It is estimated that >80% of traumatic pseudoaneurysms rupture and the mortality rate may reach up to 20% (13,18,25). Given the high mortality rate following rupture, it is strongly recommended that the pseudoaneurysms should be managed in a timely and safe manner.

Open surgery has been the traditional choice of treatment for pseudoaneurysm, and several reports have established its success (2,18,22,26). During open surgery, the pseudoaneurysm may be excised, clipped or trapped, and the surrounding hematoma may also be evacuated at the same time. However, surgery may be challenging given the friable nature of the aneurysm, which often lacks a satisfactory aneurysmal neck for clip placement; therefore, open surgery for pseudoaneurysm is associated with a higher risk of intra-operative rupture and surgical morbidity compared with surgery of a common saccular aneurysm (27-29).

With advances in technology and materials, endovascular surgery including coil embolization and parent vessel occlusion is a reasonable alternative treatment option for pseudoaneurysms. Kawaguchi *et al* (16) reported the successful embolization of a left MMA pseudoaneurysm with four fibered platinum coils. Jussen *et al* (23) reported on the embolization of two MMA pseudoaneurysms by coils and suggested that endovascular embolization represents a safe treatment option for traumatic MMA pseudoaneurysms. However, the small size and irregular morphology of pseudoaneurysms may not allow for the accommodation of standard-sized coils. Furthermore, any manipulation of the pseudoaneurysm wall, whether with the microcatheter or during coil placement, increases the risk of intraprocedural rupture (10,27). On the other hand, it is frequently difficult to completely occlude the aneurysm-bearing vessels with coils. For these reasons, complete embolization using liquid embolic agents such as Onyx™ may be a safer and more effective management option.

Onyx™ is an ethylenevinyl alcohol co-polymer dissolved in DMSO with added micronized tantalum powder to

provide radiopacity (30). A major advantage of Onyx™ is its non-adherence to the catheter and vessel, which allows the operator to inject the substance slowly and with more precision; this facilitates real-time monitoring for reflux and precludes the concern for catheter adhesion (27). It is thought that Onyx™ allows for more precise achievement of proximal occlusion than N-butyl cyanoacrylate or coils (31). Onyx™ embolization of pseudoaneurysms has been described in several previous case reports (27,32,33). The present study further demonstrates that Onyx™ treatment is a safe and effective modality for embolization of pseudoaneurysms.

In conclusion, traumatic pseudoaneurysm of the MMA is a rare, yet life-threatening condition. Although there are no typical signs on CT or MRI, meningeal pseudoaneurysm should be considered as one of the differential diagnoses in cases of enlarging hematoma or unusual or delayed hematoma evolution on CT, particularly if a fracture line crosses the middle artery location. Due to the high rupture rate and mortality associated with pseudoaneurysm, open surgery remains a traditional choice of treatment for pseudoaneurysm; however, with the development of technology and materials, embolization with Onyx™ should be considered a reasonable treatment option for traumatic pseudoaneurysm of MMA for patients who are not suitable for open surgery.

Acknowledgements

Not applicable.

Funding

The author(s) received no financial support for the research, authorship and/or publication of this article.

Availability of data and materials

All data generated or analyzed during this case are included in this published article.

Authors' contributions

XL and XZ drafted the manuscript. XZ conceived and designed the current study and revised the manuscript. All authors critically reviewed this manuscript and approved the final version.

Ethical approval and consent to participate

Not applicable.

Patient consent for publication

Informed consent by the patient was obtained for publication of this case.

Competing interests

The authors declare that they have no competing interests.

References

1. Benoit BG and Wortzman G: Traumatic cerebral aneurysms. Clinical features and natural history. *J Neurol Neurosurg Psychiatry* 36: 127-138, 1973.
2. Lim DH, Kim TS, Joo SP and Kim SH: Intracerebral hematoma caused by ruptured traumatic pseudoaneurysm of the middle meningeal artery: A case report. *J Korean Neurosurg Soc* 42: 416-418, 2007.
3. Montanari E, Polonara G, Montalti R, Vivarelli M, Ricciuti RA, Giorgetti R and Tagliabracci A: Delayed intracerebral hemorrhage after pseudoaneurysm of middle meningeal artery rupture: Case report, literature review, and forensic issues. *World Neurosurg* 117: 394-410, 2018.
4. Paiva WS, Andrade AF, Amorim RL, Bor-Seng-Shu E, Gattas G, Neville IS, Caldas JG, Figueiredo EG and Teixeira MJ: Computed tomography angiography for detection of middle meningeal artery lesions associated with acute epidural hematomas. *Biomed Res Int* 2014: 413916, 2014.
5. Lee JY, Lee CY and Kim HW: Angiographically progressive change of traumatic pseudoaneurysm arising from the middle meningeal artery. *J Korean Neurosurg Soc* 56: 423-427, 2014.
6. Srinivasan A, Lesiuk H and Goyal M: Spontaneous resolution of posttraumatic middle meningeal artery pseudoaneurysm. *AJNR Am J Neuroradiol* 27: 882-883, 2006.
7. Rahme R, Grande A, Jimenez L, Abruzzo TA and Ringer AJ: Onyx HD-500 embolization of intracranial aneurysms: Modified technique using continuous balloon inflation under conscious sedation. *J Clin Neurosci* 21: 1383-1387, 2014.
8. Ashour R and Ali Aziz-Sultan M: Onyx HD-500 for embolization of cerebral aneurysms. *Neurol Res* 36: 363-367, 2014.
9. Jittapiromsak P, Ikka L, Benachour N, Spelle L and Moret J: Transvenous balloon-assisted transarterial Onyx embolization of transverse-sigmoid dural arteriovenous malformation. *Neuroradiology* 55: 345-350, 2013.
10. Medel R, Crowley RW, Hamilton DK and Dumont AS: Endovascular obliteration of an intracranial pseudoaneurysm: The utility of Onyx. *J Neurosurg Pediatr* 4: 445-448, 2009.
11. La Barge DV III, Ng PP, Stevens EA, Friedline NK, Kestle JR and Schmidt RH: Extended intracranial applications for ethylene vinyl alcohol copolymer (Onyx): Mycotic and dissecting aneurysms. Technical note. *J Neurosurg* 111: 114-118, 2009.
12. van Rooij WJ, Sluzewski M and Beute GN: Brain AVM embolization with Onyx. *AJNR Am J Neuroradiol* 28: 172-177, 2007.
13. Wu X, Jin Y and Zhang X: Intraparenchymal hematoma caused by rupture of the traumatic pseudoaneurysm of middle meningeal artery. *J Craniofac Surg* 25: e111-e113, 2014.
14. Tsutsumi M, Kazekawa K, Tanaka A, Ueno Y, Nomoto Y, Nii K and Harada H: Traumatic middle meningeal artery pseudoaneurysm and subsequent fistula formation with the cavernous sinus: Case report. *Surg Neurol* 58: 325-328, 2002.
15. SCHULZE A: Unusual forms of epidural hematoma. *Zentralbl Neurochir* 17: 40-47, 1957 (In German).
16. Kawaguchi T, Kawano T, Kaneko Y, Ooasa T, Ooigawa H and Ogasawara S: Traumatic lesions of the bilateral middle meningeal arteries-case report. *Neurol Med Chir (Tokyo)* 42: 221-223, 2002.
17. Bozzetto-Ambrosi P, Andrade G and Azevedo-Filho H: Traumatic pseudoaneurysm of the middle meningeal artery and cerebral intraparenchymal hematoma: Case report. *Surg Neurol* 66 (Suppl 3): S29-S31, 2006.
18. Bruneau M, Gustin T, Zekhnini K and Gilliard C: Traumatic false aneurysm of the middle meningeal artery causing an intracerebral hemorrhage: Case report and literature review. *Surg Neurol* 57: 174-178, 2002.
19. Wang CH, Lee HC and Cho DY: Traumatic pseudoaneurysm of the middle meningeal artery: Possible indicators for early diagnosis in the computed tomography era. *Surg Neurol* 68: 676-681, 2007.
20. Brzozowski K, Frankowska E, Piasecki P, Zięcina P, Zukowski P and Bogusławska-Walecka R: The use of routine imaging data in diagnosis of cerebral pseudoaneurysm prior to angiography. *Eur J Radiol* 80: e401-e409, 2011.
21. Meder JF, Gaston A, Merienne L, Godon-Hardy S and Fredy D: Traumatic aneurysms of the internal and external carotid arteries. One case and a review of the literature. *J Neuroradiol* 19: 248-255, 1992 (In English and French).

22. Nayil K, Ramzan A, Makhdoomi R, Wani A, Zargar J and Shaheen F: Incidental traumatic pseudoaneurysm of the middle meningeal artery: Case report and literature review. *Turk Neurosurg* 22: 239-241, 2012.
23. Jussen D, Wiener E, Vajkoczy P and Horn P: Traumatic middle meningeal artery pseudoaneurysms: Diagnosis and endovascular treatment of two cases and review of the literature. *Neuroradiology* 54: 1133-1136, 2012.
24. Shah Q, Friedman J and Mamourian A: Spontaneous resolution of traumatic pseudoaneurysm of the middle meningeal artery. *AJNR Am J Neuroradiol* 26: 2530-2532, 2005.
25. Biondi A: Intracranial aneurysms associated with other lesions, disorders or anatomic variations. *Neuroimaging Clin N Am* 16: 467-482, 2006.
26. Kimura T, Sako K, Satoh M, Nakai H, Yonemasu Y, Takeuchi E and Ishikura H: Posttraumatic pseudoaneurysm of the middle meningeal artery: A case report. *No Shinkei Geka* 23: 1021-1025, 1995 (In Japanese).
27. Jadhav AP, Pryor JC and Nogueira RG: Onyx embolization for the endovascular treatment of infectious and traumatic aneurysms involving the cranial and cerebral vasculature. *J Neurointerv Surg* 5: 562-565, 2013.
28. Sim SY, Shin YS and Yoon SH: Endovascular internal trapping of traumatic pericallosal pseudoaneurysm with hydrogel-coated self-expandable coil in a child: A case report. *Surg Neurol* 69: 418-422, 2008.
29. Uzan M, Cantasdemir M, Seekin MS, Hanci M, Kocer N, Sarioglu AC and Islak C: Traumatic intracranial carotid tree aneurysms. *Neurosurgery* 43: 1314-1320, 1998.
30. Szajner M, Roman T, Markowicz J and Szczerbo-Trojanowska M: Onyx[®] in endovascular treatment of cerebral arteriovenous malformations-a review. *Pol J Radiol* 78: 35-41, 2013.
31. Choo DM and Shankar JJ: Onyx versus nBCA and coils in the treatment of intracranial dural arteriovenous fistulas. *Interv Neuroradiol* 22: 212-216, 2016.
32. Mehta S, Alawi A and Edgell R: E-073 endovascular treatment of a traumatic middle meningeal artery pseudoaneurysm with Onyx LES: A case report and review of literature. *J Neurointerv Surg* 6: A73, 2014.
33. Eddleman CS, Surdell D, DiPatri AJ, Tomita T and Shaibani A: Infectious intracranial aneurysms in the pediatric population: Endovascular treatment with Onyx. *Childs Nerv Syst* 24: 909-915, 2008.



This work is licensed under a Creative Commons Attribution-NonCommercial-NoDerivatives 4.0 International (CC BY-NC-ND 4.0) License.