

Delayed Type III Endoleak Caused by Fabric Erosion after Endovascular Repair of an Abdominal Aortic Aneurysm

Jae Hang Lee, M.D., Eung-joong Kim, M.D., Jin-Ho Choi, M.D.

Department of Thoracic and Cardiovascular Surgery, Dongguk University Ilsan Hospital

A 74-year-old patient presented with recurrent aneurysms in the infrarenal abdominal aorta and right common iliac artery 6 years after endovascular aortic repair using endografts in the same location. The patient underwent an aorto-bi-iliac replacement with removal of the stent graft. Two holes measuring 2 mm each were found in the removed graft, and they appeared to have been caused by wear from continuous friction between the endograft and the aortic wall.

Key words: 1. Aneurysm
2. Aorta
3. Abdominal
4. Endovascular procedures
5. Endoleak

Case report

A 74-year-old female patient visited our hospital for the evaluation of a palpable abdominal mass. The patient had undergone successful endovascular aneurysm repair (EVAR) for an infrarenal abdominal aortic aneurysm (AAA) and a right common iliac artery (CIA) aneurysm 6 years ago, and had been lost to follow-up since 3 months after the procedure.

In computed tomographic angiography (CTA) before the EVAR procedure, the patient had an aortic aneurysm; the maximal diameters of the infrarenal AAA and the right CIA aneurysm were 50 mm and 36 mm, respectively. Even though the aorta was tortuous with a proximal angle of 75°, the proximal aortic diameter of 26 mm and proximal neck length of 33 mm seemed anatomically suitable for an EVAR procedure (Fig. 1). At that time, EVAR using the SEAL stent graft (S&G Biotech, Seongnam, Korea) was

performed under general anesthesia. A bifurcated proximal graft measuring 30 mm in diameter was used as the main body; on the right side, the right internal iliac artery was covered with a limb extension using a 12-mm stent graft, and on the left side, a 20-mm bell bottom-shaped endograft was placed before the iliac bifurcation. After the surgery, no endoleak was observed on the CTA images either immediately or 2 months postoperatively. The patient did not visit the hospital again until 6 years later, when she presented with a palpable abdominal mass.

In the initial CTA images obtained during the more recent admission, type Ia and Ib endoleaks were observed, and a type III endoleak was also suspected (Fig. 2). The maximal diameters of the aneurysms were 61 mm for the AAA; 41 mm for the right CIA; and 35 mm for the left CIA. This time, the patient underwent surgery rather than an endovascular intervention, and an aorto-bi-iliac bypass using a trans-

Received: November 10, 2016, Revised: April 3, 2017, Accepted: April 7, 2017, Published online: August 5, 2017

Corresponding author: Jin-Ho Choi, Department of Thoracic and Cardiovascular Surgery, Dongguk University Ilsan Hospital, 27 Dongguk-ro, Ilsandong-gu, Goyang 10326, Korea
(Tel) 82-31-961-7285 (Fax) 82-31-961-7287 (E-mail) miracleho@gmail.com

© The Korean Society for Thoracic and Cardiovascular Surgery. 2017. All right reserved.

© This is an open access article distributed under the terms of the Creative Commons Attribution Non-Commercial License (<http://creativecommons.org/licenses/by-nc/4.0>) which permits unrestricted non-commercial use, distribution, and reproduction in any medium, provided the original work is properly cited.

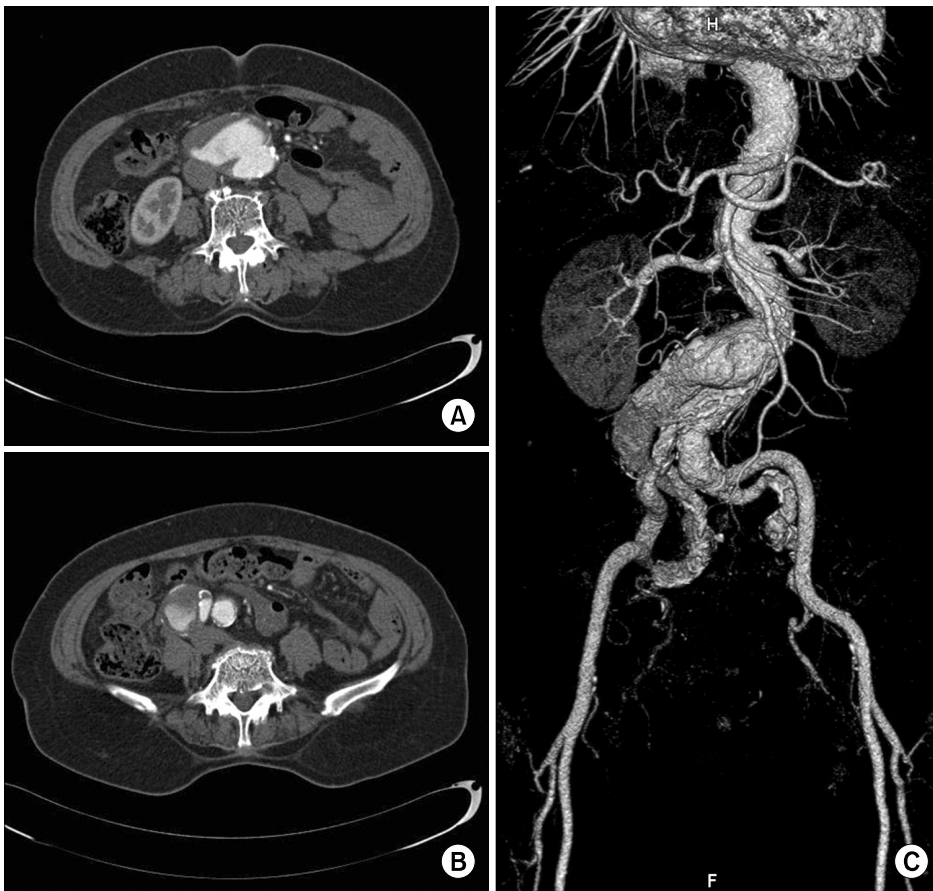


Fig. 1. Computed tomographic angiography before endovascular aortic repair. (A, B) Computed tomographic angiography shows the infrarenal abdominal aneurysm with a maximum diameter of 50 mm and the right common iliac artery aneurysm with a maximum diameter of 36 mm in the combined chronic dissection. (C) 3-Dimensional reconstruction shows the proximal hostile neck of the infrarenal abdominal aortic aneurysm with tortuosity.

peritoneal approach was performed. After cross-clamping the aneurysm proximally at the stented aorta and distally at the bi-iliac artery, the SEAL stent graft was removed, with a portion of the bare metal stent proximal to the cross-clamp left unremoved. Then, the aorto-bi-iliac artery was replaced using a prosthetic vascular graft, with the residual bare metal stent included in the proximal anastomosis. The surgical findings showed that the main body of the stent graft had been in contact with the aortic wall in the kinked area as shown in the CTA image, and there were 2 holes with erosions of 2 mm (Fig. 3A, B). The patient was discharged on postoperative day 26, and has remained well, without any complications, over 8 months of postoperative follow-up (Fig. 3C).

Discussion

Recently, EVAR has become more popular than open surgery for infrarenal AAA and for CIA aneu-

rysms. This procedure is clearly superior in terms of operative mortality and morbidity-related short-term outcomes [1], but the long-term results are still in doubt. This is because type I endoleaks or graft migration can occur due to gradual changes in the shape of the aorta, or type III endoleaks can occur due to fatigue in the metallic strut or worn-out fabric.

Although type III endoleaks rarely occur with the recent developments in device technology, they require careful attention because they are closely associated with aneurysm ruptures. In fact, for each manufactured product, type III endoleaks have only been reported as case studies with various causes [2-4]. Suggested causes of type III endoleaks are defects in the graft fabric, strut fatigue, inadequate sealing during production, and disconnection between modular components.

The SEAL aortic stent graft is the only endograft produced in Korea, and is composed of polyester fabric with self-expandable nitinol. Because it is produced domestically, which allows for the quick manu-

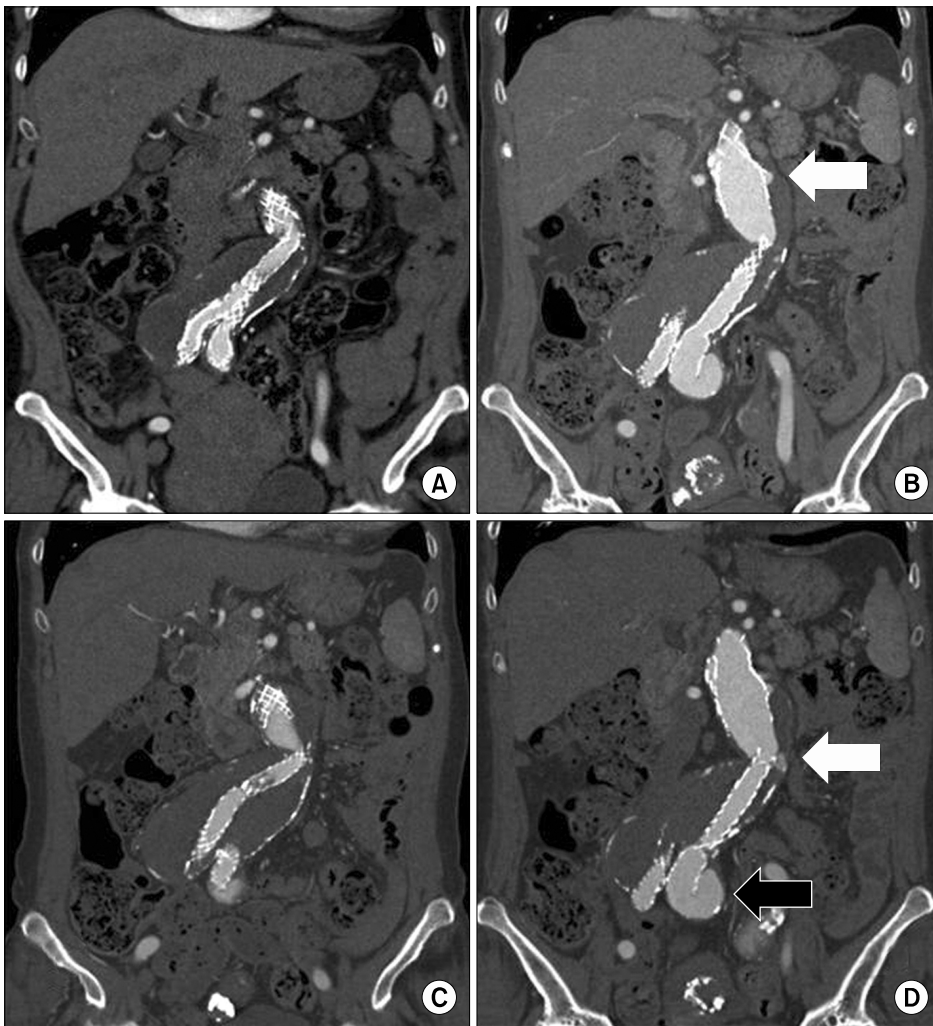


Fig. 2. CTA after endovascular aortic repair. (A) The CTA images taken immediately postoperatively show the kinked endograft making contact with the aortic wall. (B-D) A CTA image taken 6 years postoperatively shows that the endograft kinking had worsened (C), and type Ia (white arrow in B), type 3 (white arrow in D), and type 1b (black arrow in D) endoleaks were observed. CTA, computed tomographic angiography.

facture of grafts of various shapes, it has a large market in Korea. Park et al. [5] reported on the mid-term results and the durability of SEAL grafts, and a type III endoleak occurred in 1 of 33 patients, resulting from separation between the main body and a limb extension. Concerning the SEAL stent graft, there are, to date, no case reports of type III endoleaks caused by fabric erosion, and holes over 2 mm are larger defects than those reported in previous case studies.

We propose that the aneurysm in this patient recurred because the kinked stent graft made contact with the aortic wall and gradually wore out with pulsation, creating 2 large holes that led to a massive type III endoleak. As the aneurysm continued to grow, the aorta changed its shape, which caused type Ia and Ib endoleaks, accelerating the aneurysmal

change. The location of the tear was close to the proximal end of the iliac limb. Thus, the fabric could have been worn out by the friction between the aorta and the proximal edge of the iliac limb, considering its tear site location. Another hypothesis is that the type Ib endoleak occurred initially at the left CIA and eventually led to type III endoleak by expansion and angulation of the aneurysm, which made the internal stent impinge against the graft fabric. However, due to the lack of imaging during the period in which the patient was lost to follow-up, neither hypothesis can be definitely proven.

In summary, type III endoleaks may occur after EVAR with SEAL endografts, as well as different stent grafts. It appears that the device needs further improvement, with attention to durability of the fabric material and development of metallic struts with less

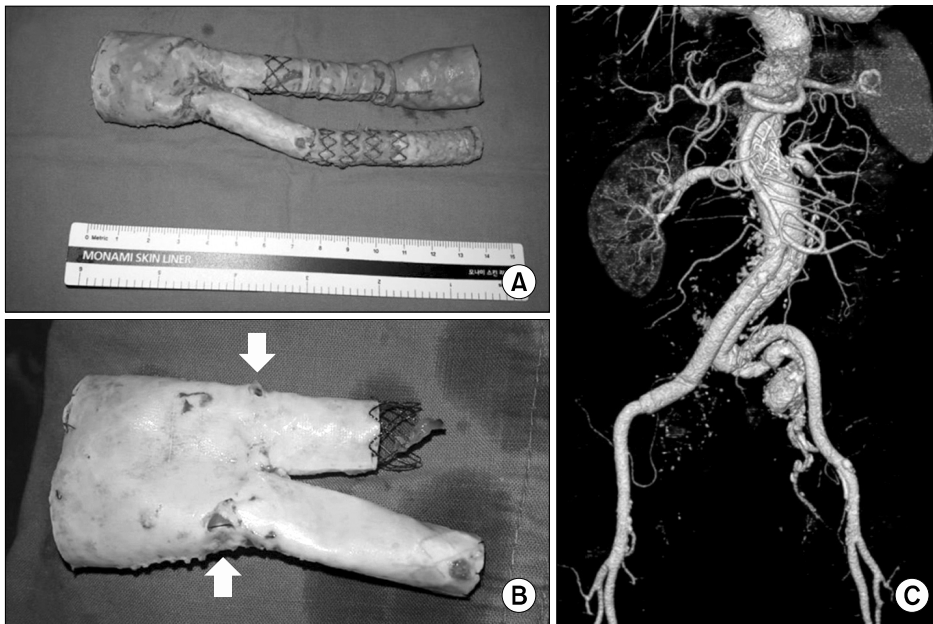


Fig. 3. Gross images of the previously inserted SEAL stent graft are shown in A and B. (A, B) The proximal bare-stent portion was left in the patient's aorta. In the main body of the endograft, 2 large holes of over 2 mm in diameter were observed (white arrows). (C) Postoperative computed tomographic angiography after aorto-bi-iliac replacement is shown in a 3-dimensional reconstruction.

graft kinking. Despite ongoing technical progress in the field of endovascular interventions, indiscriminate EVAR must be avoided in patients with unfavorable anatomy, such as hostile necks, acutely angulated aneurysms, or large iliac artery aneurysms at the distal aneurysmal end. The indications for open surgery and EVAR should be clarified in further studies.

Conflict of interest

No potential conflict of interest relevant to this article was reported.

References

1. Greenhalgh RM, Brown LC, Kwong GP, Powell JT, Thompson SG; EVAR trial participants. *Comparison of endovascular aneurysm repair with open repair in patients with abdominal aortic aneurysm (EVAR trial 1), 30-day operative mortality results: randomised controlled trial.* *Lancet* 2004;364:843-8.
2. Teutelink A, van der Laan MJ, Milner R, Blankensteijn JD. *Fabric tears as a new cause of type III endoleak with Ancure endograft.* *J Vasc Surg* 2003;38:843-6.
3. Lee WA, Huber TS, Seeger JM. *Late type III endoleak from graft erosion of an Excluder stent graft: a case report.* *J Vasc Surg* 2006;44:183-5.
4. Wanhainen A, Nyman R, Eriksson MO, Bjorck M. *First report of a late type III endoleak from fabric tears of a Zenith stent graft.* *J Vasc Surg* 2008;48:723-6.
5. Park SY, Kim JH, Byun SS, Kang JM, Choi ST, Park JH. *Endovascular therapy for abdominal aortic aneurysm and iliac artery aneurysm using SEAL aortic stent-graft: a single center experience.* *J Korean Soc Radiol* 2015;72:156-63.