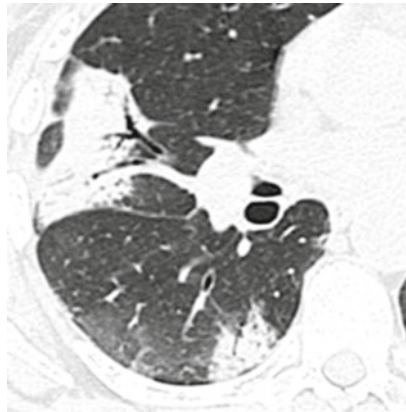



Alveolar Diseases

Radiology	Luciano Cardinale Edoardo Piacibello Giorgia Dalpiaz
-----------	---



Adenocarcinoma	Adenocarcinoma	Page 164
AE-IPF	Acute exacerbation of IPF	Page 166
AEP	Acute eosinophilic pneumonia	Page 168
AIP	Acute interstitial pneumonia	Page 170
ARDS	Acute respiratory distress syndrome	Page 172
CEP	Chronic eosinophilic pneumonia	Page 174
COP	Cryptogenic organizing pneumonia	Page 176
DAH	Diffuse alveolar hemorrhage in WG	Page 178
DIP	Desquamative interstitial pneumonia	Page 180
Drug toxicity	Amiodarone-induced lung disease	Page 182
FES	Fat embolism syndrome	Page 184
Infection, acute (PJP)	PJP	Page 186
Infection, chronic (TB)	TB	Page 188
LP	Lipoid pneumonia	Page 192
MALToma	Mucosa-associated lymphatic tissue lymphoma	Page 194
Metastases, aerogenous	Metastases, aerogenous	Page 196
PAP	Pulmonary alveolar proteinosis	Page 198
PE, alveolar	Pulmonary edema, alveolar	Page 200

Definition

Adenocarcinoma has surpassed squamous cell carcinoma as the leading histologic type, accounting for 30% of all cases of lung cancer. The new 2015 WHO classification provided the basis for a multidisciplinary approach emphasizing the close correlation among radiologic and histopathologic pattern of lung adenocarcinoma. The term “bronchioloalveolar carcinoma” has been eliminated, introducing the concepts of adenocarcinoma in situ (ais) and minimally invasive adenocarcinoma (mia) and the use of descriptive predominant patterns in invasive adenocarcinomas (lepidic, acinar, papillary, solid, and micropapillary patterns). Invasive mucinous adenocarcinoma is the new definition for mucinous bronchioloalveolar carcinoma.



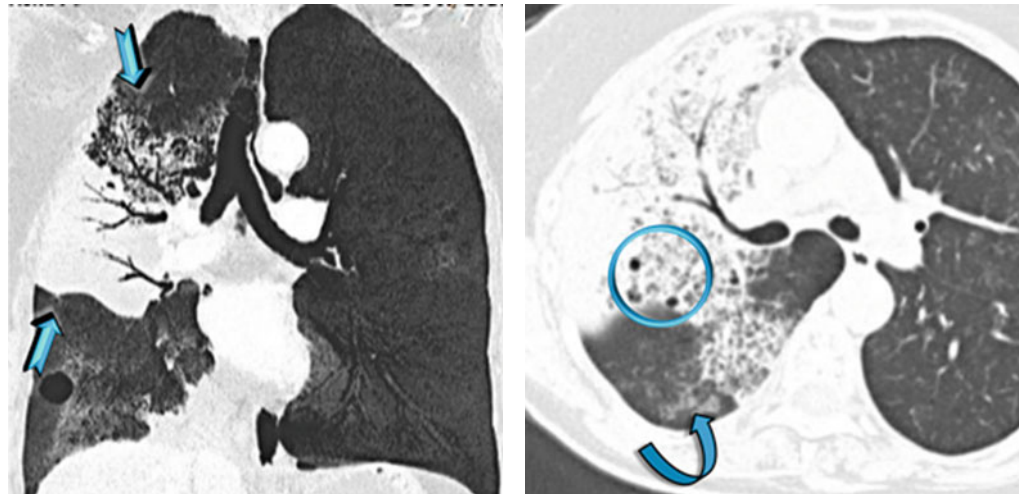
Travis WD (2015) The 2015 World Health Organization classification of lung tumors: impact of genetic, clinical and radiologic advances since the 2004 classification. *J Thorac Oncol* 10(9):1243

Key Signs

- Patchy areas of non-resolving consolidation (➔) with possible halo sign and often with air bronchogram or air-filled cystic spaces (bubble-like lucencies) (○)
- Patchy non-resolving ground-glass opacity (↘)

Distribution

Unilateral or bilateral, usually asymmetrical, and often patchy. The consolidation may be segmental or may involve an entire lobe or lung. Often peripheral distribution. Possible lower lung predominance.



Bubble-like lucencies are small lucencies inside consolidations (pseudocavitation). They can be formed by a valve mechanism by bronchiolar obstruction or by desmoplastic bronchiolar traction or paracatricial emphysema. Also, lucency can result from spared pulmonary lobules (please also refer to Bubble-like lucencies in the “Case-Based Glossary with Tips and Tricks”).

The stretching, sweeping, and widening of branching air-filled bronchi within an area of consolidation on computed tomography (CT) favor the diagnosis of cancer instead of pneumonia.



Areas of ground-glass attenuation and consolidation often have straight and angulated margins, suggesting demarcation by interlobular septum at the margin of the secondary pulmonary lobule. A halo sign may be present around the consolidation due to lepidic growth.



Patsios D (2007) Pictorial review of the many faces of bronchioloalveolar cell carcinoma. *Br J Radiol* 80(960):1015

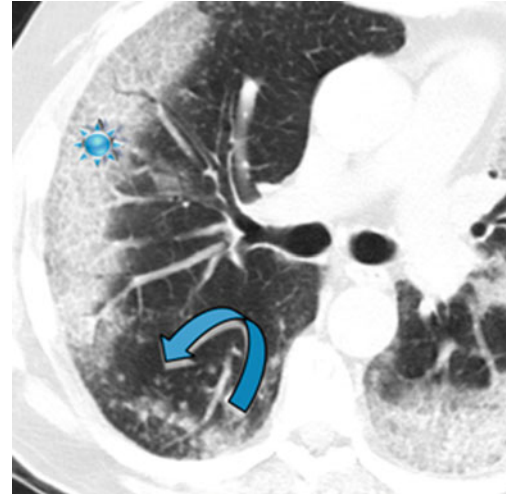
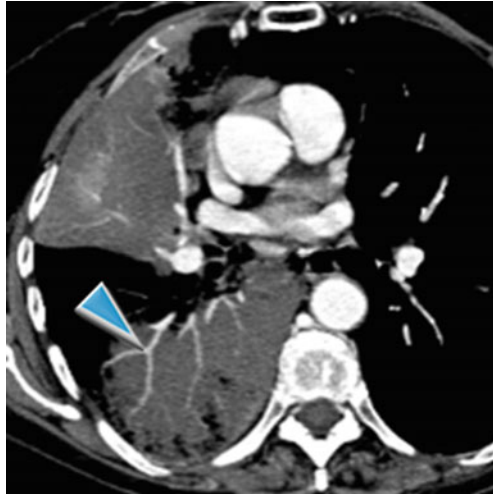
Gaeta M (1999) Radiolucencies and cavitation in bronchioloalveolar carcinoma: CT-pathologic correlation. *Eur Radiol* 9(1):55

Ancillary Signs

- Low-density consolidation with angiogram sign on contrast-enhanced CT (▶)
- Crazy paving (★)

Non-parenchymal Signs

- Centrilobular or feeding vessel nodules due to the aerogenous or hematogenous intrapulmonary spread of the tumoral cells (↔)
- Consolidation and/or nodules with halo sign (lepidic growth)
- Pleural effusion (10%)
- Lymph node enlargement



Usually, inflammatory angiogram sign, pseudocavitation, and crazy paving are more frequent in adenocarcinoma than in consolidation.

CT angiogram sign may be visible because fluid and mucus produced by the tumor are of low attenuation if CT is performed with contrast infusion. This sign may be also observed in bacterial pneumonia, lipid pneumonia, pulmonary lymphoma, and metastasis of gastrointestinal adenocarcinomas (please also refer to Angiogram sign in the “Case-Based Glossary with Tips and Tricks”).



Diffuse lung involvement may represent multifocal origin, endobronchial spread of tumor from primary focus, hematogenous metastases, or a combination of these.



Jung JI (2001) CT differentiation of pneumonic-type bronchioloalveolar cell carcinoma and infectious pneumonia. *Br J Radiol* 74(882):490

Piacibello E (2015) Lung cancer: one issue, many faces. *ECR C-2202*

Course

- Slow progression with continuous growth of neoplastic cells (lepidic growth).
- Intrapulmonary discontinuous spread of neoplastic cells through airspaces and airways; the discontinuous foci may be seen close to primary tumor as satellite foci or at distance, including the contralateral lung (aerogenous metastases).
- The discontinuous spread of neoplastic cells through lymphatic vessels can cause intrapulmonary metastasis along the lymphatic vessels or locoregional metastasis to the lymph nodes (lymphatic metastases).
- The discontinuous spread of neoplastic cells through blood vessels can cause intrapulmonary and systemic metastases (hematogenous metastases).



Gaikwad A (2014) Aerogenous metastases: a potential game changer in the diagnosis and management of primary lung adenocarcinoma. *AJR Am J Roentgenol* 203(6):W570

Warth A (2015) Prognostic impact of intra-alveolar tumor spread in pulmonary adenocarcinoma. *Am J Surg Pathol* 39:793

Kadota K (2015) Tumor spread through air spaces is an important pattern of invasion and impacts the frequency and location of recurrences after limited resection for small stage I adenocarcinomas. *J Thorac Oncol* 10:806

Definition

The criteria for acute exacerbation (AE) of IPF include an unexplained worsening of dyspnea within 1 month, evidence of hypoxemia as defined by worsened or severely impaired gas exchange, new radiographic infiltrates, and an absence of an alternative cause of disease. Surgical lung biopsy or even surgical procedures in organs other than the lungs may also trigger AE. The annual incidence of AE-IPF is typically reported at 5–15%. The histologic findings consist of diffuse alveolar damage (DAD) or, less commonly, prominent organizing pneumonia (OP) superimposed on the UIP pattern.



AE-IPF, accelerated phase



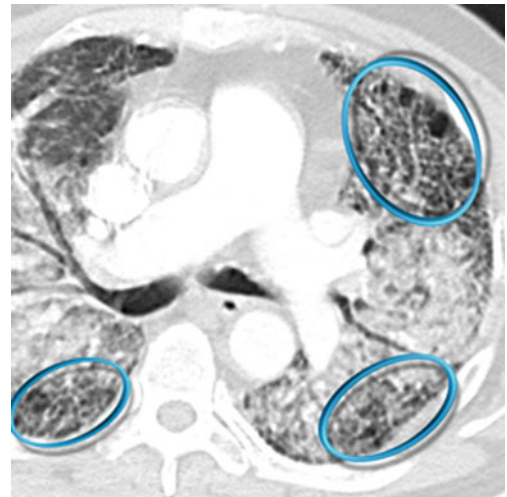
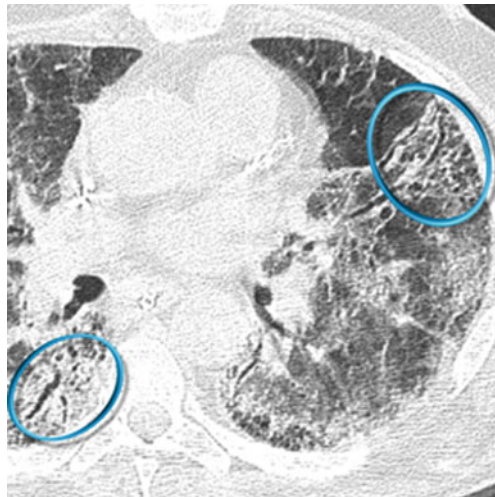
Collard HR (2007) Acute exacerbations of idiopathic pulmonary fibrosis. *Am J Respir Crit Care Med* 176(7):636

Key Signs

- Diffuse ground-glass opacity (GGO) is the dominant sign.
- Sometimes also consolidations can be visualized.
- Signs of fibrosing lung disease (●): fibrosing subpleural reticulation, traction bronchiectases, and honeycomb change typical of UIP pattern.

Distribution

Often bilateral and diffuse with possible multifocal and peripheral distribution. The consolidations tend to involve mainly the dorsal half of the lung.



Acute exacerbation is essentially a diagnosis of exclusion. Differential diagnoses include concomitant infection (such as *P. jirovecii* pneumonia or *Cytomegalovirus* infection), pulmonary edema due to left ventricular failure, pulmonary embolism, and pneumothorax.

When it is necessary to exclude the diagnosis of pulmonary thrombo-embolic disease with a CT pulmonary angiogram (CTPA), intravenous contrast enhancement increases the attenuation of the background lung parenchyma, which can complicate the evaluation of whether the lungs are of abnormally increased attenuation. In this situation, interspaced HRCT sections should be obtained prior to the acquisition of the contrast-enhanced CTPA.

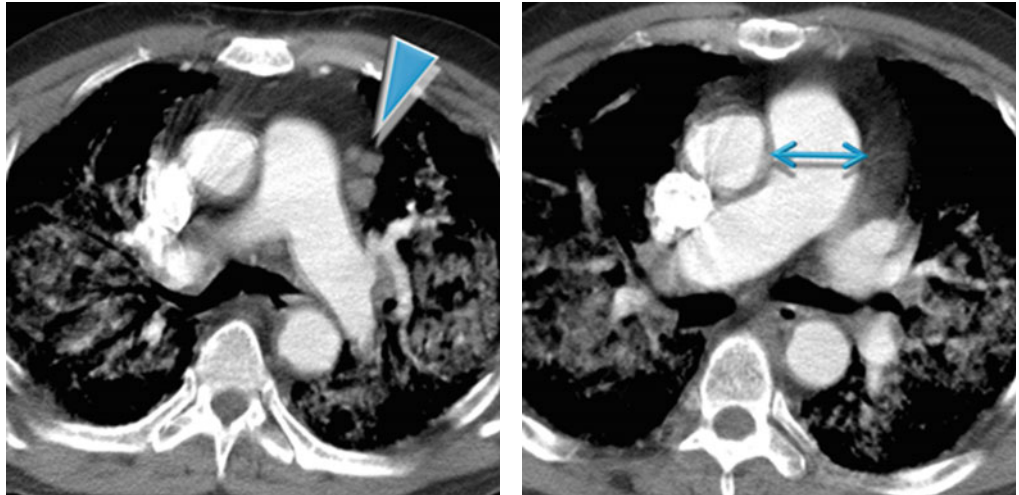


Akira M (2008) Computed tomography findings in acute exacerbation of idiopathic pulmonary fibrosis. *Am J Respir Crit Care Med* 178(4):372

Lloyd CR (2011) High-resolution CT of complications of idiopathic fibrotic lung disease. *Br J Radiol* 84(1003):581

Ancillary Signs**Non-parenchymal Signs**

- Crazy paving
- Lymph node enlargement (▶).
- Pulmonary arterial hypertension: enlargement of the main (↔) and proximal pulmonary arteries; however, normal-sized pulmonary arteries do not exclude the diagnosis.



Antoniou KM (2013) Acute exacerbations of idiopathic pulmonary fibrosis. *Respiration* 86(4):265

Luppi F (2015) Acute exacerbation of idiopathic pulmonary fibrosis: a clinical review. *Intern Emerg Med* 10(4):401

Course

- Patients with acute exacerbation have a poor prognosis with mortality exceeding 50% despite therapy.
- Survival may be related to the degree of CT involvement. The extent of disease is a more important determinant of outcome than the distribution of disease.
- AE represents the most frequent cause of rapid deterioration requiring hospitalization of IPF patients.



AE have been reported in ILDs other than IPF, including nonspecific interstitial pneumonia (NSIP), chronic hypersensitivity pneumonitis (HP), and ILD associated with connective vascular disease (CVD), particularly rheumatoid arthritis.



Fujimoto K (2012) Acute exacerbation of idiopathic pulmonary fibrosis: high-resolution CT scores predict mortality. *Eur Radiol* 22(1):83

Park IN (2007) Acute exacerbation of interstitial pneumonia other than idiopathic pulmonary fibrosis. *Chest* 132(1):214

Definition

Acute eosinophilic pneumonia is an acute severe febrile illness associated with rapidly increasing respiratory failure. The diagnosis is based on clinical findings and the presence of markedly elevated numbers of eosinophils in BAL fluid. The majority of cases are idiopathic; occasionally, it may result from drug reaction or toxic inhalation. Patients respond rapidly to high doses of corticosteroids, usually within 24–48 h. The principal histologic finding in AEP is diffuse alveolar damage (DAD) associated with interstitial and alveolar eosinophilia.



AEP



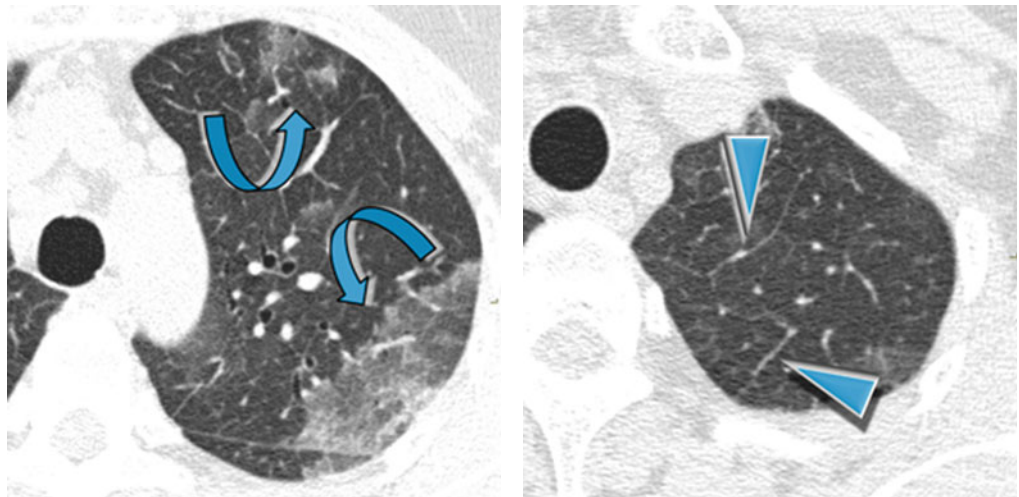
Philitt F (2002) Idiopathic acute eosinophilic pneumonia: a study of 22 patients. *Am J Respir Crit Care Med* 166(9):1235

HIGH-RESOLUTION CT: HRCT**Key Signs**

- Areas of ground-glass opacity (GGO) (↘)
- Smooth interlobular septal thickening (▶)

Distribution

Bilateral, patchy in a random or peripheral distribution, no zonal predominance



Given that initial peripheral blood eosinophil counts are usually normal, therefore developing a clinicroadiologic differential diagnosis for AEP is often difficult.

The radiologic differential diagnosis for AEP includes hydrostatic pulmonary edema (PE), acute respiratory distress syndrome (ARDS) or acute interstitial pneumonia (AIP), and atypical bacterial or viral pneumonia. In contrast to these forms, patients with AEP usually have a dramatic response to corticosteroids, with rapid resolution of clinical signs and symptoms and radiographic abnormalities.

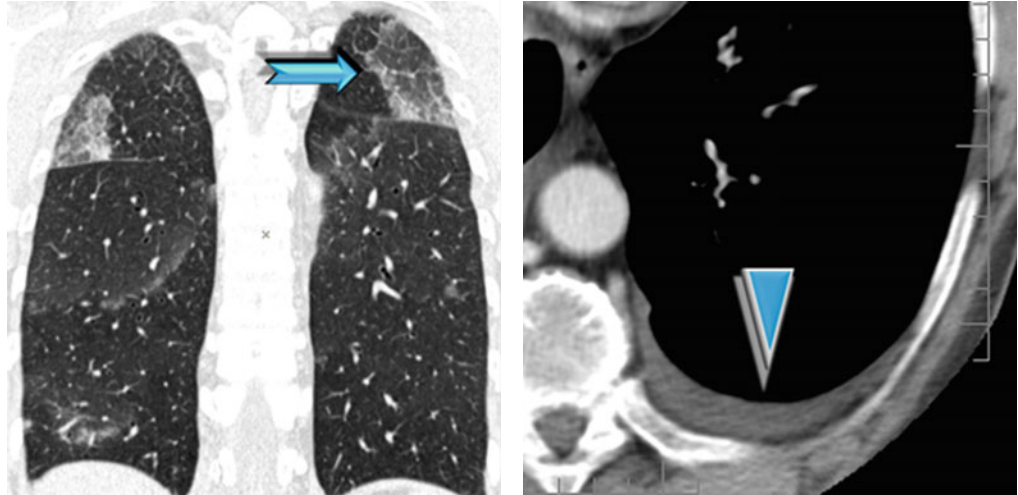


Obadina ET (2013) Acute pulmonary injury: high-resolution CT and histopathological spectrum. *Br J Radiol* 86 20120614

Jeong YJ (2007) Eosinophilic lung diseases: a clinical, radiologic, and pathologic overview. *Radiographics* 27(3):617

Ancillary Signs**Non-parenchymal Signs**

- Possible crazy paving (➡) and consolidations
- Poorly defined centrilobular nodules and thickening of bronchovascular bundles
- Small pleural effusion is present in the majority of patients (▶), absent cardiomegaly.



Peripheral blood eosinophilia is often absent in contrast to chronic eosinophilic pneumonia. Eosinophilia on BAL (>25 % eosinophils) or lung biopsy is the key for diagnosis; however, eosinophils are exquisitely sensitive to corticosteroids and may disappear from blood-stream and BAL fluid within few hours after administration of corticosteroids.



Cottin V (2016) Eosinophilic lung diseases. Clin Chest Med 37:535

Daimon T (2008) Acute eosinophilic pneumonia: thin-section CT findings in 29 patients. Eur J Radiol 65(3):462

Course

- Complete response to corticosteroids: no relapse after discontinuation of corticosteroids

Definition

Acute interstitial pneumonia is a term used for an idiopathic form of acute lung injury characterized clinically by acute respiratory failure with bilateral lung infiltrates and histologically by diffuse alveolar damage (DAD). The *acute, exudative phase* shows edema, hyaline membranes, and acute interstitial inflammation. In the *subacute, proliferative (organizing) phase*, the fibroblast proliferation mainly becomes prominent. In the *chronic, fibrotic phase*, 2 weeks or more after the injury, there is progressive fibrosis. The acute presentation and the histologic features are identical with those of DAD, so AIP has also referred to as idiopathic DAD. The average age at presentation is 50–60 years. It has no gender predominance and no association with cigarette smoking. It is classified among the idiopathic interstitial pneumonias.



AIP, Hamman–Rich syndrome, idiopathic DAD



The general term idiopathic interstitial pneumonias (IIPs) includes various diseases. The major IIPs include idiopathic pulmonary fibrosis (IPF), idiopathic nonspecific interstitial pneumonia (NSIP), desquamate interstitial pneumonia (DIP), acute interstitial pneumonia (AIP), respiratory bronchiolitis–interstitial lung disease (RB-ILD), and cryptogenic organizing pneumonia (COP). Rare idiopathic interstitial pneumonias include idiopathic lymphoid interstitial pneumonia (LIP) and idiopathic pleuroparenchymal fibroelastosis (PPFE).



Travis WD (2013) An official American Thoracic Society/European Respiratory Society statement: update of the international multidisciplinary classification of the idiopathic interstitial pneumonias. *Am J Respir Crit Care Med* 188(6):733

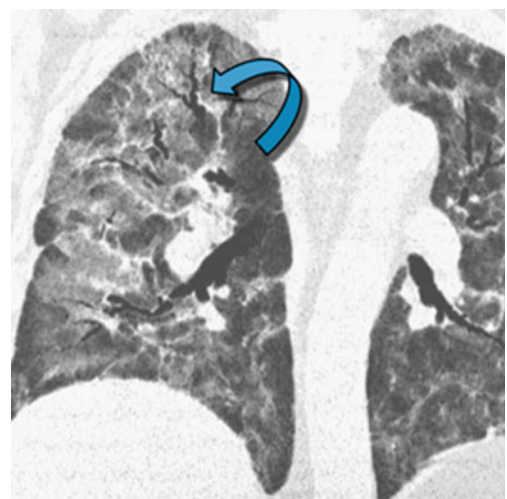
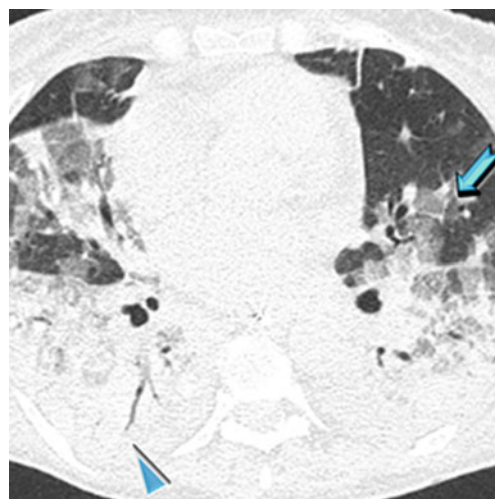
HIGH-RESOLUTION CT: HRCT**Key Signs**

The HRCT findings are strictly correlated to the pathologic phases of DAD:

- *Acute or exudative phase* (first week): extensive ground-glass opacities (➔) and/or airspace consolidation with air bronchogram (▶)
- *Proliferative phase* (second week): within areas of GGO and consolidation, the appearance of distortion of the architecture, volume loss, traction bronchiectases (↘), and bronchiolectases

Distribution

Patchy (geographic) or confluent and tends to involve mainly the dependent lung



Traction bronchiolectases or bronchiectases within areas of increased attenuation on HRCT scan is a sign of progression from the exudative to the proliferative and fibrotic phase.



Patients with greater extent of ground-glass attenuation or airspace consolidation without traction bronchiectases or bronchiolectases on HRCT scan have been shown to have a better prognosis than patients with greater extent of increased attenuation with traction bronchiectases or bronchiolectases.



Mukhopadhyay S (2012) Acute interstitial pneumonia (AIP): relationship to Hamman-Rich syndrome, diffuse alveolar damage (DAD), and acute respiratory distress syndrome (ARDS). *Semin Respir Crit Care Med* 33(5):476

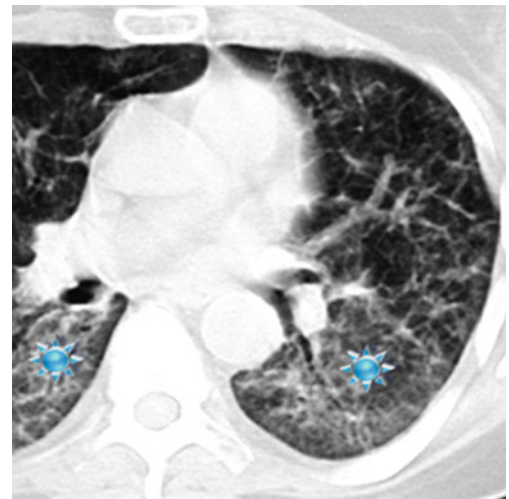
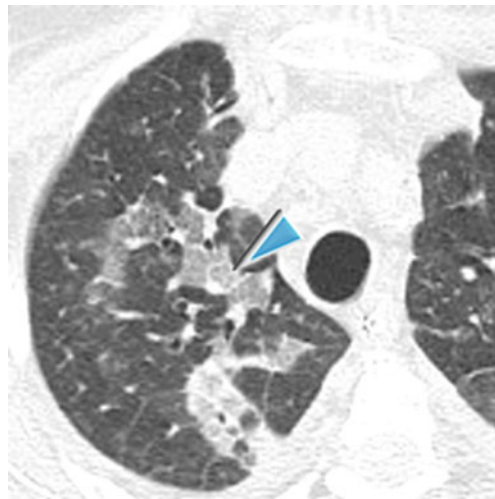
Ichikado K (2014) High-resolution computed tomography findings of acute respiratory distress syndrome, acute interstitial pneumonia, and acute exacerbation of idiopathic pulmonary fibrosis. *Semin Ultrasound CT MR* 35(1):39

Ancillary Signs

- Smooth septal thickening
- Crazy paving (▶)

Non-parenchymal Signs

- Absent



Although the HRCT findings of AIP and ARDS reflect the presence of DAD and therefore overlap, patients with AIP are more likely to have a symmetric lower lobe distribution of abnormalities and a greater prevalence of honeycombing.



Tomiyama N (2001) Acute respiratory distress syndrome and acute interstitial pneumonia: comparison of thin-section CT findings. *J Comput Assist Tomogr* 25(1):28

Course

- The prognosis is poor, with the majority of studies reporting a mortality ranging from 50 to 100%.
- In the surviving patients, HRCT may show mild residual fibrotic features (fibrosing reticulation, architectural distortion, fibrotic GGO) (please see the figure above ★) and possible mild honeycombing.



Akira M (1999) Computed tomography and pathologic findings in fulminant forms of idiopathic interstitial pneumonia. *J Thorac Imaging* 14:76

Definition

Acute respiratory distress syndrome (ARDS) is a syndrome characterized by diffuse lung injury and progressive dyspnea and hypoxemia over a short time. The clinical criteria of acute lung injury or ARDS defined by the American-European Consensus Conference in 1994 have been revised as the Berlin definition in 2012. According to this latest definition, the diagnosis is based on the onset of hypoxemia and of bilateral chest opacities within 1 week of a known risk factor. From the radiological point of view, the presence of bilateral opacities remains one of the hallmarks for diagnosis. However, it was explicitly recognized that these findings could be detected by computed tomography (CT) instead of radiography.

Pathologically, ARDS is characterized by diffuse alveolar damage (DAD) and evolves over 2 or 3 weeks through exudative, fibroproliferative phases.



ARDS



ARDS Definition Task Force (2012) Acute respiratory distress syndrome: the Berlin definition. *JAMA* 307(23):2526

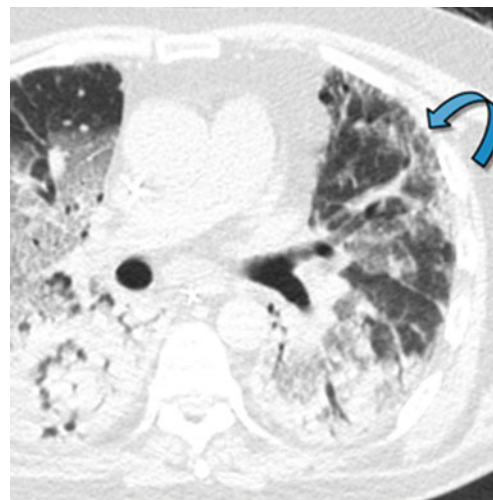
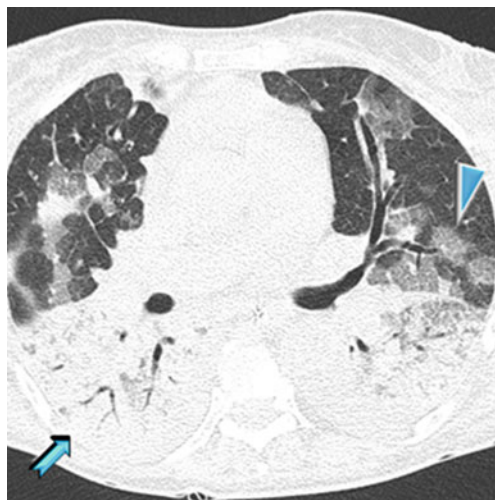
HIGH-RESOLUTION CT: HRCT**Key Signs**

The HRCT findings closely correlate to pathologic phases of DAD:

- *Acute or exudative phase* (first week): HRCT may be normal in the early phase of DAD but is usually abnormal within 12 h with extensive ground-glass opacities (▶) and/or airspace consolidation with air bronchogram (➡).
- *Proliferative phase* (second week): distortion of the architecture, volume loss, fibrosing reticulation, traction bronchiectases or bronchiolectases (↘), and honeycombing represent signs of early fibrosis.

Distribution

Bilateral, diffuse with a gravity-dependent gradient, with larger areas of consolidation in the posterobasal regions, as a result of compressive gravitational forces



Ichikado K (2014) High-resolution computed tomography findings of acute respiratory distress syndrome, acute interstitial pneumonia, and acute exacerbation of idiopathic pulmonary fibrosis. *Semin Ultrasound CT MR* 35(1):39

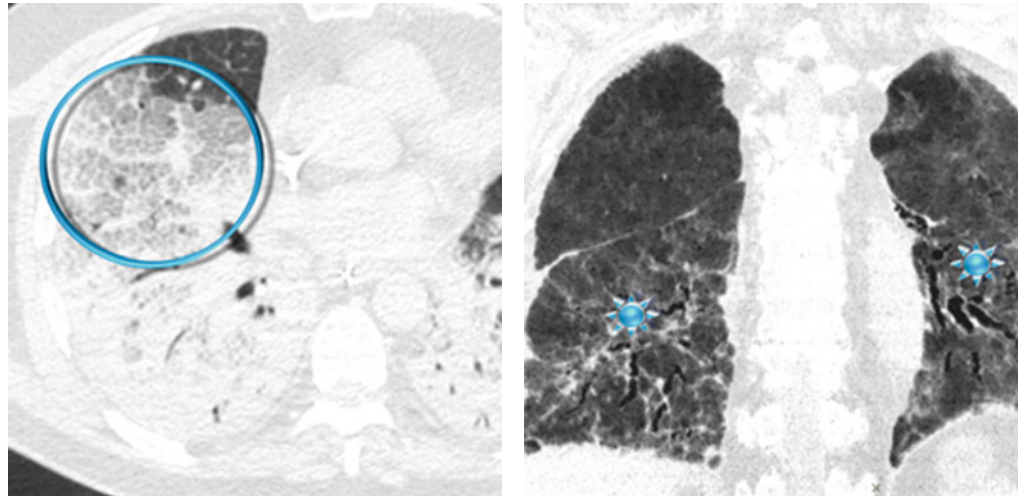
Zompatori M (2014) Overview of current lung imaging in acute respiratory distress syndrome. *Eur Respir Rev* 23(134):519

Ancillary Signs

- Reticular opacities
- Crazy paving (⊙)

Non-parenchymal Signs

- Small pleural effusion (less representative than decompensated heart failure)



In the *early stage* of disease (*exudative phase*), reticular opacities and crazy paving correspond histologically to alveolar collapse adjacent to interlobular septa and subsequent organization or correspond to edematous thickening.

In the *proliferative and fibrotic phase* (see Course below), reticulation is fibrosis (see figure with ★ above) with associated distorted parenchyma.



The differential diagnosis of ARDS includes cardiogenic pulmonary edema, acute interstitial pneumonia (AIP), diffuse alveolar hemorrhage (DAH), and acute eosinophilic pneumonia (AEP); however, the most challenging differential diagnosis is still between ARDS and cardiogenic edema, especially in the acute phase.



Ellen L (2014) Detection of fibroproliferation by chest high-resolution CT scan in resolving ARDS. *Chest* 146(5):1196–1204.

Course

- In surviving patients in the later stages, CT may usually demonstrate progressive regression of opacities with complete healing of lesions.
- A rarer evolution is progressive lung fibrosis (*fibrotic phase*): fibrosing reticulation, architectural distortion, fibrotic GGO (please see the figure above ★), and possible mild honeycombing.
- Early signs of barotrauma often correspond to interstitial emphysema and subpleural cystic airspaces. Subsequently, imaging studies can demonstrate the development of pneumomediastinum, pneumothorax (often hypertensive in mechanically ventilated patients), and subcutaneous emphysema.
- Superimposed cardiac failure, pneumonia, pulmonary embolism, ventilator-induced lung injury, malposition of tubes, central venous catheters, and drainages or other conditions may suddenly worsen the clinical evolution.



Obadina ET (2013) Acute pulmonary injury: high-resolution CT and histopathological spectrum. *Br J Radiol* 86(1027):20120614

Desai SR (1999) Acute respiratory distress syndrome: CT abnormalities at long-term follow-up. *Radiology* 210:29

Definition

Chronic eosinophilic pneumonia (CEP) is an idiopathic condition characterized by an abnormal accumulation of eosinophils in the lungs. The clinical course lasts more than 1–3 months. Most patients are middle aged, and approximately 50 % have asthma.

CEP is almost always associated with increased numbers of eosinophils on BAL fluid and in peripheral blood. Radiologically, CEP is characterized by peripheral unresolving or migrating pneumonia.



CEP



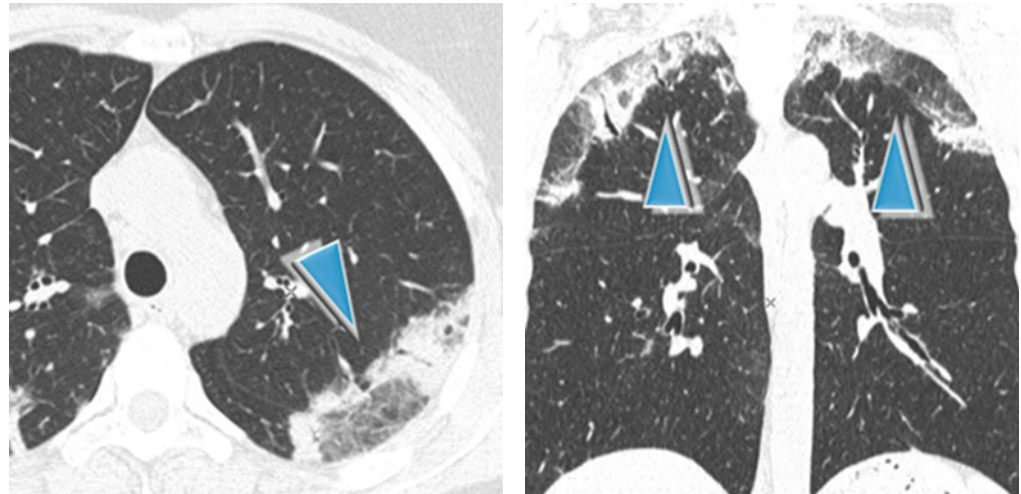
Alam M (2007) Chronic eosinophilic pneumonia: a review. *South Med J* 100(1):49

Key Signs

- Non-resolving airspace consolidations and ground-glass opacities are often associated (▶) with changing in location over a matter of weeks.

Distribution

Peripheral in almost all cases (so-called reverse batwing sign or photographic negative shadow of pulmonary edema), mainly the upper lobes, patchy or confluent



In CEP, the distribution of opacities is identical to that in Löffler syndrome, although in the latter, the lung opacities are self-limited. Also in COP, alveolar sarcoidosis, infarcts, and contusions consolidations can be seen in peripheral airspace (please also refer to Reverse batwing sign in the “Case-Based Glossary with Tips and Tricks”).

Spontaneous migration of the opacities can be present in both CEP and OP.



Yeong YJ (2007) Eosinophilic lung diseases: a clinical, radiologic, and pathologic overview. *Radiographics* 27(3):617

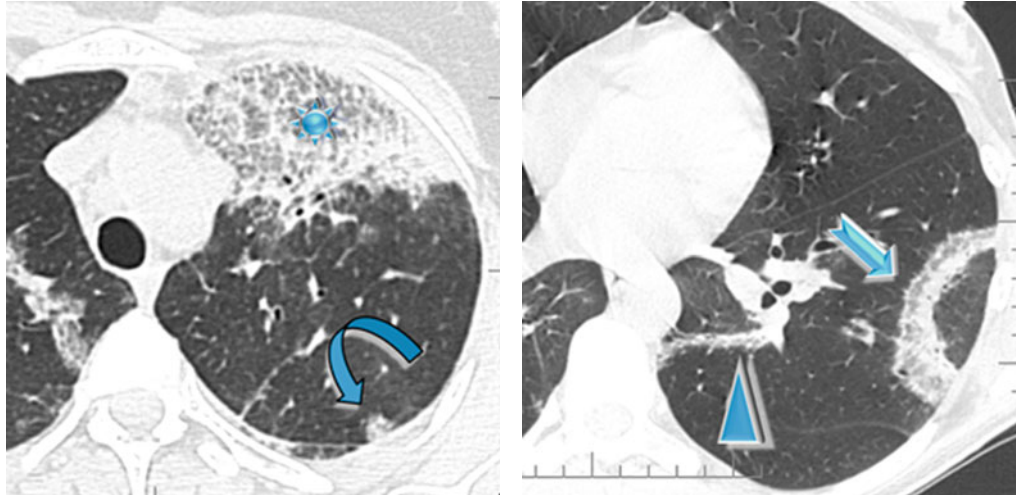
Ebara H (1994) Chronic eosinophilic pneumonia: evolution of chest radiograms and CT features. *J Comput Assist Tomogr* 18(5):737

Ancillary Signs

- Crazy paving (✱)
- Low-density (subsolid) nodules (20 %) with hazy contours (20 %) (↪)
- Reversed halo sign (atoll sign), rarely (➡)
- Linear bandlike opacities seen during resolution (▶)

Non-parenchymal Signs

- Pleural effusion (<10%)
- Mediastinal lymph node enlargement



The diagnosis of eosinophilic pneumonia relies on both characteristic clinical imaging features and demonstration of alveolar eosinophilia. Lung biopsy is generally not necessary for the diagnosis of eosinophilic pneumonia.



An identical appearance to that of CEP may be seen in patients who have simple pulmonary eosinophilia (Löffler syndrome) and in patients with Churg–Strauss syndrome (CSS).

An identical appearance of peripheral consolidations can be seen in OP. In this disease, the lesions are not only confined to the lung periphery but are also bronchocentric and often predominate in the lower lobes. In addition, a macronodular appearance or a pattern of round opacities is frequent. Septal thickening or parenchymal bands are uncommon.



Sano S (2009) Chronic eosinophilic pneumonia: a case report and review of the literature. *Cases J* 2:7735

Cottin V (2012) Eosinophilic lung diseases. *Immunol Allergy Clin North Am* 32(4):557

Course

- Response to steroid treatment is generally dramatic with improvement of symptoms within 24 h and clinical and radiological remission within 3 weeks.
- Progression to diffuse lung fibrosis is rare.
- The disease tends to recur frequently after discontinuation of steroid treatment (75%).
- During regression, consolidation tends to disappear centrifugally and may be temporarily followed by subpleural curvilinear bands. If the disease is left untreated, the opacities may progressively increase in number and even migrate.



Oyama Y (2015) Efficacy of short-term prednisolone treatment in patients with chronic eosinophilic pneumonia. *Eur Respir J* 45(6):1624

Definition

Cryptogenic organizing pneumonia (COP) is the idiopathic form of organizing pneumonia. OP is a well-known histopathologic pattern characterized by loose plugs of proliferating fibroblasts and myofibroblasts within the alveolar ducts and airspaces, accompanied by varying degrees of bronchiolar involvement. COP is classified among the idiopathic interstitial pneumonias (IIPs). Patients with COP typically present with a 2–4-month history of nonproductive cough, low-grade fever, malaise, and shortness of breath. The mean age of presentation is 50–60 years.



COP, idiopathic OP/BOOP



The general term idiopathic interstitial pneumonias (IIPs) includes various diseases. The major IIPs include idiopathic pulmonary fibrosis (IPF), idiopathic nonspecific interstitial pneumonia (NSIP), desquamative interstitial pneumonia (DIP), acute interstitial pneumonia (AIP), respiratory bronchiolitis–interstitial lung disease (RB-ILD), and cryptogenic organizing pneumonia (COP). Rare idiopathic interstitial pneumonias include idiopathic lymphoid interstitial pneumonia (LIP) and idiopathic pleuroparenchymal fibroelastosis (PPFE).



OP may also be a reaction pattern associated with infection, connective diseases, drugs, inflammatory bowel disease, inhalation injury, hypersensitivity pneumonitis, malignancy, radiation therapy, and aspiration.



Travis WD (2013) An official American Thoracic Society/European Respiratory Society statement: update of the international multidisciplinary classification of the idiopathic interstitial pneumonias. *Am J Respir Crit Care Med* 188(6):733

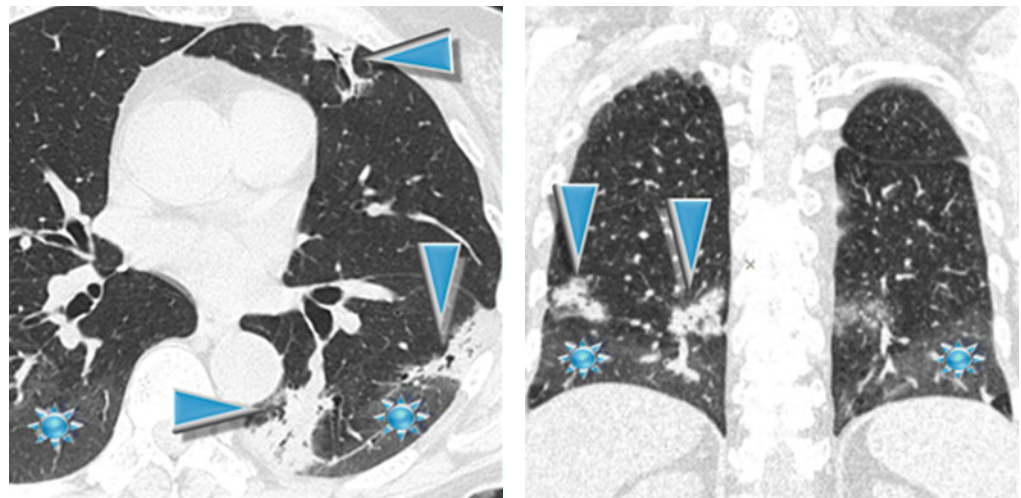
Key Signs

HIGH-RESOLUTION CT: HRCT

- Multifocal patchy consolidations (80–90%) with air bronchogram (▶) changing in location over a matter of weeks
- Ground-glass opacity (★) (60%), usually in association with areas of consolidation

Distribution

Patchy with predominant peribronchial and/or subpleural (60–80%) distribution, often with lower lobe predominance



The subpleural distribution is also defined as “reverse batwing sign” (please also refer to this sign in the “Case-Based Glossary with Tips and Tricks”).

The predominant subpleural distribution together with migration over time and spontaneous regression of consolidation are important pointers, which are also possible in CEP. A peribronchial distribution of consolidations is more frequently observed in COP than in CEP (29% vs. 9%). The most helpful distinguishing feature on CT was the presence of nodules, seen in about 30% of patients with COP and rarely (5%) in patients with CEP.



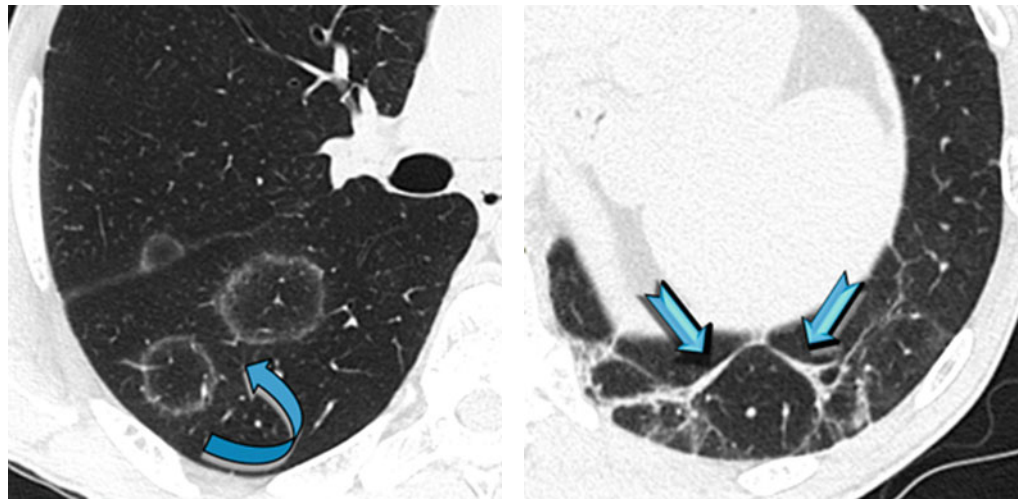
Arakawa H (2001) Bronchiolitis obliterans with organizing pneumonia versus chronic eosinophilic pneumonia: high-resolution CT findings in 81 patients. *AJR Am J Roentgenol* 176(4):1053

Ancillary Signs

- Reversed halo sign (also defined as the atoll sign) (↪) in 20 % of patients
- Perilobular sign (60 %) (➡)
- Crazy paving
- Bandlike opacities
- Low-density (subsolid) nodules (30–50 %)
- Large nodules or masses

Non-parenchymal Signs

- Possible mediastinal lymph node enlargement (20–40 %)
- Small uni- or bilateral pleural effusion (10–30 %)



The reversed halo sign, also known as the atoll sign, is characterized by a central ground-glass opacity surrounded by a more or less complete ring of consolidation (please also refer to the Reverse halo sign in the “Case-Based Glossary with Tips and Tricks”).

Perilobular pattern appears as poorly defined arcade-like polygonal structures, usually abutting the pleural surface.

Nodules are seen in 32 % of patients with COP and only 5 % of patients with CEP.



Zompatori M (1999) Bronchiolitis obliterans with organizing pneumonia (BOOP), presenting as a ring-shaped opacity at HRCT (the atoll sign). A case report. *Radiol Med* 97(4):308

Robertson BJ (2011) Organizing pneumonia: a kaleidoscope of concepts and morphologies. *Eur Radiol* 21(11):2244

Course

- Two thirds of subjects treated with corticosteroids make a full recovery: most patients recover within several weeks or months, and some respond dramatically with improvements appearing even within 1 or 2 weeks. Only a minority of patients, however, experience spontaneous remission, and about half of those treated relapse when treatment is reduced or discontinued.
- One third of patients have persistent disease which rarely, however, progresses to respiratory failure or death. On the other hand, rare hyperacute forms are possible which rapidly lead to death (accelerated OP).
- The opacities may resolve spontaneously and then form elsewhere, usually more cranially and at times in the contralateral lung (migratory opacities). If left untreated, the disease may progress to permanent damage with fibrosis and bronchiectases.

Definition

Diffuse alveolar hemorrhage (DAH) is defined as the presence of hemoptysis, diffuse alveolar infiltrates, and a drop in hematocrit level; it is one of the manifestations of primary pulmonary vasculitis, among other entities (idiopathic alveolar hemorrhage, collagen vascular diseases, drug reactions, anticoagulation disorders, and other entities).

Granulomatosis with polyangiitis (GPA, former Wegener's granulomatosis, WG) and microscopic polyangiitis (MPA) are the most common causes of DAH, representing 40% of cases. Wegener granulomatosis is the most common among the ANCA-associated vasculitides. It is characterized clinically by the triad of upper airway disease (nasal, oral, or sinus inflammation), lower respiratory tract disease (airway or lung), and glomerulonephritis. The complete triad is often not present at initial presentation. The upper respiratory tract is affected in almost all patients, and the lungs and kidneys are involved in 90% and 80% of patients, respectively.



DAH in GPA (granulomatosis with polyangiitis/ANCA-associated granulomatous vasculitis)



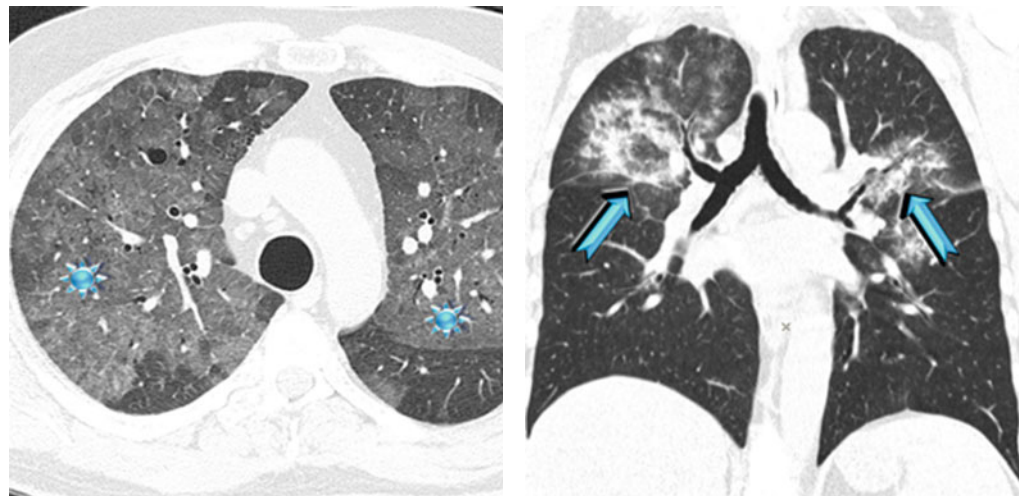
Castañer E (2010) When to suspect pulmonary vasculitis: radiologic and clinical clues. *Radiographics* 30(1):33

HIGH-RESOLUTION CT: HRCT**Key Signs**

- Ground-glass opacity (★)
- Consolidations (➔)

Distribution

Bilateral (even though unilateral predominance is also possible), diffuse, or patchy or lobular predominant in the parahilar region with sparing of the subpleural regions ("butterfly" or "batwing" distribution)



Butterfly or batwing pulmonary opacities are classically described in the chest X-ray but they are best appreciated on CT. Diseases responsible for butterfly pulmonary opacities may have acute or chronic behavior (please refer to Butterfly pulmonary opacities in the "Case-Based Glossary with Tips and Tricks").



The corresponding findings on thin-section CT are nonspecific, with ground-glass opacity as the leading feature without a characteristic distribution. Ill-defined centrilobular nodules may predominate in some patients. The presence of dense consolidation represents complete filling of the alveoli with blood.

Consolidations and ground-glass opacities can occur either in vasculitic pulmonary disease (in form of pneumonitis) or alveolar hemorrhage.



Primack SL (1995) Diffuse pulmonary hemorrhage: clinical, pathologic, and imaging features. *AJR Am J Roentgenol* 164:295.

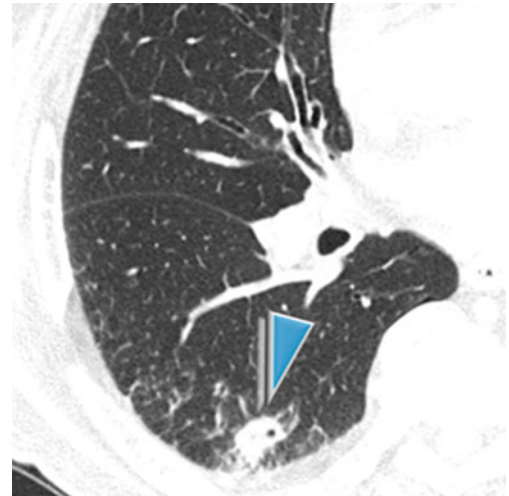
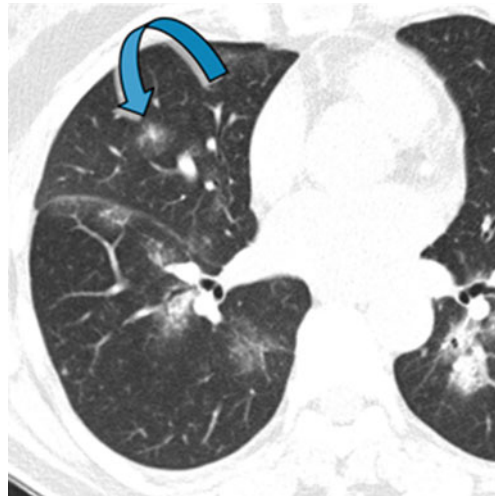
Ananthakrishnan L (2009) Wegener's granulomatosis in the chest: high-resolution CT findings. *AJR Am J Roentgenol* 192(3):676

Ancillary Signs

- Scattered low-density (subsolid) nodules, at times in connection with small vessels (↘).
- Smooth septal thickening and crazy paving.
- Solid macronodules with a diameter varying between 1 and 4 cm, usually bilateral (75%), often cavitated (▶), and with irregular thick walls, macronodules, and masses with ill-defined borders.
- Perinodular halo sign (a rim of ground-glass opacity surrounding the pulmonary lesion) is seen in up to 15% of cases.

Non-parenchymal Signs

- Hilar or mediastinal adenopathy (2–15%)
- Smooth or irregular tracheal stenosis with concentric wall thickening and possible calcifications
- Pleural effusion (less than 10%)



Martinez F (2012) Common and uncommon manifestations of Wegener granulomatosis at chest CT: radiologic-pathologic correlation. *Radiographics* 32(1):51

Course

- The complete clearing of airspace and interstitial opacities usually occurs within 10 days to 2 weeks after an acute episode of hemorrhage. This is considerably slower than the clearing of pulmonary edema, which hemorrhage closely resembles.
- Masses show a decrease in the extent with residual scarring.
- If present, airway lesions show improvement with treatment in most patients.
- After repeated episodes of pulmonary hemorrhage, a persistent reticular pattern may be seen, with areas of peripheral honeycombing and traction bronchiectases.



Chung MP (2010) Imaging of pulmonary vasculitis. *Radiology* 255(2):322

Definition

Desquamative interstitial pneumonia (DIP) is a rare interstitial lung disease, and it is classified among the idiopathic interstitial pneumonias (IIPs). Pathologically, it is characterized by a widespread filling of alveoli with macrophages. Although DIP occurs in nonsmokers, it is strongly associated with cigarette smoking (60–90%). DIP may also occur in association with passive exposure to cigarette smoke, heavy marijuana smoking, occupational dust exposure, drug reaction, collagen vascular disease, leukemia, and infection. DIP occurs most commonly in patients between 35 and 55 years of age. The clinical symptoms usually consist of slowly progressive exertional dyspnea and dry cough.



DIP, alveolar macrophage pneumonia



The general term idiopathic interstitial pneumonias (IIPs) includes various diseases. The major IIPs include idiopathic pulmonary fibrosis (IPF), idiopathic nonspecific interstitial pneumonia (NSIP), desquamative interstitial pneumonia (DIP), acute interstitial pneumonia (AIP), respiratory bronchiolitis–interstitial lung disease (RB-ILD), and cryptogenic organizing pneumonia (COP). Rare idiopathic interstitial pneumonias include idiopathic lymphoid interstitial pneumonia (LIP) and idiopathic pleuroparenchymal fibroelastosis (PPFE).



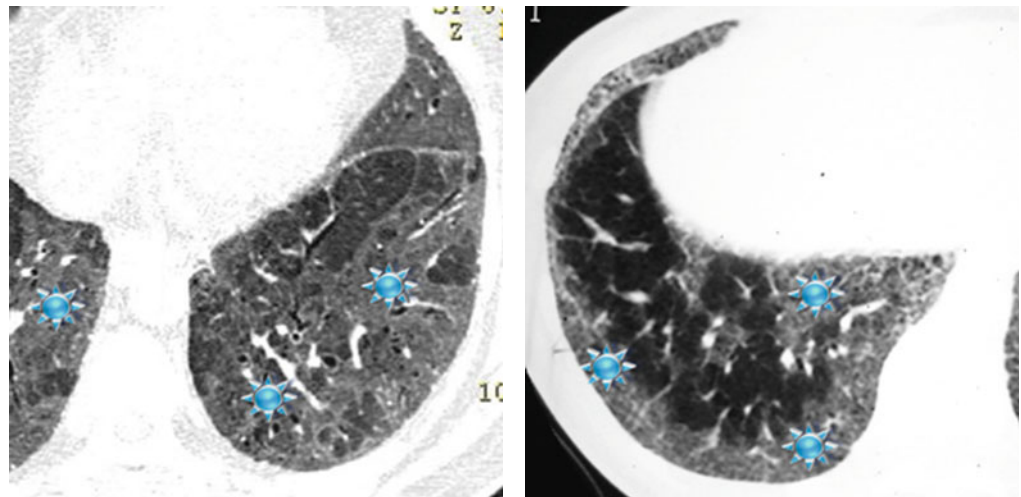
Travis WD (2013) An official American Thoracic Society/European Respiratory Society statement: update of the international multidisciplinary classification of the idiopathic interstitial pneumonias. *Am J Respir Crit Care Med* 188(6):733

HIGH-RESOLUTION CT: HRCT**Key Signs**

Extended areas of ground-glass opacity (GGO) (★)

Distribution

Diffuse, often predominant in the peripheral and subpleural regions, bilateral, and generally symmetrical



Kadoch MA (2015) Idiopathic interstitial pneumonias: a radiology-pathology correlation based on the revised 2013 American Thoracic Society-European Respiratory Society classification system. *Curr Probl Diagn Radiol* 44(1):15

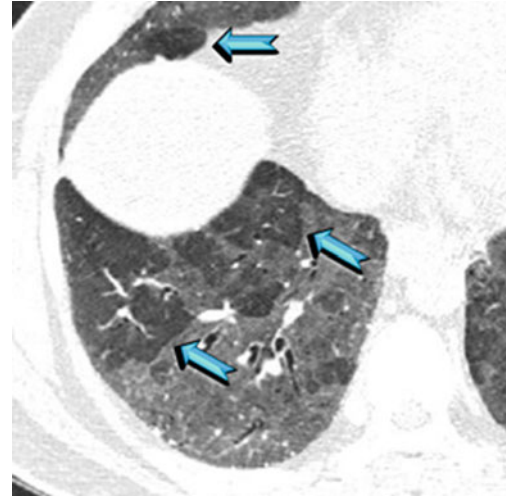
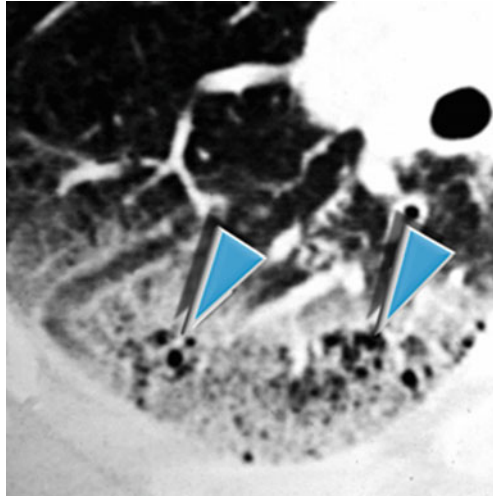
Attili AK (2008) Smoking-related interstitial lung disease: radiologic-clinical-pathologic correlation. *Radiographics* 28(5):1383

Ancillary Signs

- Occasionally smokers with DIP may also have low-density ill-defined centrilobular nodules and tiny air-filled cysts within the areas of ground-glass attenuation probably corresponding to dilated alveolar ducts or foci of emphysema (▶).
- Focal or lobular dark areas are sometimes seen, perhaps representing areas of mosaic perfusion related to bronchiolitis and airway obstruction (▶).
- Reticular opacities, honeycombing, and traction bronchiectases are rare.

Non-parenchymal Signs

- Absent



The presence of centrilobular nodules is due to the considerable overlap between the HRCT findings of RB, RB-ILD, and DIP because these entities are part of the spectrum of the same disease process, representing different degrees of severity of reaction to cigarette smoke.



Park JS (2002) Respiratory bronchiolitis-associated interstitial lung disease: radiologic features with clinical and pathologic correlation. *J Comput Assist Tomogr* 26(1):13

Course

- Follow-up HRCT is variable showing usually a decrease or resolution of the ground-glass opacities, while sometimes it remains stable.
- A progression to severe fibrosis is rare.



Nair A (2014) High-resolution computed tomography features of smoking-related interstitial lung disease. *Semin Ultrasound CT MR* 35(1):59

Hartman TE (1996) Disease progression in usual interstitial pneumonia compared with desquamative interstitial pneumonia. Assessment with serial CT. *Chest* 110(2):378

Definition

There are numerous agents with potential toxic effects on the lungs including cytotoxic and noncytotoxic drugs. Common causes of drug-induced lung disease include amiodarone, antibiotics, nonsteroidal anti-inflammatory drugs, and chemotherapeutic agents. The most common clinical manifestations of patients with pulmonary drug reaction are cough, progressive dyspnea, and fever. These symptoms are nonspecific, and therefore, the diagnosis requires a high index of suspicion by the clinician and the radiologist.

Amiodarone is a tri-iodinated drug used to treat refractory tachyarrhythmia. It accumulates in the lung, largely within macrophages and type 2 pneumocytes, where it forms lamellar inclusion bodies and has a very long half-life.



Nonetheless, it should be noted that drugs may cause different types of lung injury (see Table Drug-induced lung injury: major histopathologic reaction patterns). The HRCT features of drug-induced lung disease usually reflect the histopathologic patterns of reaction. Amiodarone itself may often cause subacute or chronic pattern (OP or NSIP) and sometimes acute (diffuse alveolar damage – DAD/ARDS).



Silva CI (2006) Drug-induced lung diseases: most common reaction patterns and corresponding high-resolution CT manifestations. *Semin Ultrasound CT MR* 27(2):111

HIGH-RESOLUTION CT: HRCT

Key Signs

OP amiodarone-induced pattern is often associated with:

- Patchy consolidations (☞)

NSIP amiodarone-induced pattern is often associated with:

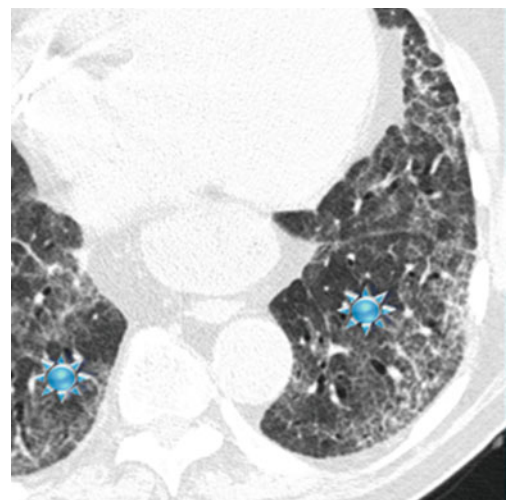
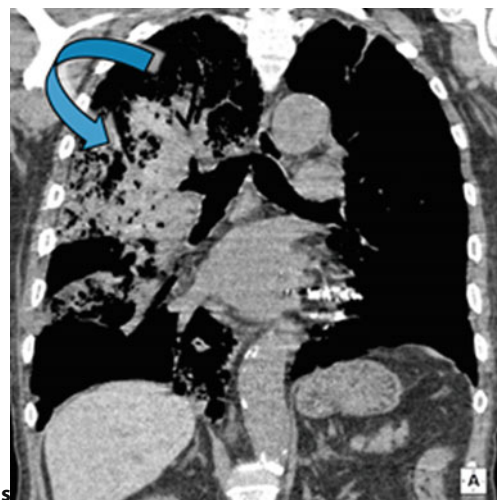
- Ground-glass opacities and fibrosing reticulation (★)

DAD amiodarone-induced pattern may be present in a minority of patients:

- Diffuse GGO (please see the third image below ■) with possible associated consolidations (ARDS-like aspect)

Distribution

- NSIP pattern: diffuse and often peripheral
- OP pattern: patchy
- DAD pattern: diffuse GGO, possibly gravity-dependent consolidation



The presence in the lung of foci of attenuation greater than that of soft tissues may be noted inside areas of consolidation or mass-like opacities. The same aspect may be present in the liver and spleen, related to the accumulation of amiodarone and its metabolites in tissue macrophages. The presence of hyperdensities within the areas of consolidation needs to be differentiated from other diseases (please refer to Hyperdense consolidation in the chapter “Alveolar Pattern”).

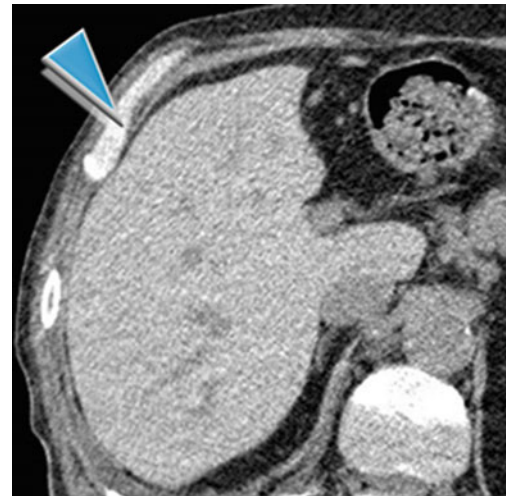
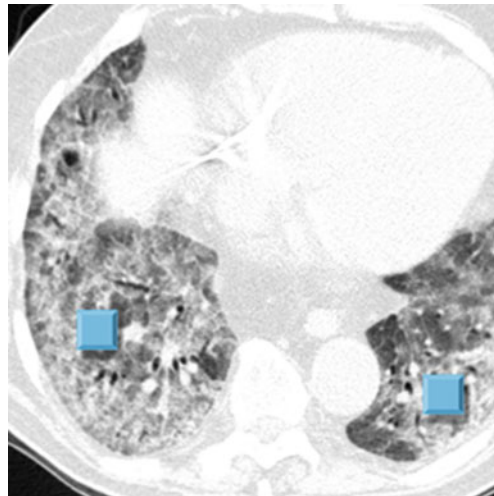
Wolkove N (2009) Amiodarone pulmonary toxicity. *Can Respir J* 16(2):43

Rossi SE (2000) Pulmonary drug toxicity: radiologic and pathologic manifestations. *Radiographics* 20(5):1245

Ancillary Signs

Non-parenchymal Signs

- Nodules/masses (PET positive)
- Crazy paving
- Pleural thickening and pleural effusion (uncommon)
- The hyperdense liver (▶) and spleen (80 %) and heart (20 %)



A minority of patients experience acute, severe lung injury culminating in death. The most dramatic manifestation is a rapidly progressing diffuse pneumonitis with acute respiratory failure and a picture typical of the acute respiratory distress syndrome (ARDS), characterized by diffuse alveolar damage (DAD).

Course

Amiodarone-induced pulmonary fibrosis develops in 5–7% of patients following the amiodarone pneumonitis. On HRCT, there are coarse interstitial fibrosing reticular opacities and traction bronchiectases. Honeycombing is less common than in idiopathic pulmonary fibrosis.

Drug-induced lung injury: major histopathologic patterns	
Acute	Subacute – chronic
Acute eosinophilic pneumonia (AEP)	Chronic interstitial pneumonitis and fibrosis (NSIP or rarely UIP)
Diffuse alveolar damage (DAD/ARDS)	Chronic eosinophilic pneumonia (CEP)
Diffuse alveolar hemorrhage (DAH)	Hypersensitivity pneumonitis (HP)
	Nonspecific interstitial pneumonia (NSIP)
	Organizing pneumonia (OP/BOOP)
	Pulmonary edema (PE)

www.pneumotox.com

Definition

Fat embolism syndrome (FES) is a systemic syndrome due to pulmonary and systemic embolization from fat particles. It is a rare entity, and the most frequent cause is a fracture of a long bone. As a matter of fact, some degree of fat embolism is present in the majority of fractures of the long bones, but the clinical syndrome is not frequent. Most patients are males of young age. The diagnosis is clinical, and the most widely adopted criteria are those from Gurd and Wilson. Diagnosis requires the presence of two major criteria or one major criteria plus four minor. Major diagnostic criteria are cutaneous petechial rash, hypoxemia, and central nervous system involvement. Minor criteria are fever, tachycardia, and laboratory abnormalities such as thrombocytopenia, anemia, jaundice, and high ESR.

From a histopathological point of view, FES is a toxic vasculitis. The most severe cases may develop the ARDS/DAD complex, while in exceptional cases, the syndrome occurs in the fulminating or hyperacute form (with cardiorespiratory collapse).



Mechanical and biochemical pathophysiological mechanisms have been proposed. As a consequence of the fracture, fat globules from the bone marrow can access to the circulation and become embolic, causing pulmonary arterial mechanical obstruction. The accumulation of fat in the pulmonary microvasculature could also cause chemical pneumonitis with perivascular hemorrhage and edema, due to the local liberation of free fatty acids and glycerol with toxic effects to the lung parenchyma.



FES, posttraumatic pulmonary fat embolism



Akhtar S (2009) Fat embolism. *Anesthesiol Clin* 27(3):533

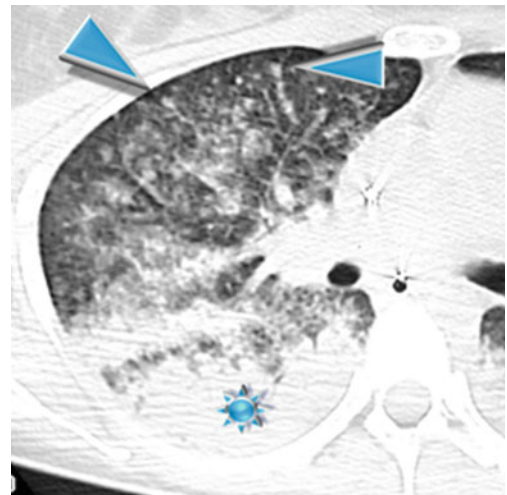
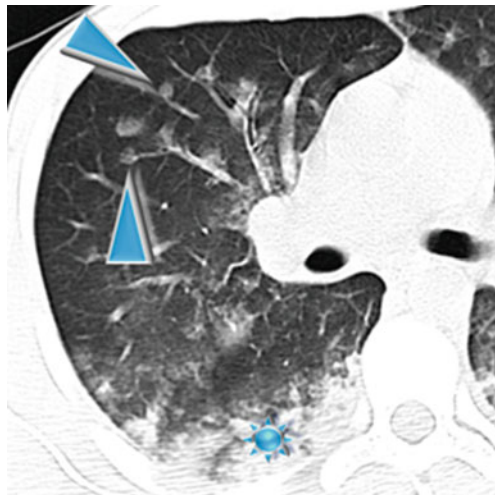
HIGH-RESOLUTION CT: HRCT

Key Signs

- Ground-glass opacities
- Consolidations (★)
- Nodules, often subsolid (GGO nodules) (▶)

Distribution

Pulmonary involvement is always bilateral. Nodules are often centrilobular with possible feeding vessels and subpleural distribution. Both nodules and GGO prevail in the upper lungs, while consolidations show gravity-dependent distribution in the lower lobes.



Malagari K, Economopoulos N, Stoupis C et al (2003) High resolution CT findings in mild pulmonary fat embolism. *Chest* 123(4):1196–1201

Gallardo X (2006) Nodular pattern at lung computed tomography in fat embolism syndrome: a helpful finding. *J Comput Assist Tomogr* 30(2):254–257



Piolanti M, Dalpiaz G (2016) Fat embolism syndrome: lung computed tomography findings in 18 patients. *J Comput Assist Tomogr* 40(3):335–342



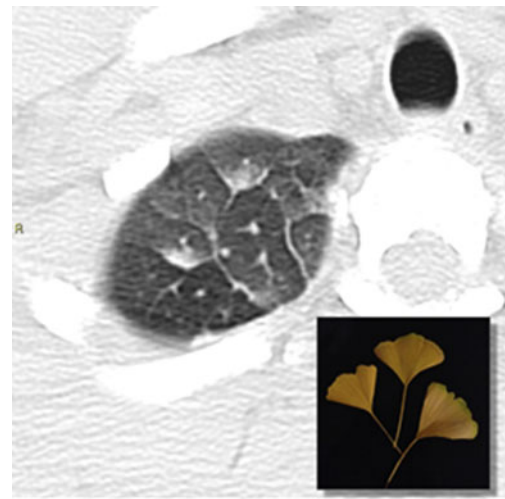
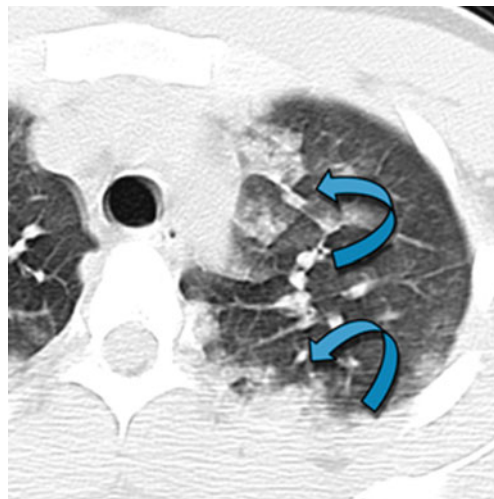
FES is essentially a posttraumatic disease that has to be differentiated from aspiration, contusions, pneumonia, and pulmonary edema. The presence of a nodular pattern is the most suggestive HRCT finding.

Ancillary Signs

- Lobular and sublobular consolidation and GGO (↗)
- Smooth septal thickening
- “Ginkgo biloba sign”

Non-parenchymal Signs

- Pleural effusions (not frequent)
- Macroscopic fat emboli in pulmonary CT angiogram (rare)



In the anterior lung, the combination of smooth septal thickening and lobular/sublobular GGO or consolidations may give rise to an aspect that reminds a ginkgo biloba leaf. We suggest this sign may be called “ginkgo biloba sign” and, like all other signs in thoracic radiology, is unlikely to be specific for FES, but rather it may suggest the presence of hemorrhage and edema.

Note that the sublobular consolidation/GGO may present a gravity-dependent distribution inside the lobes.



FES may be a likely cause for hypoxemia even in trauma patients with fractures and entirely negative imaging studies (chest roentgenogram and CT scan), provided that the chest wall involvement or pulmonary infectious complications have been ruled out.



Trisolini R (2010) Fat embolism may be responsible for hypoxemia in trauma patients with no radiological pulmonary abnormalities. *J Trauma* 68(2):E53

Course and Complications

- Most patients develop only a transitory respiratory failure, requiring only supportive care. A minority of patients develop ARDS, likely due to a combination of factors, not only FE.



Arakawa H (2000) Pulmonary fat embolism syndrome: CT findings in six patients. *J Comput Assist Tomogr* 24(1):24

Newbigin K (2016) Fat embolism syndrome: State-of-the-art review focused on pulmonary imaging findings. *Respir Med* 113:93–100

Definition

Pneumocystis jirovecii pneumonia (PJP) is an opportunistic infection of the lungs. This fungus is common in the environment and rarely causes illness in healthy people. PJP is the most common opportunistic infection in individuals with HIV infection. Pathologically, PJP typically results in the presence of foamy, intra-alveolar exudates. A definitive diagnosis of PJP requires the demonstration of organisms in sputum or BAL fluid.



PJP, *Pneumocystis carinii*, or PCP pneumonia, opportunistic infection



Cushion MT (2010) Stealth and opportunism: alternative lifestyles of species in the fungal genus *Pneumocystis*. *Annu Rev Microbiol* 64:431

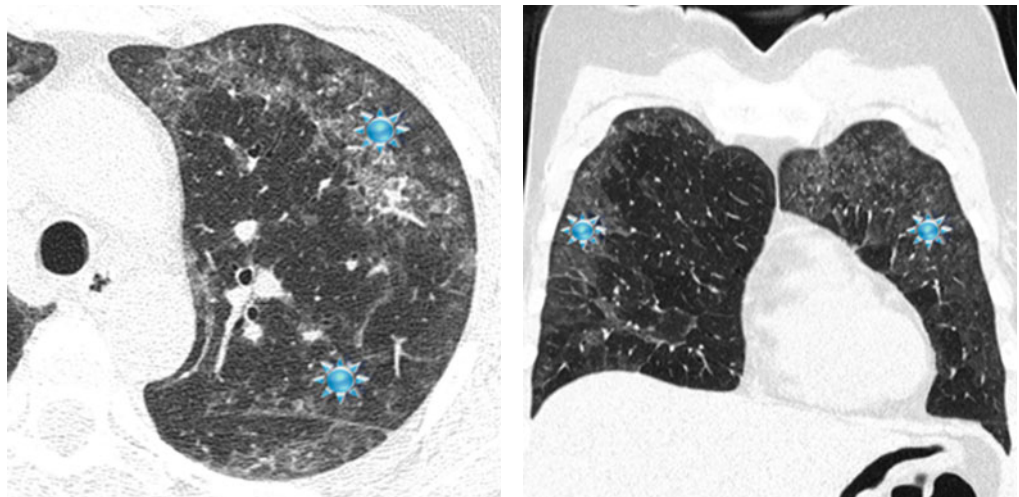
HIGH-RESOLUTION CT: HRCT

Key Signs

- Ground-glass opacities (★)
- Consolidation in patients with more severe disease

Distribution

Symmetric bilateral, diffuse, or patchy (mosaic pattern); the lesions may involve mainly the upper lobes and perihilar regions (butterfly or batwing).



A butterfly or batwing distribution may be also present in other diseases (please also refer to “Butterfly pulmonary opacities” in the “Case-Based Glossary with Tips and Tricks”).

Lung consolidation is more common in patients without HIV infection and tends to develop more rapidly, reflecting pulmonary damage from the host-immune response.

HRCT is useful in patients with suspected *PJP* who have a normal or equivocal chest X-ray finding. A negative HRCT may allow exclusion of *PJP* in such patients.



Sarkar P (2013) Clinical review: respiratory failure in HIV-infected patients – a changing picture. *Crit Care* 17(3):228

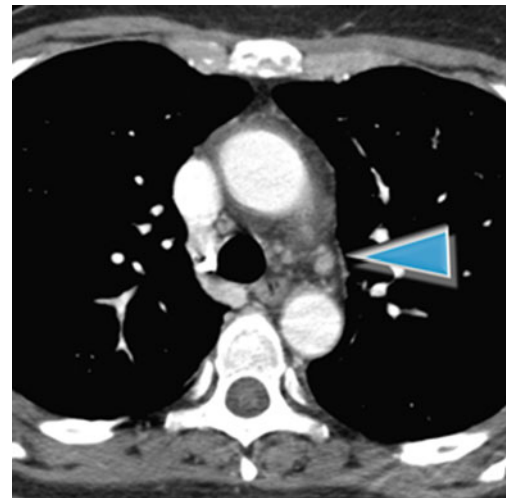
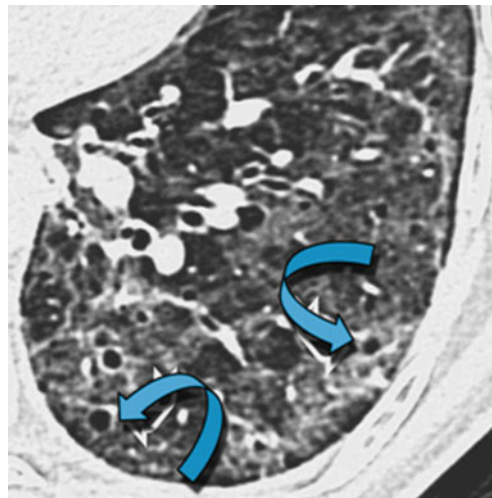
Hardak E (2010) Radiological features of *Pneumocystis jirovecii* Pneumonia in immunocompromised patients with and without AIDS. *Lung* 188(2):159

Ancillary Signs

- Cystic lesions (20–35% in patients with AIDS but only in 3% of non-AIDS immunocompromised patients) (↔)
- Smooth interlobular septal thickening
- Crazy paving
- At times signs of infectious bronchiolitis with tree-in-bud pattern, bronchial wall thickening, and bronchiectases

Non-parenchymal Signs

- Less typical manifestations: centrilobular nodules, large nodules or masses, even cavitated, also cavitated due to granulomatous reaction mimicking carcinoma (↘)
- Small hilar or mediastinal lymph node enlargement, or both, may be seen in approximately 20% of patients (▶)
- Pneumothorax
- Pleural effusion (about 5% of cases)



Pulmonary cysts (especially on upper lobes) of varying shape, size, and wall (complex, occurring in cluster, with an irregular shape) are common.

Cysts are associated with an increased frequency of spontaneous pneumothorax, although the latter can occur in the absence of definable lung cysts.

A reticular pattern associated with ground-glass attenuation is often seen in the subacute phase of the disease. This is the result of interstitial organization of the intra-alveolar exudate.



Kanne JP (2012) Pneumocystis jirovecii pneumonia: high-resolution CT findings in patients with and without HIV infection. *AJR Am J Roentgenol* 198(6):W555

Atwal SS (2014) High resolution computed tomography lung spectrum in symptomatic adult HIV-positive patients in South-East Asian Nation. *J Clin Diagn Res* 8(6):RC12

Course

- In the resolving disease, reticulation and septal thickening predominate representing organization of intra-alveolar exudates: it typically occurs in areas in which ground-glass opacity was visible during the acute phase of the disease.
- Rarely, infection with *PJP* results in diffuse parenchymal fibrosis (chronic *PJP*).
- Less frequently, *PJP* results in mild, peripheral bronchiectasis and/or bronchiolectasis, presumably the result of *PJP* bronchiolitis.
- Some authors noted the appearance of premature bullous disease in AIDS patients.



Wassermann K (1993) Chronic Pneumocystis carinii pneumonia in AIDS. *Chest* 104(3):667

Kuhlman JE (1989) Premature bullous pulmonary damage in AIDS: CT diagnosis. *Radiology* 173(1):23

Definition

Tuberculosis (TB), in the past also called phthisis or consumption, is a widespread and, in many cases, fatal, infectious disease caused by *Mycobacterium tuberculosis*. Tuberculosis typically attacks the lungs but can also affect other parts of the body. The infections that do not have symptoms are known as latent tuberculosis. Pathologically, the typical form of TB consists of a necrotizing granulomatous inflammation associated with a variable amount of accompanying non-necrotizing granulomas.



TB (short for tubercle bacillus)



Menzies D (2013) Update in tuberculosis and nontuberculous mycobacterial disease 2012. Am J Respir Crit Care Med 188(8):923

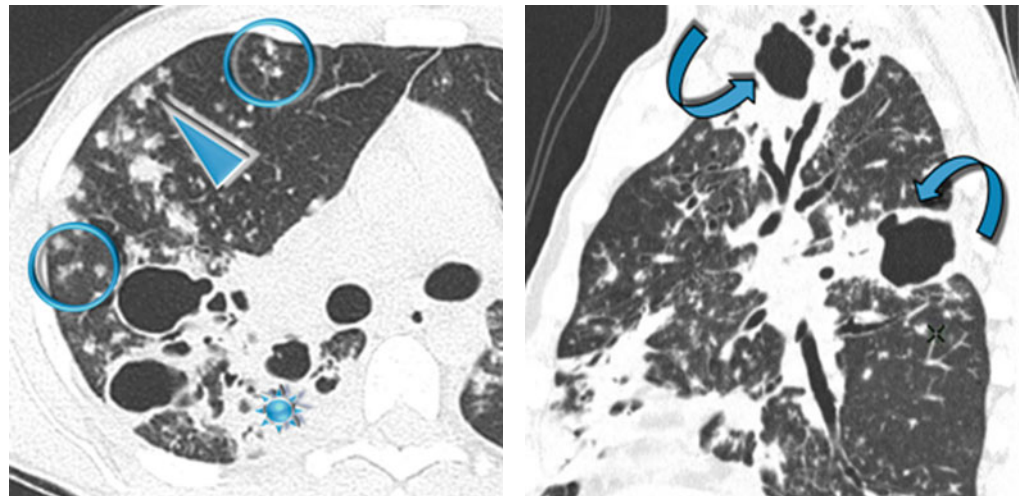
Dalpiazz G (2014) Diffuse granulomatous lung disease: combined pathological-HRCT approach. Radiol Med 119(1):54

Key Signs

- Consolidation (★)
- Macronodules and centrilobular micronodules (▶)
- Tree-in-bud sign which reflects endobronchial spread of infection (⊙)
- Cavitation (50–58 %) visible both in the consolidation and in the nodules (↘)

Distribution

Patchy unilateral or bilateral, frequently peribronchial in distribution, apical and posterior segments of the upper lobes, and superior segments of the lower lobes (↘)



The cavities typically have thick, irregular walls, which become smooth and thin with successful treatment. When the amount of fluid content is significantly high, superinfection by other bacteria should be suspected. Cavities are usually multiple and occur within areas of consolidation. The resolution can result in emphysematous change or scarring.



Cardinale L (2015) The imaging spectrum of pulmonary tuberculosis. Acta Radiol 56(5):557

Woodring JH (1986) Update: the radiographic features of pulmonary tuberculosis. AJR Am J Roentgenol 146(3):497

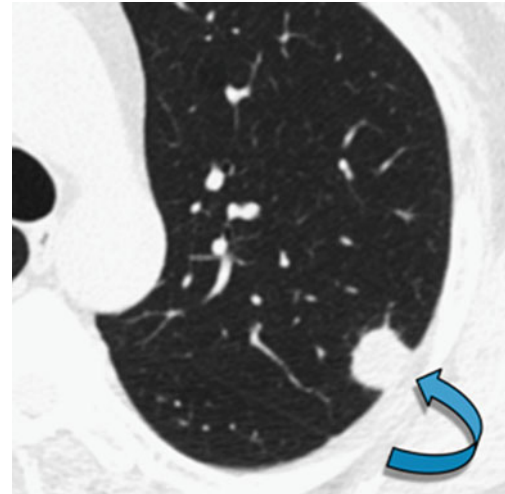
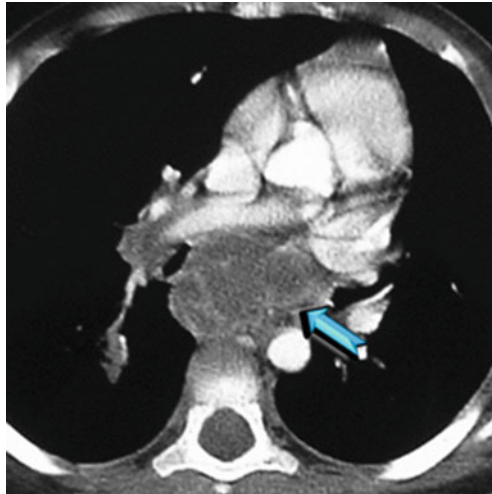
Yeong YJ (2008) Pulmonary tuberculosis: up-to-date imaging and management. AJR Am J Roentgenol 191(3):834

Ancillary Signs

- Possible association with diffuse, random, tiny and solid, well defined nodules, indicating nodules that indicate hematogenous spread of infection (please see miliary TB in the chapter “[Nodular Diseases](#)”).
- Occasionally, active TB may be associated with a reversed halo sign (atoll sign). This sign in active TB typically has nodular margins and commonly has nodules within it, which allows distinction from the halo sign seen in OP or other entities which have smooth margins (please also refer to the Reversed halo sign in the chapter “[Nodular Pattern](#)”).

Non-parenchymal Signs

- Pleural effusion (unilateral) and pleural thickening
- Hilar/mediastinal lymphadenopathy with central necrosis more visible on contrast-enhanced CT (➔)



TB may appear as solitary macronodules (tuberculomas) (please see the image above ➔).



The principal CT findings of airway TB are circumferential wall thickening and luminal narrowing, with the involvement of a long segment of the bronchi. In active disease, the airways are irregularly narrowed in their lumina and have thick walls, whereas in fibrotic disease, the airways are smoothly narrowed and have thin walls.



Moon WK (1997) Tuberculosis of the central airways: CT findings of active and fibrotic disease. *AJR Am J Roentgenol* 169(3):649

Course

- Parenchymal lesions: thin wall cavities, calcified nodules, and end-stage lung destruction.
- Airway lesions: bronchiectasis, bronchial stenosis, and broncholithiasis.
- Rasmussen aneurysm represents a pulmonary artery aneurysm or pseudoaneurysm adjacent or within a tuberculous cavity.
- Empyema necessitates the leakage of tuberculous empyema through the parietal pleura and discharge of its contents into the subcutaneous tissues of the chest wall.
- Mycetoma, fungus ball is common in patients who have cavitory TB. It appears as a well-circumscribed intracavitary mass associated with an air crescent sign (please also refer to Air crescent sign in the “[Case-Based Glossary with Tips and Tricks](#)”).



The best indicators of residual active disease are centrilobular nodules, tree-in-bud appearance, and cavitation.



Kim HY (2001) Thoracic sequelae and complications of tuberculosis. *Radiographics* 21(4):839

Table	Differential diagnosis with pulmonary TB
Nontuberculous mycobacteria	Cavitary form: in comparison with postprimary TB, cavities are more likely to be smaller or thin-walled; anyway, the differential diagnosis remains a challenge
Semi-invasive (chronic necrotizing) aspergillosis	Radiologic manifestations include unilateral or bilateral segmental areas of consolidation with or without cavitation or adjacent pleural thickening
Bacterial pneumonia	The appearance of the parenchymal consolidations in primary tuberculosis is most commonly dense and homogeneous but may also be linear, patchy, and nodular, very similar to bacterial pneumonia Lymphadenopathy and the lack of response to conventional antibiotics can suggest the correct diagnosis
Lung cancer	Tuberculomas can appear mass-like and tend to be mistaken for malignancy if typical characteristics are absent. Benign-type (diffuse, central, or lamellar) calcifications and upper lobe involvement may be clues to the imaging diagnosis of tuberculosis. In controversial situations, transthoracic needle biopsy can lead to a diagnosis
Sarcoidosis	Cavitation of parenchymal lesions is a rare finding in sarcoidosis. It is seen in an estimated 10% of patients with end-stage disease



Franquet T (2001) Spectrum of pulmonary aspergillosis: histologic, clinical, and radiologic findings. *Radiographics* 21(4):825

Tan CH (2010) Tuberculosis: a benign impostor. *AJR Am J Roentgenol* 194(3):555

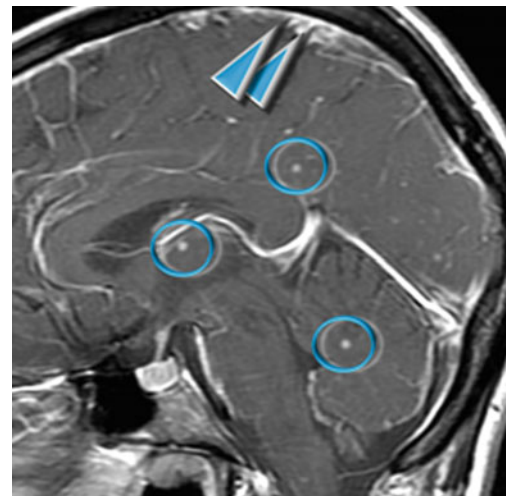
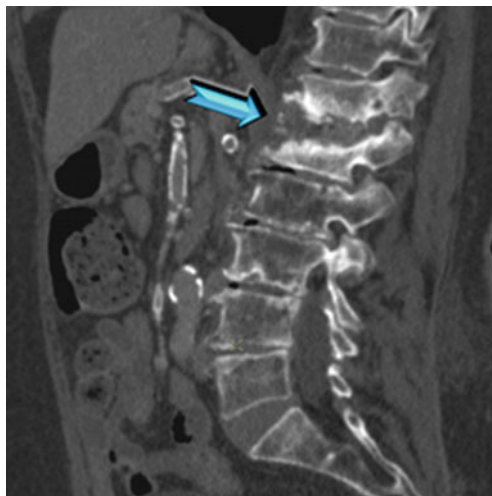
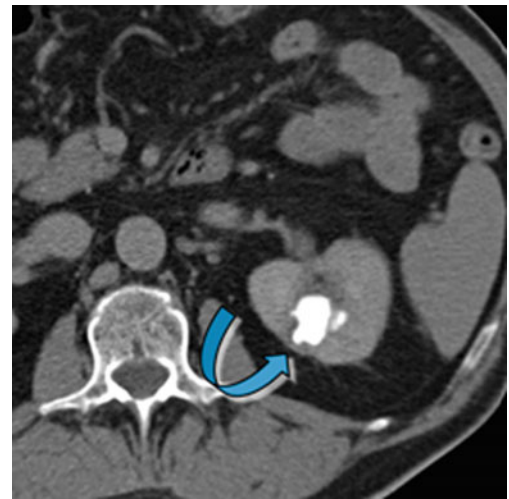
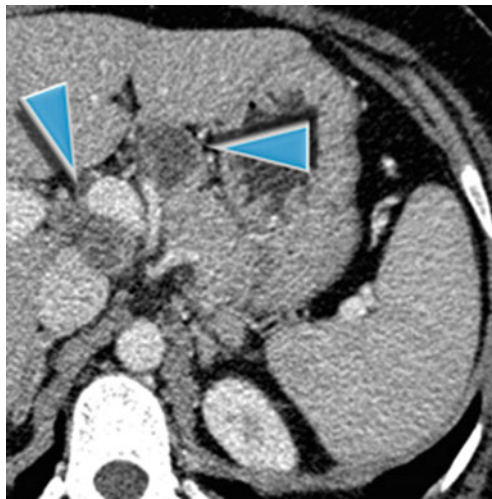
Criado E (2010) Pulmonary sarcoidosis: typical and atypical manifestations at high-resolution CT with pathologic correlation. *Radiographics* 30(6):1567

Harisinghani MG (2000) Tuberculosis from head to toe. *Radiographics* 20(2):449

Burrill J (2007) Tuberculosis: a radiologic review. *Radiographics* 27(5):1255

Table	Extrapulmonary TB
Neck TB	Tuberculosis in the head and neck represents about 15% of cases of extrapulmonary tuberculosis. The most common location is within the neck nodes, often manifesting as bilateral painless cervical lymphadenitis, also known as scrofula. The involved nodes are initially homogeneous but later undergo central necrosis, manifesting with central low attenuation at CT
Abdominal TB	The abdomen is the most common focus of extrapulmonary tuberculosis. Abdominal lymphadenopathy is the most common manifestation, observed in 55–66% of patients. The majority (40–60%) of patients with lymphadenitis have enlarged nodes with hypodensifying centers and hyperattenuating enhancing rims at CT (▶). Peritonitis may be present. Gastrointestinal tuberculosis is rare; when present, however, it almost always involves the ileocecal region (90% of cases). Hepatosplenic involvement is common in patients with disseminated disease and is either micronodular-miliary or macronodular
Urinary TB	Various patterns of hydronephrosis may be seen at CT depending on the site of the stricture and include focal caliectasis with mild thickening of adjacent parenchyma due to papillary necrosis (↘) and possible generalized hydronephrosis. Other common findings include parenchymal scarring and low-attenuation parenchymal lesions. CT is also useful in depicting the extension of disease into the extrarenal space

Table	Extrapulmonary TB
Musculoskeletal TB	The musculoskeletal system is involved in only 1–3% of cases of tuberculosis. Approximately 50% of skeletal tuberculosis involves the spine (Pott disease). The lower thoracic and upper lumbar levels are most commonly affected (➡). Isolated tuberculous osteomyelitis in the absence of associated tuberculous arthritis is relatively rare
TB involving the CNS	Involvement of the central nervous system (CNS) is seen in approximately 5% of immunocompetent patients and up to 15% of immunocompromised patients. Tuberculous meningitis is the most common manifestation of CNS. The typical radiographic finding is abnormal meningeal enhancement (▶▶). The most common CNS parenchymal lesion of tuberculosis is tuberculoma. This lesion may be solitary, multiple, or miliary and may be seen anywhere within the brain parenchyma (○). They demonstrate homogeneous or ring enhancement



Definition

Lipoid pneumonia (LP) is an uncommon condition which results from the pulmonary accumulation of fatlike compounds. The exogenous chronic form results from the recurrent aspiration or inhalation of oil or from the accidental aspiration of a large quantity of lipid material. It can have an animal, vegetable, or mineral origin. It is possible in patients with obstinate constipation and long-term use of laxative or in patients who use Vaseline for oiling tracheal cannula. Clinically, patients may be asymptomatic or present with nonspecific symptoms such as cough, tachypnea, and mild fever. As a result, the diagnosis of lipoid pneumonia is sometimes difficult to establish, and the history of ingestion or inhalation of oily material is often the key to diagnosis. Pathologically, macrophages containing phagocytosed oil fill in the alveoli and distend the alveolar walls and interlobular septa. Fibrosis is occasionally present and is of variable extent. The diagnosis of this disease requires a high index of suspicion and can be confirmed by the demonstration of lipid-laden macrophages in respiratory samples such as sputum, bronchoalveolar lavage fluid, or fine-needle aspiration cytology/biopsy from lung lesions.



LP



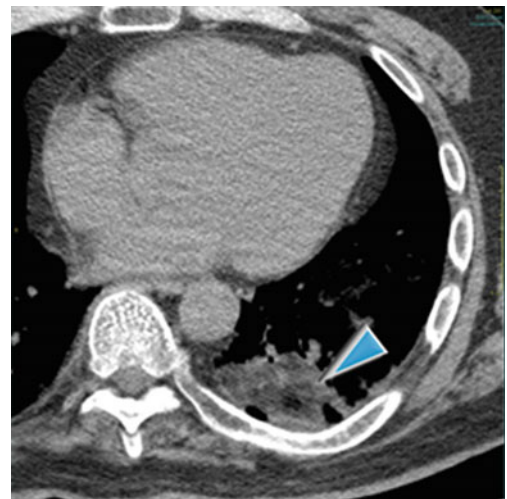
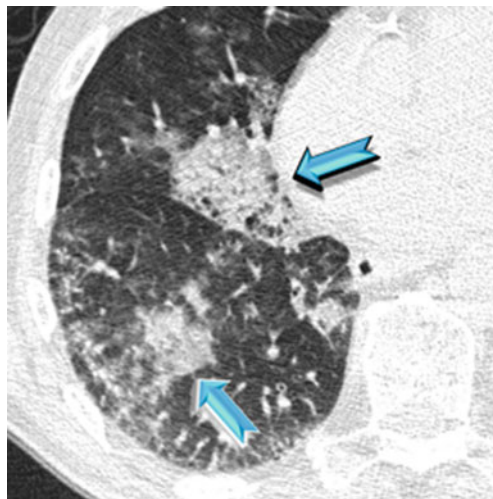
Marchiori E (2011) Exogenous lipoid pneumonia. Clinical and radiological manifestations. *Respir Med* 105(5):659

Key Signs

- Patchy ground-glass opacities
- Patchy airspace consolidations (➡) with possible low-density attenuation (negative values) (▶)

Distribution

Patchy unilateral or more frequently bilateral, middle and lower lobes and geographic distribution with posterior predominance



Low-attenuation consolidation with negative density values between -150 and -30 HU is highly suggestive of fat and consistent with lipoid pneumonia. These measures should be taken in the most hypodense part of the consolidation areas, free of any aerated parenchyma. Nevertheless, CT attenuation measurements are not always characteristic due to the averaging with attenuation values from surrounding inflammatory infiltrates.

The low-attenuation consolidation is better appreciated after contrast material administration.



Baron SE (2003) Radiological and clinical findings in acute and chronic exogenous lipoid pneumonia. *J Thorac Imaging* 18(4):217

Ancillary Signs

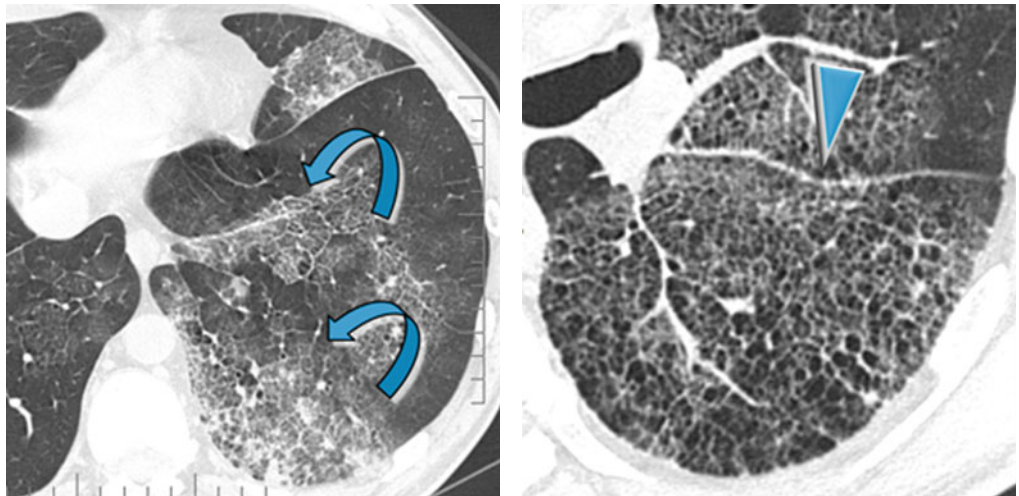
- Interlobular septal thickening and crazy paving have also been reported (↔).
- Airspace nodules (low-density centrilobular nodules).
- Signs of fibrosis in the later stages appearing as fissure distortion, volume loss, and diffuse honeycombing (▶).
- Tumorlike lesions often with spiculated profiles and mainly in the dorsal area of the lower lobes.



Chronic crazy paving may be present in lipid pneumonia but also in other alveolar diseases, often in pulmonary alveolar proteinosis (please also refer to Crazy-paving in the “Case-Based Glossary with Tips and Tricks”).

Non-parenchymal Signs

- Reactive mild lymph node enlargement



Lipoid pneumonia can present as a PET-positive lung nodule and should be considered in the differential diagnosis and workup of a solitary pulmonary nodule.



Talwar A (2004) False-positive PET scan in a patient with lipid pneumonia simulating lung cancer. *Clin Nucl Med* 29(7):426

Course

- None of the patients with chronic presentations improved either clinically or radiologically.
- The natural history and outcome of LP are variable. This and the low number of cases make it difficult to establish the optimal treatment. The first and foremost concern is the avoidance of further insult.



Laurent F (1999) Exogenous lipid pneumonia: HRCT, MR, and pathologic findings. *Eur Radiol* 9(6):1190
 Betancourt SL (2010) Lipoid pneumonia: spectrum of clinical and radiologic manifestations. *AJR Am J Roentgenol* 194(1):103

Definition

Primary pulmonary mucosa-associated lymphoid tissue (p-MALT) lymphoma is an extranodal low-grade B-cell lymphoma. It is the most common primary pulmonary lymphoma. MALToma accounts for 54–58 % of the primary pulmonary lymphomas. This tumor tends to remain localized to the lung for long periods of time, follows an indolent course, and is associated with a good prognosis. MALT lymphomas are usually indolent lesions with possible association with autoimmune disease (collagen vascular diseases such as RA, Sjögren’s syndrome, SLE, and hepatitis C virus infection). When present, symptoms, such as cough, mild dyspnea, and chest pain, are nonspecific. The median age is 60 years. About 50 % of patients have at least one extrapulmonary location of lymphoma.



MALToma, BALT lymphoma, extranodal marginal zone B-cell lymphoma



Poletti V (2013) Lymphoproliferative lung disorders: clinicopathological aspects. Eur Respir Rev 22(130):427

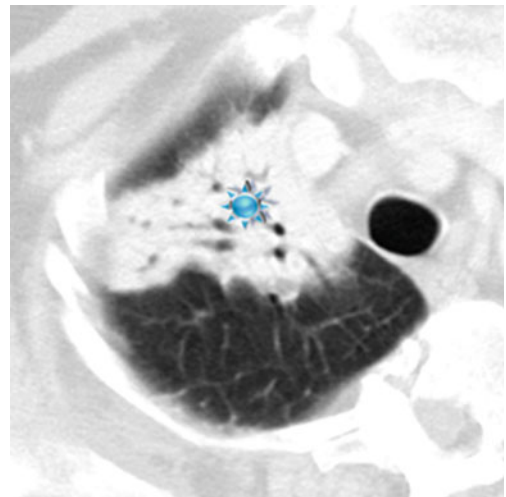
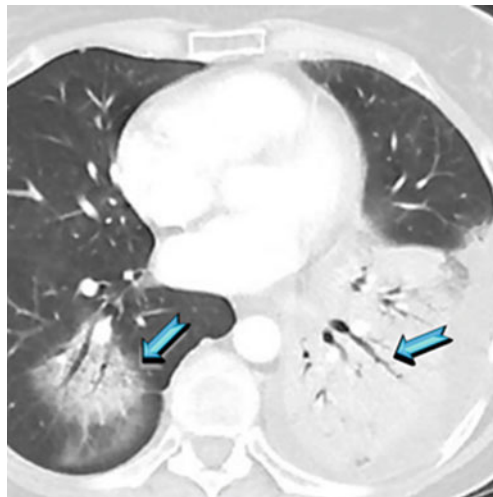
HIGH-RESOLUTION CT: HRCT

Key Signs

- Consolidations (60 %) with air bronchogram (50–90 %); bronchi within affected parenchyma may appear stretched and slightly narrowed (➡) or slightly dilated (★).

Distribution

Solitary or often multiple (70 %) and bilateral (60–70 %), peribronchovascular and peripheral



Multifocal areas of consolidation may also be seen in other alveolar chronic diseases and in particular in minimally invasive adenocarcinoma (MIA), adenocarcinoma in situ (AIS), formerly known as bronchoalveolar carcinoma (BAC), and cryptogenic organizing pneumonia (COP). See also [alveolar pattern](#), chronic subset.



Do KH (2005) Pulmonary parenchymal involvement of low-grade lymphoproliferative disorders. J Comput Assist Tomog 29(6):825

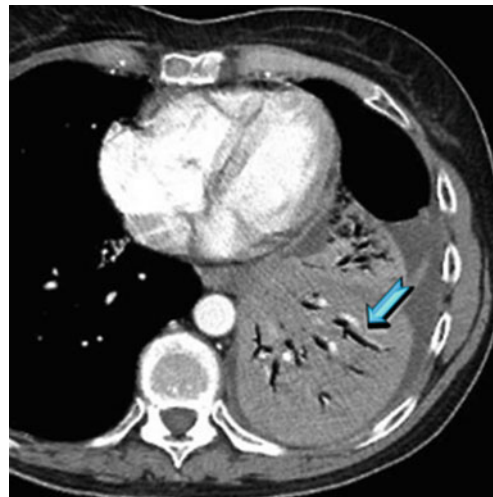
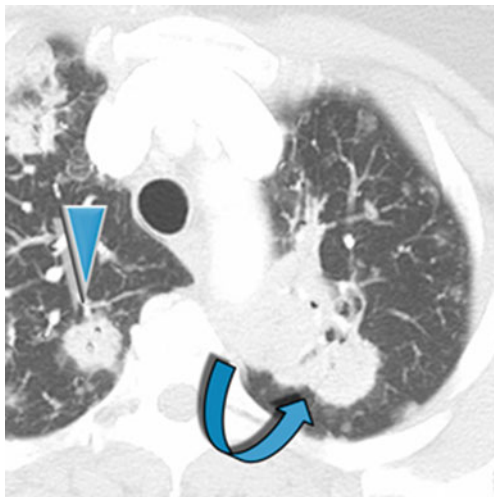
Hare SS (2012) The radiological spectrum of pulmonary lymphoproliferative disease. Br J Radiol 85(1015):848

Ancillary Signs

- Macronodules (▶) with hazy margins due to airspace filling (60 %)
- Masses (↘) with variable diameter up to several centimeters
- Possible halo sign around nodules or masses
- Angiogram sign after contrast material administration (➡)
- Interlobular septal thickening
- Bubble-like lucencies inside the lesions (rare)

Non-parenchymal Signs

- Hilar/mediastinal lymphadenopathy (30%)
- Pleural effusion (10–30%), generally associated with the parenchymal lesions



Halo sign is defined as a ground-glass opacity that surrounds circumferentially a pulmonary nodule or mass. The sign was originally described in association with invasive pulmonary aspergillosis, but, as a matter of fact, many infectious or noninfectious diseases may be associated with this sign.

Angiogram sign refers to the visualization of pulmonary vessels within an airless portion of the lung, on contrast-enhanced CT scanning. The vessels are prominently seen against a background of relatively low-attenuation lesion. It has been initially described in 1990 as a specific sign of lobar bronchoalveolar cell carcinoma. Thereafter, several retrospective studies reported that this sign can be seen in both benign and malignant diseases.

Bubble-like lucencies (pseudocavitations) inside the lesions are rare and are due to bronchiolar dilatation. Others diseases are more often responsible of bubble-like lucencies.

For all these tree signs, please refer to “Case-Based Glossary with Tips and Tricks”.



Think of primary pulmonary lymphomas in the presence of a tumorlike mass and an air bronchogram with bronchial dilatation in patients with autoimmune disease



Cardinale L (2005) CT findings in primary pulmonary lymphomas. *Radiol Med* 110(5–6):554

King LJ (2000) Pulmonary MALT lymphoma: imaging findings in 24 cases. *Eur Radiol* 10(12):1932

Course

- The parenchymal abnormalities typically show an indolent course, with slow growth over months or years.
- The survival data confirm the indolent nature of pulmonary MALT lymphoma.



Borie R (2009) Clinical characteristics and prognostic factors of pulmonary MALT lymphoma. *Eur Respir J* 34(6):1408

Definition

Metastases from an adenocarcinoma may spread into the lung along the intact alveolar walls (lepidic growth), in a fashion similar to a primary lung adenocarcinoma. Metastases may be from an adenocarcinoma of the lung or gastrointestinal tract/breast/ovary.

In primary lung adenocarcinoma, aerogenous metastases result as intrapulmonary discontinuous spread of neoplastic cells through airspaces and airways; the discontinuous foci may be seen close to primary tumor as satellite foci or at distance, including the contralateral lung. The radiologic features of this tumor growth pattern can mimic pneumonia.



Gaikwad A (2014) Aerogenous metastases: a potential game changer in the diagnosis and management of primary lung adenocarcinoma. *AJR Am J Roentgenol* 203(6):W570

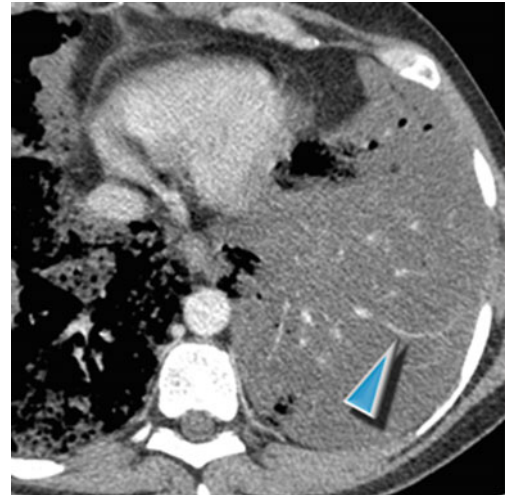
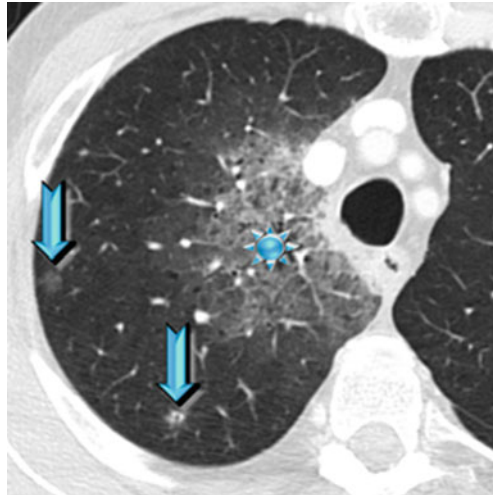
Warth A (2015) Prognostic impact of intra-alveolar tumor spread in pulmonary adenocarcinoma. *Am J Surg Pathol* 39:793

Key Signs**HIGH-RESOLUTION CT: HRCT**

- Predominant or exclusive airspace disease: ground-glass opacities (★) and consolidations
- Low-density persistent centrilobular nodules with ill-defined margins (snowflake nodules) (➡) and possible branching opacities (tree in bud)
- Possible low-attenuation consolidations with “angiogram sign” on contrast-enhanced CT (the vessels may be stretched and thin due to “mass effect”) (▶)

Distribution

Prevalent lower lobes and dependent distribution



The presence of a “dominant” consolidation may be due to primary or sometimes due to the advanced metastatic involvement of lepidic growth, more frequent in patients with gastrointestinal disease.

Possible low-attenuation consolidations with “angiogram sign” may be due to primary or metastatic mucinous adenocarcinoma. The CT findings include a uniform low attenuation and slight enhancement after intravenous injection of contrast medium. The differential diagnosis is with other diseases with hypodense consolidation and in particular with lipoid pneumonia (please see also “angiogram sign” in the “Case-Based Glossary with Tips and Tricks” “low-density consolidation” in the chapter “[Alveolar Pattern](#)”).



Nodules tend to grow in clusters on serial images, in some cases progressing to confluent airspace consolidation. The differential diagnosis of centrilobular nodules and branching opacities at CT includes infectious bronchiolitis due to mycobacterial, viral or bacterial agents. Inflammatory centrilobular nodules commonly resolve with appropriate treatment, whereas aerogenous metastases persist and grow. The CT appearance reflects cancer cells lining the small airways and alveolar spaces in a lepidic pattern with variable amounts of intra-alveolar material (e.g., cells, secretions, and mucin).

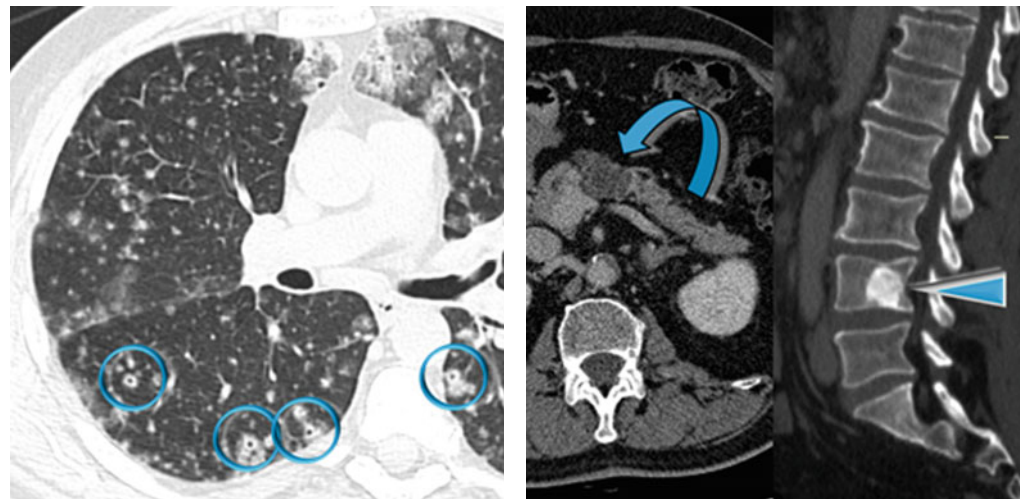


Gaeta M (2002) CT and MRI findings of mucin-containing tumors and pseudotumors of the thorax: pictorial review. *Eur Radiol* 12(1):181

Ancillary Signs

- Nodular thickening and solid nodules along lymphatic routes due to lymphangitic carcinomatosis
- Solid nodules due to hematogenous metastases, feeding vessels, and also “cavitated” (●) (please also refer to Cheerio sign in the chapter “[Nodular Pattern](#)” and in the “Case-Based Glossary with Tips and Tricks”).
- Mediastinal and abdominal lymph node enlargement
- Mucus filling of airways
- Pleural effusion
- Abdominal solid neoplasm (e.g., pancreas ↗, colon), often mucinous and consequently partially hypodense after intravenous injection of contrast medium
- Focal lytic or hyperdense bone lesions (▶) due to hematogenous metastatic involvement in infiltrative carcinoma

Non-parenchymal Signs



Synchronous primary mucinous adenocarcinoma typically presents as multiple random peripheral subsolid nodules of variable size; in comparison, aerogenous metastatic lesions appear as small clustered centrilobular and “tree-in-bud” opacities. The temporal evolution on serial CT examinations is a key in the differential diagnosis.



Tateishi U (2005) Mucin producing adenocarcinoma of the lung: thin-section computed tomography findings in 48 patients and their effect on prognosis. *J Comput Assist Tomogr* 29:361–368

Seo JB (2001) Atypical pulmonary metastases: spectrum of radiologic findings. *Radiographics* 21(2):403

Course

- Slow progression with continuous growth of neoplastic cells (lepidic growth) with growing of the consolidative and ground-glass areas
- In invasive adenocarcinomas, onset or progression of metastatic disease through lymphatic and/or blood vessels

Definition

Pulmonary alveolar proteinosis (PAP) is a rare diffuse lung disease characterized by the alveolar and interstitial accumulation of a periodic acid–Schiff (PAS) stain-positive phospholipoprotein derived from surfactant. Three distinct subgroups of PAP are currently recognized: idiopathic, secondary, and congenital. *Idiopathic/autoimmune* PAP (also termed “adult-type” PAP) accounts for the great majority of cases (90%). *Secondary* PAP (5–10% of cases) is associated with certain occupational exposures, particularly mineral dusts and fumes or an underlying hematologic malignancy or immunodeficiency disorders. *Congenital* PAP is quite rare (2% of cases) and manifests in the neonatal period with severe hypoxia.



PAP



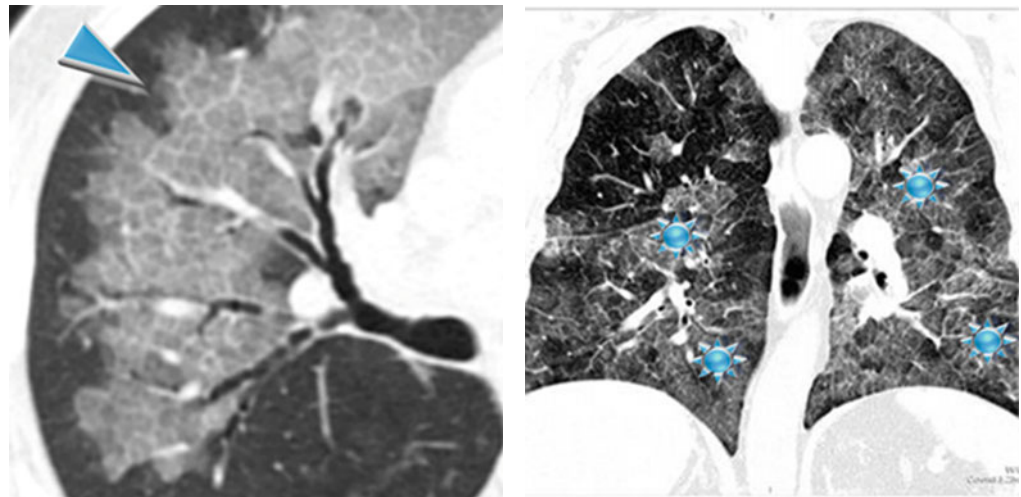
Frazier AA (2008) From the archives of the AFIP: pulmonary alveolar proteinosis. *Radiographics* 28(3):883

Key Signs

- Crazy paving (▶)
- Areas of ground-glass opacity (GGO) (★)

Distribution

Bilateral, diffuse, patchy, or geographic distribution with typically sharply demarcated margins of areas of lung opacity. No specific zonal distribution with relative sparing of apices and costophrenic angles (butterfly distribution); in some patients the abnormalities predominate in the lower lung.



Crazy paving refers to the appearance of ground-glass opacity with superimposed interlobular septal thickening and intralobular reticular thickening, seen on chest HRCT. This sign is strongly suggestive of alveolar proteinosis in patients with subacute/chronic symptoms. Other diseases with *subacute/chronic alveolar pattern* may be lipoid pneumonia, chronic eosinophilic pneumonia (CEP), organizing pneumonia (OP), sarcoidosis (alveolar), tuberculosis, primitive pulmonary neoplasms (adenocarcinoma, MALT lymphoma), nonspecific interstitial pneumonia (NSIP), and radiation pneumonitis (please also refer to Crazy paving in the “Case-Based Glossary with Tips and Tricks”).



The extent and zonal distribution of idiopathic PAP is bigger than that of secondary PAP, as some inhaled dusts may deposit according to the gravity and some other conditions (such as infectious, metastatic, or malignant processes) may spread to zones with higher vascular supply.

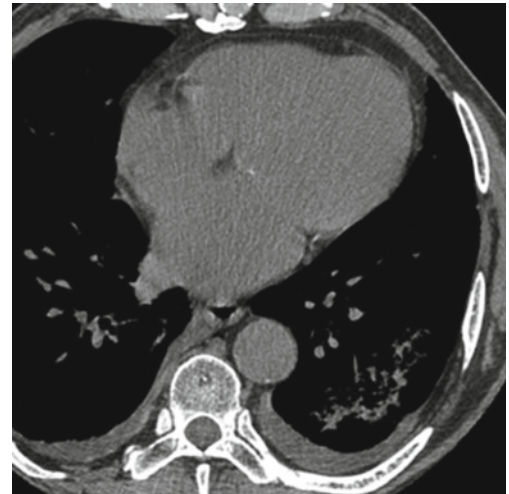
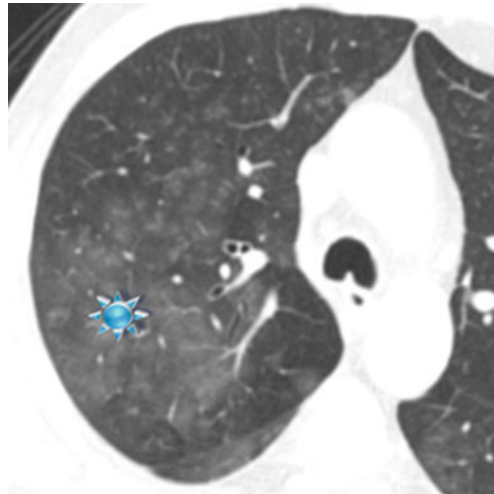


Mehrian P (2014) Features of idiopathic pulmonary alveolar proteinosis. in high resolution computed tomography. *Pol J Radiol* 79:65

Shah PL (2000) Pulmonary alveolar proteinosis: clinical aspects and current concepts on pathogenesis. *Thorax* 55:67

Ancillary Signs**Non-parenchymal Signs**

- Ill-defined low-density (subsolid) nodules (snowflake nodules) (see figure below)
- Consolidation (▶)
- Mediastinal and/or hilar lymphadenopathy
- Pleural effusion



Patients with PAP are at increased risk of developing pulmonary infection, usually caused by opportunistic agents such as *Nocardia*, *Aspergillus*, *Pneumocystis jirovecii*, and *Mycobacteria*. The presence of pleural effusion and enlarged lymph nodes in patients with PAP should be considered as highly suggestive of a superimposed infection.

Parenchymal consolidation may be caused both by the underlying disease and by supervening opportunistic infection. The latter is suspected when the consolidation is focal.



Souza CA (2012) Comparative study of clinical, pathological and HRCT findings of primary alveolar proteinosis and silicoproteinosis. *Eur J Radiol* 81(2):371

Course

- Patients with idiopathic PAP are treated with sequential therapeutic whole-lung lavage (WLL), a procedure to remove lipoproteinaceous material from pulmonary alveoli with the use of saline solution.
- In patients who undergo whole-lung lavage (WLL), both ground-glass opacity and interlobular septal thickening typically decrease. However, in some patients undergoing WLL, a reduction in GGO occurs, with the persistence of interlobular septal thickening. Sometimes this abnormality may become chronic; rarely it indicates the presence of fibrosis.



Abdelmalak BB (2015) Therapeutic whole-lung lavage for pulmonary alveolar proteinosis: a procedural update. *J Bronchol Interv Pulmonol* 22(3):251

Definition

Hydrostatic pulmonary edema is characterized by a transudative mechanism often due to increased intravascular pressure, heart failure being the most common cause. Low intravascular oncotic pressure resulting from hypoalbuminemia can also result in increased interstitial transudation of fluid. If pulmonary edema is severe enough to flood the alveoli, bilateral, patchy, or widespread “fluffy” lung opacities may become evident on chest radiography. Hydrostatic pulmonary edema is a frequent cause of admission to the hospital, in particular, in elderly patients.



A classification of pulmonary edema as (a) hydrostatic edema, (b) increased permeability edema without associated DAD, (c) mixed edema, and (d) permeability associated with DAD (ARDS) has been proposed, and either agrees with pathology, physiology, and radiological findings.



PE



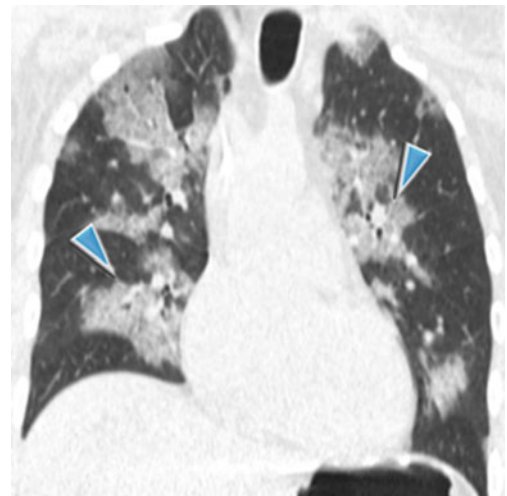
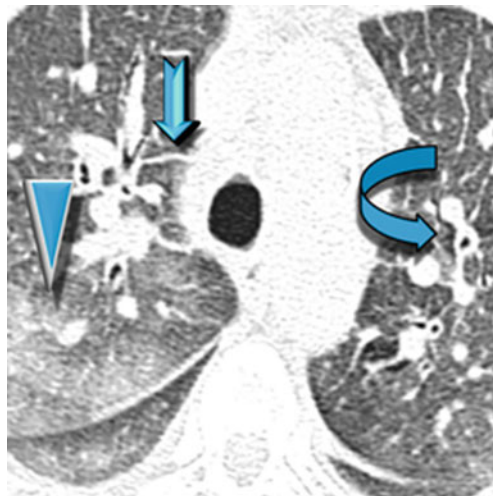
Ketai LH (1998) A new view of pulmonary edema and acute respiratory distress syndrome. J Thorac Imaging 13(3):147

Key Signs

- Areas of ground-glass opacities (▶)
- Peribronchial cuffing and vessel enlargement (↘) and smooth septal thickening (↗); all these signs are prevalent in the initial stages of disease, please see [PE, interstitial](#) in the chapter “[Septal Diseases](#)”).

Distribution

Patchy or lobular (geographic) bilateral, central, and gravitational. Possible butterfly or batwing distribution (▶)



Butterfly or batwing pulmonary opacities refer to the presence of bilateral parenchymal opacities, with perihilar distribution and sparing of the periphery of the lungs. It is classically described in the chest X-ray but is best appreciated on CT. It generally occurs with rapidly developing severe cardiac failure. It can be also caused by other diseases (see also the Butterfly pulmonary opacities in the “Case-Based Glossary with Tips and Tricks”).

It is possible that increased blood volume is the cause of ground-glass opacity or that ground-glass opacity reflects very subtle interstitial edema.



Occasionally, edema may have unilateral distribution, as may occur in patients with a prolonged lateral decubitus, or asymmetric and even with bizarre distribution in patients with regional emphysema. Pulmonary edema may also localize to the right middle and upper lobes because of myocardial infarction with papillary muscle rupture and mitral acute valve insufficiency.



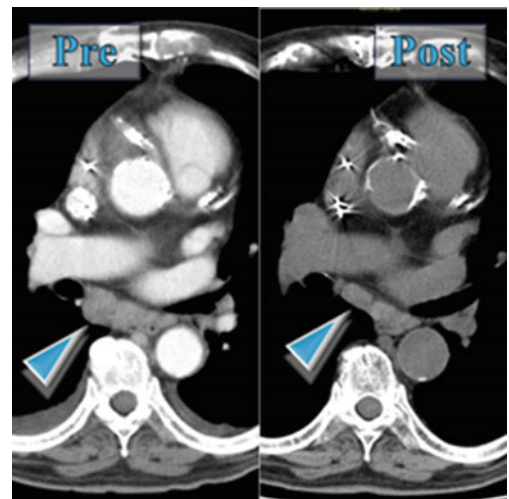
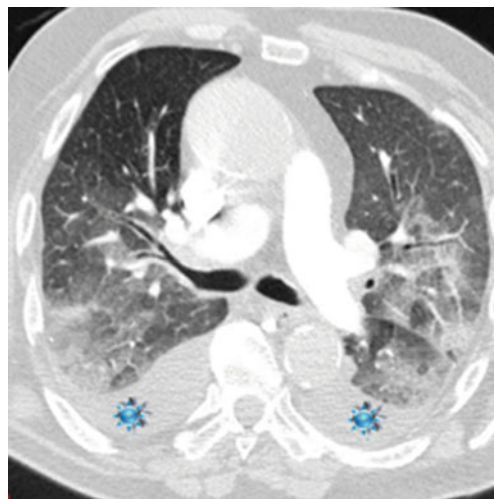
Storto ML (1995) Hydrostatic pulmonary edema: high-resolution CT findings. *AJR Am J Roentgenol* 165:817

Ancillary Signs

- Crazy paving.
- Consolidation is inconspicuous or absent in most cases.

Non-parenchymal Signs

- Among the bilateral pleural effusion (★), most are similarly sized but the right-sided can be larger. Possible unilateral pleural effusion, often on the right side.
- Cardiomegaly.
- Dilatation of pulmonary arteries and veins; vessels may become more visible at the periphery of the lung, and nongravity-dependent vessels may enlarge disproportionately, reflecting the process of “cephalization” seen on the chest radiograph.
- Enlargement of mediastinal lymph nodes due to fluid stagnation (in patients with left heart failure, identified in 40–60%). Both the enlarged lymph nodes and pleural effusion often reduce or disappear after adequate diuretic therapy (▶).



An increase in thickness of the chest wall may reflect an accumulation of fluid in the “third space,” whereas a widening of the vascular pedicle indicates an increase in the blood volume circulating in the venous district.



Cardinale L (2014) Effectiveness of chest radiography, lung ultrasound and thoracic computed tomography in the diagnosis of congestive heart failure. *World J Radiol* 6(6):230

Ribeiro CM (2006) Hydrostatic pulmonary edema: high-resolution computed tomography aspects. *J Bras Pneumol* 32(6):515

Course

- Acute onset and rapid regression with treatment are characteristic features of this form of edema and may assist in the differential diagnosis.
- In patients with left heart failure, mediastinal lymphadenopathy often decreases after adequate treatment (60%).



Chabbert V (2004) Mediastinal lymphadenopathy in congestive heart failure: a sequential CT evaluation with clinical and echocardiographic correlations. *Eur Radiol* 14(5):881