

# Gerbode defect: A comprehensive review of its history, anatomy, embryology, pathophysiology, diagnosis, and treatment



Erfanul Saker<sup>a,\*</sup>, Ghazal N. Bahri<sup>a</sup>, Michael J. Montalbano<sup>a</sup>, Jaspreet Johal<sup>a</sup>, Rachel A. Graham<sup>b</sup>, Gabrielle G. Tardieu<sup>a</sup>, Marios Loukas<sup>a</sup>, R. Shane Tubbs<sup>a,c</sup>

<sup>a</sup>Department of Anatomical Sciences, St. George's University, West Indies

<sup>b</sup>Department of Pathobiology, The Sophie Davis School of Biomedical Education, City College of New York, NY

<sup>c</sup>Department of Neurosurgery, Seattle Science Foundation, Seattle, WA

<sup>a</sup>Grenada

<sup>b,c</sup>USA

The purpose of this paper is to survey the literature on Gerbode defect and provide an overview of its history, anatomy, development, pathophysiology, diagnosis, and treatment options. The available literature on this topic, including case reports, was thoroughly reviewed. Gerbode defect is defined as abnormal shunting between the left ventricle and right atrium resulting from either a congenital defect or prior cardiac insults. The pathophysiology underlying the development of Gerbode defect is a disease process that injures the atrioventricular septum and leads to the abnormal shunting of blood. Although the most prevalent cause of Gerbode defect has historically been congenital, an increasing trend towards acquired cases has recently been reported owing to improved diagnostic capabilities and a greater number of invasive cardiac procedures. In conclusion, Gerbode defect is an increasingly recognized condition that warrants further study.

© 2017 The Authors. Production and hosting by Elsevier B.V. on behalf of King Saud University. This is an open access article under the CC BY-NC-ND license (<http://creativecommons.org/licenses/by-nc-nd/4.0/>).

**Keywords:** Classification, Echocardiography, Gerbode defect, History, Intracardiac shunt, Left ventricle to right atrium communication

## Contents

Introduction . . . . .	284
Embryology and pathologic anatomy . . . . .	285
Anatomical location of defect . . . . .	286
Pathophysiology . . . . .	287
Diagnosis . . . . .	288
Symptoms . . . . .	288

**Disclosure:** Authors have nothing to disclose with regard to commercial support.

Received 3 October 2016; revised 24 November 2016; accepted 26 January 2017.

Available online 16 February 2017

\* Corresponding author at: 37–15 78th Street, Jackson Heights, NY 11372, USA.

E-mail address: [esaker@sgu.edu](mailto:esaker@sgu.edu) (E. Saker).



P.O. Box 2925 Riyadh – 11461KSA  
Tel: +966 1 2520088 ext 40151  
Fax: +966 1 2520718  
Email: [sha@sha.org.sa](mailto:sha@sha.org.sa)  
URL: [www.sha.org.sa](http://www.sha.org.sa)

1016-7315 © 2017 The Authors. Production and hosting by Elsevier B.V. on behalf of King Saud University. This is an open access article under the CC BY-NC-ND license (<http://creativecommons.org/licenses/by-nc-nd/4.0/>).



Peer review under responsibility of King Saud University.  
URL: [www.ksu.edu.sa](http://www.ksu.edu.sa)  
<http://dx.doi.org/10.1016/j.jsha.2017.01.006>



Physical examination .....	288
Imaging modalities .....	288
Transthoracic echocardiography .....	288
Cardiovascular magnetic resonance imaging .....	289
Cardiac catheterization .....	289
Treatment .....	289
Conclusion .....	290
Conflict of interest .....	290
Acknowledgments .....	290
References .....	290

## Introduction

For over 5 millennia, exploration of the human body has been essential for understanding the complex nature of our anatomy. The first account of cardiovascular anatomy appeared in the Edwin Smith papyrus of 1700 BCE and was extended in the Ebers papyrus of 1500 BCE. These two significant references established the foundation of the anatomical sciences [1,2]. They depicted a connection between the heart and the vessels supplying the rest of the body, establishing the heart as the centerpiece of the whole.

During the infancy of anatomy, the heart was described as comprising three cavities: the right, which was said to contain the most abundant and hottest blood; the left, which had the least amount of blood and was the coldest; and the middle, which contained a uniform quantity but a purer quality of blood than the other two [3]. Not until the 16th century was it recognized, by da Vinci, that the heart comprises four chambers. He distinguished the roles of the atria and ventricles: as one filled with blood, the other expelled it, functions we now know as diastole and systole [4].

By the 17th century the flow of blood between the heart and lungs was becoming better understood, as well as the associated abnormalities [5]. The abnormal connections between the chambers were being classified on the basis of their location with respect to the membranous septum dividing the right and left sides of the heart. As we distinguish them today, the abnormal connections comprise atrial septal defect (ASD), ventricular septal defect (VSD), patent foramen ovale, and patent ductus arteriosus. ASD and VSD, in which there is an abnormal opening between the atria or ventricles, respectively, are the most common of these defects; they disrupt the natural flow of blood through the heart. However, there is another very rare communication anomaly, a left ventricle (LV) to right atrium (RA) connection (LV-RA), which is called the Gerbode defect.

### Abbreviations

AGD	Acquired Gerbode defect
ANIGD	Acquired noniatrogenic Gerbode defect
ASD	Atrial septal defect
AV	Atrioventricular
CMR	Cardiac magnetic resonance
PAH	Pulmonary arterial hypertension
TEE	Transesophageal echocardiography
TR	Tricuspid regurgitation
TV	Tricuspid valve
VSD	Ventricular septal defect

The congenital LV-RA connection was first mentioned in an autopsy report on a patient in 1838 [6,7]. Subsequently, Thurman [6] (1938), Buhl [7] (1857), and Hillier [8] (1859) extrapolated this discovery by reporting malformations between the LV and RA [9,10]. Thereafter there was a hiatus until Perry et al [11] (1949), after reviewing five cases from the literature, added a sixth, and described variations in the anatomy of this anomaly [10,11]. In 1955, Stahlman et al [12] reported two more cases, which like all their predecessors were at necropsy [10]. It was not until 1957, when Kirby et al [13] successfully closed a left ventricular/right atrial shunt, that the diagnosis was established in a living patient, albeit during an operation [10].

In 1958, Gerbode et al [14] successfully performed surgery on five patients with this anomaly and named it *Gerbode defect*. The authors concluded: “the lesion consists of a high ventricular septal defect associated with a defect of the septal leaflet of the tricuspid valve which allows left ventricular blood to enter the right atrium.” This rare anomaly accounts for only 0.08% [15] of intracardiac shunts and <1% of all congenital cardiac defects [16,17]. Gerbode defect is so rare that researchers observed only six cases at the Children’s Memorial Hospital in Chicago between 1990 and 2008 [17–19].

Until recently, communication between the LV and the RA was regarded as extremely rare and of little clinical significance [10]. However, as

documented by Yuan [20,21], acquired LV-RA communication is increasingly being reported. In this article we provide a complete and in-depth review of the Gerbode defect. Our aim is to survey the embryology, anatomy, pathophysiology, diagnosis, and treatment of the Gerbode defect to gain further insights and expand our understanding of this malady.

### Embryology and pathologic anatomy

Between the 27th day and 37th day of development, masses of tissue known as the endocardial cushions approach each other from the atrioventricular (AV) and conotruncal regions and eventually fuse, leading to a bifurcation of the lumen into two distinct canals (Fig. 1). This generates the AV membranous septum, AV canals and valves, and the aortic and pulmonary channels [22]. The AV septum has both muscular and membranous components. AV defects are very common and constitute about 7% of all congenital heart diseases. They are often due to endocardial cushion defects or failure to close the AV canal, leading to a common AV junction [23].

The membranous septum is divided by the septal leaflet of the tricuspid valve (TV) into AV and interventricular portions. The former develops from the dextrodorsal conus ridge, merging medially with the right tubercle of the ventral cushion [19]. The latter is formed by the end of the 4th week when the primitive ventricle is divided into

left and right by a muscular ridge near the apex [23].

The septal leaflet of the TV is formed from the right tubercles of the endocardial cushions, while the anterior and posterior leaflets originate from the endocardial tissue of the AV canal [19]. Since the TV attaches to the membranous septum about 1 cm apical to the attachment of the mitral valve, the AV septum separates the LV from the RA [24]. The Gerbode defect involves the AV portion of the interventricular septum, so it causes an abnormal communication between the RA and LV via the membranous part of that septum [25–31].

The most common malformation of the septal leaflet of the TV is a perforation of its anterior portion, either near the free edge of the leaflet or adjacent to its attachment. Wu et al [32] found that integration of anterior leaflet tissue was strongly associated with LV-RA shunting, and concomitant widening of the anteroseptal commissure accommodated the passage of blood from the RV to the RA [24]. Less frequently, the leaflet is malformed, or one of the commissural spaces is widened; in some cases there is a cleft in its mid portion. The valvular malformation overlies the septal defect and permits the LV to communicate with the RA. Trauma from the resulting jet of blood can cause thickening and distortion of the malformed leaflet. Eventually, the leaflet can fuse to the septal defect and communication between the LV and the RA results. Partial fusion produces

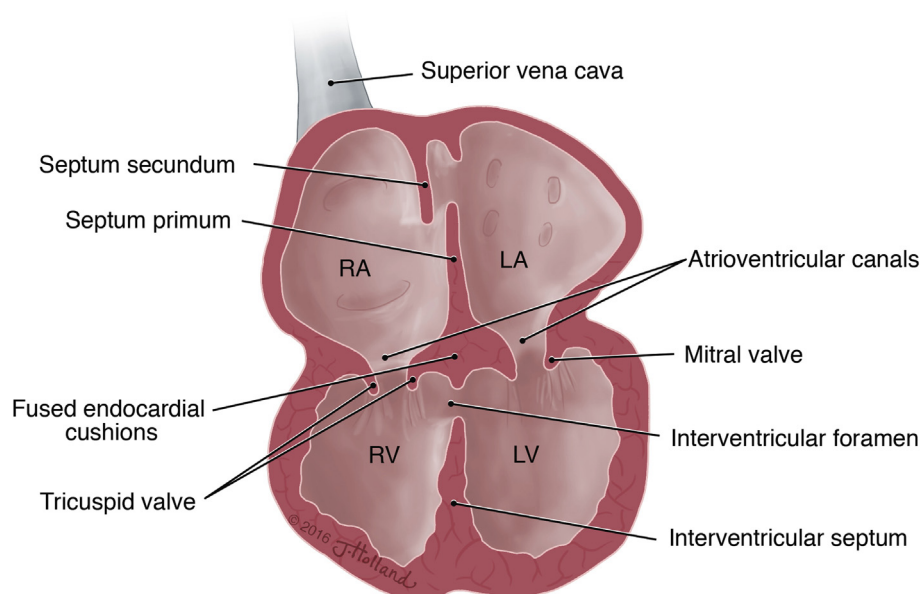


Figure 1. Developing heart at approximately 5 weeks (35 days). (Illustration by Jessica Holland ©2016, provided under CC-BY-NC-ND 4.0.) LA = left atrium; LV = left ventricle; RA = right atrium; RV = right ventricle.

a shunt into both the RA and RV. Additional malformations occur in about one-third of cases, ASD of either the patent foramen ovale or secundum type being the most commonly associated lesion [19].

### Anatomical location of defect

The classifications of the Gerbode defect correspond to different anatomical relationships. Riemenschneider and Moss [19] initially classified the defects into two types: direct and indirect. Direct defects transcend the membranous septum from the LV to the RA, while indirect defects involve a VSD with accompanying tricuspid regurgitation (TR) [20].

This terminology was later modified to describe the position of the anomaly in relation to the TV. Approximately one third of such defects occur in the AV septum and are known as supravalyvular defects [24,33]. The remaining two thirds occur between the ventricles and are known as infravalvular defects. Sakakibara and Konno [33] further elaborated the classification to include a third type with both supravalyvular and infravalvular components, referred to as intermediate defects (Fig. 2). According to Yuan [20], incidences of the three types accounted for 76%, 16%, and 8% of the total, respectively.

Taskesen et al [15] and Sinisalo et al [9] categorized the supravalyvular defects as type 1 and the infravalvular defects as types 2 and 3 [11,14,19], the most common congenital forms being types 2 and 3, which have many variants to septal leaflet anomalies of the TV [34]. These variants include a cleft, widened commissural space, perforation, abnormal chordae [9,35] and other deformities [36]. Such defects are believed to close by forming an aneurysmal pouch through incorporating adja-

cent TV tissue. This morphogenetic process has been termed aneurysmal transformation [24,32,37,38].

Supravalyvular defects are located in the AV membranous septum immediately superior to the septal leaflet of the TV and anterior to the coronary sinus. In rare cases they extend to involve a small portion of the septal leaflet at the point of its attachment [19]. As the defect indicates a location superior to the tricuspid ring, it causes a direct shunt between the RA and LV [24].

Infravalvular defects in the membranous ventricular septum are more common [24]. Such defects are located in one of three positions immediately below the septal leaflet: anteriorly within the membranous interventricular septum; centrally, involving both the membranous and the adjoining muscular septum; or as an isolated VSD of the AV communis type (Fig. 3). It has been proposed that some infravalvular defects develop from membranous VSDs as a result of structural changes that form an aneurysmal pouch with adjacent TV tissue and occur during spontaneous closure [19,24,38,39].

Both the anterior and central defects are immediately below the right and posterior cusps of the aortic valve when viewed from the LV, while the AV communis type extends either posteriorly under the septal leaflet or anteriorly in a plane perpendicular to the long axis of the pulmonary outflow tract. On the left side, this defect is separated from the aortic valve by the membranous septum. Communis type defects are usually large and associated with a cleft tricuspid leaflet or a widened commissural space. They differ from the more common forms of endocardial cushion and abnormalities in that both the atrial septum and the mitral valve are generally intact [19].

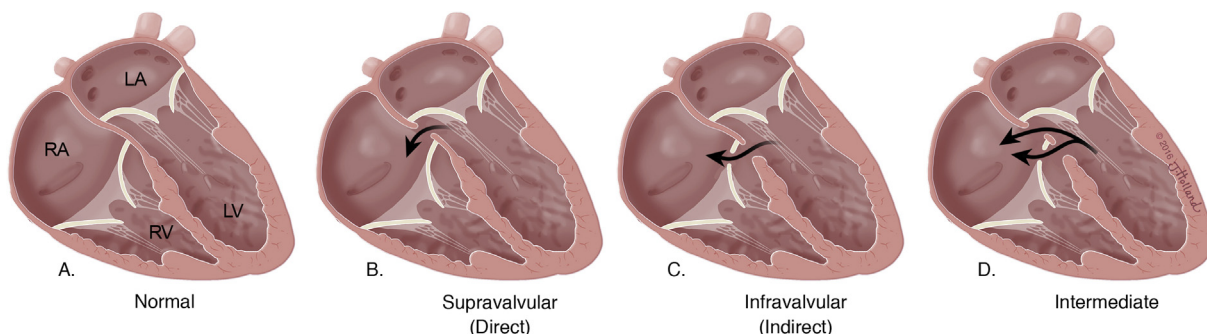


Figure 2. Comparison of normal heart to hearts with Gerbode defect. (A) Normal heart, (B) Supravalyvular defect involving membranous portion of septal wall, superior to the septal leaflet of the tricuspid valve. (C) Infravalvular defect involving membranous portion of septal wall, below the septal leaflet. (D) Both supravalyvular and infravalvular defect with septal leaflet of tricuspid valve. (Illustration by Jessica Holland ©2016, provided under CC-BY-NC-ND 4.0.)



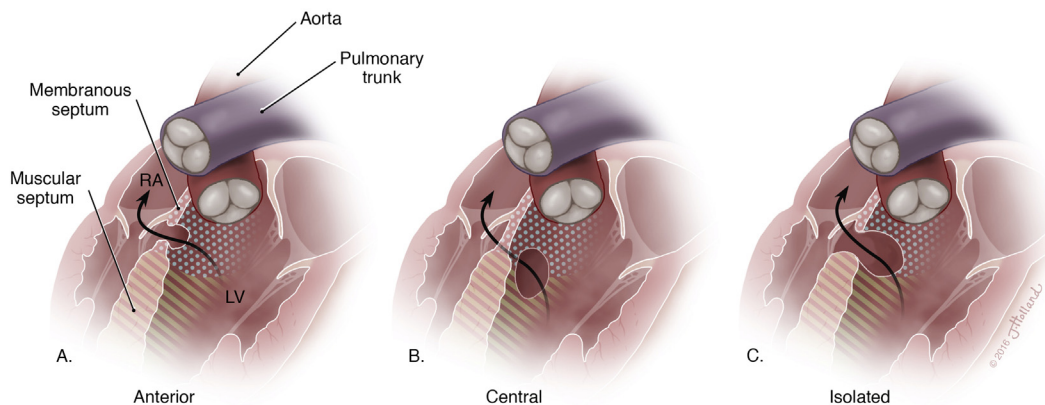


Figure 3. Various positions of infravalvular defects below the septal leaflet. (A) Anterior defect within membranous interventricular septum. (B) Central defect involving both the membranous and muscular septum, (C) Isolated ventricular septal defect resulting from failure of endocardial cushion closure. (Illustration by Jessica Holland ©2016, provided under CC-BY-NC-ND 4.0)

### Pathophysiology

Physiologically, shunting occurs from the LV to RA due to the large pressure gradient that exists between these cardiac chambers [20,24]. Shunting of blood into the RA leads to subsequent increased flow into the right ventricle, leading to enlargement of the right heart chambers [24]. The markedly increased right atrial pressure may require additional workup to distinguish the condition from pulmonary arterial hypertension, which presents similarly [29,31]. If the shunt is large enough, the left heart chambers will also become enlarged due to increased blood volumes thereby further compromising cardiac function [24,32].

Despite primarily being classified as a congenital defect, due to the increased occurrence of invasive cardiovascular procedures and improved cardiac diagnostic techniques, the number of acquired cases of Gerbode defect has increased [13,17,40–45]. Acquired Gerbode defects (AGD) are said to be an uncommon complication of surgery performed near the membranous AV septum [15,40] and are subcategorized into acquired iatrogenic and acquired noniatrogenic (ANIGD) Gerbode defect. Men account for 68% of AGD with the typical age being 49 years at the time of diagnosis and most commonly occurring iatrogenically [7,18].

The two major causes for acquired iatrogenic Gerbode defect are previous cardiac surgery (aortic valve replacement [43,46–50], mitral valve replacement [51,52], VSD-ASD repair [49,53]) and percutaneous cardiac interventions (AV node ablation, endomyocardial biopsy, and tricuspid annuloplasty), which are mainly responsible for

the increase in the past 20 years. Of particular importance is combined tricuspid annuloplasty ring insertion and mitral valve replacement [15,24,46,54] as this may lead to damage to the membranous septum caused by excessive debridement of annular calcium [20,47,51–58]. Endomyocardial biopsy has been reported to cause transient LV-RA shunt [9,59]. These complications can be avoided through meticulous debridement and technical preventive surgical procedures [15,51].

The major causes for ANIGD are endocarditis, myocardial infarction (MI) in the right coronary artery distribution [9,15,24,37,60–62], and blunt cardiac trauma [13,63–65]. Though rare, endocarditis ranks second among causes for acquired LV-RA [7]. Infective endocarditis associated ANIGD has more than doubled in occurrence in the past 10 years. From 1994–2004, there were eight reported cases, compared to 2005–2014, when there were 20 new cases [13]. These cases included prosthetic valve endocarditis (7 cases) and native valve endocarditis [9,37,66–70] of the aortic valve (14 cases), TV (9 cases), and mitral valve (5 cases).

Endocarditis has been shown to cause LV-RA shunt by reopening a congenital defect, widening a small, insignificant shunt or by destructive perforation of the septum [51,71]. For endocarditis patients with fever and septicemia, these general symptoms may mask a new shunt, making it easy to miss [9]. The most common bacteria are *Staphylococcus aureus* (41%) and *Streptococcus* species (17%) [15,40]. It has been reported that LV-RA shunts in association with VSDs increases the risk of endocarditis (58 per 10,000 patient-years) in comparison to typical VSDs or mitral regurgitation

(5.2 per 10,000 patient-years) [15,32]. MI associated ANIGD has been reported with inferior wall MI with the LV-RA shunt located in the basal septum but not anterior wall MI [37,39,72,73]. LV-RA shunt caused by MI has a mortality rate of 80% [9]. However, MI and trauma have not contributed significantly to the increase in incidence of AGD.

## Diagnosis

### *Symptoms*

Manifestation of Gerbode defect varies from asymptomatic to severe heart failure and ultimately to death, depending on the volume and duration of the LV-RA shunt [9]. Small congenital and acquired shunts are usually asymptomatic [15]. However, the systematic review by Yuan [20] revealed that most patients are symptomatic, dyspnea and fever being the prevalent clinical symptoms. Dyspnea occurs when the connection from the high-pressure to the low-pressure RA overwhelms the pulmonary circulation, causing congestion [9]. Larger shunts often present as chest pain and nonspecific left and/or more commonly right heart failure symptoms including shortness of breath, fatigue, weakness, and lower extremity edema [15]. Some of these symptoms, particularly fever, shortness of breath, and ankle swelling can also be due to associated conditions such as septicemia in endocarditis, making a shunt more difficult to diagnose [9,46,74].

### *Physical examination*

The most noticeable physical examination finding of an LV-RA shunt is a characteristic murmur similar to that of a VSD: loud, harsh pansystolic, Grade III–VI, unvarying with respiration and often associated with a thrill along the left sternal border [9,10,20,75,76]. Among all Gerbode patients with a heart murmur, nearly 72% displayed a systolic murmur [20], which is often audible over the entire precordium and radiates posteriorly [15]. It can be difficult to distinguish the systolic murmurs of a VSD from a Gerbode defect, but Vogel-poel et al [77] reported that VSD murmurs can have a higher frequency quality that varies with respiration, becoming softer during inspiration.

Elevated jugular venous pressure, liver pulsation, and peripheral edema indicating right heart failure, are also common [9,47]. They result from longstanding moderate to severe LV to RA shunts causing right heart volume strain and overload [15]. In acute cases, rales can be auscultated [40], when rapid onset of hypotension and jugular vein distension can mimic acute cardiac tamponade [9].

## *Imaging modalities*

### *Transthoracic echocardiography*

The signs and symptoms in addition to a physical examination are not enough to confirm a diagnosis of Gerbode defect. The similarities in clinical presentation between Gerbode and other LV-RA shunts can delay diagnosis or result in misdiagnosis. The main clue to identifying Gerbode defect comes from transesophageal echocardiography (TEE), which has emerged as the diagnostic procedure of choice [76]. Two-dimensional TEE is the most sensitive method for detecting LV-RA shunts [20], especially in patients with prosthetic heart valves [15,24,76,78]. Gerbode defect is highly likely when echocardiographic interrogation, in addition to the history and physical examination, reveals an unusually dilated RA [18].

Color flow Doppler is valuable for revealing high-velocity systolic flow (> 4 m/s) originating from the upper membranous septum and directed toward the RA [16,24,76]. The high flow velocity is best visualized using multiple transducer positions [44] including the parasternal short-axis, apical short-axis, and subcostal views [53], which reflect the gradient between the high-pressure LV and the low-pressure RA [79]. This characteristic stream is highly suggestive of a LV-RA shunt. However, it must be distinguished from other conditions such as ruptured sinus of Valsalva aneurysms, endocardial cushion defects, VSD, and TR [15,34–36,38,39,53,74–81].

To prevent misdiagnosis, the echocardiogram must be interpreted carefully [79]. Silbiger et al [24] specified several key echocardiographic clues suggesting Gerbode defect, including: (1) atypical jet direction; (2) persistent shunt flow into diastole; (3) lack of ventricular septal flattening; (4) no right ventricular hypertrophy; and (5) normal diastolic pulmonary artery pressure as estimated from the pulmonic regurgitant velocity.

Differences in the timing of the shunt flow can help to distinguish Gerbode defect from a ruptured sinus of Valsalva. During systole, Gerbode defect typically produces a left to right shunt, while ruptured sinus of Valsalva aneurysms will also produce diastolic shunting resulting from the diastolic gradient between the aorta and RA [24]. The locus of the high systolic flow from the membranous septum helps to distinguish Gerbode defect from TR, which originates from the valve [24,76]. If this systolic flow is misinterpreted as TR, severe pulmonary arterial hypertension (PAH) will be incorrectly diagnosed [24]. A normal diastolic pulmonary arterial pressure identified from the pulmonic regurgitation jet is helpful for

distinguishing true PAH from the high velocity jet in the RA caused by Gerbode defect [37,76,82].

Two-dimensional TEE has limitations as it is often difficult to pinpoint the anatomical location of the anomaly and its relationship to adjacent structures [15]. For example, it is difficult to visualize a TV defect in a patient with an intravalvular Gerbode lesion using two-dimensional imaging [24], although M-mode echocardiography can reveal an indicative high-frequency systolic fluttering of the TV [24,83]. Real-time (RT) three-dimensional (3D) echocardiography is more suitable for these anatomical anomalies [15,24,84]. RT 3D TEE yields rapid, high resolution anatomical characterization of the shunt [15] while providing accurate assessment of the defect's origin, shape, and size; it can also reveal a hidden shunt [50,80,84,85]. Additionally, it has become an integral part of percutaneous and catheter-based treatment [15], making it the imaging modality of choice for both diagnosis and procedural guidance. Zhang et al [86] recognized the value of 3D TEE in the percutaneous closure of multiple secundum atrial septal defects [20].

#### *Cardiovascular magnetic resonance imaging*

As an adjunct to echocardiography, even more advanced cardiac imaging techniques such as cardiac magnetic resonance (CMR) can reveal further detailed anatomical and physiological information [15]. CMR can enhance the shunt anatomy, measure left and right heart volumes, and quantify shunt flow [49,81,87–89]. This allows shunt ratios and differential flow volumes to be measured accurately [15]. Cheema et al [87] first described the CMR features of Gerbode defect, which demonstrated a flow originating from the membranous portion of the interventricular septum and extending into the RA. Furthermore, phase-contrast CMR imaging enabled the blood shunting across the defect to be quantified, helping clinical decision-making [87].

This imaging modality has disadvantages as well as advantages: high cost, limited availability, and limited portability [15]. CMR is also contraindicated in patients with noncontemporary pacemakers and implantable cardioverter defibrillators [15].

#### *Cardiac catheterization*

With increasing awareness of more refined and precise methods of cardiac investigation by cardiac catheterization and angiocardiography, more Gerbode defect cases have been diagnosed preoperatively [14]. Cardiac catheterization was once

the gold standard for assessing hemodynamic stability, especially for clarifying improperly-characterized TR flow and PAH [15,87]. Recent advances in noninvasive cardiac imaging technology have allowed for cost-efficient and painless visualization of anatomical structures, thus replacing catheterization as the preferred modality for diagnosing LV-RA shunts. Nonetheless, cardiac catheterization can be used to confirm the presence of the communication and the shunt size [15,40]. Cases in the literature that used catheterization revealed increased oxygen saturation from the superior vena cava to the RA [10,90]. The diagnosis of a LV-RA shunt was confirmed by left ventriculography, which demonstrated opacification of a dilated RA prior to the right ventricle [15,19].

#### **Treatment**

The need for treatment of Gerbode defect depends on severity of symptoms, which depend upon factors such as magnitude of shunt, flow volume, development time, concomitant anatomical abnormalities, and comorbidities (e.g., congestive heart failure, valvular leaflet perforation, subannular abscess, and complete heart block) [15,20]. Chronic, asymptomatic, or small defects can be managed conservatively [18]. Toprak et al [91] proposed that asymptomatic patients with insignificant intracardiac shunt, no associated circulatory overload, and no right ventricular volume or pressure overload due to a small LV-RA shunt be kept under close follow-up rather than undergo surgery [20,21].

Conversely, Yacoub et al [92] suggested that all LV-RA defects be repaired, regardless of their size to preclude infective endocarditis. Congenital and acquired LV-RA shunts have traditionally been corrected surgically. Surgical closure has been demonstrated to be feasible with excellent outcome and recommended for closure of all direct Gerbode defects [18,37]. During surgical closures, a patch repair is often performed on the right atrial side in order to prevent recurrence and complications such as AV block [18,20,21,68]. Tatewaki et al [93] reported such a patch repair with sutures from the ventricular side of the TV through the leaflets. Others reported a Dacron patch closure with septal leaflet reimplantation onto the patch [71], an annuloplasty ring implantation, or TV replacement [40,67,71]. Prifti et al [37] noted the usage of two single pledgeted prolene sutures and reconstructed the septal and anterior TV leaflets using an autologous pericardial patch. Their technique allows for reconstruction of the TV, if



necessary, while repairing the defect with one patch that might be beneficial in an infectious presentation [37].

Long-term follow-up results have shown that a small fraction of the LV-RA shunts close spontaneously, while a few develop infective endocarditis during follow-up [20]. It is suggested that patients with an acquired LV-RA shunt receive interventional therapy with the use of the Amplatzer duct occluders to close the shunts [20]. The Amplatzer occluder device is a mainstay in treatment as it provides less radial force [15] than the muscular ventricular septal defect closure device causing fewer complications [37].

Additionally, acquired LV-RA shunts especially the infective and iatrogenic subtypes, are often associated with multiple comorbidities, including congestive heart failure (usually within 6 months if left untreated properly), valvular leaflet perforation, subannular abscess, and complete heart block [21]. These shunts must be operated on, because percutaneous devices cannot be inserted during infection [9].

The development of percutaneous closure options such as the transcatheter closure approach [20,90] has led to fewer surgical procedures [15]. The use of percutaneous transcatheter closure techniques has been used mostly in high-risk surgical candidates due to previous valve replacement, advanced age, anticoagulation, and multiple comorbidities [37].

## Conclusion

The Gerbode defect was originally described in 1838, with further refinements in nomenclature and taxonomy that expanded the classification until the current modifications were in place that accounted for defect type and position with respect to the TV. The etiology is typically congenital with irregularities emerging by perforation of anterior intraventricular septum, malformation of leaflets, or widening of the commissural space. These embryological deviations subsequently permit an abnormal communication that begins the physiological processes leading to pathology. Pathophysiological states that occur subsequent to the defect may require differentiation from other pathologies such as pulmonary arterial hypertension, but such diagnoses can be determined through modalities including echocardiography and CMR. Surgical treatment is performed contingent upon severity of symptoms, management of comorbidities, and other findings as determined by clinical judgment.

## Conflict of interest

All authors have no conflicts of interest to declare.

## Acknowledgments

The authors wish to thank Jessica Holland, MS, Medical Illustrator in the Department of Anatomical Sciences, St. George's University, Grenada, West Indies, for the creation of her illustration used in this publication.

## References

- [1] Loukas M, Hanna M, Alsaiegh N, Shoja MM, Tubbs RS. Clinical anatomy as practiced by Ancient Egyptians. *Clin Anat* 2011;24:409–15.
- [2] Shoja MM, Tubbs RS, Loukas M, Ardan MR. Wrong theories on the origin of blood vessels: Polybus and *De Natura Hominis*. *Int J Cardiol* 2008;126:313–5.
- [3] Shoja MM, Tubbs RS, Loukas M, Ardan MR. The Aristotelian account of "heart and veins". *Int J Cardiol* 2008;125:304–10.
- [4] Shoja MM, Agutter PS, Loukas M, Benninger B, Shokouhi G, Namdar H, et al.. Leonardo da Vinci's studies of the heart. *Int J Cardiol* 2013;167:1126–38.
- [5] Loukas M, Youssef P, Gielecki J, Walocha J, Natsis K, Tubbs RS. History of cardiac anatomy: a comprehensive review from the Egyptians to today. *Clin Anat* 2016;29:270–84.
- [6] Thurnam J. On aneurisms of the heart with cases. *Med Chir Trans* 1838;21:187.
- [7] Buhl, quoted by Meyer H. Ueber angeborene Enge oder Verschluss der Lungenarterienbahn. *Virchows Arch Path Anat* 1857;12:497.
- [8] Hillier T. Congenital malformation of the heart; perforation of the septum ventriculorum, establishing a communication between the left ventricle and the right auricle. *Trans Path Soc Lond* 1859;10:110.
- [9] Sinisalo JP, Sreeram N, Jokinen E, Qureshi SA. Acquired left ventricular-right atrium shunts. *Eur J Cardiothorac Surg* 2014;39:500–6.
- [10] Barclay RS, Reid JM, Coleman EN, Stevenson JG, Welsh TM, McSwan N. Communication between the left ventricle and right atrium. *Thorax* 1967;22:473–7.
- [11] Perry EL, Burchell HB, Edwards JE. Congenital communication between the left ventricle and the right atrium; co-existing ventricular septal defect and double tricuspid orifice. *Mayo Clin Proc* 1949;24:198–206.
- [12] Stahlman M, Kaplan S, Helmsworth JA, Clark LC, Scott Jr HW. Syndrome of left ventricular-right atrial shunt resulting from high interventricular-septal defect associated with defective septal leaflet of the tricuspid valve. *Circulation* 1955;12:813–8.
- [13] Kirby CK, Johnson J, Zinsser HF. Successful closure of a left ventricular-right atrial shunt. *Ann Surg* 1957;145:392–4.
- [14] Gerbode F, Hultgren H, Melrose D, Osborn J. Syndrome of left ventricular-right atrial shunt: successful surgical repair of defect in five cases, with observation of bradycardia on closure. *Ann Surg* 1958;148:433–46.
- [15] Taskesen T, Prouse AF, Goldberg SL, Gill EA. Gerbode defect: another nail for the 3D transesophageal echo hammer? *Int J Cardiovasc Imaging* 2015;31:753–64.
- [16] Wasserman SM, Fann JL, Atwood JE, Burdon TA, Fadel BM. Acquired left ventricular-right atrial communication. *Echocardiography* 2002;19:67–72.



- [17] Tidake A, Gangurde P, Mahajan A. Gerbode defect—a rare defect of atrioventricular septum and tricuspid valve. *J Clin Diagn Res* 2015;9:6–8.
- [18] Kelle AM, Young L, Kaushal S, Duffy CE, Anderson RH, Backer CL. The Gerbode defect: the significance of a left ventricular to right atrial shunt. *Cardiol Young* 2009;19:96–9.
- [19] Riemenschneider TA, Moss AJ. Left ventricular-right atrial communication. *Am J Cardiol* 1967;19:710–8.
- [20] Yuan S. A systematic review of acquired left ventricle to right atrium shunts (Gerbode defects). *Hellenic J Cardiol* 2015;56:357–72.
- [21] Yuan S. Left ventricular to right atrial shunt (Gerbode defect): congenital versus acquired. *Adv Intervent Cardiol* 2014;37:185–94.
- [22] Sadler TW. *Langman's Medical Embryology*. 10th ed. Baltimore: LWW; 2006.
- [23] Moore KL, Persaud TVN. *Before we are born: essentials of embryology and birth defects*. 4th ed. Philadelphia: W.B. Saunders; 1993.
- [24] Silbiger JJ, Kamran M, Handwerker S, Kumar N, Marcali M. The Gerbode defect: left ventricular to right atrial communication—anatomic, hemodynamic, and echocardiographic features. *Echocardiography* 2009;26:993–8.
- [25] Brili SV, Barberis VI, Karamitros IA, Fourlas CA, Stefanadis CI. Mild cyanosis due to coexistence of congenitally corrected transposition of the great arteries and Gerbode-type defect. *Cardiology* 2006;105: 41–2.
- [26] Vizzari G, Pizzino F, Crouch JD, Ammar KA, Gal A, Khandheria BK, et al.. Congenital Gerbode defect in a patient with an acute myocardial infarction and cardiogenic shock masquerading as an acute ventricular septal defect. *J Cardiothorac Vasc Anesth* 2015;29:1311–3.
- [27] Apostolakis S, Konstantinides S. The right ventricle in health and disease: insights into physiology, pathophysiology, and diagnostic management. *Cardiology* 2012;4:263–73.
- [28] Loukas M, Klaassen Z, Tubbs RS. Anatomical observations of the moderator band. *Clin Anat* 2010;23:443–50.
- [29] Allwork SP, Anderson RH. Developmental anatomy of the membranous part of the ventricular septum in the human heart. *Br Heart J* 1979;4:275–80.
- [30] Lin CJ, Lin CY, Chen CH, Zhou B, Chang CP. Partitioning the heart: mechanisms of cardiac septation and valve development. *Development* 2012;139:3277–9.
- [31] Grignola JC. Hemodynamic assessment of pulmonary hypertension. *World J Cardiol* 2011;3:10–7.
- [32] Wu MH, Chang CI, Wang JK, Lue HC. Characterization of aneurysmal transformation in perimembranous ventricular septal defects: an adhered anterior leaflet of tricuspid valve predisposes to the development of left ventricular-to-right atrial shunt. *Int J Cardiol* 1994;47:117–25.
- [33] Sakakibara S, Konno S. Congenital aneurysm of the sinus of Valsalva anatomy and classification. *Am Heart J* 1962;63:405–24.
- [34] Burrows PE, Fellows KE, Keane JF. Cineangiography of the perimembranous ventricular septal defect with left ventricular–right atrial shunt. *J Am Coll Cardiol* 1983;1:1129–34.
- [35] Komai H, Naito Y, Fujiwara K, Takagaki Y, Nishimura Y, Kawasaki S. An unusual variation of left ventricular–right atrial communication. *Surg Today* 1996;26:825–7.
- [36] Rosenquist GC, Sweeney LJ. Normal variations in tricuspid valve attachments to the membranous ventricular septum: a clue to the etiology of left ventricle-to-right atrial communication. *Am Heart J* 1975;89:186–8.
- [37] Prifti E, Ademaj F, Baboci A, Demiraj A. Acquired Gerbode defect following endocarditis of the tricuspid valve: a case report and literature review. *J Cardiothorac Surg* 2015;10:115.
- [38] Anderson RH, Lenox CC, Zuberbuhler JR. Mechanisms of closure of perimembranous ventricular septal defect. *Am J Cardiol* 1983;52:341–5.
- [39] Menon V, Webb JG, Hillis LD, Sleeper LA, Abboud R, Dzavik V, et al.. Outcome and profile of ventricular septal rupture with cardiogenic shock after myocardial infarction: a report from the SHOCK trial registry. Should we emergently revascularize occluded coronaries in cardiogenic shock? *J Am Coll Cardiol* 2000;36:1110–6.
- [40] Elian D, Di Segni E, Kaplinsky E, Mohr R, Vered Z. Acquired left ventricular–right atrial communication caused by infective endocarditis detected by transesophageal echocardiography: case report and review of the literature. *J Am Soc Echocardiogr* 1995;8:108–10.
- [41] Laurichesse J, Ferrane J, Scebat L, et al.. Communication between the left ventricle and the right auricle. *Arch Mal Coeur* 1964;57:703–24.
- [42] Cabalka AK, Hagler DJ, Mookadam F, Chandrasekaran K, Wright RS. Percutaneous closure of left ventricular-to-right atrial fistula after prosthetic mitral valve replacement using the amplatzer duct occluder. *Catheter Cardiovasc Interv* 2005;64:522–7.
- [43] Weinrich M, Graeter TP, Langer F, Schafers HJ. Left ventricular–right atrial fistula complicating redo mitral valve replacement. *Ann Thorac Surg* 2001;71:343–5.
- [44] Shen WK, Khandheria BK. Transesophageal echocardiography: detection of an acquired left ventricular–right atrial shunt. *J Am Soc Echocardiogr* 1991;4:199–202.
- [45] Watanabe A, Kazui T, Tsukamoto M, Komatsu S. Left ventricular pseudoaneurysm and intracardiac fistulas after replacement of mitral valve prosthesis. *Ann Thorac Surg* 1993;55:1236–9.
- [46] Benisty J, Roller M, Sahar G, Paz R, Vidne B, Sagie A. Iatrogenic left ventricular–right atrial fistula following mitral valve replacement and tricuspid annuloplasty: diagnosis by transthoracic and transesophageal echocardiography. *J Heart Valve Dis* 2000;9:732–5.
- [47] Frigg C, Cassina T, Siclari F, Mauri R. Unusual complication after aortic valve replacement. *Interactive Cardiovasc Thor Surg* 2008;7:149–50.
- [48] Silverman NA, Sethi GK, Scott SM. Acquired left ventricular–right atrial fistula following aortic valve replacement. *Ann Thorac Surg* 1980;30:482–6.
- [49] Trehan V, Ramakrishnan S, Goyal NK. Successful device closure of an acquired Gerbode defect. *Catheter Cardiovasc Interv* 2006;68:942–5.
- [50] Yared K, Solis J, Passeri J, King ME, Levine RA. Three-dimensional echocardiographic assessment of acquired left ventricular to right atrial shunt (Gerbode defect). *J Am Soc Echocardiogr* 2009;22:435.e.
- [51] Marsten JL, Hildner FJ. Left ventricular–right atrial communication following valve replacement. *J Thorac Cardiovasc Surg* 1969;58:588–91.
- [52] Seabra-Gomes R, Ross DN, Gonzalez-Lavin L. Iatrogenic left ventricular–right atrial fistula following mitral valve replacement. *Thorax* 1973;28:235–41.
- [53] Dzwonczyk T, Davidson Jr WR. The spectrum of left ventricular–right atrial communications in the adult: essentials of echocardiographic assessment. *J Am Soc Echocardiogr* 1995;8:263–9.
- [54] Aoyagi S, Arinaga K, Oda T, Hori H. Left ventricular–right atrial communication following tricuspid annuloplasty. *Eur J Cardiothorac Surg* 2008;34:680–1.
- [55] Dadkhah R, Friart A, Leclerc JL, Moreels M, Haberman D, Lienart F. Uncommon acquired Gerbode defect (left ventricular to right atrial communication) following a tricuspid annuloplasty without concomitant mitral surgery. *Eur J Echocardiogr* 2009;10:579–81.
- [56] Tayama E, Tomita Y, Imasaka K, Kono T. Iatrogenic left ventricular–right atrial communication after tricuspid annuloplasty; a case report. *J Cardiothorac Surg* 2014;9:104.

- [57] Amirghofran AA, Emaminia A. Left ventricular–right atrial communication (Gerbode-type defect) following mitral valve replacement. *J Card Surg* 2009;24:474–6.
- [58] Elmistekawy E, Dickie S, Nicholson D, et al. Left ventricular outflow tract–right atrial fistula following aortic valve replacement. *J Card Surg* 2012;27:570–2.
- [59] Katta S, Akosah K, Stambler B, Salter D, Guerraty A, Mohanty PK. Atrioventricular fistula: an unusual complication of endomyocardial biopsy in a heart transplant recipient. *J Am Soc Echocardiogr* 1994;7:405–9.
- [60] Doig JC, Au J, Dark JH, Furniss SS. Post-infarction communication between a left ventricular aneurysm and the right atrium. *Eur Heart J* 1992;13:1006–7.
- [61] Newman NJ, Rozanski L, Kreulen T. Acquired left ventricular to right atrial intracardiac shunt after myocardial infarction: A case report and review of the literature. *J Am Soc Echocardiogr* 1996;9:716–20.
- [62] Jobic Y, Verdun F, Guillo P, Bezon E, Gilard M, Etienne Y, et al. Postinfarction atrioventricular septal rupture. *J Am Soc Echocardiogr* 1997;10:680–4.
- [63] Olsovsky MR, Topaz O, DiSciascio G, Vetrovec GW. Acute traumatic ventricular septal rupture. *Am Heart J* 1996;131:1039–41.
- [64] Venkatesh G, Lonn EM, Holder DA, Williams WG, Mulji A. Acquired left ventricular to right atrial communication and complete heart block following nonpenetrating cardiac trauma. *Can J Cardiol* 1996;12:349–52.
- [65] Selinger L, Werner K, Silber R, Nellesen U, Inselmann G. Natural history of a ventriculoatrial fistula after a gunshot injury in 1945. *Ann Thorac Surg* 1998;65:1137–8.
- [66] Inoue H, Iguro Y, Kinjo T, Matsumoto H, Yotsumoto G, Sakata R. Acquired left ventricular–right atrial communication and severe aortic valve regurgitation caused by infective endocarditis. *Thorac Cardiovasc Surg* 2009;57:54–6.
- [67] Battin M, Fong LV, Monro JL. Gerbode ventricular septal defect following endocarditis. *Eur J Cardiothorac Surg* 1991;5:613–4.
- [68] Hsu SY, Shen TC. A spontaneously closed, acquired supra-valvular Gerbode defect mimicking an unruptured sinus of Valsalva aneurysm. *Eur Heart J Cardiovasc Imaging* 2014;15:471.
- [69] Aberg T, Johansson L, Michaelsson M, Rhedin B. Left ventricular–right atrial shunt of septic origin: presentation of a case with surgical closure. *J Thorac Cardiovasc Surg* 1971;61:212–6.
- [70] Ellis CJ, Gray KE, Ainscow DAP. Left ventricular to right atrial shunt resulting from infective endocarditis. *Thorax* 1975;30:118–20.
- [71] Velebit V, Schöneberger A, Ciaroni S, Bloch A, Maurice J, Christenson JT, et al. “Acquired” left ventricular-to-right atrial shunt (Gerbode defect) after bacterial endocarditis. *Tex Heart Inst J* 1995;22:100–2.
- [72] Edwards BS, Edwards WD, Edwards JE. Ventricular septal rupture complicating acute myocardial infarction: identification of simple and complex types in 53 autopsied hearts. *Am J Cardiol* 1984;54:1201–5.
- [73] Crenshaw BS, Granger CB, Birnbaum Y, Pieper KS, Morris DC, Kleiman NS, et al. Risk factors, angiographic patterns, and outcomes in patients with ventricular septal defect complicating acute myocardial infarction. GUSTO-I (global utilization of streptokinase and TPA for occluded coronary arteries) trial investigators. *Circulation* 2000;101:27–32.
- [74] Cantor S, Sanderson R, Cohn K. Left ventricular–right atrial shunt due to bacterial endocarditis. *Chest* 1971;60:552–4.
- [75] Can I, Krueger K, Chandrashekar Y, Li JM, Dykoski R, Tholakanahalli VN. Gerbode-type defect induced by catheter ablation of the atrioventricular node. *Circulation* 2009;119(22):e553–6.
- [76] Uslu N, Kayacioglu I, Ates M, Eren M. ‘Acquired’ left ventricular to right atrial shunt after mitral valve replacement: detection by transthoracic colour Doppler echocardiography. *Can J Cardiol* 2007;23:735–6.
- [77] Vogelpoel L, Schrire V, Beck W, Nellen M, Swanepoel A. The atypical systolic murmur of minute ventricular septal defect and its recognition by amyl nitrite and phenylephrine. *Am Heart J* 1961;62:101–18.
- [78] Katz ES, Tunick PA, Kronzon I. To-and-fro left ventricular-to-right atrial shunting after valve replacement shown by transesophageal echocardiography. *Am Heart J* 1991;121:211–4.
- [79] Tehrani F, Movahed MR. How to prevent echocardiographic misinterpretation of Gerbode type defect as pulmonary arterial hypertension. *Eur J Echocardiogr* 2007;8:494–7.
- [80] Hansalia S, Manda J, Pothineni KR, Nanda NC. Usefulness of live/real time three-dimensional transthoracic echocardiography in diagnosing acquired left ventricular–right atrial communication misdiagnosed as severe pulmonary hypertension by two-dimensional transthoracic echocardiography. *Echocardiography* 2009;26:224–7.
- [81] Desai RV, Seghatol-Eslami F, Nabavizadeh F, Lloyd SG. Unusual mechanism of tricuspid regurgitation in ventricular septal defect. *Echocardiography* 2011;28:E36–8.
- [82] Saiki Y, Kawase M, Ida T, Mannouji E, Kasegawa H, Takahashi Y, et al. The successful surgical repair of a left ventricular–right atrial communication and aneurysm of the mitral valve caused by infective endocarditis: report of a case. *Surg Today*. 1994;24:655–8.
- [83] Grenadier E, Shem-Tov A, Motro M, Palant A. Echocardiographic diagnosis of left ventricular–right atrial communication. *Am Heart J* 1981;106:407–9.
- [84] Acar P, Seguela PE, Hascoet S. The Gerbode defect or left ventricular to right atrial shunt assessed by transthoracic 3D echocardiography. *Echocardiography* 2011;28:E140–2.
- [85] Notarangelo MF, Bontardelli F, Taliani U, Agostinelli A, Vignali L, Ardissino D. A rare ventricular septal defect: a case report. *G Ital Cardiol* 2013;14:283–5.
- [86] Zhang C, Li Z, Xu J. Real-time three-dimensional transesophageal echocardiography is useful for percutaneous closure of multiple secundum atrial septal defects. *Hellenic J Cardiol* 2014;55:486–91.
- [87] Cheema OM, Patel AA, Chang SM, Shah DJ. Gerbode ventricular septal defect diagnosed at cardiac MR imaging: case report. *Radiology* 2009;252:50–2.
- [88] Chaturvedi A, Lau R, Kicska G, Reddy GP. MR findings in iatrogenic Gerbode defect. *Int J Cardiovasc Imaging* 2013;29:3–4.
- [89] Mousavi N, Shook DC, Kilcullen N, Aranki S, Kwong RY, Landzberg MJ, et al. Multimodality imaging of a Gerbode defect. *Circulation* 2012;126:e1–2.
- [90] Dangol A, Bansal M, Al-Khatib Y. Transcatheter closure of acquired left ventricle-to-right atrium shunt: first case report in an infant and review of the literature. *Pediatr Cardiol* 2013;34:1258–60.
- [91] Toprak C, Kahveci G, Akpinar S, Tabakçi MM, Güler Y. Concomitant Gerbode-like defect and anterior mitral leaflet perforation after aortic valve replacement for endocarditis. *Echocardiography* 2013;30:E231–5.
- [92] Yacoub MH, Mansur A, Towers M, Westbury H. Bacterial endocarditis complicating left ventricle to right atrium communication. *Br J Dis Chest* 1972;66:78–82.
- [93] Tatewaki H, Alesnik J, Morales D. Acquired left ventricle to right atrial shunt (Gerbode defect) and massive pulmonary embolus [Internet]. <http://www.ctsnet.org/sections/clinical-resources/clinicalcases/article-14> [Accessed 16 November 2016].