

[CASE REPORT]

Familial HLA-B*52 Vasculitis: Maternal, Atypical Cogan's Syndrome with Takayasu Arteritis-mimicking Aortitis and Filial Takayasu Arteritis

Satoshi Morinaka¹, Yohei Takano¹, Hiroto Tsuboi², Daisuke Goto^{1,3} and Takayuki Sumida²

Abstract:

Cogan's syndrome (CS), a rare vasculitis characterized by non-syphilitic, interstitial keratitis and Ménière-like attacks, is classified into "typical" and "atypical" forms, while Takayasu arteritis (TAK) is a rare large-vessel vasculitis associated with human leukocyte antigen (HLA)-B*52. Very few cases meet both the CS and TAK classification criteria. We herein report a 53-year-old woman diagnosed with atypical CS and aortitis similar to TAK. Her 25-year-old daughter manifested TAK without symptoms of CS, and both are HLA-B*52 positive. Our case highlights the difficulties of distinguishing aortitis with atypical CS from aortitis with TAK.

Key words: Cogan's syndrome, Takayasu arteritis, HLA-B*52, hearing loss, aortitis

(Intern Med 59: 1899-1904, 2020)

(DOI: 10.2169/internalmedicine.4067-19)

Introduction

Cogan's syndrome (CS) is a very rare chronic vasculitis, classically characterized by interstitial keratitis (IK) and vestibuloauditory symptoms. It may include arteritis (affecting small, medium, or large arteries), aortitis, aortic aneurysms, and aortic and mitral valvulitis (1). Recently, Haynes et al. reported atypical CS, which includes vestibuloauditory dysfunction with various inflammatory eye diseases (e.g., conjunctivitis, scleritis, uveitis, optic disk edema, or retinal vasculitis) other than IK (2). However, the associations between CS and the human leukocyte antigen (HLA) system remain unknown (3).

Takayasu arteritis (TAK) is a rare, chronic large-vessel vasculitis of the aorta and its major branches often found in young women. Ocular manifestations and vision loss associated with concomitant flow-limiting of the carotid or vertebral artery may occur (4), but sensorineural hearing loss (SNHL), often due to steroid-dependent sensorineural hearing loss (SDSNHL), is rare (5). A firm association between

TAK and HLA-B*52 has been established (6).

There are few case reports of CS overlapping with TAK (7, 8). However, aortitis occurs in about 10% of patients with CS (9). It seems to be difficult to distinguish aortitis associated with CS and CS overlapping with TAK. We herein report a 53-year-old woman afflicted by atypical CS with HLA-B*52 and aortitis similar to TAK. Her 25-year-old daughter was also confirmed to have HLA-B*52-positive TAK but without CS manifestation.

Case Report

A 53-year-old Japanese woman with a 2-year history of bilateral hearing loss and vertigo presented with acute breathlessness and left back pain at night. Steroid treatment for a previous diagnosis of sudden deafness was unsuccessful, and her previous conjunctival hyperemia in the left eye had remained unresolved for an entire year. The ophthalmologist had continued steroid eyedrop therapy, but the patient was experiencing a continuous cycle of symptomatic remission and relapse. There was no headache, fever, weight

¹Division of Rheumatology, Ibaraki Prefectural Central Hospital, Japan, ²Division of Rheumatology, Department of Internal Medicine, Faculty of Medicine, University of Tsukuba, Japan and ³Division of Rheumatology, Ibaraki Clinical Education and Training Center, Tsukuba University Hospital, Japan

Received: October 17, 2019; Accepted: March 4, 2020; Advance Publication by J-STAGE: April 23, 2020

Correspondence to Dr. Takayuki Sumida, tsumida@md.tsukuba.ac.jp

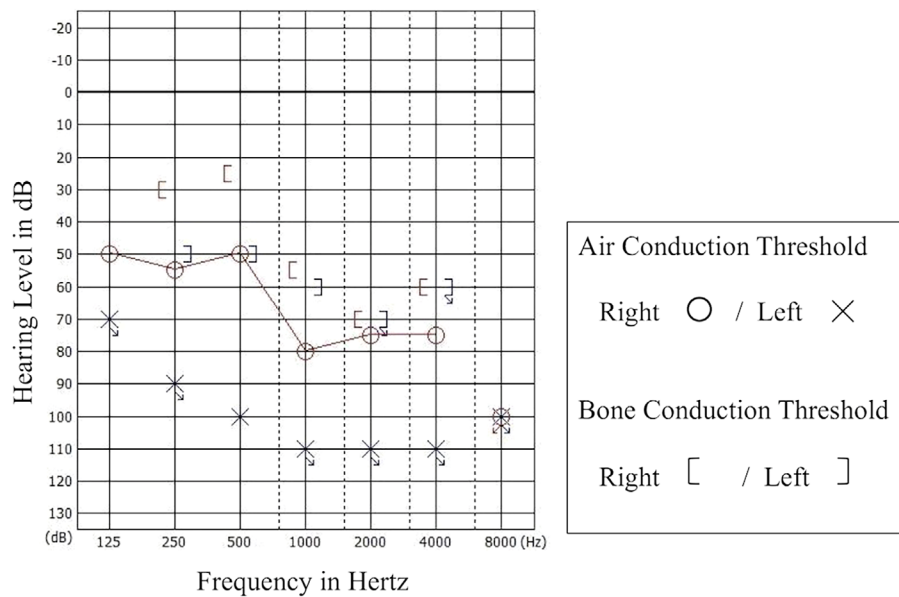


Figure 1. An ear audiogram showing bilateral sensorineural hearing loss.

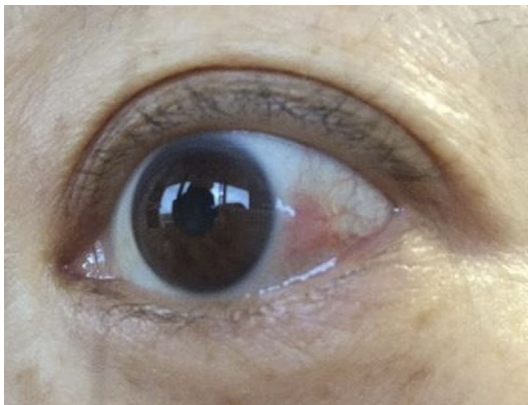


Figure 2. Left eye showing conjunctival hyperemia.

loss, numbness of the arms, or jaw claudication. A two-year history of high blood pressure also remained untreated. The patient neither smoked nor consumed alcohol and had three daughters, one of whom was afflicted with TAK.

A physical examination revealed a pulse rate of 131/min with a decreased left brachial artery pulse. Her blood pressure was 230/93 mmHg in the right arm and 160/88 mmHg in the left, body temperature was 37.1 °C, and respiratory rate was 28/min with an oxygen saturation of 99% on room air. No bruit was audible in the neck and chest. Diastolic regurgitant murmurs were observed along the left sternal border. Her lungs were clear to auscultation. There was bilateral sensorineural hearing loss with deafness on the left side (Fig. 1). Episcleritis was observed in the left eye upon a slit-lamp examination (Fig. 2).

The laboratory test findings were as follows: C-reactive protein, 1.50 mg/dL; erythrocyte sedimentation rate (ESR), 96 mm/h; white blood cells, 7,400/ μ L (lymphocyte count, 2,300/ μ L); hemoglobin, 9.8 g/dL, aspartate transaminase, 11 U/L; alanine transaminase, 8 U/L; creatinine, 0.50 mg/dL;

hemoglobin A1c, 6.2%; immunoglobulin G, 2,578 mg/dL; and soluble interleukin-2 receptor (sIL-2R), 242 U/mL (normal range <496 U/mL). Complement fractions C3 and C4 were increased, but rheumatoid factor, antinuclear antibodies, and anti-neutrophil cytoplasmic antibodies were all negative. Serology for hepatitis B, hepatitis C, HIV, and syphilis, in addition to interferon-gamma release assays (T-SPOT.TB), were also negative.

Electrocardiography (ECG) and chest radiograph results were normal, but echocardiography revealed moderate aortic regurgitation (AR). Contrast-enhanced computed tomography (CT) showed a low-density area around the ascending aorta, aortic arch, bilateral common carotid artery, and left subclavian artery (Fig. 3A). It also revealed narrowing of the left carotid artery and subclavian artery, leading us to suspect acute aortic dissection and vasculitis. After admission, we performed contrast-enhanced magnetic resonance angiography (MRA), which showed narrowing of the left carotid and subclavian arteries as well as an inability to visualize the left vertebral artery (Fig. 3B). Carotid ultrasonography confirmed the “Macaroni Sign” of the left carotid artery, which showed long, homogeneous, isoechoic, circumferential wall thickening (10). The intima-media thickness (IMT) of the left common carotid artery was 1.61 to 2.04 mm, and the mean IMT was 1.75 mm (maximal normal value: 0.6 mm) (Fig. 3C).

Based on these findings, we finally diagnosed the patient with atypical Cogan’s syndrome (CS) based on her bilateral sensorineural deafness and vertigo plus episcleritis without interstitial keratitis (IK) within two years (2). Since CS is a rare disease with no signature test, the diagnosis is based on the clinical findings (mandatory criteria: sensorineural hearing loss and inflammatory ocular disease) rather than any established diagnostic criteria (11). Furthermore, 3 out of 6 diagnostic criteria for TAK based on the 1990 American

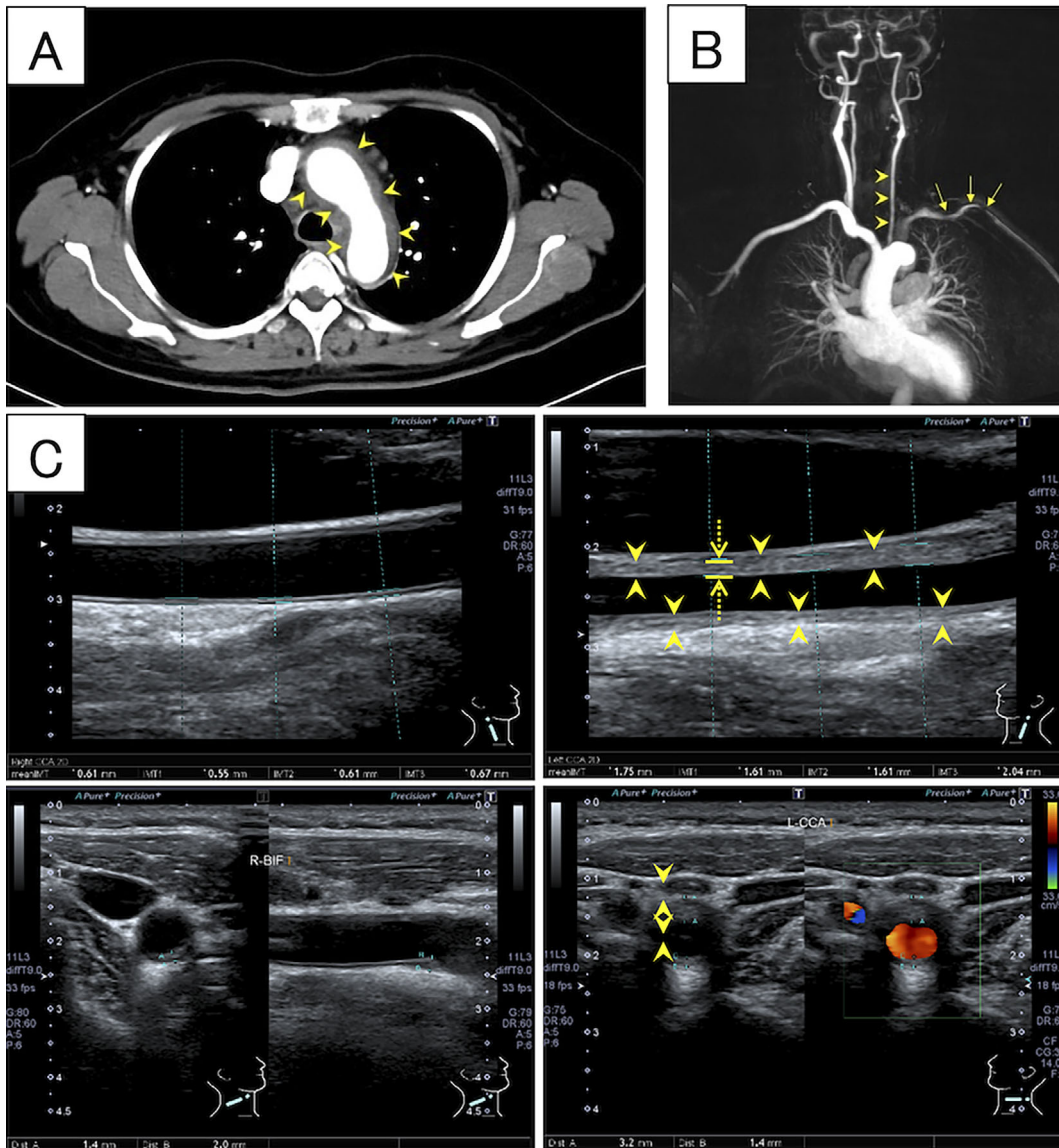


Figure 3. Image findings of arteritis. A) Contrast-enhanced computed tomography (CT) of the aortic arch. CT showing thickened walls of the aortic arch (arrowheads). B) Contrast-enhanced magnetic resonance angiography (MRA) of the neck and chest. MRA showing a narrowing of the left carotid artery (arrowheads) and left subclavian artery (arrows) plus non-visualization of the left vertebral artery. C) Ultrasonography of the common carotid artery. Left upper panel) Right, longitudinal section. Right upper panel) Left, longitudinal section. “Macaroni Sign” visible as long, homogeneous, isoechoic wall thickening (arrowheads). Dotted arrows indicate the intima-media thickness (IMT). Left lower panel) Right, transversal section. Right lower panel) Left, transversal section. Circumferential wall thickening (arrowheads).

College of Rheumatology (ACR) guidelines were met, namely a decreased brachial artery pulse, a difference of > 10 mmHg in the systolic blood pressure between arms, and arteriographic narrowing of the aorta and subclavian artery (12).

The patient’s 25-year-old daughter had also developed TAK at the age of 21. At the first visit, she had a fever ranging from 37 to 38 °C, fatigue in the left upper extremity during work, and disappearance of the left brachial artery pulse. Her blood pressure was 123/65 mmHg in the right arm and not measurable in the left. Contrast-enhanced CT revealed stenosis of the left subclavian artery and left verte-

bral artery. The diagnosis was based on the presence of 5 of the 6 ACR 1990 criteria for the classification of TAK (12). Prednisolone and tocilizumab therapy was started at our hospital, but in contrast to her mother, the daughter never manifested ocular or vestibuloauditory symptoms and was therefore not diagnosed with CS (11). We performed HLA-I allele typing for both the patient and her daughter after receiving their informed consent. Both had the HLA-B*52 allele, which strongly suggests TAK involvement (6).

The patient was treated with 50 mg of daily oral prednisolone (0.8 mg/kg/day) therapy, which led to the resolution of her left back pain, conjunctival hyperemia in the left eye,

and declining C-reactive protein (CRP) and ESR levels. We gradually reduced prednisolone to 30 mg/day by week 5, but the hearing loss did not resolve, even after a pulse of 1 g of intravenous methylprednisolone. Carotid ultrasonography showed that the mean IMT of the left common carotid artery had improved from 1.75 to 1.01 mm. Prednisolone was then reduced to 10 mg/day over the next 9 months. The patient is currently under regular follow-up and remains in remission.

Discussion

CS is rare, particularly in young adults, with an average onset age of 29 years old and no gender bias. Its etiology is unknown, but is thought to be related to upper respiratory tract infections (1). In 2014, Bonaguri et al. published a study that suggested the usefulness of anti-heat shock protein 70 (anti-Hsp70) antibodies in distinguishing typical from atypical CS and also presented a significant association with sensorineural hearing loss (13). In 2018, Kawasaki et al. published two cases suggesting an association with *Chlamydia trachomatis* infection and CS due to anti-Hsp70 antibodies being simultaneously produced against Hsp60 antigens found on *C. trachomatis* (8). However, they analyzed titers of serum antibodies to *Chlamydia* species but not serum anti-Hsp70 antibodies, and furthermore, both of their cases were “atypical” CS and not the “typical” CS that is often positive for anti-Hsp70 antibodies. Thus, the notion of a bacterial infection being causative for CS remains controversial.

Other findings suggest that CS is an autoimmune disease, as a 2002 report by Lunardi et al. revealed Cogan peptides in the serum of all studied patients. Purified peptide-specific autoantibodies from these patients caused hearing loss and interstitial keratitis with glaucoma in rabbits (14). Thus, the mechanistic origin of the systemic symptoms may be autoimmune vasculitis within diverse blood vessels (15).

TAK is a rare, large-vessel vasculitis mostly seen in young women, and female-to-male ratios range between 5 and 12 to 1, although the reason for this predominance is unknown. In the past, TAK was mostly reported in Asian populations, but it is now known to be distributed worldwide (4). The associations between TAK and HLA-B*52 have been established, as HLA-B*52 is the only gene that relates to TAK beyond ethnicity. Therefore, it is obvious that TAK shares a high prevalence with HLA-B*52 in Asia (6). The etiology of TAK has not yet been established, although previous studies have shown the involvement of several triggers (genetic predisposition, environmental triggers, microorganisms, and/or their antigenic components), pathogenic effector T cells, macrophages, and decreases in Treg cells (4). In 2018, Terao et al. published a study suggesting an interactive effect between leukocyte immunoglobulin-like receptor (LILR) A3 and HLA-B*52 in TAK, as HLA-B expresses HLA class I molecules on the surface of organ tissue cells (16). However, LILRA3 is the only member of the

LILR family that encodes a soluble protein that binds to HLA class I molecules and regulates the NK cell activity. It is therefore suggested that the overactivation of NK cells may be involved with pathogenesis of TAK (16).

There are few reports of TAK overlapping with atypical CS. In 1998, Raza et al. reported a case of atypical CS with TAK (7) while in 2018, Kawasaki et al. reported a case of atypical CS with HLA-B*52-positive TAK (8). In the present study, we encountered a case of atypical CS with HLA-B*52 and aortitis similar to TAK. These three cases met the classification criteria for both CS and TAK (Table), but even CS alone may be complicated by aortitis. Is it therefore possible to prove that TAK overlaps with CS?

The ocular involvement in typical CS is very characteristic, and IK, particularly in syphilis, is part of Hutchinson’s triad. In syphilis, IK results from lymphocyte infiltration and blood vessel invasion (normal cornea have no blood vessels) caused by the immune response to foreign antigens rather than direct infection (17). For this reason, the presence or absence of IK is a critical factor in the classification of CS, but other probable inflammatory eye diseases in atypical CS are due to small vessel vasculitis. In contrast, the ocular manifestations in TAK are associated with flow-limited carotid or vertebral arteries with retinal involvement due to hypoperfusion from an occluded internal carotid artery (4).

The vestibuloauditory involvement in CS is complicated. Typical CS often tests positive for anti-Hsp70 antibodies, which suggests immunological mechanisms of SNHL (13). In atypical CS, however, the pathogenesis remains unclear but may rely on small-vessel vasculitis of the inner ear. Hearing loss, likely due to small-vessel vasculitis, is severe and usually irreversible in CS compared to the rarer SNHL in TAK with large-vessel vasculitis (1). Most cases of SNHL associated with TAK are steroid-dependent (18). Vertigo or dizziness in TAK is not caused by vasculitis in the inner ear but is instead thought to be caused by ischemia or an inflammatory, hyperactive carotid sinus reflex (19).

Our case highlights the fact that the diagnostic criteria for CS and TAK may be met simultaneously. As aortitis associated with CS was indistinguishable from TAK in our case, we were unable to diagnose any overlap of CS and TAK. This is in line with previously reported cases that also showed no strong evidence of disease overlap. In the case of Raza et al., hearing loss improved with steroid treatment, which is consistent with SDSNHL associated with TAK, but this treatment may have been successful because of the early point of intervention (7). However, in the case of Kawasaki et al., the course of hearing loss was not shown. In both our case and the Kawasaki et al. cases, HLA-B*52 was positive, but whether or not this increased the risk of aortitis, even in CS, is unclear.

Typing HLA-B*52 can be clinically useful from three points of view. First, we may be able to understand the difference between CS with aortitis and CS-overlapping TAK in the future, although there have been no reports of HLA-B*52 positivity in CS alone to date. Second, two of the three

Table. Cases That Fulfill Classification Criteria for Both Cogan's Syndrome and Takayasu Arteritis.

Case	Age	Gender	Onset	Type of CS	Location of aortitis	ACR criteria for TAK	HLA-B	Max CRP (mg/dL)	Treatment	Prognosis			Ref.
										ear	eye	Aortitis	
1	58	female	CS → TAK (1 month interval)	atypical	left subclavian artery	5 of 6	unknown	7.10	PSL, pulse of mPSL, AZA add-on-PSL, IVCY, later MTX add-on-PSL	remission	remission	remission	[7]
2	44	female	CS → TAK (2 years interval)	atypical	ascending aorta, pulmonary artery, left subclavian artery	3 of 6	B*52	22.69	PSL	no change	unknown	remission	[8]
Present Case	53	female	CS → Aortitis (2 years interval)	atypical	ascending aorta, aortic arch, bilateral common carotid artery, left subclavian artery	3 of 6	B*52	1.50	PSL, pulse of mPSL	no change	remission	remission	

CS: Cogan's syndrome, TAK: Takayasu arteritis, ACR criteria for TAK: number of the six American College of Rheumatology 1990 criteria for the classification of Takayasu arteritis (age at disease onset ≤40 years; claudication of extremities; decreased brachial artery pulse; >10 mmHg difference in systolic blood pressure between the two arms; Bruit over subclavian arteries or aorta; angiographic narrowing of a large upper extremity artery), HLA-B: Human Leukocyte Antigen-B, CRP: C-reactive protein, Ref.: Reference, PSL: prednisolone, mPSL: methylprednisolone, AZA: azathioprine, IVCY: intravenous cyclophosphamide, MTX: methotrexate

cases (including the presently reported case) met the classification criteria for both CS and TAK and were HLA-B*52-positive (the third had an unknown HLA-B*52 status) (Table). Furthermore, all three cases were atypical CS, and CS preceded TAK or aortitis (Table). We believe that typing HLA-B*52 when diagnosing atypical CS may help predict future aortitis complications. Third, tocilizumab is approved for the treatment of TAK in Japan. If atypical CS is associated with aortitis, proving the existence of overlapping TAK would enable the administration of tocilizumab in addition to conventional steroid therapy for CS treatment.

In conclusion, it is difficult to distinguish aortitis associated with CS and TAK. The element of vasculitis is stronger in atypical CS than in typical CS, and we propose that atypical CS with HLA-B*52 may present with a pathology similar to TAK. We suggest typing HLA-B*52 in atypical CS for the accumulation of more cases.

Written, informed consent for this case report was obtained from the patients.

The authors state that they have no Conflict of Interest (COI).

Acknowledgement

We thank Dr. Bryan J. Mathis of the Medical English Communications Center, University of Tsukuba, for language review of this manuscript.

References

- Iliescu DA, Timaru CM, Batras M, De Simone A, Stefan C. Cogan's Syndrome. *Romanian J Ophthalmol* **59**: 6-13, 2015.
- Haynes BF, Kaiser-Kupfer MI, Mason P, Fauci AS. Cogan syndrome: studies in thirteen patients, long-term follow-up, and a review of the literature. *Medicine (Baltimore)* **59**: 426-441, 1980.
- Ladas ID. Histocompatibility (HLA) antigens and eye diseases other than uveitis. *Surv Ophthalmol* **27**: 233-244, 1983.
- Zaldivar Villon MLF, de la Rocha JAL, Espinoza LR. Takayasu arteritis: recent developments. *Curr Rheumatol Rep* **21**: 45, 2019.
- Kanzaki J, Kanzaki S, Ogawa K. Long-term prognosis of steroid-dependent sensorineural hearing loss. *Audiol Neurotol* **14**: 26-34, 2009.
- Takamura C, Ohhigashi H, Ebana Y, Isobe M. New human leukocyte antigen risk allele in Japanese patients with Takayasu arteritis. *Circ J* **76**: 1697-1702, 2012.
- Raza K, Karokis D, Kitas GD. Cogan's syndrome with Takayasu's arteritis. *Br J Rheumatol* **37**: 369-372, 1998.
- Kawasaki Y, Uehara T, Kawana S. Cutaneous vasculitis in Cogan's syndrome: a report of two cases associated with chlamydia infection. *J Nippon Med Sch* **85**: 172-177, 2018.
- Kessel A, Vadasz Z, Toubi E. Cogan syndrome-pathogenesis, clinical variants and treatment approaches. *Autoimmun Rev* **13**: 351-354, 2014.
- Ghembaza MEA, Boulenouar F, Lounici A. "Macaroni Sign" in Takayasu arteritis. *J Cardiovasc Imaging* **26**: 186-187, 2018.
- Tayer-Shifman OE, Ilan O, Tovi H, Tal Y. Cogan's syndrome-clinical guidelines and novel therapeutic approaches. *Clin Rev Allergy Immunol* **47**: 65-72, 2014.
- Arend WP, Michel BA, Bloch DA, et al. The American College of Rheumatology 1990 criteria for the classification of takayasu arteritis. *Arthritis Rheum* **33**: 1129-1134, 2010.
- Bonaguri C, Orsoni J, Russo A, et al. Cogan's syndrome: anti-Hsp 70 antibodies are a serological marker in the typical form. *Isr Med Assoc J* **16**: 285-288, 2014.
- Lunardi C, Bason C, Leandri M, et al. Autoantibodies to inner ear and endothelial antigens in Cogan's syndrome. *The Lancet* **360**: 915-921, 2002.
- Belhoucha B, Belghmidi S, Benbaddan I, et al. Atypical Cogan's syndrome: case report of an oculoaudi vestibular disease. *Am J Med Case Rep* **2**: 139-142, 2014.
- Terao C, Yoshifuji H, Matsumura T, et al. Genetic determinants and an epistasis of *LILRA3* and HLA-B*52 in Takayasu arteritis. *Proc Natl Acad Sci* **115**: 13045-13050, 2018.
- Gauthier A-S, Noureddine S, Delbosc B. Interstitial keratitis diagnosis and treatment. *J Fr Ophtalmol* **42**: e229-e237, 2019.

18. Kanzaki J, Kanzaki S, Ogawa K. Long-term prognosis of steroid-dependent sensorineural hearing loss. *Audiol Neurotol* **14**: 26-34, 2009.
19. Sano K. Takayasu disease - pulseless disease. *Brain and Nerve* **60**: 31-35, 2008.

The Internal Medicine is an Open Access journal distributed under the Creative Commons Attribution-NonCommercial-NoDerivatives 4.0 International License. To view the details of this license, please visit (<https://creativecommons.org/licenses/by-nc-nd/4.0/>).

© 2020 The Japanese Society of Internal Medicine
Intern Med 59: 1899-1904, 2020