



Research Paper

Usefulness of supraclavicular flap in reconstruction following resection of oral cancer



B. Vageesh Padiyar*, S.M. Azeem Mohiyuddin, A. Sagayaraj, Shuaib Merchant

Department of Otorhinolaryngology Head and Neck Surgery, Sri Devaraj Urs Medical College and Research Centre, Tamaka, Kolar, Karnataka, 563101, India

Received 7 August 2016; received in revised form 29 December 2016; accepted 3 January 2017
Available online 4 August 2017

KEYWORDS

Squamous cell carcinoma;
Buccal mucosa cancer;
External jugular vein;
Supraclavicular artery flap

Abstract Objective: To evaluate the usefulness of supraclavicular artery flap in reconstruction of defects following resection of buccal mucosa cancer.

Methods: Twenty-five patients who presented to R.L Jalappa Hospital and Research centre and diagnosed as squamous cell carcinoma of buccal mucosa staged T₂ and above were included in our study. All patients underwent wide excision of tumour and neck dissection. Six patients underwent hemi-mandibulectomy while 4 patients underwent marginal mandibulectomy depending on extent of the tumour along with neck dissection. The defect following surgery was reconstructed using the supraclavicular artery flap and were followed up for minimum 6 months during which they were assessed for the functional and aesthetic outcome using a scoring system. The details of the scoring system comprised of 7 attributes. Each attribute was given a score of 10 if the patients experienced that attribute, while a score of 0 was given if the patient did not experience that particular attribute.

Results: Seven (28%) patients had complete necrosis of the flap. One patient had a local recurrence 2 months following surgery and was lost to follow up. The remaining 17 patients were followed up for a minimum of 6 months and a scoring system was adopted to evaluate the functional and aesthetic outcome of the supraclavicular flap. We observed that 14 patients had an excellent outcome score (58%), 3 patients had a good outcome score (13%), while 7 patients (28%) had flap necrosis.

* Corresponding author.

E-mail address: gpadiyar@hotmail.com (B.V. Padiyar).

Peer review under responsibility of Chinese Medical Association.



Production and Hosting by Elsevier on behalf of KeAi

Conclusions: We find the supraclavicular flap to be safe, technically simple, sensate, thin, pliable and reliable regional fasciocutaneous flap in reconstructing intra oral defects. Preserving the external jugular vein and sacrificing supraclavicular nerves give good outcome.

Copyright © 2017 Chinese Medical Association. Production and hosting by Elsevier B.V. on behalf of KeAi Communications Co., Ltd. This is an open access article under the CC BY-NC-ND license (<http://creativecommons.org/licenses/by-nc-nd/4.0/>).

Introduction

There is a high prevalence of squamous cell carcinoma of buccal mucosa in Kolar district, India.¹ Patients present with locally advanced disease requiring composite resection of disease and adjuvant treatment.

For many years, reconstructive surgeons have used myocutaneous and fasciocutaneous flaps for closure of defects following resection of oral cancers. Pectoralis major myocutaneous flap is the workhorse for reconstruction of these defects in developing countries. The pedicled flaps are easy to harvest and are very reliable. However, these flaps can be too bulky and can also lead to donor site morbidity.

Microvascular free tissue transfer has expanded the options available for reconstruction. However it requires longer operative time, extensive postoperative monitoring and specialized expertise that may not be available in peripheral centres. Patients with peripheral vascular disease are not suitable for these flaps.

The goal of reconstructive surgery is to provide anatomical functional units with skin colour and texture matching at the recipient site.

With advancements in knowledge of vascular anatomy and physiology of skin, several forgotten flaps like supraclavicular flap were rediscovered.^{2,3} Few studies in literature have described the usefulness of this flap in oral reconstructions. It is a reliable fasciocutaneous pedicled flap in suitable patients which can reduce surgical time and morbidity.

Materials and methods

Following approval from the central ethics committee, this prospective interventional study was conducted in the Department of Otorhinolaryngology, R.L. Jalappa Hospital

and Research centre, a tertiary rural centre, attached to Sri Devaraj Urs Medical College, Kolar, India. This study was conducted from January 2014 to June 2015. The patients were followed up for at least 6 months and were assessed for functional outcome like closure of the defect, mouth opening, mastication and aesthetic appearance.

Our study included 25 patients with biopsy confirmed squamous cell carcinoma of buccal mucosa. Among these, 15 patients (60%) were at stage T₂, 4 patients (16%) were at stage T₃ and 6 patients (24%) were at stage T₄ (due to mandibular erosion). Patients who required full thickness resection of cheek or had previous neck dissections or radiotherapy to neck or large scars were excluded from the study.

All patients included in this study underwent composite resection (6 patients underwent hemi-mandibulectomy and 4 patients underwent marginal hemi-mandibulectomy) along with neck dissection and reconstruction using supraclavicular artery flap. The flap was raised in the supraclavicular area extending into the deltopectoral groove in all patients (Fig. 1). During initial part of the study, 8 patients (32%) underwent external jugular vein ligation to provide length. In later part of the study the external jugular vein was preserved in 17 patients (68%) and the supraclavicular nerves were sacrificed among 17 patients (68%). Arc of rotation was maximized by transecting the sternal and clavicular heads of the sternocleidomastoid muscle elevating it as a fascio-auricular pedicle flap leaving the base undisturbed to protect the vessels from tension/torsion (Fig. 1). Intraoperative details regarding flap dimensions, skin-paddle dimensions, pattern of flap, time taken to raise the flap and intraoperative complications were documented. Postoperative outcome and complications were documented. Three patients received postoperative radiotherapy.

The patients were followed up for a minimum period of 6 months after completion of treatment (mean follow up of 11 months, Fig. 2). Patients were assessed on a total of

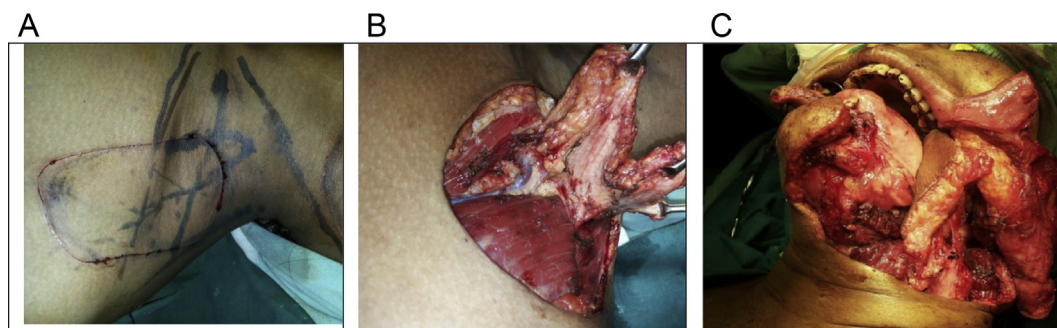


Fig. 1 Pictures during the surgery. A. Marking for harvesting the flap. B. Flap being raised preserving the external jugular vein. C. Insetting the flap in oral cavity.

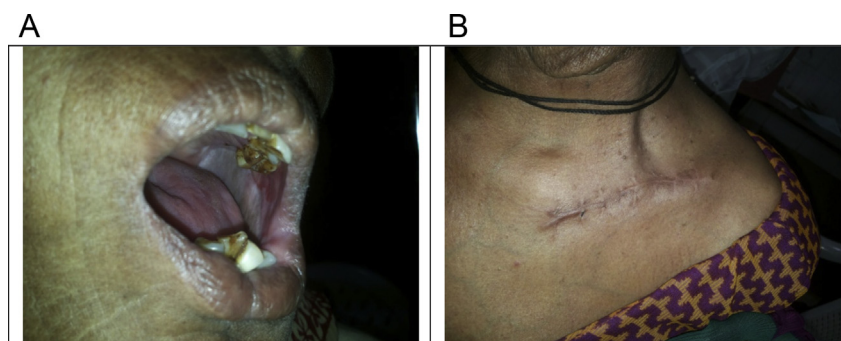


Fig. 2 Operative site – 6 weeks after surgery. A. Flap site. B. Donor site.

seven parameters. Each parameter was given a score of 0 or 10 as shown in Table 1 (0 – no improvement, 10 – perfectly functional). The parameters were assessed by a single para-medical observer, the details of which have been illustrated in Table 1. A total score between 0 and 20 means poor functional and aesthetic outcome. A total score between 20 and 40 means good outcome. A total score between 40 and 70 means excellent functional and aesthetic outcome in relation to the flap.

Results

Twenty-five patients ($n = 25$) underwent composite resection of the lesion with the defect reconstructed using the supraclavicular flap. Among 25 patients, 4 patients were male (16%) and 21 patients were female (84%).

The mean age of the patients was 54 years (range, 28–70). All patients had the lesion confined to the oral cavity. In this study, majority had the epicenter of the lesion situated in buccal mucosa (60%). Twenty percent of our patients had the epicenter of the lesion in the lower alveolus and 20% in retromolar trigone.

Table 1 Functional and aesthetic outcome score.

Particulars	Yes (Score = 10)	No (Score = 0)
Ability to swallow without difficulty		
Ability to chew in cases where mandible has been resected		
Adequate mouth opening		
Free movements of the tongue		
Obvious deformity/poor aesthetic appearance		
Unwillingness/apprehension of patient to keep the operated site exposed/hidden/reconstructed area		
Social behaviour of patient/attends community meetings		

Fifteen patients were at stage T₂ (60%), 4 patients were at stage T₃ (16%) while 6 patients were at staged T₄ (24%) as they had mandibular involvement (skin was not involved). Eighteen patients underwent supra-omohyoid neck dissection, while 7 patients underwent modified radical neck dissection.

All the 6 patients staged T_{4a} underwent hemi-mandibulectomy, 4 patients underwent marginal mandibulectomy for clearance of the disease and 9 patients underwent mandibular periosteal stripping due to close proximity of the lesion to the mandible. Six patients did not undergo mandibulectomy or periosteal stripping since an adequate margin was present all around the malignant lesion. Mean dimension of the defect was 4 cm × 3.7 cm.

Mean flap length was 5.6 cm and mean flap width was 5.6 cm. The mean length of the pedicle measured 5.3 cm and skin paddle width measured 5 cm. Average time taken to raise the flap was 50 min. Donor site was closed primarily in all cases. We raised a vertically designed flap in 76% of the patients and horizontally designed flap in 24%.

Eight patients had flap discoloration on 2nd postoperative day. Three of these patients recovered flap vascularity after administration of low molecular weight heparin for 3 days and release of few stitches. Five patients had complete flap necrosis by the 4th postoperative day. Two patients developed infection at the site of the flap leading to subsequent wound dehiscence and complete flap necrosis within 8th postoperative day of the surgery. Totally seven patients (28%) had complete flap necrosis by 8th postoperative day requiring debridement and pectoralis major myocutaneous flap reconstruction.

The rest of the 18 patients (72%) had good flap uptake. Among the seven patients who had complete flap necrosis, the external jugular vein had been ligated in five while raising the flap either as a part of modified radical neck dissection or due to the vein obscuring the arc of rotation, thereby causing inadequate length of the flap reaching the defect. This set of patients belonged to the initial part of the study.

During initial part of the study the supraclavicular sensory nerves were saved in 8 patients. All these patients had pain at the donor site (5 patients had pain while chewing food while 3 patients had dull aching pain throughout the day). Five patients who had close margin of resection (<5 mm) received adjuvant chemo radiotherapy. Three patients underwent adjuvant radiotherapy. Two patients refused postoperative radiotherapy. Flap was healthy in all patients who received radiation to the tumour bed.

Patients were evaluated based on the function and outcome with respect to the supraclavicular flap. Fourteen patients (56%) had an excellent outcome score, 3 patients (12%) had a good outcome score, while 7 patients (28%) had a poor outcome score. One patient, who had defaulted postoperative radiotherapy, presented with a local recurrence 2 months later and could not be evaluated for aesthetic and functional outcome, even though the flap was healthy in spite of the local recurrence. This patient was eventually lost during follow-up period.

Discussion

Majority of the patients in this study were females. There is high prevalence of oral cancer in Kolar district particularly involving the lower buccal mucosa and lower alveolus complex. This could be due to the practice of chewing tobacco and keeping tobacco and betel nut quid overnight in the cheek among the ladies. Most of the patients present with locally advanced disease in this region.

This study included a majority of patients at T₂ stage (60%) as patients with full thickness cheek involvement were excluded from this study. All 6 patients who staged T_{4a} underwent hemi-mandibulectomy. Four patients staged T₃ underwent marginal hemi-mandibulectomy. Nine patients underwent mandibular periosteal stripping due to close proximity of the lesion to the mandible. All patients underwent reconstruction with supraclavicular flap.

Reconstruction of oral defects following cancer surgery is a challenge to the head and neck surgeon as the function has to be restored as far as possible and the outcome of reconstruction should be of good aesthetic appearance. Though the workhorse for such reconstruction in developing countries is pectoralis major myocutaneous flap (PMMC), it is too bulky and can lead to donor site morbidity. Microvascular free tissue transfer is an ideal option but requires two team approach, expertise, longer operating time and may not be feasible in patients with peripheral vascular diseases. Therefore many fasciocutaneous flaps which were described earlier like supraclavicular flap have been rediscovered with better knowledge of anatomy.

The flap based on the supraclavicular branch of the transverse cervical artery was first described by Kazanijian and Converse² as "in charretera" or acromial flap. The supraclavicular fasciocutaneous flap was initially introduced by Lamberty and Cormack³ in 1979 and described the artery as a perforator that arises from the transverse cervical artery in 93% of cases or from the suprascapular artery in 7% of cases. In 1997, Pallua described the supraclavicular island flap for releasing post burn mentosternal contractures as a reliable and useful flap. Later in 2000, Pallua and Noah⁴ further defined anatomical features of the supraclavicular artery by their study on cadavers.

In the initial part of the study we used the horizontal axial pattern of the flap (28%) but in subsequent cases with posterior defects the required length of the flap was more. In such cases we used vertical patterned flap (72%) and found it more useful and safe in reaching the defect. This pattern not only gave adequate length, but also gave a good arc of rotation up to 270° without exerting any tension/torsion on the pedicle. These observations were similar to

cadaveric micro angiographic studies describing a cervico-pectoral flap pattern with the main blood supply coming from the perforator of transverse cervical artery.⁵ In literature the vascularity of the flap comes from the transverse cervical artery in 93% of cases while in 3% it comes from branches of suprascapular artery.⁴

In our study we found the supraclavicular artery to arise from the transverse cervical artery in all cases. This was similar to the study performed by Vinh et al.⁶ However in contrast to this observation, other studies in literature have shown the supraclavicular artery to raise from transverse cervical in 62.9% and from the suprascapular artery in 37.1% of 28 dissections from 14 cadavers.⁷

In the initial part of the study, the external jugular vein was ligated in 8 patients to achieve adequate arc of rotation. Five patients among them had complete flap necrosis on the 2nd day due to venous congestion. There was no flap necrosis within the first three days in 17 patients where the external jugular vein was saved. Similar to our observation, most authors suggest preservation of the venous drainage within the fascial pedicle itself to maintain the vascular integrity of the flap.^{6,8-10} To our knowledge only one author has mentioned that in order to get a better arc of rotation, the external jugular vein can be divided, since it contributes for a secondary drainage of the flap.¹¹ However in such circumstances, at least one draining vessel should be constantly present.

In the initial part of the study, 8 patients complained of dull aching pain at the donor site. In all these 8 patients supraclavicular nerves were preserved in an attempt to have a sensate flap. Similar observations have been reported in few other studies and authors recommend to cut the supraclavicular nerves from the plexus in order to prevent dysaesthesia. However, in view of free flaps, the supraclavicular nerves might be preserved for anastomosis to a sensory nerve at the recipient site. This might be important in the maintenance of adequate cutaneous sensation, as well as its restitution of function.^{12,13}

In our study, the 17 patients in whom supraclavicular nerves were sacrificed did not experience any pain at the donor site. Two patients in our study had infection which resulted in flap necrosis on 5th postoperative day. Five patients had close margins of resection and were advised postoperative chemotherapy with radiotherapy. Five patients were advised postoperative radiotherapy as they at stage of T₃ or T_{4a}. Three of these patients completed adjuvant radiotherapy and 2 defaulted. One patient who defaulted postoperative radiotherapy developed local recurrence 8 months following surgery and was later lost to follow up. One patient who was advised postoperative chemotherapy with radiotherapy (close margins) defaulted adjuvant treatment and had local recurrence 11 months following surgery. However, the flap was healthy in him. In our study, post-operation radiotherapy or chemotherapy did not affect the survival of the flap. These observations were similar to studies performed by Razdan, who concluded that neck dissection or radiation do not compromise the viability of this flap. One study suggested that the vascularity might be compromised in patients who have received radiation to the neck and alternative reconstructive techniques should be considered.¹⁴ Seventeen patients who had good flap uptake and no recurrence

were provided with a scale for assessment of function and aesthetics. Fourteen patients (56%) had an excellent outcome score while 3 patients (12%) had a good outcome score. Our flap harvest time was 50 min which was similar to other studies where less than 1 h was required to harvest the flap.^{9,15–17} In our study the advantages of the flap were ease of flap elevation, pliability and thin texture, minimal donor site morbidity and short operating time.⁸ The disadvantages include the relatively smaller size of flap, small caliber of the pedicle and difficulty encountered if a large external jugular vein crosses the arc of rotation.

Conclusion

Reconstruction following oral cancer surgery is challenging. Microvascular free tissue transfer and pedicled myocutaneous flaps may not always be a suitable option especially in peripheral hospitals. Supraclavicular flap is a good option in reconstruction of oral defects which do not involve full thickness of cheek. It is easy to raise, reliable, less bulky and has minimal donor site morbidity and short operating time. Preservation of external jugular vein is very important for survival of the flap. Preservation of supraclavicular nerves can lead to donor site morbidity like dysaesthesia. This flap is best suited in patients with T₂ or T₃ oral cancers particularly when they have co-morbidities which may not allow long operating time.

Conflict of interest

The authors declare that they have no conflict of interest.

Acknowledgements

None.

References

1. Kalyani R, Das S, Bindra SMS, Kumar H. Cancer profile in the Department of Pathology of Sri Devaraj Urs Medical College, Kolar: a ten years study. *Indian J Cancer*. 2010;47:160–165.
2. Kazanjian VH, Converse J. *The Surgical Treatment of Facial Injuries*. Baltimore, MD, USA: Williams & Wilkins; 1949.
3. Lamberty BG, Cormack GC. Misconceptions regarding the cervico-humeral flap. *Br J Plast Surg*. 1983;36:60–63.
4. Pallua N, Magnus NE. The tunneled supraclavicular island flap: an optimized technique for head and neck reconstruction. *Plast Reconstr Surg*. 2000;105:842–851. discussion 852–854.
5. Chin T, Ogawa R, Murakami M, Hyakusoku H. An anatomical study and clinical cases of 'super-thin flaps' with transverse cervical perforator. *Br J Plast Surg*. 2005;58:550–555.
6. Vinh VQ, Van Anh T, Ogawa R, Hyakusoku H. Anatomical and clinical studies of the supraclavicular flap: analysis of 103 flaps used to reconstruct neck scar contractures. *Plast Reconstr Surg*. 2009;123:1471–1480.
7. Levy JM, Eko FN, Hilaire HS, Friedlander PL, Melgar MA, Chiu ES. Posterolateral skull base reconstruction using the supraclavicular artery island flap. *J Craniofac Surg*. 2011;22:1751–1754.
8. Shah JP, Haribhakti V, Loree TR, Sutaria P. Complications of the pectoralis major myocutaneous flap in head and neck reconstruction. *Am J Surg*. 1990;160:352–355.
9. Chiu ES, Liu PH, Friedlander PL. Supraclavicular artery island flap for head and neck oncologic reconstruction: indications, complications, and outcomes. *Plast Reconstr Surg*. 2009;124:115–123.
10. Di BG, Aquinati A, Pierangeli M, Scalise A, Bertani A. From the "charretera" to the supraclavicular fascial island flap: revisitation and further evolution of a controversial flap. *Plast Reconstr Surg*. 2005;115:70–76.
11. Cordova A, Pirrello R, D'Arpa S, Jeschke J, Brenner E, Moschella F. Vascular anatomy of the supraclavicular area revisited: feasibility of the free supraclavicular perforator flap. *Plast Reconstr Surg*. 2008;122:1399–1409.
12. Sands TT, Martin JB, Simms E, Henderson MM, Friedlander PL, Chiu ES. Supraclavicular artery island flap innervation: anatomical studies and clinical implications. *J Plast Reconstr Aesthet Surg*. 2012;65:68–71.
13. Hunt JP, Buchmann LO. The supraclavicular artery flap for lateral skull and scalp defects: effective and efficient alternative to free tissue transfer. *J Neurol Surg Rep*. 2014;75:e5–e10.
14. Razdan SN, Albornoz CR, Ro T, et al. Safety of the supraclavicular artery island flap in the setting of neck dissection and radiation therapy. *J Reconstr Microsurg*. 2015;31:378–383.
15. Chen WL, Zhang DM, Yang ZH, et al. Extended supraclavicular fasciocutaneous island flap based on the transverse cervical artery for head and neck reconstruction after cancer ablation. *J Oral Maxillofac Surg*. 2010;68:2422–2430.
16. Sandu K, Monnier P, Pasche P. Supraclavicular flap in head and neck reconstruction: experience in 50 consecutive patients. *Eur Arch Otorhinolaryngol*. 2012;269:1261–1267.
17. Alves HR, Ishida LC, Ishida LH, et al. A clinical experience of the supraclavicular flap used to reconstruct head and neck defects in late-stage cancer patients. *J Plast Reconstr Aesthet Surg*. 2012;65:1350–1356.

Edited by Yi Fang