


# Myocarditis in SARS-CoV-2 negative patients with suspected preceding infection

Matthew Henwood,<sup>1</sup> Daniel Lake,<sup>2</sup> Felix Allen,<sup>3</sup> Mansoor Sange <sup>2</sup>

<sup>1</sup>Anaesthetics, Maidstone and Tunbridge Wells NHS Trust, Maidstone, UK

<sup>2</sup>Anaesthetics, Darent Valley Hospital, Dartford, UK

<sup>3</sup>Intensive Care, York Teaching Hospital NHS Foundation Trust, York, UK

## Correspondence to

Dr Matthew Henwood;  
matthew.henwood@nhs.net

Accepted 16 December 2020

## SUMMARY

SARS-CoV-2 is primarily a respiratory disease; however, there have been multiple reports of associated myocarditis. In our 463 bedded, district general hospital, we noted an influx of young patients with myocarditis shortly after the peak of the outbreak. We report two cases presenting with myocarditis, both of whom tested negative for the virus despite clinical and biochemical evidence of recent infection. Diagnosis was made based on positive transthoracic echocardiogram (TTE) findings and a raised troponin, not in the context of suspected acute coronary syndrome. We recommend that patients with negative coronavirus tests should still be considered at risk of potential sequelae from the disease. There should be a low threshold for performing basic cardiac investigations: ECG, troponin and TTE as well as seeking a cardiology opinion. Colchicine is a recognised treatment for viral pericarditis and should be considered as adjunctive treatment; however, further research is required specific to SARS-CoV-2.

## BACKGROUND

At the time of writing, SARS-CoV-2 had been confirmed in 6 799 713 cases and caused 397 388 deaths across the globe.<sup>1</sup> The primary pathology is respiratory in nature, with common features including cough, dyspnoea and fever. Unfortunately, the virus may present in many more varied ways, including diarrhoea, headache, myalgia or even incidentally in asymptomatic patients.<sup>2 3</sup> In addition, there have been multiple reports of fulminant myocarditis as the cause of presentation in those infected with the virus.<sup>4-8</sup> These case reports describe myocarditis concurrent with SARS-CoV-2. We present a case series of two patients, both requiring intensive care involvement due to severe cardiac manifestation of COVID-19. Both of these patients were clinically suspected of having contracted COVID-19 prior to attendance to the hospital, but by the time of presentation tested negative. Both patients were found to have raised troponin and reduced contractility on echocardiogram (ECHO), in keeping with myocarditis. Management was largely supportive with the addition of colchicine and both survived to discharge home. At this time of high prevalence of SARS-CoV-2, we recommend low thresholds for early cardiac investigations in those presenting to hospital with any unexplained cardio-respiratory symptoms, especially in those with a history of prior symptoms in keeping with the virus or exposure to it.

## CASE PRESENTATION 1

A 30-year-old man of Indian origin who was a fit and well mechanic, with no medical history,

presented to the emergency department (ED) with a 7-day history of feeling generally unwell, associated with bilateral flank pain. He had initially seen his general practitioner 4 days prior, with the same symptoms, and was started on co-amoxiclav. On examination, he was feverish at 38.1°C, tachycardiac at 132 beats per minute (BPM), normotensive (119/86) and saturating 92% on room air. His chest was clear; however, he had a soft but tender abdomen, localised over the right lower quadrant.

## INVESTIGATIONS

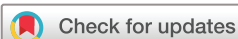His initial bloods revealed a raised C reactive protein CRP (168 mg/L), lymphopenia ( $0.4 \times 10^9/L$ ), but a total white cell count (WCC) within normal range and thrombocytopenia ( $73 \times 10^9/L$ ). A non-contrast, CT urogram was performed, and while it did not identify any renal pathology, lymphadenopathy in the right iliac fossa was noted.

## DIFFERENTIAL DIAGNOSIS

He was admitted under the surgical team for a suspected appendicitis. A repeat CT abdomen was performed with contrast and demonstrated persisting enlarged lymph nodes measuring up to 18 mm in the right iliac fossa and mildly enlarged para-aortal retroperitoneal lymph nodes. In addition, there was a widened and fluid-filled caecum with slightly thickened ascending colon bowel wall and unclear inflammatory changes in the right iliac fossa.

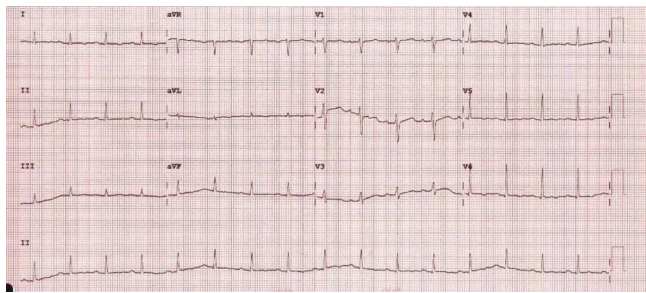
## TREATMENT

While awaiting surgery, he developed respiratory symptoms, initially becoming tachypnoeic and requiring nasal cannula oxygen before rapidly deteriorating until he required continuous positive airway pressure (CPAP) of 8 cm H<sub>2</sub>O and a fractional inspired oxygen (FiO<sub>2</sub>) of 40%. On examination, he was mildly drowsy, but rousable, and had developed bilateral basal crackles, a raised jugular venous pulse, peripheral oedema and was profoundly hypotensive (78/45). He was screened for SARS-CoV-2, as well as having a CT pulmonary angiogram (CTPA) to exclude a pulmonary embolism (PE). The CTPA was reported negative for a PE and showed no signs of interstitial lung disease. A COVID-19 blood panel returned the following results: troponin 1002.5 ng/L, ferritin >1500 µg/L, procalcitonin (PCT) 76.65 ng/mL, CRP 258 mg/L, D-dimer 417 ng/mL, WCC  $16 \times 10^9/L$ , lymphocyte count  $0.7 \times 10^9/L$ . He was therefore treated as a suspected SARS-CoV-2 infection. A viral swab was sent to confirm the diagnosis; however, it returned



© BMJ Publishing Group Limited 2021. No commercial re-use. See rights and permissions. Published by BMJ.

**To cite:** Henwood M, Lake D, Allen F, et al. *BMJ Case Rep* 2021;**14**:e239513. doi:10.1136/bcr-2020-239513



**Figure 1** ECG from case 1 at the time of developing symptoms of heart failure. Demonstrates sinus tachycardia with T-wave inversion in leads I, V5 and V6.

negative. His ECGs showed sinus tachycardia with T-wave inversion in the lateral leads (figure 1). Due to increasing respiratory support and signs of acute heart failure, he was transferred to intensive care.

A bedside ECHO identified a non-dilated LV with septal dyskinesia and hypokinesia of the remaining walls. The right ventricle was also reported as dilated with impaired function, while the valves were structurally normal. A review by the cardiology team concluded that the troponin rise was likely secondary to a COVID-19 myocarditis rather than a thrombotic event. He was therefore started on colchicine 500 µg twice daily (BD).

#### OUTCOME AND FOLLOW-UP

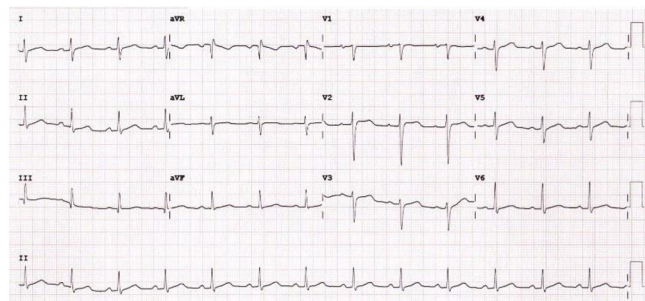
A second SARS-CoV-2 swab was sent and returned negative. All urine, sputum and blood cultures returned without any growth. Throughout his stay, the troponin levels gradually normalised, returning to 92.8 ng/L at the time of discharge. He was stepped down from intensive care after 5 days and then discharged home 7 days later. No repeat ECHO was carried out while an inpatient, however, a follow-up outpatient ECHO was reported as showing an ejection fraction (EF) of 55%, with an otherwise normal heart.

#### CASE PRESENTATION 2

A 41-year-old man of Afro-Caribbean origin, who was previously fit and well, with no medical history, presented to the ED with a 6-day history of generalised malaise. He also described a central, sharp chest pain which did not radiate and which was not brought on by exertion but was exacerbated by inspiration. Other associated symptoms included an intermittent fever as well as dizziness on exertion, although he denied any shortness of breath. On examination, he appeared most comfortable in a sitting position with a slight forward lean. He was pyrexical at 39.1°C, tachycardic at 122 BPM, hypotensive at 78/50 mm Hg but saturating 97% on room air. On auscultation, his chest was clear with normal heart sounds and no evidence of a pericardial rub.

#### INVESTIGATIONS

His initial ECG showed widespread S and T segment (ST) elevation (figure 2) associated with a significantly raised troponin I (17 161 ng/L). The remainder of his standard blood tests were unremarkable except for a raised WCC ( $18.7 \times 10^9/L$ ), CRP (380 mg/L) and creatinine (130 µmol/L). An extended panel showed that his ferritin (521 µg/L), lactate dehydrogenase (866 I.U/L) and D-dimer (3006 ng/mL) were all raised, while his PCT was significantly raised (24.84 ng/mL). Despite this, his swab for SARS-CoV-2 returned negative.



**Figure 2** ECG from case 2 at presentation shows ST elevation in leads V1–V4 and high take-off in the lateral leads.

A baseline chest X-ray showed minor bilateral, patchy opacifications and cardiomegaly. While a CT angiogram performed demonstrated normal coronary arteries, it confirmed the presence of a globular, enlarged heart with pericardial thickening. Furthermore, the CT reported dependent, bilateral ground glass appearances and marked peri-hilar bronchiolar soft-tissue thickening. An initial bedside ECHO performed in ED showed an ejection fraction of approximately 20%–25% with global hypokinesia. A repeat, formal transthoracic echocardiogram (TTE) was carried out the next day (while on dobutamine) and was reported as showing normal cavity size with mild hypertrophy and an EF of 40%. Otherwise there was normal valve morphology and no evidence of a pericardial effusion.

#### DIFFERENTIAL DIAGNOSIS

The first diagnosis, considered based on the clinical symptoms and associated ST changes on the ECG, was an acute ST-elevated myocardial infarction. However, the ECGs were uploaded, and the case discussed with the local percutaneous coronary intervention centre who felt that the global ECHO dysfunction and widespread ST changes were more in keeping with myocarditis.

The CT angiogram was performed to rule out aortic dissection. Acute infection with COVID-19 was also considered based on the clinical history as well as the X-ray and CT findings of the lungs; however, his respiratory requirement was minimal.

#### TREATMENT

Due to hypotension, he was transferred to the intensive care unit (ICU) for cautious fluid resuscitation as well as norepinephrine and dobutamine therapy. He was commenced on antibiotic therapy (based on the result of his PCT) as well as nasal optiflow, 40% FiO<sub>2</sub> 60L/min. While in ICU, he was reviewed by the local cardiology team who concluded that he was at low risk for acute coronary syndrome and agreed with the referral centre that a viral myocarditis secondary to a SARS-CoV-2 infection was more likely. He was prescribed colchicine 500 µg BD as treatment for the myocarditis.

#### OUTCOME AND FOLLOW-UP

During his stay in ICU, his chest pain improved and his repeat ECGs did not show further evidence of ischaemic changes. Serial troponins initially rose, up to 25 592 ng/L on day 2 but then continued to fall until, at the time of discharge, they were 80 ng/L. The three SARS-CoV-2 swabs carried out during his admission all returned negative. Sputum, blood and urine cultures failed to grow any infectious organisms, despite the significantly raised PCT, so antibiotics were stopped. Over the 5 days in intensive care, his inotropic and respiratory support were weaned off, at which point he was discharged to the cardiology

ward. From there he was subsequently discharged home, a total of 9 days after admission, to complete a total course of 4 weeks of colchicine. A follow-up ECHO showed evidence of resolving myocarditis with an ejection fraction of 65% while a cardiac MRI was reported as showing normal biventricular function with no evidence of pericardial effusions. However, it did conclude that the high pericardial signal on T2-weighted imaging was suggestive of recent or resolving pericarditis.

## DISCUSSION

The WHO defines myocarditis as an ‘inflammatory disease of the myocardium diagnosed by established histological, immunological and immunohistochemical criteria’. For viral-induced myocarditis, a positive PCR of a virus known to cause myocarditis is required alongside the conformation of myocardial inflammation. The disease is classically characterised by pleuritic chest pain associated with exertional dyspnoea, fatigue and, if severe, syncope from arrhythmias or cardiogenic shock. ECG changes are non-specific and include ST changes while biochemical markers, such as troponin, are normally raised and echocardiography demonstrates regional or global hypokinesia without evidence of structural abnormality. As well as occurring independently, myocarditis can also co-exist with pericarditis (known as myopericarditis) in which additional classical signs of pericarditis are evident, including pericardial rub on auscultation, widespread ST elevation or PR segment depression on the ECG and pericardial effusion.<sup>9</sup> While the gold standard for myocarditis diagnosis is with an endomyocardial biopsy (an invasive procedure which involves catheterisation of the heart via an arterial line), this technique is a specialist procedure which is not carried out in many district general hospitals and due to its invasive nature is only recommended by the European Society of Cardiology in specific circumstances.<sup>10</sup> Instead, cardiac MRI, a less invasive diagnostic technique, is often used and has been shown to have good correlation with endomyocardial biopsy in patients with an acute history, raised troponins and negative coronary artery disease.<sup>11</sup>

Earlier case studies describe similar diagnostic findings to ours, with one important exception; their cases tested positive for coronavirus.<sup>4–8</sup> This is in contrast to the two we present, both of whom tested negative and were otherwise young, fit and well. Despite having features of COVID-19, both of these

patients tested negative for SARS-CoV-2 on two-to-three separate occasions and not just from nasal swabs but also sputum samples. It is here that we must acknowledge a limitation in our case series; without positive coronavirus swabs, we cannot state for certain that these cases were secondary to coronavirus. However, based on symptoms prior to presentation and laboratory tests (summarised in table 1), which conform to patterns observed in patients with confirmed COVID-19, it was felt that, in spite of a negative swab, these patients had been infected by SARS-CoV-2, even if they were not actively infected at the time of their hospital admission.

While one possible explanation for the negative swab results is that no test is 100% accurate, and therefore, some false negatives are to be expected. The samples taken from these patients included both nasal swabs as well as sputum samples and were tested using real-time (RT) PCR. According to a systemic review, the sensitivity of RT PCR is between 71% and 98% while another study identified that tests on sputum samples resulted in a test sensitivity only inferior to that of broncho-alveolar leverage (72% compared with 92%, respectively).<sup>12 13</sup> As a result, it seems unlikely that the reason that both of these cases returned multiple negative swabs was due to the false negative rate of the test itself. An alternative explanation for the negative SARS-CoV-2 swabs seen in our reported cases could be that they presented with inflammatory sequelae of the infection, having cleared the majority of the virus during a preceding, mild form, of the respiratory illness. A study looking at the viral load in the oropharynx over time in patients with confirmed COVID-19 identified that just 33% of the patients followed had detectable viral loads 20 days after symptom onset. In fact, if patients were grouped according to the severity of the symptoms displayed, only 23% of those with mild symptoms had detectable viral loads 20 days after symptom onset.<sup>14</sup> It is therefore possible that these patients, who likely had such a mild infection as to not require hospitalisation, had already cleared the majority of the virus, resulting in very small viral loads, below the detection level of the PCR test. If these patients had been swabbed during their prior symptoms, then it is possible that the virus may have been detected. Alternatively, as the use of antibody testing becomes more widely available, it could have a role to play in the diagnosis of cases, such as these, where throat swabs are negative but there is a high index of suspicion of prior SARS-CoV-2 infection. A positive antibody

**Table 1** Summary of the results of investigations carried out in case 1 and case 2 at time of presentation and on discharge

Investigations	Patient 1		Patient 2	
	On admission	On discharge	On admission	On discharge
SARS-CoV-2 oropharynx swab	Negative	Negative	Negative	Negative
Troponin I (ng/L)	1002.5	92.8	17 161	80
PCT (ng/mL)	76.65	0.52	24.8	5.53
CRP (mg/L)	168	<5	380	64
Ferritin (µg/L)	>15 000	Not repeated	521	928
LDH (IU/L)	713	464	866	Not repeated
D-dimer (ng/mL)	417	380	3006	1871
Chest X-ray	Perihilar congestion, globular heart	Not done	Globular heart, effusion on left base	Not done
ECG findings	T-wave inversion leads I, V5 and V6.	Normal sinus rhythm	Widespread ST changes	Normal sinus rhythm
TTE findings	Septal dyskinesia. Hypokinesia of remaining walls	EF 55% nil acute	EF 20%–25% Global dyskinesia	EF 65%, findings in keeping with resolving myocarditis
Other	Not done	Not done	CT—bilateral ground glass	MRI—normal biventricular function. Increased pericardial T2-weighted signalling

CRP, C reactive protein; CT, computerised tomography; ECG, electroencephalogram; EF, ejection fraction; LDH, lactate dehydrogenase; MRI, magnetic resonance imaging; PCT, procalcitonin; TTE, transthoracic echocardiogram.



test in these situations could provide additional support for the diagnosis. However, a clinical review into the use of antibody testing in the diagnosis of COVID-19 highlights that while it may have a role to play, there are some questions which must be answered before its role can be validated.<sup>15</sup> Of relevance to our cases include; that the majority of testing carried out so far has been on inpatients who are nasal swab positive, therefore, its function in community COVID-19, where titres may be lower, still remains to be seen. Also, an understanding of the time taken for a rise in antibody levels, above that required to result in a positive test, as well as the length of time antibodies remain in the blood will be of paramount importance in determining when the results of the test can be meaningfully interpreted.<sup>15</sup> As such, the role of antibody testing in the diagnosis of COVID-19-induced sequelae is promising, but further research is still required.

In both of the cases presented, an adjuvant dose of 500 µg of colchicine BD was used for symptomatic control. The decision to begin this treatment came following advice from the local cardiology team who highlighted that while there is no evidence of the benefit of colchicine in myocarditis, it is a recommended adjunct in the treatment of pericarditis.<sup>10</sup> As a result, the treatment was empirical during a time that the patients were too unstable to have more definitive imaging carried out. While both of the patients that received this regime survived to discharge, it must be understood that owing to COVID-19 being such a novel disease, the most effective treatment for both the infection and its sequelae is still a matter for ongoing research. As such, treatment of myocarditis secondary to COVID-19 from other case studies has been varied and additional therapies including: immunoglobulin, lopinavir/ritonavir, intravenous aspirin and methylprednisolone, in addition to supportive therapies<sup>4 6 7</sup> have all been reported. The use of corticosteroids is of particular interest because, while the European Society of Guidelines do not recommend their use for viral-induced pericarditis (due to the risk of reactivation of viral infections associated with ongoing inflammation), they have become the cornerstone of management of respiratory COVID-19 since the publication of the preliminary results of the RECOVERY trial were published.<sup>16</sup> As such, corticosteroids could play an important role in the treatment of myopericarditis in patients presenting with a combined COVID-19 respiratory illness.

A raised procalcitonin was noted in both cases, despite all cultures returning negative for any bacterial growth. Procalcitonin is a haematological test hailed as a specific marker of bacterial infection, so much so that protocols for stopping and starting antibiotics have been derived based on its concentration in a patient's serum. Like all other tests, the positive predictive value of PCT is not 100%. There are a number of other reported causes of hyperprocalcitoninaemia, including fungal infections, major trauma or burns, recent major surgery and medullary thyroid carcinoma.<sup>17 18</sup> While neither of the patients we presented were ever found to have had any of these other causes of a raised PCT, they did share varying degrees of cardiogenic shock—which itself has been identified as a cause of a raised PCT.<sup>19 20</sup> Both cases required inotropic support and both had TTEs showing global hypokinesia and had PCTs of 73 ng/mL (case 1) and 24 ng/mL (case 2). While no compelling correlations can be drawn from two cases, these findings warrant further investigation as to whether a raised PCT in the absence of demonstratable bacterial infection could be an indicator of current or impending cardiogenic shock.

Due to the high prevalence of this condition, it must be assumed that any patient presenting to hospital may have been exposed to SARS-CoV-2. Furthermore, due to the unknown rate

of asymptomatic cases, we cannot rely on the absence of symptoms of COVID-19 to clinically rule out infection. Baring these two points in mind diagnosis can be difficult, owing to the overlap between the presenting symptoms of both COVID-19 infection, the sequelae of myocarditis and other respiratory and non-respiratory conditions. Initial description of the clinical features of the virus found that 12% of cases admitted to hospital had some form of acute cardiac injury, with this proportion rising to 31% if admitted to intensive care.<sup>2</sup> In addition, postmortem biopsies of patients, whose primary cause of death was respiratory manifestation of the disease, demonstrated myocardial oedema, fibrosis and hypertrophy.<sup>21</sup> As such, we recommend having a low threshold for performing serial ECGs, troponins and ECHOs on those presenting to hospital with unexplained cardiorespiratory symptoms, especially in those with normal lung imaging. If these demonstrate significant abnormalities, then early cardiology opinion should be sought. While we used colchicine in this cohort of patients, further research is required prior to it being recommended.

### Learning points

- ▶ SARS-CoV-2-related myocarditis should be considered as a cause of cardiorespiratory distress in patients exposed to the condition or known to have had it.
- ▶ Even in those not known to have been exposed to the virus, given its prevalence and propensity to be asymptomatic, early cardiac investigations should be performed in those with unexplained cardiorespiratory symptoms.
- ▶ A negative SARS-CoV-2 PCR may not rule out the virus as the cause of myocarditis.
- ▶ Treatment is largely supportive, early intensive care unit involvement is recommended with cardiology follow-up.
- ▶ PCT may have a role in prognostication of viral-induced myocarditis.

**Contributors** MH, DL, FA, MS: project lead.

**Funding** The authors have not declared a specific grant for this research from any funding agency in the public, commercial or not-for-profit sectors.

**Competing interests** None declared.

**Patient consent for publication** Obtained.

**Provenance and peer review** Not commissioned; externally peer reviewed.

This article is made freely available for use in accordance with BMJ's website terms and conditions for the duration of the covid-19 pandemic or until otherwise determined by BMJ. You may use, download and print the article for any lawful, non-commercial purpose (including text and data mining) provided that all copyright notices and trade marks are retained.

### ORCID iD

Mansoor Sange <http://orcid.org/0000-0003-1237-2007>

### REFERENCES

- 1 World Health Organization. WHO coronavirus disease (COVID-19) dashboard. Available: <https://covid19.who.int/> [Accessed 7 Jun 2020].
- 2 Huang C, Wang Y, Li X, et al. Clinical features of patients infected with 2019 novel coronavirus in Wuhan, China. *Lancet* 2020;395:497–506.
- 3 Mizumoto K, Kagaya K, Zarebski A, et al. Estimating the asymptomatic proportion of coronavirus disease 2019 (COVID-19) cases on board the Diamond Princess cruise ship, Yokohama, Japan, 2020. *Euro Surveill* 2020;25.
- 4 Inciardi RM, Lupi L, Zaccone G, et al. Cardiac involvement in a patient with coronavirus disease 2019 (COVID-19). *JAMA Cardiol* 2020;5:819–24.
- 5 Chen C, Zhou Y, Wang DW. SARS-CoV-2: a potential novel etiology of fulminant myocarditis. *Herz* 2020;45:230–2.
- 6 Hu H, Ma F, Wei X, et al. Coronavirus fulminant myocarditis saved with glucocorticoid and human immunoglobulin. *Eur Heart J* 2020;16. doi:10.1093/eurheartj/ehaa190. [Epub ahead of print: 16 Mar 2020].

- 7 Zeng J-H, Liu Y-X, Yuan J, *et al.* First case of COVID-19 complicated with fulminant myocarditis: a case report and insights. *Infection* 2020;48:773–7.
- 8 Kim I-C, Kim JY, Kim HA, *et al.* COVID-19-related myocarditis in a 21-year-old female patient. *Eur Heart J* 2020;41:1859.
- 9 Adler Y, Charron P, Imazio M, *et al.* 2015 ESC Guidelines for the diagnosis and management of pericardial diseases: The Task Force for the Diagnosis and Management of Pericardial Diseases of the European Society of Cardiology (ESC) Endorsed by: The European Association for Cardio-Thoracic Surgery (EACTS). *Eur Heart J* 2015;36:2921–64.
- 10 Cooper LT, Baughman KL, Feldman AM, *et al.* The role of endomyocardial biopsy in the management of cardiovascular disease: a scientific statement from the American Heart Association, the American College of Cardiology, and the European Society of Cardiology. endorsed by the Heart Failure Society of America and the Heart Failure Association of the European Society of Cardiology. *J Am Coll Cardiol* 2007;50:1914–31.
- 11 Caforio ALP, Pankuweit S, Arbustini E, *et al.* Current state of knowledge on aetiology, diagnosis, management, and therapy of myocarditis: a position statement of the European Society of Cardiology working group on myocardial and pericardial diseases. *Eur Heart J* 2013;34:2636–48.
- 12 Arevalo-Rodriguez I, Buitrago-Garcia D, Simancas-Racines D, *et al.* False-negative results of initial RT-PCR assays for COVID-19: a systematic review. *PLoS One* 2020;15:e0242958.
- 13 Wang W, Xu Y, Gao R, *et al.* Detection of SARS-CoV-2 in different types of clinical specimens. *JAMA* 2020;323:1843–4.
- 14 To KK-W, Tsang OT-Y, Leung W-S, *et al.* Temporal profiles of viral load in posterior oropharyngeal saliva samples and serum antibody responses during infection by SARS-CoV-2: an observational cohort study. *Lancet Infect Dis* 2020;20:565–74.
- 15 Deeks JJ, Dinnes J, Takwoingi Y, *et al.* Antibody tests for identification of current and past infection with SARS-CoV-2. *Cochrane Database Syst Rev* 2020;6:CD013652.
- 16 RECOVERY Collaborative Group, Horby P, Lim WS, *et al.* Dexamethasone in hospitalized patients with Covid-19 - preliminary report. *N Engl J Med* 2020:NEJMoa2021436.
- 17 Samsudin I, Vasikaran SD. Clinical utility and measurement of procalcitonin. *Clin Biochem Rev* 2017;38:59–68.
- 18 Algeciras-Schimmich A, Preissner CM, Theobald JP, *et al.* Procalcitonin: a marker for the diagnosis and follow-up of patients with medullary thyroid carcinoma. *J Clin Endocrinol Metab* 2009;94:861–8.
- 19 Kafkas N, Venetsanou K, Patsilina S, *et al.* Procalcitonin in acute myocardial infarction. *Acute Card Care* 2008;10:30–6.
- 20 Hensel M, Volk T, Döcke WD, *et al.* Hyperprocalcitonemia in patients with noninfectious SIRS and pulmonary dysfunction associated with cardiopulmonary bypass. *Anesthesiology* 1998;89:93–104.
- 21 Tian S, Xiong Y, Liu H, *et al.* Pathological study of the 2019 novel coronavirus disease (COVID-19) through postmortem core biopsies. *Mod Pathol* 2020;33:1007–14.

Copyright 2021 BMJ Publishing Group. All rights reserved. For permission to reuse any of this content visit <https://www.bmj.com/company/products-services/rights-and-licensing/permissions/>  
BMJ Case Report Fellows may re-use this article for personal use and teaching without any further permission.

Become a Fellow of BMJ Case Reports today and you can:

- ▶ Submit as many cases as you like
- ▶ Enjoy fast sympathetic peer review and rapid publication of accepted articles
- ▶ Access all the published articles
- ▶ Re-use any of the published material for personal use and teaching without further permission

#### Customer Service

If you have any further queries about your subscription, please contact our customer services team on +44 (0) 207111 1105 or via email at [support@bmj.com](mailto:support@bmj.com).

Visit [casereports.bmj.com](http://casereports.bmj.com) for more articles like this and to become a Fellow