



Contents lists available at ScienceDirect

Gynecology and Minimally Invasive Therapy

journal homepage: www.e-gmit.com

Case report

Postmolar choriocarcinoma after an interval of 7 years: Case report and literature review

Min-Min Hou^a, Lian Xu^b, Ming-Rong Qie^{a,*}^a Department of Obstetrics & Gynecology, West China Second Hospital, Sichuan University, Chengdu, Sichuan, 610041, People's Republic of China^b Department of Pathology, West China Second Hospital, Sichuan University, Chengdu, Sichuan, 610041, People's Republic of China

ARTICLE INFO

Article history:

Received 2 January 2017

Received in revised form

29 May 2017

Accepted 20 July 2017

Available online 17 November 2017

Keywords:

Choriocarcinoma

Hysterectomy

Laparoscopy

ABSTRACT

Choriocarcinoma is a rare pregnancy-related malignancy. The majority is arising from non-molar pregnancy. Here we report a patient who was diagnosed with postmolar choriocarcinoma after an interval of 7 years. Before surgery, we suspected the diagnosis of the patient was intramural pregnancy or choriocarcinoma. Laparoscopy was performed and hysterectomy was carried out. Postoperative pathological evaluation of the surgical specimen confirmed the case was choriocarcinoma. Hysterectomy through laparoscopy was feasible and safe for selected patients.

Copyright © 2017, The Asia-Pacific Association for Gynecologic Endoscopy and Minimally Invasive Therapy. Published by Elsevier Taiwan LLC. This is an open access article under the CC BY-NC-ND license (<http://creativecommons.org/licenses/by-nc-nd/4.0/>).

Introduction

Gestational trophoblastic disease (GTD) encompasses a unique group of uncommon but interrelated conditions that derived from the anomalous growth of placental trophoblastic tissue, which differ in propensity for regression, invasion, metastasis, and recurrence. The World Health Organization (WHO) divides GTD into the following groups: pre-malignant disease represented by complete hydatidiform moles (CHM) and partial hydatidiform moles (PHM), and malignant forms represented by invasive moles, choriocarcinoma, placental site trophoblastic tumor (PSTT), and epithelioid trophoblastic tumor (ETT).^{1,2} This disease is very uncommon and is often highly complicated. In addition, the incidence of the disease is declining, presumably due to improved medical care and to social, economic and educational changes.³ Hydatidiform mole accounts for about 80% of all cases of GTD, and occurs in 0.6–1.1/1000 pregnancies in North America.⁴ Invasive mole develops when molar villi invade the myometrium through venous channels. The development of local invasion after CHM occurs in about 3%–5% of patients, and metastatic disease is rare.⁵ While choriocarcinoma is rarer than hydatidiform mole, occurring in

1–9.2/20,222–40,000 pregnancies.⁶ It is usually arises in the uterine cavity. And an other type of this tumor is classified in the germ cell tumors of the ovary that arises from this organ. Extra-uterine choriocarcinoma is rarely seen in clinical practice.⁷ Gestational choriocarcinoma may follow any type of pregnancy and mostly is associated with coincident or antecedent pregnancy. These pregnancy may be a miscarriage, a term pregnancy, or a molar pregnancy. The majority arise following a non molar pregnancy. Here we report a case that is diagnosed to be postmolar choriocarcinoma after a long interval of 7-year, which is difficult to distinguish it from intramural pregnancy pre-operatively.

Case report

A 47-year-old woman (Gravida 2, para 1) was admitted to our clinic with the complaint of vaginal bleeding for one month after 3-month menopausal. Before this, she had an irregular menstrual cycle with 3–5 days of menstrual period and 30–60 days of menstrual cycle. She used a condom or rhythm method for contraception. In this month, she had vaginal blotting accompanied with lower abdomen dull pain that can be endured. No frequent urination, odynuria, anus belly, fever and others discomfort was accompanied. So she did not pay attention to it and did not to see doctor. After 20 days blotting, the vaginal bleeding increased, she went to a community hospital. Ultrasonography has detected an echogenic focus about 6.4 × 4.6 × 5.1 cm in posterior myometrium of the uterus. No physical or other auxiliary examination was

Conflicts of interest: The authors have no conflicts of interest relevant to this article.

* Corresponding author.

E-mail addresses: mayvenhou@126.com (M.-M. Hou), qmrjzz@126.com (M.-R. Qie).

<http://dx.doi.org/10.1016/j.gmit.2017.07.002>

2213-3070/Copyright © 2017, The Asia-Pacific Association for Gynecologic Endoscopy and Minimally Invasive Therapy. Published by Elsevier Taiwan LLC. This is an open access article under the CC BY-NC-ND license (<http://creativecommons.org/licenses/by-nc-nd/4.0/>).

suggested. So she came to our hospital. Ultrasonography showed a strong echo mass of $6.4 \times 5.1 \times 7.1$ cm at the intramural layer in left fundus of the uterus which slightly convex to the serous layer. The serum level of β -HCG was 65,576.8 mIU/ml. There was no positive foundation of her lung CT. Intramural pregnancy was suspected and hospitalization was suggested. In the course of the disease, the patient didn't accompanied with cough, phlegm, hemoptysis and weight lose. She had a history of hydatidiform mole 7-year-ago, and had received two times of evacuation. She received follow-up till the serum β -HCG decreased to be normal. She did not have a routine physical examination.

After admission, we performed physical examination and ultrasonic acoustic imaging. Bimanual examination has demonstrated an enlarged uterus as 10-gestation-week in the lower part of abdomen without tenderness. Doppler analysis revealed an heterogenic mass measuring $7.1 \times 5.4 \times 5.6$ cm with high blood flow and low resistance vascularity, and area of $4.9 \times 4.9 \times 5.9$ cm lack of contrast agent was found in the mass (see in Fig. 1). The serum level of β -HCG was 74,145.8 mIU/ml, which was higher than that of the first result (4-say interval). Because of the nonspecific characteristics of ultrasonography, we arranged pelvic CT the next day after admission, the results showed a low density lesion on the upper posterior uterine wall that was no clear boundary with uterine myometrium. It was heterogenic after T2-weight imaging (see in Fig. 2). So uterine choriocarcinoma was suspected, and intramural pregnancy could not excluded. After a sufficient pre-operative preparation and content with patient, laparoscopy was performed under systematic anesthesia. An enlarged uterus as 10-week gestational size was found. A maroon and crispy lesion was on the left posterior myometrium converting to serous layer and was infiltrating anterior serous muscular layer of the rectum. Bilateral ovaries and tubes were normal. We removed the lesion firstly. The frozen section result showed scattered low-differentiated carcinoma cells in the extensive hemorrhage and necrosis tissue. Because the patient had no desire for fertility, we performed hysterectomy. The final pathological findings (see in Fig. 3) were uterine choriocarcinoma accompanied with extensive hemorrhage and necrosis, infiltrating the whole muscular layer. Results of IHC were P63++, CD146+++, CK-P+++, PLAP-, HCG+++, 90% positive rate of Ki 67. According to the stage and scoring system (see in Tables 1 and 2), the diagnosis was postmolar choriocarcinoma, stage 1, score 9. Treatment is based on classification into risk groups defines by stage and scoring system.⁸ For patients with the high-risk disease (FIGO stage IV and stages II–III score ≥ 7) should be treated initially with multi agent chemotherapy with or without adjuvant surgery or radiotherapy.⁹ So when we confirmed the diagnose after surgery, EMA-CO regimen was given in order to

prevent recurrence and metastasis. Now the patient was in following-up with a fine condition.

Discussion

As a kind of highly malignant disease, choriocarcinoma is characterized by hyperplastic and anaplastic syncytiotrophoblasts and cytotrophoblasts, hemorrhage, tissue necrosis, and absence of chorionic villi. It spreads by directly invading the myometrium and vascular channels, resulting in involvement at distant sites, most commonly the lungs (80%), vagina (30%), brain (10%), liver (10%).^{10,11} The clinical symptoms and signs may be nonspecific, making the diagnosis difficult. When patients present with vaginal bleeding after term pregnancies or miscarriages, abnormal serum level of β -HCG, choriocarcinoma should be considered. The Cancer Committee of the International Federation of Gynecologists and Obstetricians (FIGO) has established the guidelines for the diagnosis of postmolar GTN. The components include at least 1 of the following: ① HCG plateau for 4 consecutive values over 3 weeks; ② HCG rise of $\geq 10\%$ for 3 values over 2 weeks; ③ HCG persistence 6 months after molar evacuation; ④ histopathologic diagnosis of choriocarcinoma; or ⑤ presence of metastatic disease.¹² The following two points are important for judging invasive mole or choriocarcinoma: ① The interval of pre-molar evacuation: invasive mole is less than one year, while choriocarcinoma is more than one year; ② Histological examination: for invasive mole, villi can be found microscopically, while for choriocarcinoma, only trophoblastic cells can be found.¹³ For our patient, she had a history of complete mole 7-year-ago and had received evacuation. The level of serum β -HCG decreased to normal in the follow-up. After that, she did not conceive. The final pathological diagnose confirmed postmolar choriocarcinoma. It is a rare case for its long interval from her mole history. It is suggested that when patients were older than 40-year-old, the risk of developing postmolar GTN will increase 37%, while it will increase 56% when older than 50-year-old.¹⁴ Pathological characteristically, choriocarcinoma is associated with proliferating sertoli cells that losing the normal histological manifestation and infiltrating uterine muscular layer extensively, which causes necrosis, hemorrhage and distant metastasis.¹⁵ In gross appearance, the uterus increases irregularly in size and is soft. The surface shows blue purple nodules sometimes. When viewed sectionally, the focus is maroon, accompanied with hemorrhage, necrosis and infection. Actively growth of sertoli cells can be seen around the foci, which can infiltrate vascular.

GTN is the only malignancies that can be diagnosed basing on clinical symptoms and signs without pathological evidence, which agreed by FIGO and ISGC. Because of the particularity, GTN is

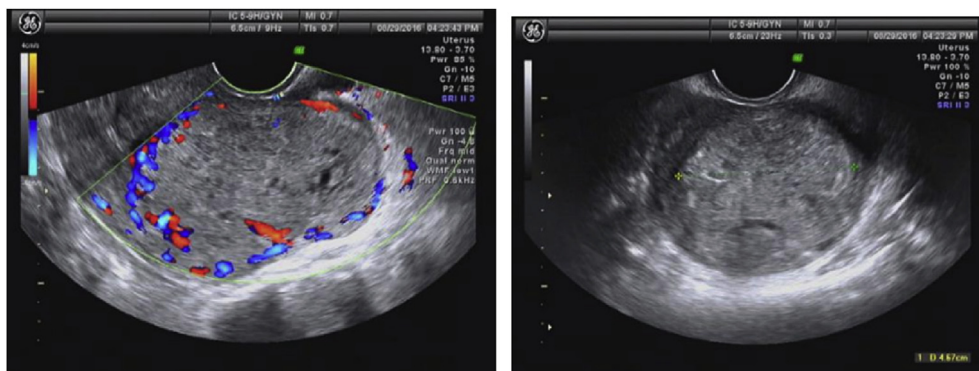


Fig. 1. The ultrasonography showed an heterogenic mass with high blood flow and low resistance vascularity.

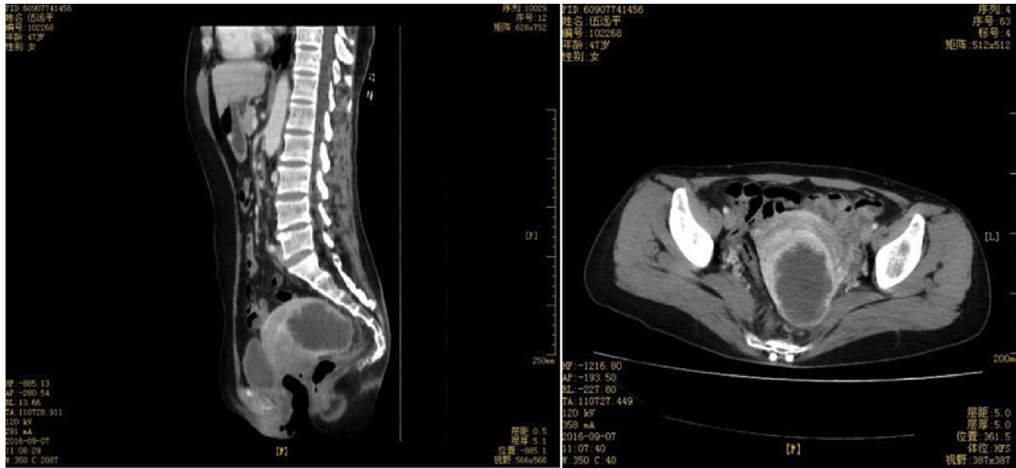

Fig. 2. The CT scan showed a low density lesion on the upper posterior uterine wall that was no clear boundary from uterine myometrium and rectum serous layer.

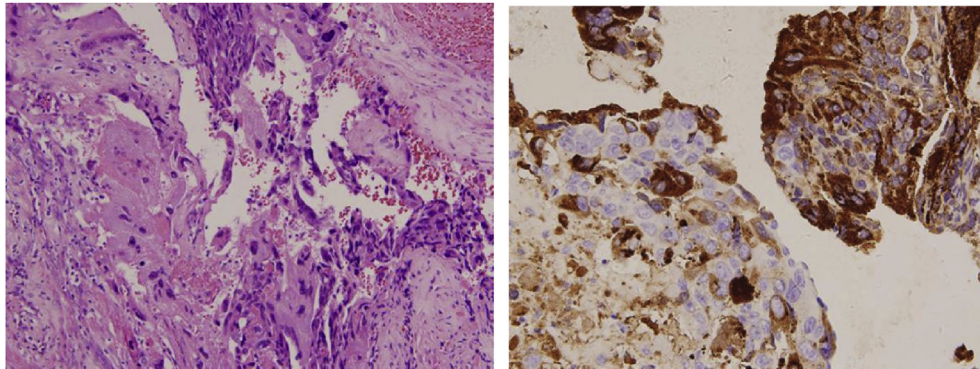


Fig. 3. The pathological findings were uterine choriocarcinoma accompanied with extensive hemorrhage and necrosis.

Table 1
Staging for gestational trophoblastic neoplasia.

Stage	Description
I	Disease confined to uterus
II	Disease extends outside uterus but is limited to genital structures (adnexa, vagina, broad ligament)
III	Disease extends to lungs with or without genital tract involvement
IV	Disease involves other metastatic sites

Lurain. Gestational trophoblastic disease II. Am J Obstet Gynecol 2011.¹

Table 2
Scoring system for gestational trophoblastic neoplasia.

FIGO/WHO risk factor scoring with stage	Score			
	0	1	2	4
Age	≤40	>40	–	–
Antecedent pregnancy	Mole	Abortion	Term	–
Interval from index pregnancy, months	<4	4–6	7–12	>12
Pretreatment hCG, mIU/ml	<10 ³	10 ³ –10 ⁴	10 ⁴ –10 ⁵	>10 ⁵
Largest tumor mass, including uterus, cm	<3	3–4	≥5	–
Site of metastases including uterus	Lung	Spleen, kidney	GI tract	Brain, liver
No. of metastases	–	1–4	5–8	>8
Previous failed chemotherapy	–	–	Single drug	≥2 drugs

GI, gastrointestinal; hCG, human chorionic gonadotropin.

Total score for patient is obtained by adding individual scores for each prognostic factor: low risk ≤ 6; high risk > 6.

Ngan H.Y., Seckl M.J., Berkowitz R.S., et al. Update on the diagnosis and treatment of gestational trophoblastic disease. Internal Journal of Gynecology and Obstetrics 131(2015):s123–s126.²⁴

clinical diagnosed without histological evidence in most conditions. While choriocarcinoma can be much more tricky to diagnose as the disease can develop months or many years after a prior pregnancy with protean presentation possible. And also because of that, misdiagnosis of GTN is not uncommon, especially for cases without extrauterine metastasis. Under this condition, differential diagnosis should be made from other pregnancy-related benign diseases, especially ectopic pregnancy in uncommon implantation sites, such as interstitium cervix, cesarean scar, rudimentary horn of the uterus, intra-myometrium. The diagnosis of our patient was not sure pre-operatively. Both Doppler ultrasonography and pelvic CT showed the foci were in the uterine myometrium, so intramural pregnancy could not be excluded. Intramural pregnancy is one of the rare types of ectopic pregnancy. It refers to a uterine conceptus within the myometrium, without the connection with the fallopian tubes or endometrial cavity. It accounts for less than 1% of all ectopic pregnancy and the incidence is increasing in recent years.¹⁶ The cause of intramural pregnancy is unclear, and the possible risk factors include a prior uterine trauma, adenomyosis, pelvic surgery, and in vitro fertilization.¹⁷ The clinical symptoms of intramural pregnancy is nonspecific. The complaints can be vaginal bleeding, mild abdominal pain. Massive hemoperitoneum will be found in patients of uterine rupture type, and this also can occur in patients with choriocarcinoma. The similar symptoms of choriocarcinoma and intramural pregnancy include: ① irregular vaginal bleeding; ② no villi structure can be found in the tissue of evacuation; ③ elevating serum β -HCG; and ④ a mass in uterine myometrium can be found in imaging examination. Diagnose will be confirmed after pathological examination.

Treatment of GTN is generally by chemotherapy. Sometimes surgery can also be regarded as an effective treatment for selected patients with drug-resistant foci. Data shows disease in the lung, brain, liver, colon may be cured by partial organ resection.^{18–20} For patients with suspected GTN foci confined to uterus, resection under laparoscopy is feasible and is an important method for diagnose and differential diagnose. Hysterectomy is a reasonable option for patients who do not wish to preserve their fertility. It is particularly advisable for patients >40 whose risk of developing GTN is significantly increased. Hysterectomy can eliminate the risk of locally invasive disease, while it does not prevent metastases.²¹ GTN is a group of rare malignancies, with the incidence much less than benign pregnant associated disease. As histological examination is not routinely requested, the diagnosis of GTN can be delayed resulting in significantly greater morbidity.¹⁵ After a molar pregnancy, GTN may have the histologic pattern of either molar tissue or choriocarcinoma. However, following a non-molar pregnancy, GTN characteristically has only the histologic feature of choriocarcinoma. When it is difficult in making diagnosis, it is recommended to get tissue for pathological examination through hysterectomy or curettage, laparoscopy or laparotomy.²² It is reported that in a small percentage of perimenopausal and postmenopausal women, hysterectomy may be curative and/or may decrease the likelihood that the patient will need chemotherapy, or it may reduce the number of chemotherapy cycles needed to achieve cure.²³ For our patient, no obvious abnormalities were found on her lung CT, and the foci was found to be confined to the uterus on pelvic CT. We choose laparoscopy getting pathology evidence as

the preferred option. After hysterectomy through laparoscopy and a cycle of EMA-CO regimen chemotherapy, the patient recovered well and now in following up. It is important to note that for intramural pregnancy or choriocarcinoma, especially for the latter, because of the high blood flow, carefulness is needed during the procedure.

References

- Lurain JR. Gestational trophoblastic disease II: classification and management of gestational trophoblastic neoplasia. *Am J Obstet Gynecol.* 2011;204:11–18.
- Lurain JR. Gestational trophoblastic disease I: epidemiology, pathology, clinical presentation and diagnosis of gestational trophoblastic disease, and management of hydatidiform mole. *Am J Obstet Gynecol.* 2010;203:531–539.
- Martin BH, Kin JM. Changes in gestational trophoblastic tumors over four decades: a Korean experience. *J Reprod Med.* 1998;43:60–68.
- Sebire NJ, Foskett M, Fisher RA, et al. Risk of partial and complete hydatidiform molar pregnancy in relation to maternal age. *BJOG.* 2002;109:99–102.
- Berkowitz RS, Goldstein DP. Molar pregnancy. *N Engl J Med.* 2009;360:1639–1645.
- Mangili G, Lorusso D, Brown J, et al. Trophoblastic disease review for diagnosis and management: a joint report from the international society for the study of trophoblastic disease, European organisation for the treatment of trophoblastic disease, and the gynecologic cancer intergroup. *Int J Gynecol Cancer.* 2014;24(9 suppl 3):S109–S116.
- Baykal C, Tulunay G, Bulbul D, et al. Primary choriocarcinoma of the uterine cervix in a postmenopausal patient: a case report. *Gynecol Oncol.* 2003;(90):667–669.
- Lurain JR, Casanova LA, Miller DS, et al. Prognostic factors in gestational trophoblastic tumors: a proposed new scoring system based on multivariate analysis. *Am J Obstet Gynecol.* 1991;164:611–616.
- Alazzam M, Tidy J, Hancock BW, et al. First line chemotherapy in low risk gestational trophoblastic neoplasia. *Cochrane Database Syst Rev.* 2009;1, CD007102.
- Berkowitz RS, Goldstein DP. Pathogenesis of gestational trophoblastic neoplasms. *Pathobiol Annu.* 1981;11:391–411.
- Goldstein DP, Berkowitz RS. Current management of gestational trophoblastic neoplasia. *Hematol Oncol Clin N Am.* 2012;(26):111–131.
- Ngan HYS, Bender H, Benedet JL, et al. Gestational trophoblastic neoplasia, FIGO staging and classification. *Int J Gynecol Obstet.* 2003;83:175–177.
- Xia Z, Song H, Tang M. Risk of malignancy and prognosis using a provisional scoring system in hydatidiform mole. *Clin Med J.* 1980;20, 53–51.
- Tsukamoto N, Iwasaka T, Kashimura Y, et al. Gestational trophoblastic disease in women aged 50 or more. *Gynecol Oncol.* 1985;20:53–61.
- Seckl MJ, Gillmore R, Foskett M, et al. Routine terminations of pregnancy – should we screen for gestational trophoblastic neoplasia? *Lancet.* 2004;364:705–707.
- Glass T, Smith P, Hodges R, et al. Intramural pregnancy presenting in a patient with tuberous sclerosis. *J Clin Ultrasound.* 2010;7(38):393–396.
- Wu PJ, Han CM, Wang CJ, et al. Early detection and minimally invasive management of intramural pregnancy. *J Minim Invasive Gynecol.* 2013;1(20):123–126.
- Eoh KJ, Chung YS, Yim GW, et al. Role of surgical therapy in the management of gestational trophoblastic neoplasia. *Obstet Gynecol Sci.* 2015;58(4):277–282.
- Ryu JH, Choi CH, Kim TJ, Lee JW, Kim BG, Bae DS. Chemo-resistant choriocarcinoma metastatic to colon cured by low-anterior resection. *J Gynecol Oncol.* 2011;22(3):203–206.
- Armellino MF, Ambrosino F, Forner AL, et al. Jejunal perforation from metastatic choriocarcinoma. Case report and review of the literature. *G Chir.* 2008;29(4):145–148.
- Berkowitz RS, Goldstein DP. Current management of gestational trophoblastic disease. *Gynecol Oncol.* 2009;112:654–662.
- Seckl MJ, Sebire NJ, Fisher RA, et al. Gestational trophoblastic disease: ESMO clinical practice guideline for diagnosis, treatment and follow-up. *Ann Oncol.* 2013;00:1–12.
- Clark R, Nevadunsky N, Ghosh S, et al. The evolving role of hysterectomy in gestational trophoblastic neoplasia at the New England Trophoblastic Disease Center. *J Reprod Med.* 2010;55(5–6):194–198.
- Ngan HY, Seckl MJ, Berkowitz RS, et al. Update on the diagnosis and treatment of gestational trophoblastic disease. *Intern J Gynecol Obstet.* 2015;131:s123–s126.