



# Staged operation in the surgical treatment of granulomatous lobular mastitis

Lu Xie, Wenchao Qu, Jiamei Feng, Shijun Shao, Qingqian Gao, Jiaye Sun, Huili Tang, Hua Wan, Xueqing Wu

Mammary Department, Shuguang Hospital Affiliated to Shanghai University of Traditional Chinese Medicine, Shanghai, China

*Contributions:* (I) Conception and design: H Wan, X Wu; (II) Administrative support: H Wan, X Wu; (III) Provision of study materials or patients: All authors; (IV) Collection and assembly of data: L Xie, H Tang; (V) Data analysis and interpretation: L Xie; (VI) Manuscript writing: All authors; (VII) Final approval of manuscript: All authors.

*Correspondence to:* Hua Wan, BS; Xueqing Wu, MD. Mammary Department, Shuguang Hospital Affiliated to Shanghai University of Traditional Chinese Medicine, 528 Zhangheng Road, Shanghai 201203, China. Email: drwanhua@163.com; snow\_zi@hotmail.com.

**Background:** Granulomatous lobular mastitis (GLM) is a chronic inflammatory breast condition characterized by an unclear etiology and an undefined therapeutic approach. Surgical intervention is considered an alternative modality for managing GLM. Staged operation is the predominant and characteristic surgical approach in the treatment of GLM in our center; therefore, we evaluated the efficacy of staged operative techniques in this cohort study.

**Methods:** We retrospectively reviewed 212 patients with GLM who underwent staged operation between August 2020 and July 2022 in the inpatient department of our institute. Their clinical history information, clinic complaints, treatment details, surgical outcomes, follow-up results, and scores on the satisfaction questionnaire were analyzed. The patients were called for follow-up and consultation with a deadline of August 2023.

**Results:** The median follow-up time was 27 months (range, 14–37 months). In total, 212 patients were treated with three different staged procedures according to the individual assessment and patient willingness, including 168 patients who underwent one-stage debridement operation and two-stage suture operation (DO + SO), 25 patients who underwent one-stage debridement operation without suture (DO), and 19 patients who underwent one-stage debridement and simultaneous suture operation (DSO). The median recovery time was 29 days (range, 14–60 days). A minority of patients developed postoperative complications, including effusion (1.89%), flap ischemia (0.94%), areola-nipple ischemia (0.94%) and sinus tract formation (2.36%). The scores of the satisfaction questionnaire were  $43.10 \pm 3.09$ , and 186 patients (87.74%) gave high scores for postoperative breast appearance. Only 5 of 212 patients (2.36%) developed recurrence.

**Conclusions:** Staged operation performed in our institute is an effective and safe surgical therapy in patients with GLM, yielding a short recovery time, low recurrence and good cosmetic results.

**Keywords:** Granulomatous lobular mastitis (GLM); staged operation; recovery time; recurrence; satisfaction questionnaire

Submitted Sep 12, 2023. Accepted for publication Jan 11, 2024. Published online Feb 20, 2024.

doi: 10.21037/gs-23-386

View this article at: <https://dx.doi.org/10.21037/gs-23-386>

## Introduction

Granulomatous lobular mastitis (GLM) is a chronic inflammatory breast disease that typically occurs in women of childbearing age and mimics breast carcinoma

both clinically and radiologically (1). Although the morbidity of the disease appears to be growing, to date, the etiology of GLM remains unclear, and the disease is generally thought to be associated with autoimmunity (2),

hyperprolactinemia (3), oral contraceptives (4) and microbiological infection (5). The most common clinical manifestations of GLM include palpable breast masses, abscess formation, overlying skin inflammation, chronically unhealed ulcerations or fistulas and nipple retraction, with rapid onset and persistent procedure (6). Additionally, some patients present extramammary symptoms, such as fever, axillary lymphadenopathy, arthritis and erythema nodosa (7). The condition frequently has a chronic and long-term course, lasting up to 1–2 years (8).

While standard and optimal treatment guidelines have yet to be formulated, GLM remains a therapeutic challenge for clinicians. When GLM is diagnosed, there are two disparate treatment options in the literature: a conservative strategy involving medical therapy with antibiotics and corticosteroids versus a surgical approach.

#### Highlight box

##### Key findings

- Staged operation was safely and effectively performed in patients with granulomatous lobular mastitis (GLM) to achieve a low recurrence rate of 2.36% and an acceptable cosmetic breast appearance.
- Appropriate surgical timing and operative methods contribute to the success of GLM management.

##### What is known and what is new?

- Corticosteroid therapy was recommended as the primary conservative therapy for GLM management, but the usage of corticosteroids for a prolonged time may lead to medical-related side effects. Surgical treatment, including incision and drainage, wide excision, or even mastectomy, is an alternative approach for managing GLM and has been reported with varying results. Limited excision can result in a high tendency for recurrence; therefore, wide surgical excision has recently acquired acceptability for treating an increasing number of GLM cases, but extended resection may cause cosmetic disfigurement and poor wound healing.
- The staged operation in our center comprised three different surgical procedures for GLM management according to the individual clinical appraisal and patient willingness, and yielded successful outcomes with a short recovery time, a low recurrence rate of 2.36% and high cosmetic satisfaction.

##### What is the implication, and what should change now?

- This is the first study to evaluate the efficacy of staged operation to treat GLM. As a result, staged operation is safely and effectively performed in the surgical management of GLM with a high cure rate, low recurrence rate and cosmetic satisfaction, suggesting that it can be considered a preferred surgical treatment protocol for GLM management.

The role of antibiotic therapy in GLM is highly questioned, and there is no clear evidence yet to date on the therapeutic value of such treatment. Patients may be treated with antibiotics at the beginning of the therapy cascade due to the infectious clinical presentation (9,10), but antibiotic therapy usually fails, with a poor response rate of 3–21% (11–13). The application of corticosteroid therapy is recommended, but with no standard dose or regimens (14); such drugs are tapered gradually based on clinical findings and need to be applied for a long course. The usage of corticosteroids leads to a decrease in the breast lesions but also to various side effects, including weight gain, hyperglycemia, dyspepsia, and the risk of Cushing's syndrome (15).

Recently, surgical intervention has been recommended as one of the alternative treatment approaches, with fast recovery, high cure rates and low recurrence when compared with conservative treatment (6,16). In a meta-analysis conducted by Lei *et al.* (17), surgical treatment without or with corticosteroids and oral steroids were associated with cure rates of 90.6%, 94.5% and 71.8% and relative recurrence rates of 6.8%, 4.0% and 20.9%, respectively. Limited excision tends to result in a high tendency for recurrence; thus, wide excision is considered the ideal surgical option. Yabanoğlu *et al.* (18) reported that wide surgical excision resulted in a lower recurrence rate than conservative corticosteroid treatment. However, poor cosmetic breast outcomes may occur, especially in patients who undergo wide surgical excision procedures and who opt for mastectomy due to aggressive and recurrent symptoms (19,20).

Although GLM is a rare breast disease, our department, as a center dealing with GLM patients intensively from local and out-of-town regions, has encountered over 3,000 patients in the last 10 years, and over 1,000 of these patients underwent a surgical operation; thus, we have gained plenty of experience in treating GLM as a dominant disease. On the basis of our clinical experience, we have identified and performed characteristic staged operations for GLM surgical management, depending on the individual clinical appraisal and informed preference of the patients, achieving a high cure rate and low recurrence rate with acceptable cosmetic results. Here, we present the surgical selection, details and outcomes of staged operation in the surgical management of GLM patients, aiming to evaluate the applicability and efficacy of staged surgery. We present this article in accordance with the STROBE reporting checklist (available at <https://gs.amegroups.com/>

article/view/10.21037/gS-23-386/rc).

## Methods

### Patients

This was a retrospective case series with data collection conducted in the inpatient department of Shuguang Hospital affiliated to Shanghai University of Traditional Chinese Medicine mammary department over 2 years. A total of 212 patients diagnosed with GLM from August 2020 to July 2022 were recruited in this study and underwent appropriate surgical treatment, and complete follow-up data were obtained with a deadline of August 2023. This study was conducted in accordance with the Declaration of Helsinki (as revised in 2013). This research was approved by the Ethics Committee of Shuguang Hospital affiliated to Shanghai University of Traditional Chinese Medicine, approval #2021-956-31-02. Individual consent for this retrospective analysis was waived.

Multiple assessments involving clinical history information, clinical complaints, serological tests, ultrasound, enhanced magnetic resonance imaging (MRI), and histopathologic examinations were performed. Clinical history information included age, body mass index (BMI), history of delivery, history of smoking, history of diabetes, history of taking psychiatric drugs and history of GLM. Clinical complaints, such as disease duration; nipple involvement; the presence of masses, abscess and fistulas; extramammary symptoms; and treatment modalities, were all documented. Serological tests included routine blood tests, C-reactive protein (CRP), erythrocyte sedimentation rate (ESR) and prolactin (PRL). Microbiological culture was performed to evaluate the presence of bacteria. All patients were routinely examined by ultrasound and enhanced MRI to assess the extent of the lesion.

The diagnosis of GLM should combine clinical complaints, physical examination, imaging examination, laboratory tests and pathological examination (21). GLM is diagnosed histopathology by the presence of noncaseating granulomas centered around the breast lobules, multinuclear giant cells, leukocytes, plasma cells and possibly sterile microabscesses (22). All cases were pathologically confirmed by two experienced pathologists and were excluded for plasma cell mastitis, Zuska's disease, sarcoidosis, and Wegener disease. The exclusion criteria yielded 39 patients, including 1 male patient, 11 patients treated only with conservative therapy, 6 patients whose

pathological findings were not consistent with GLM, and 21 patients who were lost to follow-up. The enrollment of the patients is depicted in *Figure 1* as a flowchart.

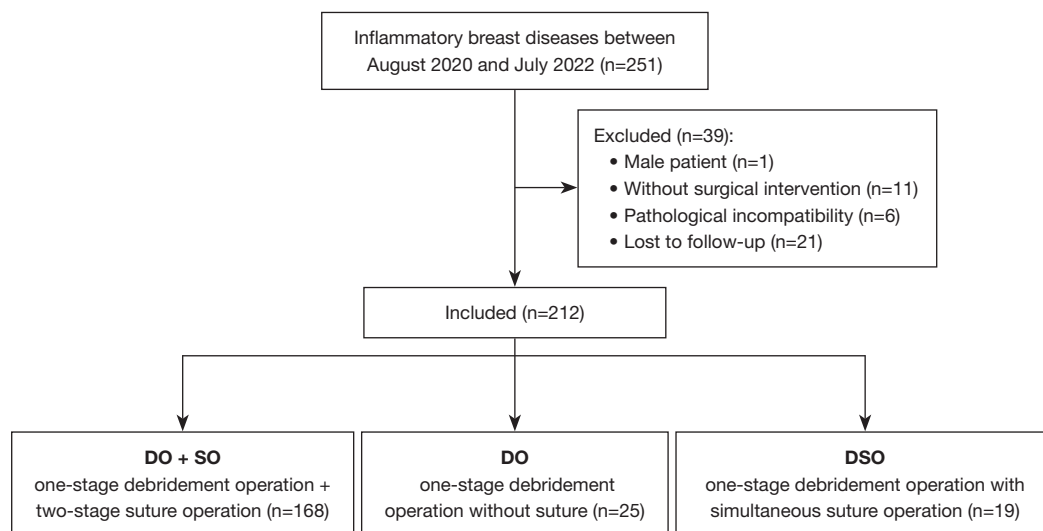
In this study, GLM was classified into three stages according to progression and clinical manifestations (23): (I) acute stage: early stage with swelling and pain or formed abscess, possibly accompanied by systemic symptoms such as fever; (II) subacute stage: plateau stage with recurrent and multiple manifestations such as masses, abscesses, and fistulas; and (III) chronic stage: remission stage with residual breast lump or persistent fistulas.

### Surgical technique

All surgical operations were performed under general anesthesia. Antibiotic cephalosporin or clindamycin was routinely administered to all patients postoperatively for 3 days. On the basis of the inflammatory skin changes and involved lesion localization, minor crescent or radial incisions were frequently performed, and the length was adjusted after repair to avoid dog-ear deformity. A concealed periareolar incision was preferred in patients without overlying skin changes, while a radial incision was preferred in patients with nipple inversion extending radially from the areola.

Staged operation was divided into three different procedures, including one-stage debridement operation and two-stage suture operation (DO + SO), one-stage debridement operation without suture (DO), and one-stage debridement with simultaneous suture operation (DSO), depending on the individual clinical appraisal and patient preference. During the one-stage debridement operation, the abscess cavity was fully opened for smooth drainage of pus, and the involved necrotic breast tissue, dilated ducts posterior to the nipple and ducts with substantial volumes of secretions were completely removed. We were careful to retain normal tissue and edematous glands surrounding the involved lesions to avoid over-excision. Gauze pieces were used for frequent dressing after the debridement operation. Cosmetically acceptable techniques were chosen. Intraglandular displacement techniques and local tissue rearrangement were generally used to close the pouch after resection of the lesions located in any quadrant of the breast, and nipple plastic surgery was applied in patients with inverted nipples by severing the underlying tight fibrous tissue bands and canaliculi.

We washed the pouch with saline alone during the debridement operation but repeatedly washed the wound



**Figure 1** Flow diagram of enrolled patients with granulomatous lobular mastitis from August 2020 to July 2022. DO + SO, one-stage debridement operation and two-stage suture operation; DO, one-stage debridement operation without suture; DSO, one-stage debridement and simultaneous suture operation.

sequentially with saline, hydrogen peroxide, and sterilized water before the suture procedure. A hemovac drain was routinely placed before suture, and the drains were withdrawn when the drain content decreased below 10 ml. All patients were followed up in terms of early and late complications.

### *Efficacy evaluation*

The cure standard was defined as the absence of breast inflammatory manifestations and the disappearance of radiological findings. If symptoms were not relieved after treatment, the patient was considered a non-responder (24). Recurrence was defined as the reappearance of the lesion in the ipsilateral breast within six months after reaching the standard of cure; a de novo lesion was defined as the appearance of a new lesion outside the original lesion in the ipsilateral breast and the contralateral breast (23). The recovery period was defined as the time between one-stage operation and the completion of cure criterion. Data on surgical outcomes, recurrence and follow-up results were collected and analyzed.

### *Satisfaction questionnaire*

Patients' subjective postoperative evaluations are one of the most significant indications of surgical success. Therefore, a satisfaction questionnaire soliciting responses related to

breast shape, treatment time, economic costs, treatment effect and life influence was employed in this study (25). The questionnaire was completed by each patient.

### *Statistical analysis*

The patient data were analyzed using SPSS 26.0 software (IBM Corp., Armonk, NY, USA). Quantitative variables are presented as the mean  $\pm$  standard deviation (SD) or median (range), while categorical variables are shown as numbers and percentages (%).  $P < 0.05$  served as the statistical standard for significant differences.

## **Results**

### *Clinical history information*

This study enrolled 212 GLM patients who underwent staged operation. The average age of all patients was approximately 33.90 years (range, 23–60 years) old. The BMI was  $23.85 \pm 4.01$  kg/m<sup>2</sup>, and 78 of 212 patients (36.79%) were overweight (BMI  $\geq 24.0$  kg/m<sup>2</sup>). A total of 207 patients (97.64%) had a pregnancy history of at least one delivery, 5 patients (2.36%) were smokers, 2 patients (0.94%) had a history of diabetes, and 2 patients (0.94%) took psychiatric drugs. A history of GLM was present in 34 patients (16.04%). The baseline demographic characteristics are shown in *Table 1*.

**Table 1** Clinical history information

Clinical history information	Values (N=212)
Age, years, mean [range]	33.90 [23–60]
BMI, kg/m <sup>2</sup> , mean ± SD	23.85±4.01
Delivery, n (%)	207 (97.64)
Smoking, n (%)	5 (2.36)
Diabetes, n (%)	2 (0.94)
Mental illness, n (%)	2 (0.94)
History of GLM, n (%)	34 (16.04)

BMI, body mass index; SD, standard deviation; GLM, granulomatous lobular mastitis.

### Clinical features

According to the clinical manifestations presented in *Table 2*, the mean duration of GLM was 3.0 months (range, 0.1–36 months), and 207 of 212 patients (97.64%) had unilateral breast involvement. The main symptoms were a painful lump (100%), abscesses complicated by superficial skin redness (78.77%), and fistula formation (48.11%). Nipple inversion was observed in 148 patients (69.81%). Additionally, 21 patients (9.91%) presented with extramammary symptom in the form of erythema nodosum. The masses with hard texture measured 1.5–18 cm (mean 9.69 cm) in size; additionally, the size in the DO + SO group (9.97±3.71 cm) and DO group (11.24±3.55 cm) was significantly larger than that in the DSO group (5.21±2.96 cm) ( $P<0.001$  and  $P<0.001$ , respectively).

In terms of previous treatments, the patients had accepted multiple treatment options, ranging from medical treatment with antibiotics (52.36%), corticosteroids (16.04%) and traditional Chinese medicine (TCM) (89.15%) to surgical interventions, including fine needle aspiration (13.21%), incision and drainage (13.21%), and excision (7.08%).

All patients routinely underwent serological tests, including routine blood tests, CRP, ESR and PRL, with values of (9.28±3.26)×10<sup>9</sup>/L (normal range, 3.69–9.16×10<sup>9</sup>/L), 9.75±16.28 mg/L (normal range, 0.00–8.00 mg/L),

**Table 2** Clinical features

Clinical features	Values (N=212)
Duration, months, median [range]	3.0 [0.1–36]
Affected side(s), n (%)	
Both sides	5 (2.36)
Unilateral side	207 (97.64)
Clinical findings, n (%)	
Nipple inversion	148 (69.81)
Painful mass	212 (100.00)
Abscess	167 (78.77)
Fistulas	102 (48.11)
Extramammary symptom, n (%)	
Erythema nodosum	21 (9.91)
Mass size, cm, mean ± SD	9.69±3.90
DO + SO group	9.97±3.71
DO group	11.24±3.55
DSO group	5.21±2.96***
Treatment options, n (%)	
Antibiotics	111 (52.36)
Corticosteroids	34 (16.04)
Traditional Chinese medicine	189 (89.15)
Fine needle aspiration	28 (13.21)
Incision and drainage	28 (13.21)
Excision	15 (7.08)
Laboratory tests, mean ± SD	
Leukocyte, ×10 <sup>9</sup> /L	9.28±3.26
CRP, mg/L	9.75±16.28
ESR, mm/L	36.94±25.15
PRL, mIU/L	584.22±538.60
Bacterial culture, n (%)	0 (0)

\*\*\*, DSO group vs. DO + SO group and DO group,  $P<0.001$ . DO + SO, one-stage debridement operation and two-stage suture operation; DO, one-stage debridement operation without suture; DSO, one-stage debridement and simultaneous suture operation; CRP, C-reactive protein; ESR, erythrocyte sedimentation rate; PRL, prolactin.



**Table 3** Postoperative outcomes

Postoperative outcomes	Values (N=212)
Recovery time, days, median [range]	29 [14–60]
DO + SO group	29 [28–35]
DO group	45 [30–60]
DSO group	14 [14–19]
Postoperative complications, n (%)	
Effusion	4 (1.89)
Flap ischemia	2 (0.94)
Areola-nipple ischemia	2 (0.94)
Sinus formation	5 (2.36)

DO + SO, one-stage debridement operation and two-stage suture operation; DO, one-stage debridement operation without suture; DSO, one-stage debridement and simultaneous suture operation.

36.94±25.15 mm/L (normal range 0.0–26.0 mm/L), and 584.22±538.60 mIU/L (normal range, 108.78–557.13 mIU/L), respectively. Compared to the DSO group, the DO + SO group and DO group presented significantly higher CRP ( $P=0.002$  and  $P<0.001$ , respectively) and ESR ( $P=0.004$  and  $P=0.001$ , respectively) levels, indicating a more severe inflammatory response. Additionally, the microbiological culture was negative upon routine examination for pathogens.

### **Surgical intervention**

Among the enrolled patients, 168 patients accepted DO + SO, 25 patients underwent DO, and 19 patients underwent DSO. The postoperative outcomes are presented in *Table 3*, and the cases that underwent staged operation are shown in *Figure 2* and *Figure 3*.

The median recovery time of all patients was 29 days (range, 14–60 days). The median time to healing in the DO + SO group and DSO group was 29 days (range, 28–35 days) and 14 days (range, 14–19 days), respectively, and the stitches could be removed after 2 to 3 weeks postoperatively. Patients in the DO group changed the dressing using draining gauze pieces every day postoperatively; as a result, the median recovery time was 45 days (range, 30–60 days). No intraoperative complications occurred in any patients.

In the postoperative follow-up period, a lack of postoperative wound healing was caused by effusion

(1.89%), flap ischemia (0.94%), areola-nipple ischemia (0.94%) and sinus formation (2.36%). All patients were successfully managed by frequent dressings.

### **Satisfaction questionnaire**

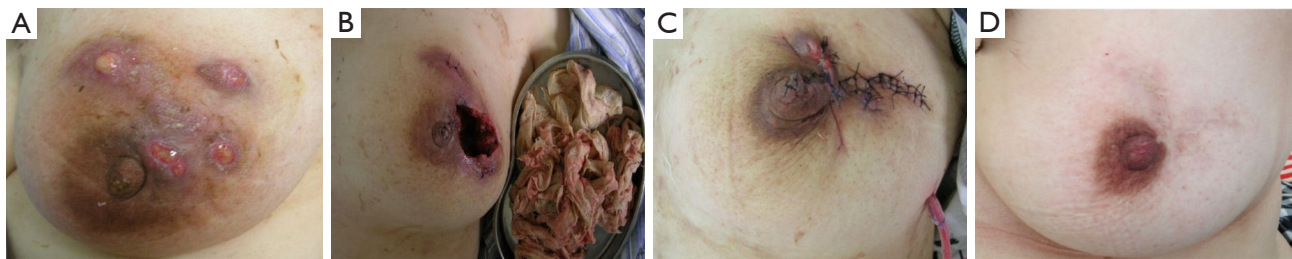
Owing to the complicated features of and difficult treatment strategies for GLM, the efficiency of surgical treatment needs to comprehensively consider breast shape, treatment time, economic costs, treatment effect and life influence. As shown in *Table 4*, the total scores of the satisfaction questionnaire were 43.10±3.09, and the scores of the five aspects were 8.73±1.51, 8.71±1.44, 7.58±1.37, 9.91±0.61, and 8.18±1.06. A total of 108 patients (50.94%) gave a score of 10, and 78 patients (36.79%) gave a score of 8, suggesting their satisfaction with their postoperative breast appearance. A total of 191 patients (90.09%) thought that the surgical treatment did not interfere with their daily life, 181 patients (85.38%) thought that the treatment time was acceptable, and 207 patients (97.64%) received a good treatment effect.

### **Follow-up results**

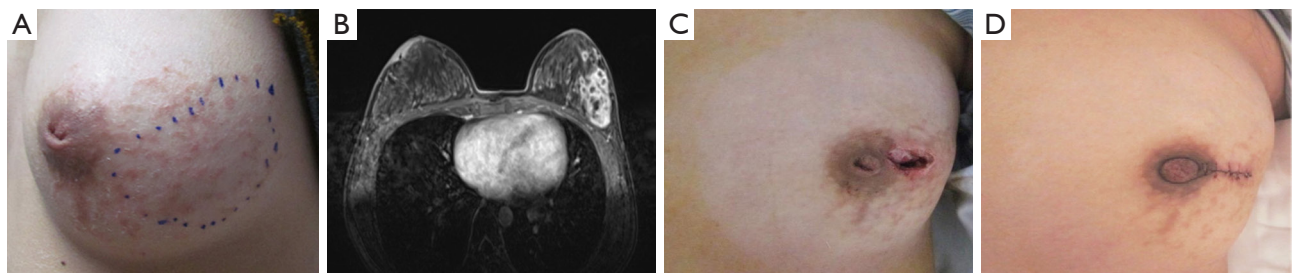
In a total of 212 cases, follow-up visits by consultations lasted for 14–37 months, with a median of 27 months. During the follow-up periods (*Table 5*), 5 patients developed recurrence at 3 weeks to 6 months postoperatively, with a recurrence rate of 2.36%. Two of the five patients were effectively managed by conservative treatment, while three others benefited from reoperation. Additionally, 14 patients (6.60%) presented a new lesion in the contralateral breast at 3 to 25 months, and 9 patients (4.25%) developed a new lesion in the ipsilateral breast at 14 to 35 months; therefore, the rate of de novo lesion development was 10.85%.

### **Discussion**

GLM is a chronic inflammatory breast illness that is most commonly encountered in women of childbearing age with a delivery history (26) and was first reported by Kessler and Wolloch in 1972 (27) and further detailed by Cohen in 1977 (28); however, the etiology remains unknown. The main complications of GLM are a tender mass, superficial abscess formation, chronic draining fistulas and extramammary symptoms such as erythema nodosum. These findings were also confirmed in our study. Although GLM is recognized as a benign disease, the clinical features have a great impact on patients' quality of life, including



**Figure 2** Case 1. A 40-year-old female patient presented with a left upper-outer quadrant lesion after DO + SO with intraglandular flap transposition. (A) Preoperative breast mass with abscesses complicated by superficial skin redness and multiple ulcers; (B) 3 days after the one-stage debridement operation and gauze-piece dressing change; (C) 3 days after the two-stage suture operation; (D) 6 months after the staged operation. DO + SO, one-stage debridement operation and two-stage suture operation.



**Figure 3** Case 2. A 28-year-old female patient developed a left lateral quadrant lesion after DO + SO with radial incision and nipple plastic surgery. (A) Preoperative painful lump with a congenital inverted nipple; (B) enhanced magnetic resonance imaging images showing non-mass-like enhancement in the lateral left breast; (C) 3 days after the one-stage debridement operation; (D) 2 weeks after the two-stage suture operation. DO + SO, one-stage debridement operation and two-stage suture operation.

**Table 4** Satisfaction questionnaire

Satisfaction questionnaire	Scores (N=212)
Total	43.10±3.09
Breast shape	8.73±1.51
Treatment time	8.71±1.44
Economic costs	7.58±1.37
Treatment effect	9.91±0.61
Life influence	8.18±1.06

Data are presented as mean ± standard deviation.

**Table 5** Follow-up results

Follow-up results	Values (N=212)
Follow-up time, months, median [range]	27 [14–37]
Recurrence, n (%)	5 (2.36)
<i>De novo</i> lesion, n (%)	23 (10.85)
Contralateral side	14 (6.60)
Ipsilateral side	9 (4.25)

chronic symptoms, a low cure rate, a high recurrence rate and a protracted course.

Until now, no uniform standards for treatment and no effective preventive methods have been established for this disease (21). Alternative treatment methods vary from observation and medical therapy (antibiotics, corticosteroids, TCM) to surgical therapy (fine needle

aspiration, incision and drainage, excision and mastectomy), and multiple methods are frequently used sequentially or simultaneously to improve the therapeutic effect (13,14). The management strategy for GLM is controversial, and consequently, the option of conservative treatment and surgical therapy has always been discussed in the literature and in present clinical practice.

Conservative regimens comprise mainly antibiotics and corticosteroids; in general, medical treatment may have a

longer course of recovery. However, there is not sufficient evidence for the efficacy of antibiotic treatment for GLM patients without a proven bacterial infection. Several studies have reported that appropriate antibiotics could be used with consideration in patients with an acute infection, but the response can be quite slow with low efficacy, and long courses of antibiotics should be avoided (24,29). Corticosteroids are the mainstay of treatment for GLM with no standard dose and various regimens lasting for approximately 2–6 months (21,30), and the recurrence rate can be up to 15–37.5% (14,31–33). In addition, the usage of corticosteroids for a prolonged time may lead to weight gain, osteoporosis, and worsening infections (34).

Surgical treatment, including incision and drainage, wide excision, or even mastectomy, is also one of the alternative treatment options in present clinical practice (35) and has been described with varying results. A 16–66% recurrence rate after surgical treatment has been reported (36–38). Wide surgical excision has recently acquired acceptability for treating an increasing number of GLM cases, but extended resection to obtain clean surgical margins may cause effusion, hematoma, and breast gland abnormalities, while limited surgical methods may result in a high tendency for recurrence (25,39). Regarding surgery, some studies have concluded that surgical operation is the ideal treatment strategy (9,35,40–42); however, some authors have advocated surgery as a last-line approach since surgical intervention may cause complications such as cosmetic disfigurement, poor wound healing, flap ischemia and sinus formation (1,22,43). Thus, GLM is acknowledged to be a difficult and distressing breast disease for surgeons.

From our perspective, surgical treatment is carried out to shorten the disease duration and reduce recurrence, and appropriate surgical methods can be seen as the preferred therapeutic modalities. In clinical practice, we have identified staged operations and utilized different staged surgical techniques depending on the individual clinical assessment and patient willingness. Our aims for surgical techniques are to design minor incisions and excise as few glands as possible intraoperatively to preserve the maximum volume of healthy tissue and achieve a low recurrence rate. To the best of our knowledge, this is the first study to apply staged operations for GLM surgical management. In this study, we retrospectively analyzed the efficacy of staged surgery and compared many factors, including recovery time, postoperative complications, recurrence rate, and satisfaction questionnaire results.

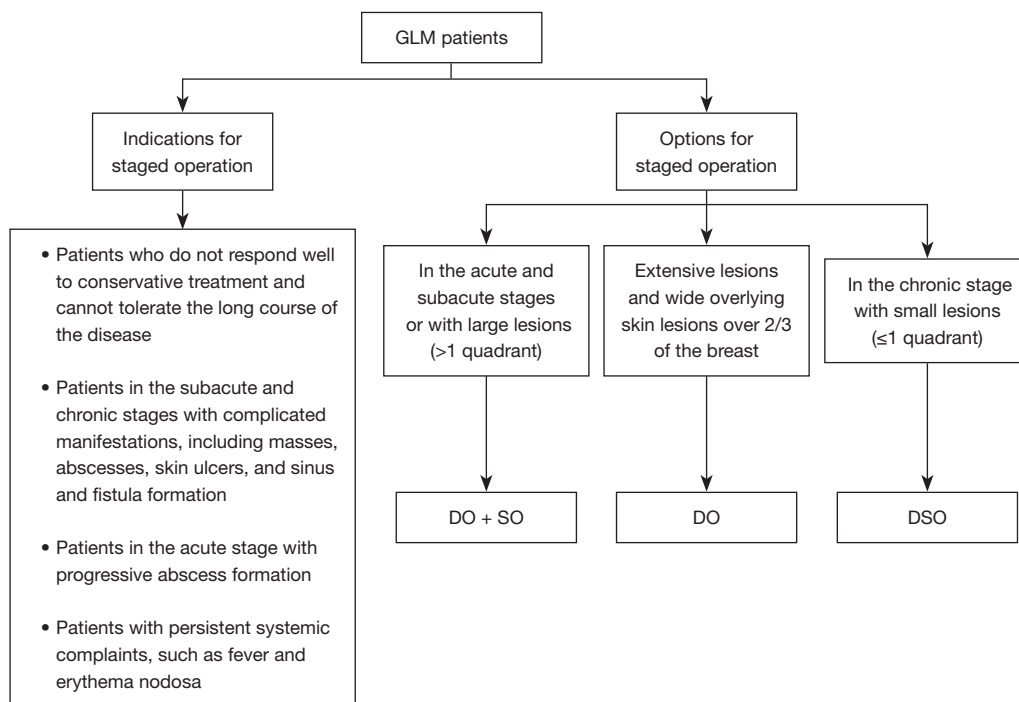
The staged operation was strictly conducted throughout

the perioperative period, and physical examinations and radiological assessments, including ultrasound and MRI, were necessary to evaluate the range of lesions and rule out breast cancer. The appropriate operative timing is the key to the successful treatment of GLM. We recommended the following indications for the consideration of staged operation: (I) patients who do not respond well to conservative treatment and cannot tolerate the long course of the disease; (II) patients in the subacute and chronic stages with complicated manifestations, including masses, abscesses, skin ulcers, and sinus and fistula formation; (III) patients in the acute stage with progressive abscess formation; and (IV) patients with persistent systemic complaints, such as fever and erythema nodosa.

Certainly, patients and their families, as well as their surgeons, undoubtedly deliberated over the surgical technique prior to surgery. The option of appropriate surgical methods is also one of the keys to the success of surgery, and the protocol is summarized in *Figure 4*. For cases in the acute and subacute stages or with large lesions (>1 quadrant), we performed the surgical combination of one-stage debridement operation and two-stage suture operation with an interval of 2 weeks of open wound dressing care; for patients with extensive lesions and wide overlying skin lesions over 2/3 of the breast, we utilized the DO techniques combined with gauze-piece dressing changes to promote the natural growth of breast tissue and skin; for patients in the chronic stage with small lesions (≤1 quadrant), we performed the DSO procedure. To achieve an acceptable cosmetic appearance, we performed simultaneous plastic and reconstructive breast surgeries during the suture procedure. In general, the surgical methods comprised local tissue rearrangement, medial and lateral mammoplasty, intraglandular flap transposition and nipple plasty. Postoperative complications developed in a minority of our cases (6.13%), including effusion (1.89%), flap ischemia (0.94%), areola-nipple ischemia (0.94%) and sinus formation (2.36%), and were managed conservatively.

In an international multidisciplinary consensus (21), patients who have acute infection symptoms or are in the advanced stage and patients with extensive lesions and a wide area of skin lesions involving more than 2/3 of the breast are relatively contraindicated for surgery, owing to possibly severe intraoperative bleeding, inflammatory progression and cosmetic disfigurement. However, our staged surgical approaches allow such patients who have relative contraindications but cannot tolerate serious symptoms to have the opportunity to undergo surgical management and





**Figure 4** Staged operation protocol for granulomatous lobular mastitis surgical management. GLM, granulomatous lobular mastitis; DO + SO, one-stage debridement operation and two-stage suture operation; DO, one-stage debridement operation without suture; DSO, one-stage debridement and simultaneous suture operation.

recover in a relatively short time. We found that the lesions significantly shrank with acute inflammation fully controlled under the combination of debridement operation and gauze-piece drainage.

Since recurrence is generally prevalent in GLM, long-term follow-up is needed. Our retrospective investigation found an overall recurrence rate of only 2.36%; we additionally observed that 6.60% of patients developed a new lesion in the contralateral breast and that 4.25% of patients presented a new lesion in the ipsilateral side. A satisfaction questionnaire was used in this study since it was suggested that the subjective evaluation of patients postoperatively must be taken into consideration. According to the literature (23), we comprehensively evaluated five aspects, including breast shape, treatment time, economic costs, treatment effect and life influence. The majority of patients gave high satisfaction scores for our staged operation.

The decision of whether surgery or conservative treatment is preferred might depend on the patient's expectations, surveillance opportunities and divergent regional therapy management. For patients who meet

the surgical indications, proper surgical management can be established. This study demonstrated that the staged operation techniques at our center yielded successful outcomes with a high cure rate and low recurrence tendency for GLM patients, and most patients were satisfied with their cosmetic breast appearance. Nevertheless, larger-scale randomized controlled trials with longer follow-up periods are needed to evaluate the efficacy and superiority of staged surgery.

## Conclusions

With a large case series between August 2020 and July 2022 in the inpatient department of our center, we evaluated staged operations (varying applications of DO + SO, DO and DSO), which were safely and effectively performed in patients diagnosed with GLM depending on the individual clinical appraisal and patients' willingness. A low recurrence rate of 2.36% and an acceptable cosmetic breast appearance were achieved, suggesting that staged operation can be considered a preferred treatment protocol for GLM surgical management.

## Acknowledgments

*Funding:* This research was supported by the Health Industry Clinical Research Project of Shanghai Municipal Health Commission (No. 202040254) and the Si-Ming Fund of Shuguang Hospital Affiliated to Shanghai University of Traditional Chinese Medicine (No. SGKJ-202308).

## Footnote

*Reporting Checklist:* The authors have completed the STROBE reporting checklist. Available at <https://gs.amegroups.com/article/view/10.21037/gS-23-386/rc>

*Data Sharing Statement:* Available at <https://gs.amegroups.com/article/view/10.21037/gS-23-386/dss>

*Peer Review File:* Available at <https://gs.amegroups.com/article/view/10.21037/gS-23-386/prf>

*Conflicts of Interest:* All authors have completed the ICMJE uniform disclosure form (available at <https://gs.amegroups.com/article/view/10.21037/gS-23-386/coif>). The authors have no conflicts of interest to declare.

*Ethical Statement:* The authors are accountable for all aspects of the work in ensuring that questions related to the accuracy or integrity of any part of the work are appropriately investigated and resolved. This study was conducted in accordance with the Declaration of Helsinki (as revised in 2013). This study was approved by the Ethics Committee of Shuguang Hospital affiliated to Shanghai University of Traditional Chinese Medicine, approval #2021-956-31-02. Individual consent for this retrospective analysis was waived.

*Open Access Statement:* This is an Open Access article distributed in accordance with the Creative Commons Attribution-NonCommercial-NoDerivs 4.0 International License (CC BY-NC-ND 4.0), which permits the non-commercial replication and distribution of the article with the strict proviso that no changes or edits are made and the original work is properly cited (including links to both the formal publication through the relevant DOI and the license). See: <https://creativecommons.org/licenses/by-nc-nd/4.0/>.

## References

1. Barreto DS, Sedgwick EL, Nagi CS, et al. Granulomatous

- mastitis: etiology, imaging, pathology, treatment, and clinical findings. *Breast Cancer Res Treat* 2018;171:527-34.
2. Parperis K, Achilleos S, Costi E, et al. Granulomatous mastitis, erythema nodosum and arthritis syndrome: case-based review. *Rheumatol Int* 2021;41:1175-81.
3. Tian C, Wang H, Liu Z, et al. Characteristics and Management of Granulomatous Lobular Mastitis Associated with Antipsychotics-Induced Hyperprolactinemia. *Breastfeed Med* 2022;17:599-604.
4. Tasci HI, Turk E, Erinanc OH, et al. Factors Affecting Recurrence of Idiopathic Granulomatous Mastitis. *J Coll Physicians Surg Pak* 2022;32:161-5.
5. Bi J, Li Z, Lin X, et al. Etiology of granulomatous lobular mastitis based on metagenomic next-generation sequencing. *Int J Infect Dis* 2021;113:243-50.
6. Martinez-Ramos D, Simon-Monterde L, Suelves-Piqueres C, et al. Idiopathic granulomatous mastitis: A systematic review of 3060 patients. *Breast J* 2019;25:1245-50.
7. Velidedeoglu M, Papila Kundaktepe B, Mete B, et al. Idiopathic granulomatous mastitis associated with erythema nodosum may indicate a worse prognosis. *Int J Rheum Dis* 2021;24:1370-7.
8. Benson JR, Dumitru D. Idiopathic granulomatous mastitis: presentation, investigation and management. *Future Oncol* 2016;12:1381-94.
9. Elzahaby IA, Khater A, Fathi A, et al. Etiologic revelation and outcome of the surgical management of idiopathic granulomatous mastitis; An Egyptian centre experience. *Breast Dis* 2016;36:115-22.
10. Bashir MU, Ramcharan A, Alothman S, et al. The enigma of granulomatous mastitis: A series. *Breast Dis* 2017;37:17-20.
11. Aghajanzadeh M, Hassanzadeh R, Alizadeh Sefat S, et al. Granulomatous mastitis: Presentations, diagnosis, treatment and outcome in 206 patients from the north of Iran. *Breast* 2015;24:456-60.
12. Freeman CM, Xia BT, Wilson GC, et al. Idiopathic granulomatous mastitis: A diagnostic and therapeutic challenge. *Am J Surg* 2017;214:701-6.
13. Velidedeoglu M, Umman V, Kilic F, et al. Idiopathic granulomatous mastitis: introducing a diagnostic algorithm based on 5 years of follow-up of 152 cases from Turkey and a review of the literature. *Surg Today* 2022;52:668-80.
14. Montazer M, Dadashzadeh M, Moosavi Toomatari SE. Comparison of the Outcome of Low Dose and High-Dose Corticosteroid in the Treatment of Idiopathic Granulomatous Mastitis. *Asian Pac J Cancer Prev* 2020;21:993-6.
15. Çetin K, Sıkar HE, Göret NE, et al. Comparison of

- Topical, Systemic, and Combined Therapy with Steroids on Idiopathic Granulomatous Mastitis: A Prospective Randomized Study. *World J Surg* 2019;43:2865-73.
16. Hur SM, Cho DH, Lee SK, et al. Experience of treatment of patients with granulomatous lobular mastitis. *J Korean Surg Soc* 2013;85:1-6.
  17. Lei X, Chen K, Zhu L, et al. Treatments for Idiopathic Granulomatous Mastitis: Systematic Review and Meta-Analysis. *Breastfeed Med* 2017;12:415-21.
  18. Yabanoğlu H, Çolakoğlu T, Belli S, et al. A Comparative Study of Conservative versus Surgical Treatment Protocols for 77 Patients with Idiopathic Granulomatous Mastitis. *Breast J* 2015;21:363-9.
  19. Calis H, Karabeyoglu SM. Follow-up of granulomatous mastitis with monitoring versus surgery. *Breast Dis* 2017;37:69-72.
  20. Hladik M, Schoeller T, Ensaf F, et al. Idiopathic granulomatous mastitis: successful treatment by mastectomy and immediate breast reconstruction. *J Plast Reconstr Aesthet Surg* 2011;64:1604-7.
  21. Yuan QQ, Xiao SY, Farouk O, et al. Management of granulomatous lobular mastitis: an international multidisciplinary consensus (2021 edition). *Mil Med Res* 2022;9:20.
  22. Wolfrum A, Kümmel S, Theuerkauf I, et al. Granulomatous Mastitis: A Therapeutic and Diagnostic Challenge. *Breast Care (Basel)* 2018;13:413-8.
  23. Liu X, Chen Q. Expert consensus on traditional Chinese medicine diagnosis and treatment of granulomatous lobular mastitis (2021 edition). *Chin J Sur Integr Tradit West Med* 2022;28:597-602.
  24. Mahlab-Guri K, Asher I, Allweis T, et al. Granulomatous Lobular Mastitis. *Isr Med Assoc J* 2015;17:476-80.
  25. Wang J, Zhang Y, Lu X, et al. Idiopathic Granulomatous Mastitis with Skin Rupture: A Retrospective Cohort Study of 200 Patients Who Underwent Surgical and Nonsurgical Treatment. *J Invest Surg* 2021;34:810-5.
  26. Li SB, Xiong Y, Han XR, et al. Pregnancy associated granulomatous mastitis: clinical characteristics, management, and outcome. *Breastfeed Med* 2021;16:759-64.
  27. Kessler E, Wolloch Y. Granulomatous mastitis: a lesion clinically simulating carcinoma. *Am J Clin Pathol* 1972;58:642-6.
  28. Cohen C. Granulomatous mastitis. A review of 5 cases. *S Afr Med J* 1977;52:14-6.
  29. Omranipour R, Vasigh M. Mastitis, Breast Abscess, and Granulomatous Mastitis. *Adv Exp Med Biol* 2020;1252:53-61.
  30. Coombe RF, Hamed H. An update on granulomatous mastitis: a rare and complex condition. *Br J Hosp Med (Lond)* 2021;82:1-7.
  31. Yuksekdog S, Yildiz A, Yildirak K, et al. Conservative management of 154 patients with idiopathic granulomatous mastitis: Simple is better? *Ann Ital Chir* 2020;91:154-60.
  32. Sarkar DK, Banerjee R, Gupta S, et al. Management of idiopathic granulomatous mastitis: a prospective study. *Ann R Coll Surg Engl* 2023;105:218-24.
  33. Azlina AF, Ariza Z, Arni T, et al. Chronic granulomatous mastitis: diagnostic and therapeutic considerations. *World J Surg* 2003;27:515-8.
  34. Yaghan R, Hamouri S, Ayoub NM, et al. A Proposal of a Clinically Based Classification for Idiopathic Granulomatous Mastitis. *Asian Pac J Cancer Prev* 2019;20:929-34.
  35. Prasad S, Jaiprakash P, Dave A, et al. Idiopathic granulomatous mastitis: an institutional experience. *Turk J Surg* 2017;33:100-3.
  36. Ocal K, Dag A, Turkmenoglu O, et al. Granulomatous mastitis: clinical, pathological features, and management. *Breast J* 2010;16:176-82.
  37. Kok KY, Telisinghe PU. Granulomatous mastitis: presentation, treatment and outcome in 43 patients. *Surgeon* 2010;8:197-201.
  38. Lermi N, Ekin A, Ocak T, et al. What predicts the recurrence in idiopathic granulomatous mastitis? *Clin Rheumatol* 2023;42:2491-500.
  39. Dağ A, Edizsoy A, Berkeşoğlu M. Oncoplastic Breast Surgery Techniques When Surgery is Essential for the Management of the Idiopathic Granulomatous Mastitis. *J Invest Surg* 2022;35:653-8.
  40. Xu S, Zhu X, Miao L, et al. Treatment of granulomatous mastitis in different stages. *Asian J Surg* 2022;45:2287-8.
  41. Toman D, Prokop J, Kubala O, et al. Granulomatous mastitis treatment options and our experience. *Rozhl Chir* 2021;100:192-75.
  42. Li C, Wei X, Wang Y, et al. Rotational gland dissection for refractory granulomatous mastitis: A single-center retrospective study. *Asian J Surg* 2024;47:328-32.
  43. Sheybani F, Sarvghad M, Naderi H, et al. Treatment for and clinical characteristics of granulomatous mastitis. *Obstet Gynecol* 2015;125:801-7.

**Cite this article as:** Xie L, Qu W, Feng J, Shao S, Gao Q, Sun J, Tang H, Wan H, Wu X. Staged operation in the surgical treatment of granulomatous lobular mastitis. *Gland Surg* 2024;13(2):144-154. doi: 10.21037/gs-23-386