

Case Report

Prolonged delayed vasospasm in the setting of nonaneurysmal intraventricular hemorrhage

Rose Fluss, Avra Laarakker¹, Jonathan Nakhla², Allan Brook³, David Joseph Altschul

Department of Neurosurgery, Montefiore Medical Center, University Hospital for Albert Einstein College of Medicine, Bronx, NY, ¹Department of Plastics Surgery, University of New Mexico, ¹ University of New Mexico, Albuquerque, NM, ²Department of Neurosurgery, Brown University, Providence, RI 02903, ³Department of Radiology, Montefiore Medical Center, University Hospital for Albert Einstein College of Medicine, Bronx, NY 10467, USA

E-mail: Rose Fluss - fluss@mail.einstein.yu.edu; Avra Laarakker - avracadavra@gmail.com; Jonathan Nakhla - jonathan.nakhla@gmail.com;

Allan Brook - abrook@montefiore.org; *David Joseph Altschul - daltschu@montefiore.org

*Corresponding author

Received: 12 November 18 Accepted: 14 December 18 Published: 11 March 19

Abstract

Background: Though still thought to be rare, in recent years, vasospasm as a result of primary intraventricular hemorrhage (IVH) has been increasingly recognized in patients with spontaneous primary intraventricular hemorrhage, of various etiologies. Unlike vasospasm in aneurysmal subarachnoid hemorrhage (SAH), which has a well-defined time frame of 3–21 days, such a window is poorly defined for primary spontaneous intraventricular hemorrhage from other vascular etiologies.

Case Description: We report on two cases of prolonged delayed proximal intracranial cerebral vasospasm occurring 29 and 22 days after the initial presentation.

Conclusion: To our knowledge, this is the first report of such delayed vasospasm in spontaneous primary intraventricular hemorrhage secondary to a dural arteriovenous fistula and cavernous malformation. Our two cases of vasospasm in patients with nontraumatic nonaneurysmal SAH with IVH presented outside the expected time period of 21 days. It is important to recognize that symptomatic vasospasm secondary to intraventricular hemorrhage is a rare but devastating complication that can have serious deleterious consequences if gone unrecognized and untreated.

Key Words: Delayed cerebral ischemia, delayed cerebral vasospasm, intraventricular hemorrhage

Access this article online

Website:

www.surgicalneurologyint.com

DOI:

10.4103/sni.sni_396_18

Quick Response Code:

BACKGROUND

Though still thought to be rare, in recent years, vasospasm of vascular origin with intraventricular hemorrhage (IVH) has been increasingly recognized in patients with spontaneous primary intraventricular hemorrhage, of various etiologies.^[1-5] We report on two cases of prolonged delayed proximal intracranial cerebral vasospasm occurring 29 and 22 days after the initial presentation. To our knowledge, this is the first report of such delayed vasospasm in spontaneous primary intraventricular hemorrhage secondary to a ruptured dural arteriovenous fistula and cavernous malformation. Our two cases of

vasospasm in patients with nontraumatic nonaneurysmal subarachnoid hemorrhage with IVH also presented outside the usual expected time period of 21 days.

This is an open access journal, and articles are distributed under the terms of the Creative Commons Attribution-NonCommercial-ShareAlike 4.0 License, which allows others to remix, tweak, and build upon the work non-commercially, as long as appropriate credit is given and the new creations are licensed under the identical terms.

For reprints contact: reprints@medknow.com

How to cite this article: Fluss R, Laarakker A, Nakhla J, Brook A, Altschul DJ. Prolonged delayed vasospasm in the setting of nonaneurysmal intraventricular hemorrhage. *Surg Neurol Int* 2019;10:29.

<http://surgicalneurologyint.com/Prolonged-delayed-vasospasm-in-the-setting-of-nonaneurysmal-intraventricular-hemorrhage/>

CASE DESCRIPTION

Patient 1

A 47-year-old man was presented with acute onset of nausea, light-headedness, palpitations, and fatigue. His mental status deteriorated but his neurological exam was otherwise nonfocal. Computed tomography (CT) [Figure 1] revealed a right parietal intraparenchymal hemorrhage with IVH. A ventriculostomy was placed for hydrocephalus. Catheter angiography showed a Cognard type IV dAVF [Figure 2], which was embolized the next day and cured [Figure 3]. On post-bleed day (PBD) 12, he became stuporous. An MRI revealed acute bilateral basal ganglia infarcts and a magnetic resonance angiography for severe multivessel vasospasm. He improved with induced hypertension; however, his symptoms worsened and he was taken for angiogram. At angiogram, verapamil was delivered to the right internal carotid and vertebral arteries; furthermore, both A1 segments of the anterior cerebral arteries underwent balloon angioplasty. On PBD 29, he became aphasic and angiogram now showed severe left internal carotid artery vasospasm [Figures 4 and 5], which was in a different vascular distribution than his prior vasospasm episode. Induced hypertension was initiated with no improvement. Balloon angioplasty was then performed with improvement in exam. He underwent workup for vasculitides that were negative given the severity of the vasospasm; however, afterward, it did not recur. On discharge on PBD 52, he was conversant and ambulatory without assistance. He made a full recovery 3 months after discharge.

Patient 2

The patient is a 66-year-old right-handed man with a remote history of idiopathic intraventricular hemorrhage 6 years prior to presentation at our clinic. He was presented to the ER with severe headaches and was found to again have an intraventricular hemorrhage on CT scan [Figure 6]. Angiogram [Figure 7] was again negative and an MRI [Figure 8] showed what appeared to be a cavernous malformation with of the third ventricle with surrounding hemorrhage and layering in the atria of the occipital horns bilaterally. Subsequently, the hemorrhage eventually recirculated into the subarachnoid space and he developed hydrocephalus requiring external ventricular drainage on PBD 9. Two days later, he underwent a right transcortical approach for removal of the cavernous malformation. His hospital course was complicated by cerebral vasospasm on PBD 22, which failed medical management and required interventional treatment by angioplasty of the left vertebral artery, bilateral A1, right M1, and a verapamil injection to the right ICA [Figure 9]. Upon discharge, he was dysphasic, with poor memory and balance; however, he improved to functional independence over the subsequent 2 months.

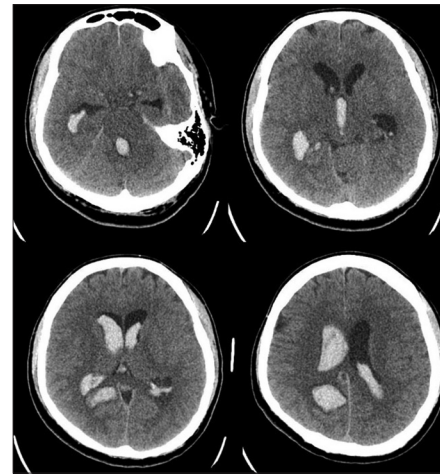


Figure 1: Case #1 Presenting axial non-contrast CT scan showing large amount of IVH

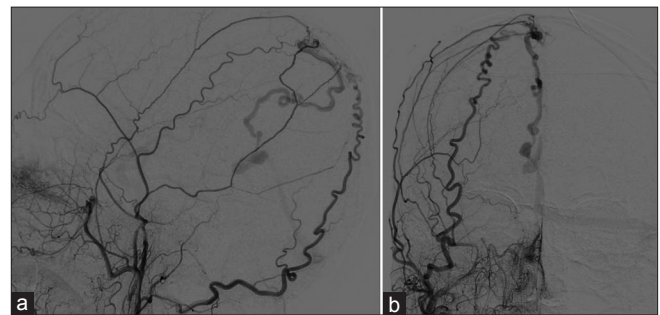


Figure 2: Case #1 Catheter angiography showed a Cognard type IV dAVF [(a) Lateral and (b) A/P Views]

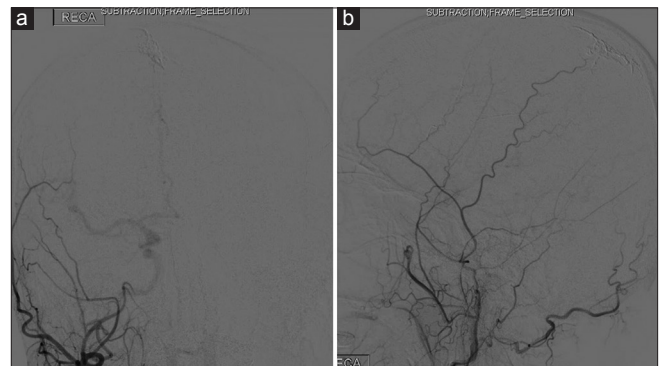

Figure 3: Case #1 Catheter angiography showing cured dAVF [(a) A/P and (b) Lateral Views]

CONCLUSION

We described above two rare cases of patients with IVH with symptomatic vasospasm occurring outside the anticipated window for vasospasm. The proposed mechanism for delayed vasospasm is thought to be recirculation of IVH into the subarachnoid space as opposed to vasospasm due to the direct presence of blood in the subarachnoid space. Since the process of recirculation takes time to occur, the actual time for vasospasm presentation is directly related

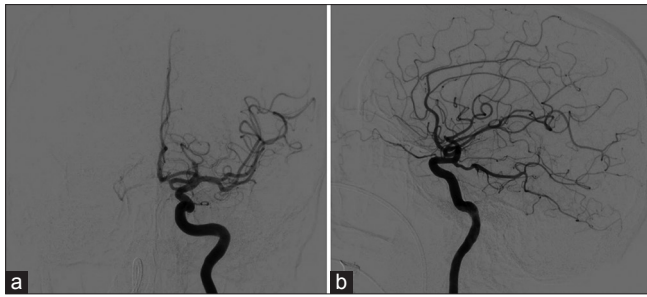


Figure 4: Case #1 Catheter angiography of initial left ICA injection [(a) A/P view and (b) Lateral View]

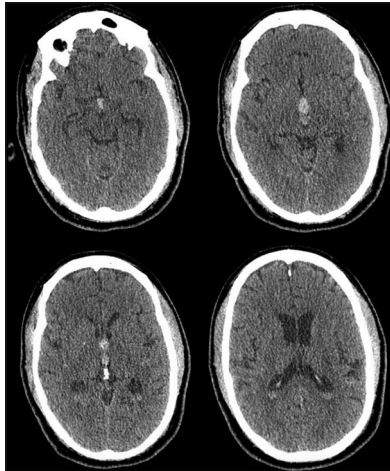


Figure 6: Case #2. Presenting axial non-contrast CT scan showing primary 3rd ventricular IVH

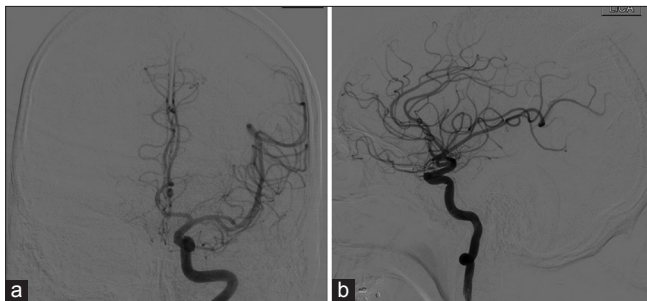

Figure 8: Case #1 (a) Initial Catheter angiography AP projection of left ICA. (b) Initial Catheter angiography lateral projection of left ICA

to the time it takes for blood to enter the subarachnoid space. When accounting for this time delay, the vasospasm actually occurs within the normal timeframe. We speculate that due to this process of recirculation, the window of concern for vasospasm is both delayed and prolonged, as was seen in our two patients. The understanding of resorption and clearance of IVH is poorly described, but time of clearance would presumably be longer and may contribute to the delayed effect on the intracranial arteries in the subarachnoid space. Additionally, large volumes of blood would also have prolonged clearance time and thus prolong the exposure of blood, blood breakdown products,

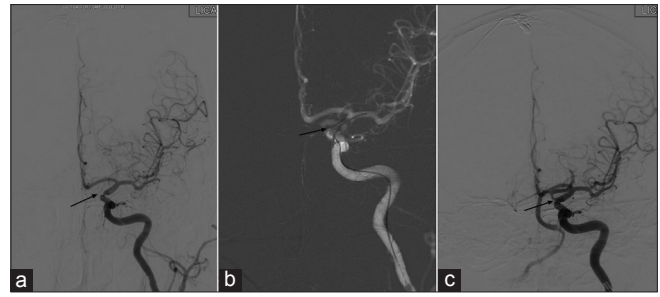


Figure 5: (a) Catheter angiography from PBD 29 showing severe supraclinoid left ICA vasospasm. (b) Balloon inflation angioplasty of vasospasm segment. (c) Improvement of vasospasm s/p balloon angioplasty of left ICA

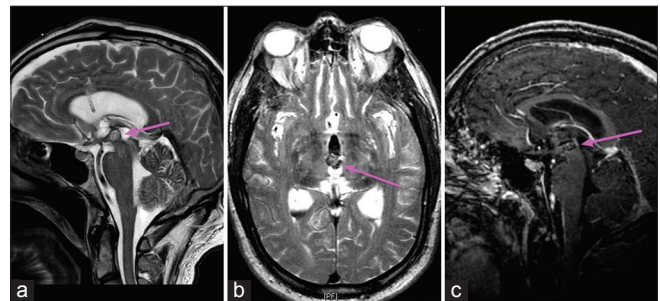


Figure 7: Case #2 MRI showing typical appearance of cavernoma in the 3rd ventricle. [(a) Sagittal T2, (b) Axial T2, (c) Sagittal T1 with contrast]

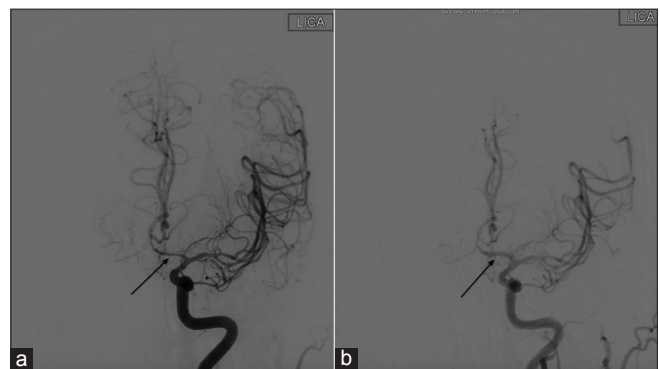

Figure 9: Case #2 (a) Catheter angiography from PBD 22 showing a dominant left A1 segment with vasospasm. (b) Improvement of vasospasm s/p balloon angioplasty of left A1 segment

and inflammatory cytokines to the blood vessels leading to delayed vasospasm. It is important to recognize that symptomatic vasospasm secondary to intraventricular hemorrhage is a rare but devastating complication that can have serious deleterious consequences if remained unrecognized and untreated.

Declaration of patient consent

The authors certify that they have obtained all appropriate patient consent forms. In the form the patient(s) has/have given his/her/their consent for his/her/their images and other clinical information to be reported in the journal. The patients understand that their names

and initials will not be published and due efforts will be made to conceal their identity, but anonymity cannot be guaranteed.

Financial support and sponsorship

Nil.

Conflicts of interest

There are no conflicts of interest.

REFERENCES

1. Dull C, Torbey MT. Cerebral vasospasm associated with intraventricular hemorrhage. *Neurocrit Care* 2005;3:150-2.
2. Gerard E, Frontera JA, Wright CB. Vasospasm and cerebral infarction following isolated intraventricular hemorrhage. *Neurocrit Care* 2007;7:257-9.
3. Kobayashi M, Takayama H, Mihara B, Kawase T. Severe vasospasm caused by repeated intraventricular haemorrhage from small arteriovenous malformation. *Acta Neurochir (Wien)* 2002;144:405-6.
4. Kothbauer K, Schroth G, Seiler RW, Do D-D. Severe symptomatic vasospasm after rupture of an arteriovenous malformation. *Am J Neuroradiol* 1995;16:1073-5.
5. Macdonald RL. Delayed neurological deterioration after subarachnoid haemorrhage. *Nat Rev Neurol* 2014;10:44-58.
6. Park BS, Won YS, Choi CS, Kim BM. Severe symptomatic vasospasm following intraventricular hemorrhage from arteriovenous fistula. *J Korean Neurosurg Soc* 2009;45:300-2.
7. Yanaka K, Hyodo A, Tsuchida Y, Yoshii Y, Nose T. Symptomatic cerebral vasospasm after intraventricular hemorrhage from ruptured arteriovenous malformation. *Surg Neurol* 1992;38:63-7.
8. Yokobori S, Watanabe A, Nakae R, Onda H, Fuse A, Kushimoto S, et al. Cerebral vasospasms after intraventricular hemorrhage from an arteriovenous malformation-case report. *Neurol Med Chir (Tokyo)* 2010;50:320-3.