



Brunner's gland adenomas in two cats

Elizabeth S Hines¹, Paula Roberta Giaretta²,
 João Pedro Cavasin², Molly E Church³,
 Kenneth K Sadanaga⁴ and Brian F Porter¹

Journal of Feline Medicine and Surgery Open Reports
 1–5

© The Author(s) 2024

Article reuse guidelines:

sagepub.com/journals-permissions

DOI: 10.1177/20551169241241208

journals.sagepub.com/home/jfmsopenreports

This paper was handled and processed by the American Editorial Office (AAFP) for publication in *JFMS Open Reports*



Abstract

Case series summary Two cats, aged 13.5 and 14 years, presented with duodenal masses ultimately diagnosed as Brunner's gland (BG) adenomas. In the first cat, the lesion was a firm, pale tan, proximal duodenal polyp adjacent to the major duodenal papilla that was composed histologically of a well demarcated, expansile mass of well-differentiated BGs separated by fibrovascular septa and few adipocytes. This patient was euthanized for otitis-related vestibular signs, and the clinical significance of the duodenal polyp is unknown. The second cat presented with a 6-month history of vomiting. This cat had a mural duodenal mass in the region of the major duodenal papilla of approximately 2 cm, which was histologically composed of a dense population of variably ectatic BGs expanding the submucosa and lamina propria. This patient's mass was non-resectable, but the vomiting resolved after palliative gastroenterostomy loop surgery to allow ingesta to flow past the mass. The patient survived 35 months after the procedure.

Relevance and novel information BG adenoma is a rare, typically benign tumor in humans with non-specific clinical manifestations and no clear etiopathogenesis. This lesion, and the related condition BG hyperplasia, has been documented rarely in animals (one dog, two horses, and in mice and rats). This is the first description of the lesion in the cat. The comparative pathology, differential diagnoses and possible significance of these lesions are discussed.

Keywords: Brunner's gland adenoma; Brunner's gland hyperplasia; polyp; duodenum

Accepted: 5 March 2024

Case series description

Case 1

A 14-year-old castrated male domestic longhair cat was evaluated at the Texas A&M University Small Animal Teaching Hospital for acute onset of hindlimb ataxia, noticed in the morning after the patient woke the owner by vomiting a hairball. The cat had a history of weight loss, unspecified gastrointestinal signs and a lower energy level 2 months prior, at which time the referring veterinarian suspected either gastrointestinal lymphoma or inflammatory enteropathy. Conservative and symptomatic management was provided.

On presentation, the cat was ataxic with pain referable to the T3–L3 region of the spinal cord. A full neurologic examination could not be performed due to the cat's temperament, and he was sent home with instructions for supportive care. Within a few hours at home, the cat's

signs worsened to a severe head turn, dorsal recumbency and the inability to right himself. Clinical differentials included encephalitis, meningitis or a tumor. An MRI

¹Department of Veterinary Pathobiology, Texas A&M University, School of Veterinary Medicine & Biomedical Sciences, College Station, TX, USA

²Department of Small Animal Clinical Sciences, Texas A&M University, School of Veterinary Medicine & Biomedical Sciences, College Station, TX, USA

³Department of Pathobiology, University of Pennsylvania, Ryan Veterinary Hospital, Philadelphia, PA, USA

⁴Veterinary Referral Center (VRC), Malvern, PA, USA

Corresponding author:

Elizabeth S Hines DVM, MPH, MS, Department of Veterinary Pathobiology, Texas A&M University, School of Veterinary Medicine & Biomedical Sciences, College Station, TX 77843-4467, USA
 Email: dvmhines@gmail.com



Creative Commons Non Commercial CC BY-NC: This article is distributed under the terms of the Creative Commons

Attribution-NonCommercial 4.0 License (<https://creativecommons.org/licenses/by-nc/4.0/>) which permits non-commercial use, reproduction and distribution of the work without further permission provided the original work is attributed as specified on the SAGE and Open Access pages (<https://us.sagepub.com/en-us/nam/open-access-at-sage>).

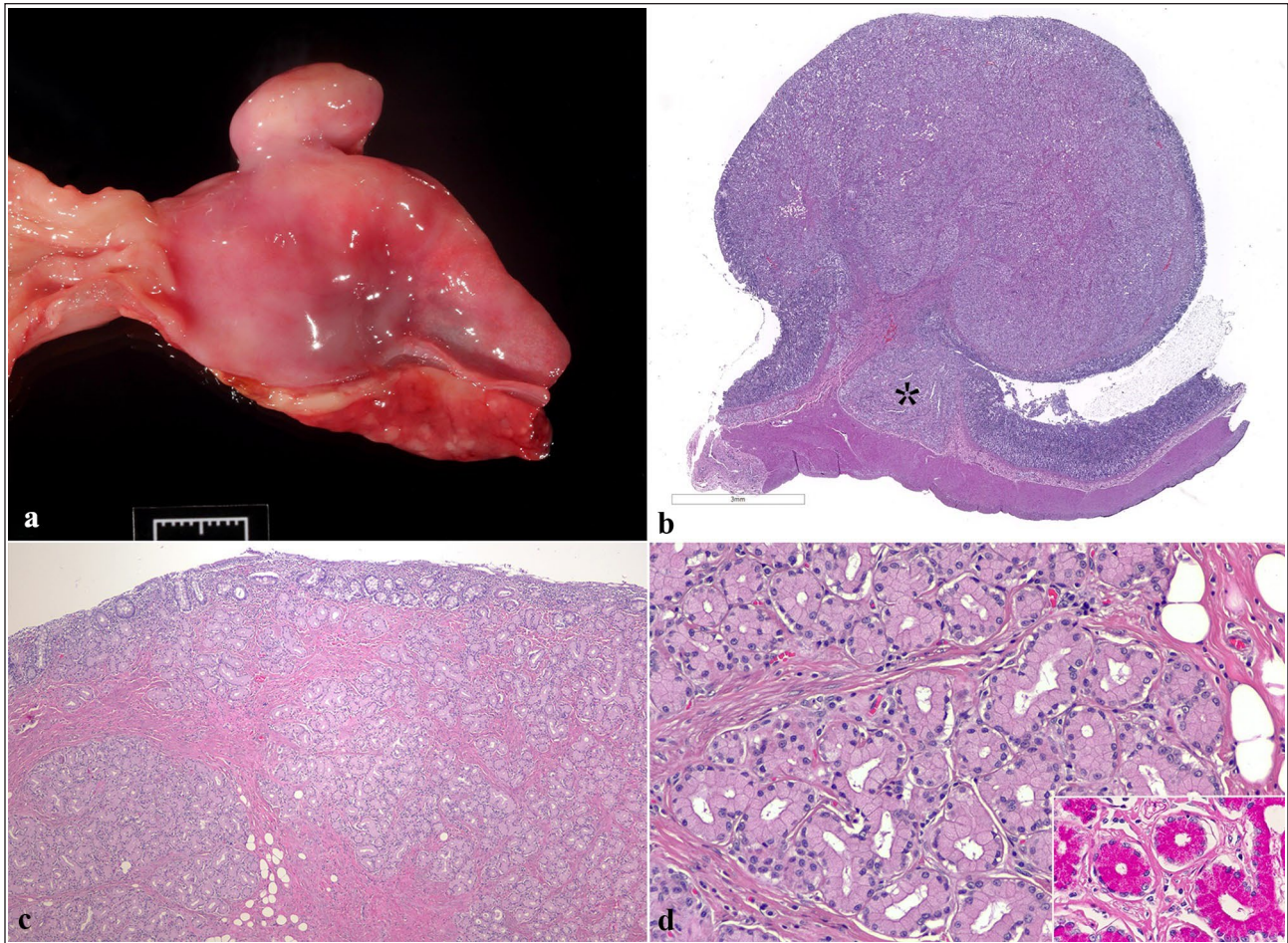


Figure 1 Case 1. (a) An exophytic duodenal mass, $1.8 \times 0.8 \times 1.0$ cm, soft and tan, on a short stalk (a polyp) is centered approximately 1.5 cm aborad to the gastroduodenal junction (the junction is to the left of the image). Scale bar 1 cm; (b) subgross image of the duodenal polyp histologically. Asterisk denotes the major duodenal papilla. Scale bar 3 mm; hematoxylin and eosin (H&E); (c) higher magnification view of the polyp, composed of lobules of well-differentiated Brunner's glands (BGs) separated by bands of fibrous connective tissue and rests of adipocytes. H&E; (d) High magnification view of well-differentiated, mildly ectatic BGs with basilar nuclei and foamy eosinophilic cytoplasm. Atypia is minimal, and no mitoses are seen. H&E. Inset: glands are positive on Periodic acid–Schiff stain

examination was offered but based on the patient's age and concerns over quality of life, the owner opted for humane euthanasia without further diagnostic work-up.

Significant findings on the postmortem examination included abundant, green to yellow, purulent material filling the right tympanic bullae (consistent with otitis media) with evidence of bilateral otitis media and interna on histology; low-grade, small T-cell lymphoma affecting the duodenum and jejunum; pancreatic islet amyloidosis; mild chronic kidney disease; and a polypoid, exophytic duodenal mass on a short stalk approximately 1.5 cm aborad to the gastroduodenal junction (Figure 1). The polyp was $1.8 \times 0.8 \times 1.0$ cm, and was soft, pale tan and occupied approximately 90% of the duodenal lumen.

Histologically, the polyp consisted of lobules of well-differentiated polygonal cells with foamy, Periodic

acid–Schiff positive, eosinophilic cytoplasm and round to flattened basal nuclei. These were arranged in small, occasionally slightly dilated, closely packed tubules containing scant basophilic material (Brunner's glands [BGs]), which expanded the submucosa, elevated the mucosa, infiltrated the lamina propria and minimally compressed the adjacent major duodenal papilla (MDP) (Figure 1). Anisocytosis and anisokaryosis were mild, and no mitotic figures were seen in 2.37 mm^2 . Small clusters of adipocytes, as well as follicular arrangements of lymphocytes and fewer plasma cells, were scattered within the polyp (Figure 1). The luminal aspect of the polyp was ulcerated, with scant amounts of overlying fibrin and cellular debris. The clear histomorphology of the cells, minimal cellular atypia without mitotic figures and the polypoid mass effect all supported a diagnosis of well-differentiated BG adenoma.

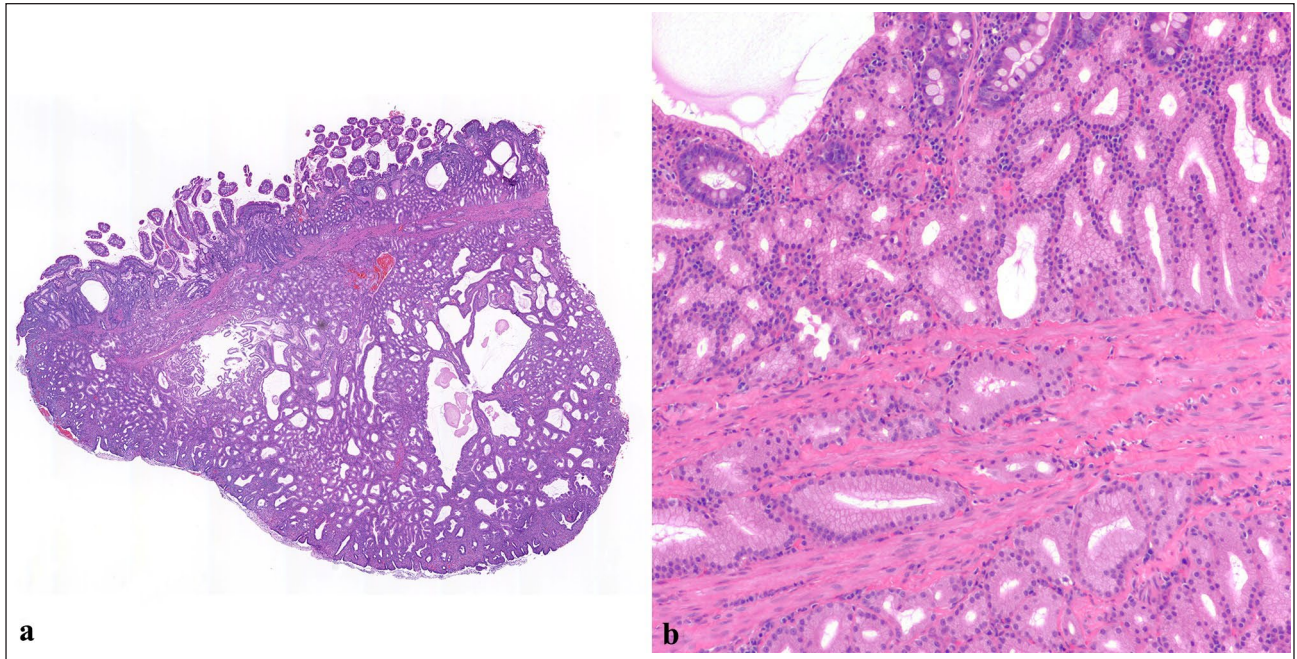


Figure 2 Case 2. (a) Subgross view of the sample showing ectatic Brunner's glands (BGs) forming a nodule in the submucosa, hematoxylin and eosin (H&E); (b) BGs infiltrate the muscularis mucosa and lamina propria, with a variable degree of glandular dilation, H&E

Case 2

A 13.5-year-old spayed female American domestic short-hair cat was evaluated at the Veterinary Referral Center in Malvern (PA) for a mural duodenal mass and right-sided hydronephrosis and hydroureter. The cat had a 6-month history of daily vomiting undigested food with liquid, unspecified 'spinal issues' with a duration of 5–6 years, and colitis and chronic constipation. Conservative and symptomatic management was provided for the vomiting, colitis and constipation. On presentation, the cat was referred to cardiology for assessment of a grade III/VI left and right holosystolic heart murmur, which revealed a small transeptal interventricular septal defect, suspected to be congenital.

On abdominal ultrasound and exploratory celiotomy, the duodenal mass was approximately 1.4 cm in diameter, occupying approximately 80% of the duodenal lumen, and located adjacent and distal to the MDP. Owing to the size and location of the mass, a wedge biopsy was performed rather than full resection. The patient underwent a palliative gastroduodenostomy without resection of the remaining duodenum. The primary aim of the procedure was palliative, to alleviate emesis by allowing ingesta to pass directly from the pylorus to the distal duodenum.

Histologically, the biopsy primarily consisted of numerous variably ectatic BGs, often containing eosinophilic material (Figure 2a). These replaced the submucosa and the muscularis in section (full thickness biopsy unavailable) and extended into the lamina propria

(Figure 2b). A variably dense population of small lymphocytes and plasma cells was within the lamina propria. Based on the mass effect, a diagnosis of BG adenoma was made.

After surgery, the patient's vomiting resolved completely, her appetite improved and the owner reported that the cat seemed more active and subjectively happier. The cat continued to have firm stools every 2–3 days, with continued maintenance therapy for constipation for the remainder of her life. The primary care veterinarian reported that no new clinical signs or complications developed after surgery. The patient did not receive further work-up for her other medical issues. A total of 35 months after surgery, the cat developed severe obstipation, hindlimb weakness and ataxia. Given the cat's age and prognosis, the owners elected humane euthanasia. No postmortem examination was performed, so no information on the progression of the BG adenoma or other comorbidities is available.

Discussion

BGs are tubuloacinar glands in the submucosa of the duodenum, responsible for secreting mucin, bicarbonate and alkaline substances to neutralize gastric acid and chyme as they enter the small intestine.^{1–3} They are most concentrated in the proximal duodenum, decreasing in number throughout the length of the duodenum.

In the human literature, the terminology regarding proliferative lesions of the BGs is better established than in the veterinary literature. BG hyperplasia refers to focal

or multinodular endoscopically visible duodenal nodules histologically characterized by proliferative aggregates of BGs that occupy at least 50% of an endoscopic biopsy.^{1,4} An isolated mass containing proliferative BG is called a BG hamartoma or adenoma (these terms are often used interchangeably),^{1,5} or a Brunneroma.^{6,7} Some authors favor the term hamartoma/adenoma over hyperplasia for lesions with a diameter greater than 5 mm, or for those including interspersed fibrous connective tissue, adipose or lymphoid tissue.^{1,5} The distinction between hamartoma and adenoma in these cases may be academic, as both are benign proliferative lesions.^{1,5}

The literature on proliferative lesions of BGs in veterinary species is limited, with BG hyperplasia being reported in two horses,^{2,8} sand rats (*Psammomys obesus*)⁵ and transgenic mice.⁹ BG adenoma has been reported in one dog and one of the horses with concurrent BG hyperplasia.^{3,8} The term BG hamartoma has not been used in the veterinary literature, and we avoid its usage in the presented cases to minimize nomenclatural confusion.

In the two cases reported in horses, BG hyperplasia has been characterized as a marked increase in BGs, which may create a gross nodule.² Such hyperplasia caused chronic gastric impaction in a 7-year-old Cob crossbreed gelding, which ultimately led to euthanasia.² Diffuse BG hyperplasia (coalescing nodules with a diameter up to 7 mm throughout the duodenum) and BG adenoma (a sessile mass with a diameter of approximately 2 cm) have been associated with recurrent gastric distension and colic in an Arabian mare.⁸

In the sand rat, BG hyperplasia has a high incidence and very similar histomorphology to human BG hyperplasia.⁵ In transgenic mice that overexpress DNA polymerase beta, diffuse BG hyperplasia occurs in female mice more frequently than in male mice.⁹ In rodents, the clinical significance of BG proliferation is not clear, and hyperplasia is likely incidental, except where it may become dysplastic.^{4,9}

In one dog, an 8-year-old, spayed female English Springer Spaniel, a BG adenoma with a diameter of 8 cm was reported.³ The dog presented for refractory vomiting, weight loss and lethargy, which all fully resolved after surgical removal of the adenoma and a similarly sized trichobezoar.³

BG hyperplasia in humans is often asymptomatic and may be considered incidental.^{1,3,8} Hyperplasia is postulated to occur secondary to gastric acid hypersecretion; however, this is a point of debate.^{1,3,5,8} BG hyperplasia is also reported in humans with chronic pancreatitis, chronic renal failure, mucosal injury and *Helicobacter pylori* infection.^{1,3,5,8}

In humans, BG adenomas or hamartomas are rare, making up less than 1% of primary small intestinal tumors, and are typically isolated, pedunculated polyps

with a diameter of 1–2 cm located in the proximal duodenum and decreasing in frequency throughout the middle and distal duodenum.¹ BG adenomas/hamartomas are considered benign and although it has been suggested that they may rarely progress into adenocarcinoma, careful examination of these cases has revealed that the dysplastic epithelium actually involves the surface epithelium with secondary involvement of hyperplastic BGs.^{1,4} Malignant progression of BG adenomas is not documented in veterinary species.

Clinical manifestations of BG hamartomas in humans are non-specific and include abdominal pain, vomiting and gastrointestinal bleeding or obstruction.¹ Rarely, duodenal intussusception and other complications can occur.^{1,7} If the hamartoma blocks or severely compresses the duodenal papilla, extrahepatic biliary and pancreatic duct obstruction can also develop.¹ BG adenomas may have the potential to cause secondary obstructive problems in animals, given the case report from Bowen et al.³ The resolution of emesis in case 2, which followed palliative loop gastroenterostomy to allow ingesta to bypass the BG lesion, further supports this hypothesis. As case 1 had other significant gastrointestinal lesions, the significance of the BG adenoma cannot be determined.

The histopathologic diagnosis of BG proliferative lesions may be difficult on endoscopy, as masses are contained within the submucosa and the size of endoscopic examples may preclude the identification of a mass effect.^{3,6,8} The identification and description of a mass-like lesion is essential for the diagnosis.

In feline pyloroduodenal hyperplastic polyps, a differential for BG adenomas, the polyps arise from the surface epithelium, have a characteristic tubulopapillary arrangement of cells that retain surface mucous cell differentiation, do not invade underlying tissue and may contain abundant inflammatory cells (hyperplastic inflammatory polyps).^{10–12} In gastric adenomas, benign surface epithelial cells lose mucous cell differentiation.¹³

Given that the masses in these cases were adjacent to the MDP, other differentials should include a hyperplastic or adenomatous MDP, choledochal cysts or ampullary neoplasia.^{14,15} Papillitis is more common than neoplasia of the MDP in cats, but previously reported neoplastic lesions arising at or immediately adjacent to the MDP include lymphoma, carcinoid and an unspecified proximal duodenal adenoma adjacent to the MDP.¹⁶ Based on the cases in this report, BG adenoma is another differential for MDP-adjacent masses.

Benign polyps of the duodenum can usually be safely surgically excised in cats.¹⁷ A canine case report suggests that the surgical excision of BG adenomas may be curative;³ however, there are not enough data available to confirm whether this is true. Palliative gastroenterostomy loop, performed in case 2, allowed for

a significant improvement of the clinical signs and prolonged quality of life for a patient that was not a good candidate for complete surgical resection.

Conclusions

To the authors' knowledge, this is the first report of BG adenoma in cats, and only the fourth report of BG adenoma in any domestic veterinary species. While BG adenoma and hyperplasia are uncommon to rare lesions, they are differentials for clinicians and diagnosticians to consider during the assessment of feline duodenal masses. Further investigation of the etiopathogenesis, epidemiology and clinical significance of this entity is needed in veterinary species.

Acknowledgements The authors thank Dr Marie Sahee Min, Dr Justin Heinz and the Texas A&M University Small Animal Teaching Hospital staff for their contributions to the clinical care of case 1.

Conflict of interest The authors declared no potential conflicts of interest with respect to the research, authorship, and/or publication of this article.

Funding The authors received no financial support for the research, authorship, and/or publication of this article.

Ethical approval The work described in this manuscript involved the use of non-experimental (owned or unowned) animals. Established internationally recognized high standards ('best practice') of veterinary clinical care for the individual patient were always followed and/or this work involved the use of cadavers. Ethical approval from a committee was therefore not specifically required for publication in *JFMS Open Reports*. Although not required, where ethical approval was still obtained, it is stated in the manuscript.

Informed consent Informed consent (verbal or written) was obtained from the owner or legal custodian of all animal(s) described in this work (experimental or non-experimental animals, including cadavers) for all procedure(s) undertaken (prospective or retrospective studies). No animals or people are identifiable within this publication, and therefore additional informed consent for publication was not required.

ORCID iD Elizabeth S Hines  <https://orcid.org/0000-0002-1181-2827>

Paula Roberta Giaretta  <https://orcid.org/0000-0003-2261-281X>

References

- Zhu M, Li H, Wu Y, et al. **Brunner's gland hamartoma of the duodenum: a literature review.** *Adv Ther* 2021; 38: 2779–2794.
- Scarlin G, Guerzoni K, Pickles K, et al. **Brunner's gland hyperplasia and recurrent gastric impaction in a horse.** *Vet Rec Case Rep* 2021; 9. DOI: 10.1003/vrc2.56.
- Bowen EJ, Mundy P, Tivers MS, et al. **Duodenal Brunner's gland adenoma causing chronic small intestinal obstruction in a dog.** *J Small Anim Pract* 2012; 53: 136–139.
- Graeme-Cook F. **Polyps of the stomach.** In: Odze R and Goldblum J (eds). *Surgical pathology of the GI tract, liver, biliary tract, and pancreas.* Philadelphia, PA: Elsevier, 2023, pp 666–667.
- Steinbach TJ and Kane JD. **Brunner's gland hyperplasia in the sand rat (*Psammomys obesus*).** *Vet Pathol* 2013; 50: 709–714.
- Varghese S, Dhot P, Bhardwaj T, et al. **Brunneroma – a rare tumour of the duodenum.** *Med J Armed Forces India* 1997; 53: 61–62.
- Patankar AM, Wadhwa AM, Bajaj A, et al. **Brunneroma: a rare cause of duodeno-duodenal intussusception.** *Euroasian J Hepato-gastroenterol* 2016; 6: 84–88.
- Kullmann A, Schott HC, II, Cook VL, et al. **Brunner's gland hyperplasia and adenoma associated with colic in an aged Arabian mare.** *J Vet Intern Med* 2013; 27: 777–781.
- Yoshizawa K, Jelezcova E, Brown AR, et al. **Gastrointestinal hyperplasia with altered expression of DNA polymerase β .** *PLoS One* 2009; 4. DOI: 10.1371/journal.pone.0006493.
- Daure E, Jania R, Jennings S, et al. **Ultrasonographic and clinicopathological features of pyloroduodenal adenomatous polyps in cats.** *J Feline Med Surg* 2017; 19: 141–145.
- Maxie G (ed). *Jubb, Kennedy & Palmer's pathology of domestic animals.* 6th ed. St. Louis, MO: Elsevier, 2015.
- Uneyama M, Chambers JK, Nakashima K, et al. **Feline pyloric and duodenal adenoma: a histological and immunohistochemical study.** *Vet Pathol* 2021; 58: 1025–1032.
- Munday JS, Lohr CV and Kiupel M. **Tumors of the alimentary tract.** In: Meuton DJ (ed). *Tumors of domestic animals.* Ames, IA: Wiley Blackwell, 2017, pp 561–563.
- Haines VL, Brown PR, Hruban RH, et al. **Adenocarcinoma of the hepatopancreatic ampulla in a domestic cat.** *Vet Pathol* 1996; 33: 439–441.
- Schreeg ME, Miller SA and Cullen JM. **Choledochal cyst with secondary cholangitis, choledochitis, duodenal papillitis, and pancreatitis in a young domestic shorthair cat.** *J Vet Diagn Invest* 2021; 33: 782–787.
- Schreeg ME, Cullen JM, Robertson J, et al. **Histologic characterization of the major duodenal papilla and association with concurrent biliary, pancreatic, and intestinal pathology in cats.** *Vet Pathol* 2025; 61: 207–220.
- MacDonald JM, Mullen HS and Moroff SD. **Adenomatous polyps of the duodenum in cats: 18 cases (1985–1990).** *J Am Vet Med Assoc* 1993; 202: 647–651.