



## Case report

## Fatal pulmonary hemorrhage after taking anticoagulation medication



Samuel P. Hammar

Diagnostic Specialties Laboratory, Inc. P.S., 700 Lebo Blvd. Bremerton, WA 98310, USA

## ARTICLE INFO

## Article history:

Received 1 August 2014  
 Received in revised form  
 12 May 2015  
 Accepted 16 May 2015

## Keywords:

Acute lung hemorrhage  
 Anticoagulation therapy  
 Xarelto<sup>®</sup>  
 Rivaroxaban

## ABSTRACT

We describe a 64-year-old man with extensive diffuse acute lung hemorrhage, presumably as a result of anticoagulation therapy. We evaluated reports in the literature concerning acute exacerbation (acute lung injury of unknown cause) in UIP and other forms of fibrotic interstitial pneumonias. We also evaluated autopsy tissue in this case in order to determine the cause of death in this 64-year-old man, who was initially thought to have an asbestos-related disease. Based on the autopsy findings, this man died as a result of anticoagulation therapy; specifically, the use of Xarelto<sup>®</sup> (rivaroxaban).

© 2015 The Author. Published by Elsevier Ltd. This is an open access article under the CC BY-NC-ND license (<http://creativecommons.org/licenses/by-nc-nd/4.0/>).

## 1. Case report

A 64-year-old Caucasian male underwent right total knee replacement on December 4, 2013 and was subsequently prescribed a 21-day supply of the anticoagulation drug Xarelto<sup>®</sup> (rivaroxaban), 10 mg by mouth every day with dinner. Approximately two weeks had elapsed since he stopped taking Xarelto when, on January 13, 2014, the patient was admitted to the hospital with a violent, nonproductive cough and extreme shortness of breath. He denied fever. He had an elevated white blood cell count of 20,400 K/uL. CT scan showed ground-glass opacity and bilateral atypical pneumonia. He was treated with antibiotics (azithromycin 500 mg daily and ceftriaxone 100 mL NS, 1 g q24h). He was started on subcutaneous heparin (enoxaparin 40 mg/0.4 mL) at bedtime between 1/14/14 and 1/26/14 for prevention of deep venous thrombosis (DVT)/pulmonary embolism (PE) for a total of 12 doses.

Other medical problems included pulmonary nodules; prostatic hyperplasia; obstructive sleep apnea; hyperlipidemia; left shoulder rotator cuff repair; and recent knee replacement surgery. He had a prior history of asbestos exposure and there was concern he might have an asbestos-related disease.

A chest radiograph and CT scan showed stable cardiomegaly, a right pneumothorax, diffuse interstitial thickening with patchy airspace opacities, and lack of significant honeycombing. The abnormalities were stated to have significantly progressed since September 2011.

The patient was thought to have community acquired pneumonia on top of pre-existing asbestosis and interstitial lung disease. Video-assisted thoracoscopic lung biopsy was performed on January 21, 2014. Preoperative and post-operative diagnoses were: 1) probable interstitial lung disease; 2) asbestosis; and 3) atrial arrhythmia. Operative findings stated the surface of the right lung was abnormal. Wedge biopsies of the right middle and lower lobes were obtained and pathologic evaluation revealed patchy interstitial fibrosis with chronic inflammation consistent with usual interstitial pneumonia (UIP), with focal organizing pneumonia and progression toward end-stage lung.

A progress note dated January 23, 2014 stated the patient was to remain on ceftriaxone for 14 days; IV steroids for interstitial lung disease; metoprolol for atrial fibrillation; Prevacid for gastrointestinal (GI) prophylaxis; Dilaudid for pain control; enoxaparin (heparin) for DVT prophylaxis; and N-acetyl cysteine (NAC) 600 mg BID.

The patient started coughing up bloody mucus on 1/23/14. His chest tube was removed on post-op day #4 and he was restarted on 20 mg of Xarelto every evening between 1/26/14 and time of discharge on 2/7/14. He was also started on IV Lasix without improvement so his Lasix was increased to 40 mg BID IV. Upon discharge from the hospital, he was switched to oral furosemide (Lasix) 40 mg daily for 30 days.

The patient had a prolonged hospital stay (26 days) and was discharged home to hospice care with a prognosis of two weeks to one year. He had severe dyspnea on minimal exertion. In fact, in the course of one month, he progressed from being ambulatory and independent to being oxygen-dependent and requiring complete care. He continued his prescription of 20 mg of Xarelto at home.

E-mail address: [sam@samhammarmd.com](mailto:sam@samhammarmd.com).

Discharge medications included:

1. Prednisone 30 mg b.i.d.
2. Benzonatate 200 mg every 8 h PRN.
3. Diltiazem 240 mg every day.
4. Furosemide (Lasix) 40 mg daily.
5. Prevacid 30 mg every day.
6. Toprol-XL 25 mg every day.
7. Morphine sublingual 5–10 mg every 2 h PRN with 30 mL dispensed.
8. Ativan 0.5–1 mg every 8 h PRN with #30 dispensed.
9. Rivaroxaban (Xarelto®) 20 mg daily [at home].
10. Metformin, 500 mg twice daily.

Discharge diagnoses were:

1. Idiopathic pulmonary fibrosis, status-post open lung biopsy.
2. Asbestosis [note: this as a clinical diagnosis. While he had a history of asbestos exposure, he did not have radiographic or pathologic asbestosis].
3. Acute-on-chronic hypoxemic respiratory failure.
4. Atrial fibrillation with rapid ventricular response.
5. Steroid-induced hyperglycemia treated with metformin.
6. Lower extremity edema from cor pulmonale and steroids, treated with Lasix.

The patient's condition continued to deteriorate and he expired on February 15, 2014. An autopsy was performed on February 19, 2014.

### 1.1. Autopsy findings

The decedent measured approximately 71" to 72" tall and weighed an estimated 250 pounds. There was mild rigor and livor mortis. Examination of the thorax revealed a scar at approximately the 10th or 11th rib on the right. Ribs and sternum were normal. The mediastinal tissue was normal. No hyaline pleural plaques were identified. The pleural cavities did not contain fluid. The trachea was normal.

The right lung, fixed, weighed 1231.5 g and measured approximately 22 × 16 × 12 cm. The surface of the right lung was hemorrhagic with petechiae and was somewhat nodular. The visceral pleural surface was finely nodular. Upon sectioning, the parenchyma was extremely hemorrhagic. There were a few nodules on the pleural surface. No thrombi or thromboemboli were identified. There were no hyaline pleural plaques on the visceral or parietal pleura, including the surface of the lungs.

The superior vena cava was normal. The heart was in its usual anatomic position and appeared normal. No tumor was identified on the pericardium. There was blood on the parietal pleural surface. There did not appear to be blood in the trachea or bronchi.

The left lung, fixed, weighed 1038 g and measured approximately 22 × 15 × 8 cm. There was nodularity on the visceral pleural surface. The surface of the left lung was hemorrhagic with petechiae. Upon sectioning, the parenchyma was extensively hemorrhagic.

The macroscopic appearance of the lungs is shown in Figs. 1 and 2.

Microscopically, the lungs showed extensive hemorrhage (Fig. 3) with filling of alveolar spaces with fresh blood. There were areas of hyaline membrane formation (Fig. 4) with bright red material lining the alveolar spaces. There was subpleural interstitial fibrosis with some honeycombing, the findings being consistent with usual interstitial pneumonia (Fig. 5). There was mild interstitial fibrosis. There were aggregates of macrophages in alveolar

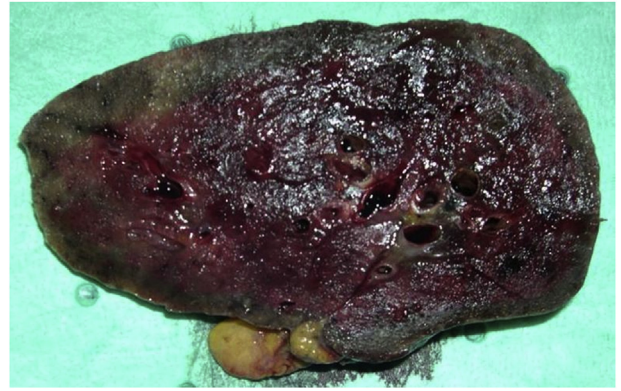

Fig. 1. Macroscopic appearance of lung.

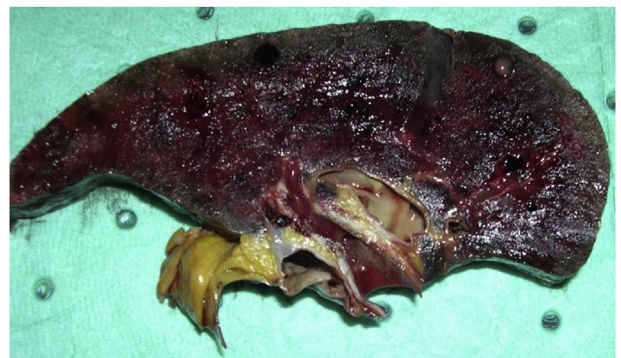

Fig. 2. Macroscopic appearance of lung.

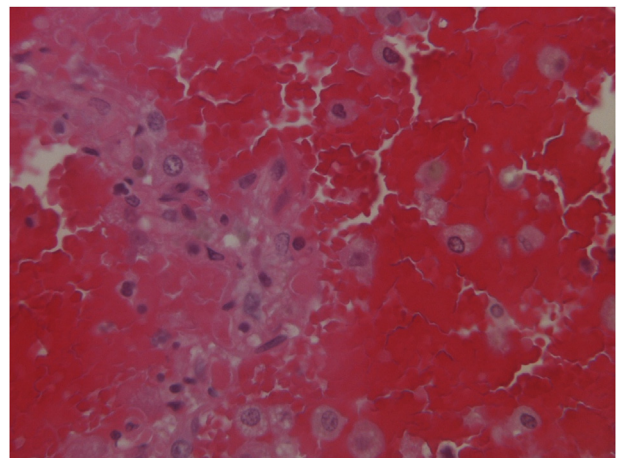


Fig. 3. Extensive intrapulmonary hemorrhage.

spaces. No neoplasm was identified. Trichrome stained sections showed peripheral interstitial fibrosis and blood (Fig. 6). Iron stains showed hemosiderin (Figs. 7 and 8).

## 2. Acute lung injury of unknown cause

We evaluated reports in the literature concerning acute exacerbation (acute lung injury of unknown cause) in UIP and other forms of fibrotic interstitial pneumonias [1–4]. These reports of acute lung injury did not provide any mechanism by which these acute processes developed. In the report by Swigris et al. [2], the

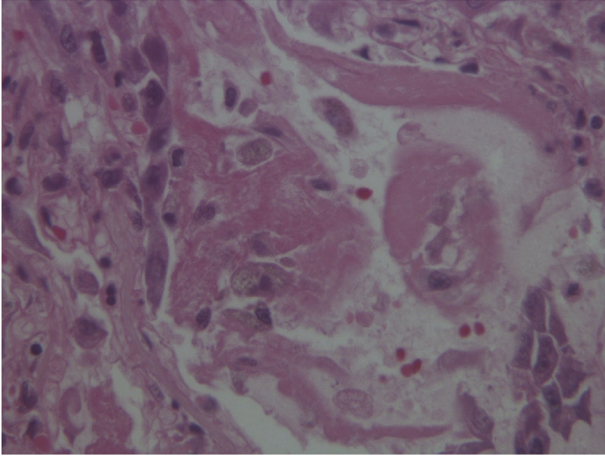
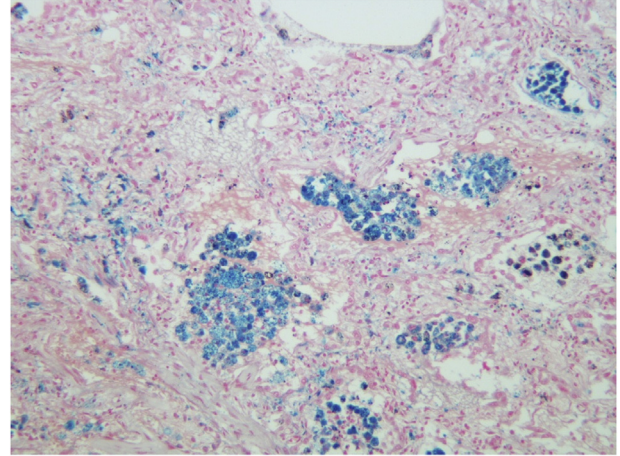


Fig. 4. Hyaline membrane formation.



Iron stain (200x)

Fig. 7. Hemosiderin.

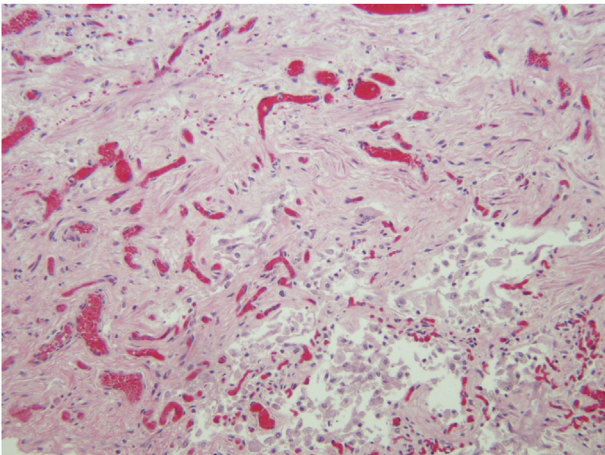
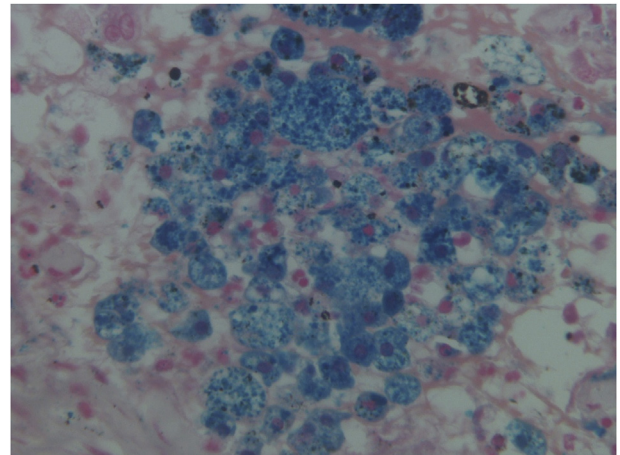
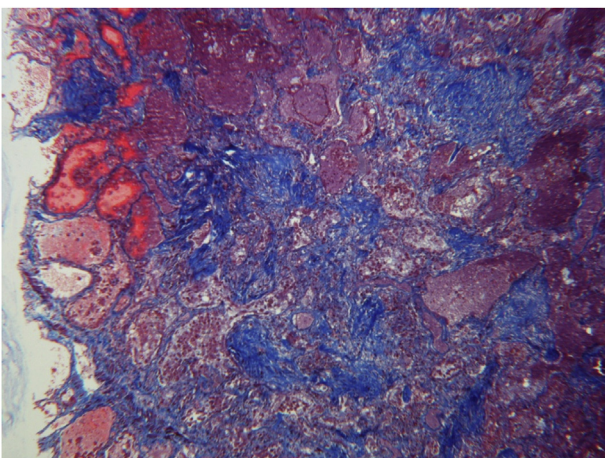


Fig. 5. Usual interstitial pneumonia (UIP).



Iron stain (400x)

Fig. 8. Hemosiderin.



Trichrome stain

Fig. 6. Peripheral interstitial fibrosis and blood.

presentation. Differential diagnosis of AIP included essentially all causes of acute lung injury (e.g., infection, acute inflammatory lung diseases such as acute eosinophilic pneumonia or diffuse alveolar hemorrhage, aspiration, drug-induced lung disease, nonpulmonary disorders leading to a systemic inflammatory response such as pancreatitis or underlying connective tissue disease, heart failure, etc.). The authors stated that, generally, there were no specific clinical clues that helped differentiate AIP from known causes of acute respiratory distress syndrome (ARDS) and that most patients (over 70%) succumbed to the disease within two weeks of diagnosis.

Collard et al. [3] stated the natural history of idiopathic pulmonary fibrosis (IPF) had been characterized as a steady, predictable decline in lung function over time, but that more recent studies suggested that some patients may develop acute deterioration in respiratory status of unknown etiology (termed *acute exacerbations of IPF*). The authors stated the etiology of acute exacerbation of IPF was unknown, although they listed three competing hypotheses for which no consensus could be reached.

Churg et al. [4] published an article in the American Journal of Surgical Pathology in 2007 concerning acute exacerbation in usual interstitial pneumonia (UIP) and other forms of fibrotic interstitial

authors stated that based on nine published series of acute interstitial pneumonia (AIP), approximately two-thirds of patients had symptoms for less than 1 week before diagnosis, while the remaining one-third had symptoms up to 60 days prior to

pneumonias. The authors reported on 12 patients: 9 with underlying UIP, 2 with underlying fibrotic nonspecific interstitial pneumonia, and 1 with underlying chronic hypersensitivity pneumonitis. Ten patients survived the acute episode, however, the two patients who died had histologic diffuse alveolar damage. The authors concluded that acute exacerbation of UIP and other fibrotic lung diseases produces a variety of pathologic patterns on biopsy and patients with organizing pneumonia or extensive fibroblastic foci as the acute pattern seem to do better than those with diffuse alveolar damage (DAD).

### 3. Hemorrhagic events during anticoagulation therapy

Anticoagulation therapy is frequently given as a prophylaxis for deep venous thrombosis (blood clot) following total hip replacement and total knee replacement, although the main complication of anticoagulation therapy is risk of bleeding, even when therapeutic control is achieved. Low-molecular-weight heparin products such as enoxaparin can be administered to reverse the effects of acute bleeding in approximately 60% of cases and is associated with a statistically reduced mortality risk compared with unfractionated heparin [5].

According to a report by Smythe et al. [6] concerning rivaroxaban (Xarelto<sup>®</sup>) and practical considerations for ensuring safety and efficacy, rivaroxaban is one of a new generation of anticoagulants called direct factor Xa inhibitors used in the U.S. for the prevention of stroke and systemic embolism in patients with non-valvular atrial fibrillation and which was also approved by the FDA for use in people who have just undergone hip or knee replacement surgery to reduce the risk of deep vein thrombosis (DVT) and pulmonary embolism (PE). As a result of pharmacokinetics and pharmacodynamics, a fixed dose of rivaroxaban is administered without routine coagulation testing. The authors stated rivaroxaban has a short half-life, undergoes a dual mode of elimination (hepatic and renal), and is a substrate of P-glycoprotein. It has a lower potential for drug interactions compared with warfarin. Injectable (intravenous) and oral anticoagulant agents are widely used for the prevention and treatment of venous and arterial thrombosis, which is associated with significant morbidity and mortality.

After a 5 mg dose of rivaroxaban, there is 22% maximum FXa inhibition, which increases to 68% after a 30-mg dose. Maximum inhibition occurs 1–4 h after dosing. There has been an increasing desire to measure rivaroxaban's anticoagulant effect reliably, however, current limitations include the lack of routinely available standardized, validated assays with established target ranges as well as the lack of an established relationship of laboratory parameters to clinically important outcomes. The authors [6] reported the potential scenarios for measuring a prothrombin time (PT) in rivaroxaban patients. For example, in cases of suspected over-anticoagulation, a linear relationship exists between increasing rivaroxaban concentration and increasing prothrombin time (PT). Excessive prolongation may signal over-anticoagulation. As a result, one must combine interpretation of prothrombin time results with clinical assessment. Also, after administration of blood products and/or clotting factors in cases of over-anticoagulation, reversal of PT may not correlate with cessation of bleeding. Therefore, continued prolongation or rebound may require repeated administration of blood products and/or concentrated clotting factor. The authors noted that it is unclear if the normalization of the PT indicates reversal of drug effect when using a concentrated clotting factor product.

Rivaroxaban and other anticoagulants require special care when managing use around invasive procedures. Recommendations for the time period to withhold the drug prior to an invasive procedure

varied from 2 to 6 days. Because of this, individualized assessment of the thrombosis versus bleeding risk is necessary. The combination of rivaroxaban and other anticoagulants, antiplatelet drugs, or fibrinolytics increase the risk of hemorrhage. Because many hospitals and health systems are unfamiliar with rivaroxaban and its pharmacologic profile, unintentional combination therapy can occur. Concurrent use of rivaroxaban with warfarin, dabigatran, apixaban, heparin, low-molecular weight heparin (enoxaparin, dalteparin, tinzaparin), fondaparinux, and intravenous direct thrombin inhibitors (DTIs) such as argatroban, bivalirudin, lepirudin, and desirudin should be avoided with the exception of short-term overlap during transition from one anticoagulant to another. It was noted that healthcare providers should avoid concurrent antiplatelet therapy when there is no compelling indication, keeping the current aspirin dose under 100 mg/day when needed and using warfarin instead of rivaroxaban when triple antithrombotic therapy is needed.

The authors [6] listed potential drug interactions with rivaroxaban in Table 7 on page 1235 of their report. The authors stated that because of rivaroxaban's balanced renal and hepatic elimination, current U.S. rivaroxaban labeling indicates that the only clinically significant drug interactions identified to date are those involving combined use of a strong CYP3A4 inhibitor with a P-glycoprotein inhibitor or combined use of a strong CYP3A inducer with a P-glycoprotein inducer.

Another important and challenging factor in managing rivaroxaban is to ensure that the dose is correct for the patient's indication and comorbidities. There are two different doses approved for non-valvular atrial fibrillation (NVAF) based on the patient's renal function; two different doses approved for venous thromboembolism (VTE) based on timing from the event; and a much lower dose studied for acute coronary syndrome (ACS). Each of these doses is different from orthopedic VTE prophylaxis dose. In addition, the creatinine clearance at which dose reduction is required varies by indication. The authors [6] stated certain challenges will arise when a patient on rivaroxaban for one indication develops another condition for which rivaroxaban is indicated but at a different dose regimen. Clinicians are cautioned against using 15 or 20-mg/day dose for NVAF or VTE treatment, or as a secondary prophylaxis immediately following elective orthopedic or other procedures with a high bleeding risk. The authors [6] urge health systems to develop a system that identifies who prescribes the initial 15-mg twice/day dose for 21 days versus who prescribes the 20 mg/day long-term dose and how this transition in care happens safely and effectively. A person's body weight and dosage is also a factor as shown in Table 8 on page 1238 of the article.

While evaluating our case, we did an extensive MedLine search to see if there might be any other conditions that would account for this patient's pulmonary hemorrhage. Death as a result of Xarelto<sup>®</sup> as well as related generic and/or brand-name drugs containing the same primary active ingredients reported to the FDA between the 1st quarter of 2004 and the 3rd quarter of 2012 was 101 (1.03%); note: this percentage was stated to represent the percentage of deaths to all adverse events reported and not to drug utilization.

According to the website *Institute for Safe Medication Practices* [7], warfarin (Coumadin) and newcomers dabigatran (Pradaxa) and rivaroxaban (Xarelto) counted for 1734 reports to the FDA in the 2nd quarter of 2012, including 233 patient deaths, reinforcing the conclusion that anticoagulants rank among the highest risk of all outpatient drug treatments. In fact, excessive bleeding as a result of dabigatran (Pradaxa) was about 5x more likely than warfarin to result in death (19% versus 4%, adjusted OR 5.2; 95% CI 3.4–8.0). As for rivaroxaban, an additional quarter of data confirmed an earlier finding that blood clot-related events were reported more frequently in patients receiving the 10 mg/daily dose after hip or

knee replacement surgery compared to the 20 mg regimen for patients with non-valvular atrial fibrillation, which raised the concern whether the 10 mg dose was suboptimal. Embolic-thrombotic events such as pulmonary embolism (PE) and deep vein thrombosis (DVT) were much more likely to be reported in lower dose patients after surgery compared to atrial fibrillation patients with twice the recommended daily dose (56% vs. 17%, adjusted OR 7.0; 95% CI 3.9–12.6). Of the three anticoagulants, only rivaroxaban had a 50% lower recommended dose for hip/knee surgery compared to its other indications.

The German newspaper *Der Spiegel* stated that at least 968 adverse events involving Xarelto were reported to German health officials in the first eight months of 2013, including 72 deaths. The numbers compare to 750 adverse events and 58 deaths throughout all of the previous year, indicating that the increase tracked with the rise in use of Xarelto, which had reportedly increased 240% after just 1 1/2 years on the market. There have also been concerns about the use of Pradaxa, which began shortly after the medication was introduced in October 2010. Pradaxa quickly became one of the medications most commonly associated with adverse events reported to the FDA. The FDA received at least 3781 reports involving serious injuries associated with the use of Pradaxa during 2011, including 2367 reports of hemorrhage and 542 deaths.

#### 4. Conclusion

With respect to our case, there was no indication that our patient's condition and subsequent demise were related to acute exacerbation of IPF. While the intent of the physician(s) in our case was to prevent post-operative blood clots by giving anticoagulation medication, the opposite occurred; the patient was actually hemorrhaging into his lungs as confirmed by postmortem evaluation of lung tissue, which showed extensive acute lung injury/hemorrhage as a result of anticoagulation therapy.

While rivaroxaban (Xarelto<sup>®</sup>), which has been marketed as a replacement for warfarin (Coumadin), like all blood thinners, carries a risk of bleeding, direct thrombin inhibitors and factor Xa inhibitors such as rivaroxaban currently lack an effective reversal agent such as vitamin K and plasma to reverse bleeding problems,

making it more difficult to prevent serious injury or death in patients taking rivaroxaban (Xarelto<sup>®</sup>).

Because of the potential serious and sometimes fatal side-effects associated with the use of rivaroxaban and other similar drugs, patients, family members, caregivers, and physicians should be educated so they recognize the signs of bleeding (e.g., frequent or prolonged bleeding from minor wounds such as from cuts while shaving; bleeding around the gums and mucous membranes such as during tooth brushing and nose blowing; heavy menstrual bleeding; urine or stool discoloration; and easy bruising or hematomas from daily activities such as carrying grocery bags or laundry baskets) and seek urgent medical attention should such bleeding occur.

#### Conflict of interest

Dr. Samuel P. Hammar has served as an expert in civil litigation cases, predominantly for the plaintiff, as a result of claims of injury from asbestos and tobacco.

#### References

- [1] V. Ambrosini, A. Cancellieri, M. Chilosi, M. Zompatori, R. Trisolini, L. Saragoni, V. Poletti, Acute exacerbation of idiopathic pulmonary fibrosis: report of a series, *Eur. Respir. J.* 22 (2003) 821–826.
- [2] J.J. Swigris, K.K. Brown, Acute interstitial pneumonia and acute exacerbations of idiopathic pulmonary fibrosis, *Semin. Respir. Crit. Care Med.* 27 (2006) 659–667.
- [3] H.R. Collard, B.B. Moore, K.R. Flaherty, K.K. Brown, R.J. Kaner, T.E. King, et al., Acute exacerbations of idiopathic pulmonary fibrosis, *Am. J. Respir. Crit. Care Med.* 176 (2007) 636–643.
- [4] A. Churg, M.L. Müller, I.S. Silva, J.L. Wright, Acute exacerbation (acute lung injury of unknown cause) in UIP and other forms of fibrotic interstitial pneumonias, *Am. J. Surg. Pathol.* 31 (2007) 277–284.
- [5] R. Nathwani, A complicated case of anticoagulation, *BMJ Case Reports Publ. Online* (9 Jan 2013), <http://dx.doi.org/10.1136/bcr-2012-007672:1-2>.
- [6] M.A. Smythe, J. Fanikos, M.P. Gulseth, A.K. Wittkowsky, S.A. Spinler, W.E. Dager, E.A. Nutescu, Rivaroxaban: practical considerations for ensuring safety and efficacy, *Pharmacotherapy* 33 (2013) 1223–1245, <http://dx.doi.org/10.1002/phar.1289>.
- [7] Institute for Safe Medication Practices. Updates on anticoagulants dabigatran (Pradaxa) and rivaroxaban (Xarelto). [www.ismp.org/quarterwatch/pdfs/2012Q2](http://www.ismp.org/quarterwatch/pdfs/2012Q2).