

Case Report

Spontaneous obliteration highlights the dynamic nature of cerebral arteriovenous malformations: A case report and review of the literature

Su Lone Lim, Aaron Song Chuan Foo, Bengt Karlsson, Tseng Tsai Yeo

Department of Surgery, Division of Neurosurgery, National University Hospital, 5 Lower Kent Ridge Road, 119074 Singapore

E-mail: Su Lone Lim - limsulone@gmail.com; *Aaron Song Chuan Foo - aaronfoosongchuan@hotmail.com; Bengt Karlsson - nykuttram@yahoo.se; Tseng Tsai Yeo - drttyeo@yahoo.com

*Corresponding author

Received: 16 September 15 Accepted: 07 February 16 Published: 20 April 16

Abstract

Background: Cerebral arteriovenous malformations (AVMs) are dynamic lesions and have been documented to arise *de novo*, enlarge, regress, obliterate, and even recur. Spontaneous obliteration of AVM is a rare and poorly understood phenomenon.

Case Description: We present a case of spontaneous obliteration of AVM in a 60-year-old gentleman who presented with intraparenchymal hemorrhage from a ruptured right parieto-occipital AVM. Angiography performed before gamma knife surgery 4 months after his initial presentation demonstrated complete absence of AVM.

Conclusion: In our center's 20-year experience of treatment of cerebral AVMs (approximately 600 cases), this is the only case that has been aborted due to spontaneous obliteration leading us to infer that the incidence of spontaneous AVM obliteration is <1%. Spontaneous obliteration of AVM is a rare but well-established phenomenon that bears testimony to the dynamics of this vascular disorder.

Key Words: Cerebral arteriovenous malformation, dynamic lesion, spontaneous obliteration

Access this article online

Website:www.surgicalneurologyint.com**DOI:**

10.4103/2152-7806.180766

Quick Response Code:

INTRODUCTION

Gamma knife surgery is a well-established treatment modality for small and medium-sized cerebral arteriovenous malformations (AVMs). It has been used in Singapore since 1995, and around 600 AVMs have been treated. The following is the first case in our experience in which the AVM could not be visualized on stereotactic digital subtraction angiography in a patient scheduled for gamma knife surgery. This prompted us to explore the dynamics behind spontaneous obliteration of AVMs.

CASE REPORT

The patient is a 60-year-old gentleman who presented with acute intracerebral hemorrhage in the right

parieto-occipital region [Figure 1]. Computer tomography angiography revealed an AVM in the right parietal lobe with a feeding vessel originating from the right posterior cerebral artery and a cortical draining vein leading into the superior sagittal sinus [Figure 2].

This is an open access article distributed under the terms of the Creative Commons Attribution-NonCommercial-ShareAlike 3.0 License, which allows others to remix, tweak, and build upon the work non-commercially, as long as the author is credited and the new creations are licensed under the identical terms.

For reprints contact: reprints@medknow.com

How to cite this article: Lim SL, Foo AS, Karlsson B, Yeo TT. Spontaneous obliteration highlights the dynamic nature of cerebral arteriovenous malformations: A case report and review of the literature. *Surg Neurol Int* 2016;7:45. <http://surgicalneurologyint.com/Spontaneous-obliteration-highlights-the-dynamic-nature-of-cerebral-arteriovenous-malformations-A-case-report-and-review-of-the-literature/>

Digital subtraction angiography performed 5 days after the initial hemorrhage revealed a 1.0 cm nidus of abnormal vessels, which was supplied by a single feeder from the right posterior cerebral artery and drained by a single vein into the superior sagittal sinus, confirming the presence of an AVM [Figure 3]. Digital subtraction angiography also confirmed fetal origins for both posterior cerebral arteries. The AVM was classified as a Spetzler-Martin Grade 2 AVM (size smaller than 3 cm, located in an eloquent region of the brain with superficial venous drainage).

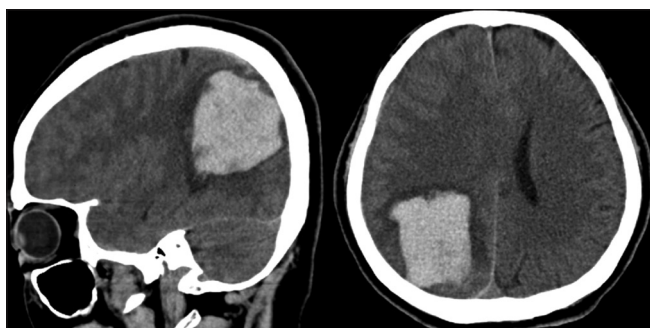


Figure 1: Computer tomography scan showing acute intracerebral hemorrhage in the right parieto-occipital region

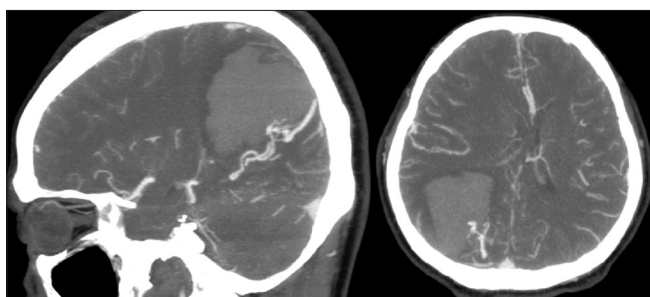


Figure 2: Computer tomography angiography showing arteriovenous malformation in right parieto-occipital region

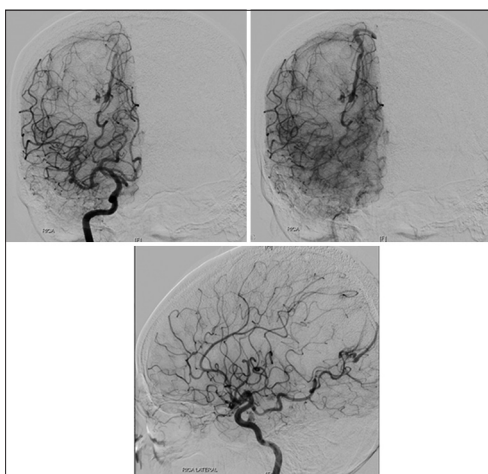


Figure 3: Digital subtraction angiography showing arteriovenous malformation in right parieto-occipital region with single feeding artery from right posterior cerebral artery and single draining vein into the superior sagittal sinus

The patient's intracerebral hemorrhage was managed conservatively and he was discharged with minor deficit (left inferior quadrantanopia). He opted to treat his AVM with gamma knife surgery which was scheduled 4 months after his initial presentation. However, the stereotactic digital subtraction angiography performed just before gamma knife surgery planning demonstrated absence of the AVM nidus and resolution of the network of abnormal draining vessels [Figure 4]. Gamma knife surgery was aborted and the patient discharged. His visual deficit remains stable and he is well otherwise 18 months posthemorrhage.

DISCUSSION

The classic belief that all AVMs are congenital lesions arising from vascular dysgenesis during early fetal development has been challenged.^[17] Recent evidence showing that they may develop later in life has been published.^[9] Interval enlargement,^[16] self-remodeling,^[16] and spontaneous obliteration^[1,3,12,19,21] of these lesions in children and adults bear testimony to their dynamic nature and suggest that a complex interplay of both mechanical and genetic factors influence the natural history of these vascular malformations.

Spontaneous obliteration is defined as the disappearance of an AVM in the absence of any intervention or therapy.^[3] Spontaneous obliteration of an AVM is a rare but well-recognized phenomenon with a suggested prevalence of 0.3–1.3%.^[1,3,12,19,21] In our center's 20-year experience of treatment of cerebral AVMs (approximately 600 cases), this is the only case that has been aborted due to spontaneous obliteration leading us to infer that the incidence of spontaneous AVM obliteration is <1%.

Current hypotheses for spontaneous AVM obliteration are centered on the interruption of arterial feeders and venous outflow occlusion. Compressive effects of mass lesions, such as intracerebral hematomas due to AVM rupture,^[8,18,20,22,26,27] postsurgical brain swelling,^[14] and posthemorrhage gliosis,^[10] have been associated with spontaneous obliteration of AVM. Other events linked with spontaneous obliteration of AVM include premature atherosclerosis,^[2,11,14,23] embolic phenomenon causing occlusion of feeders,^[11,25] turbulence of flow within feeders causing endothelial shearing and thrombus formation,^[7] hypercoagulable states,^[24] and genetic disturbances in angiogenesis pathways, such as in cases associated with hereditary hemorrhagic telangiectasia.^[5,6,13] Spontaneous AVM obliteration is also associated with certain angiographic features, including a small nidus, single feeding artery, and solo draining vein.^[14,21] As the proposed mechanisms of spontaneous obliteration are centered on intercepting AVM blood flow, AVMs with single entry and exit channels may thus be

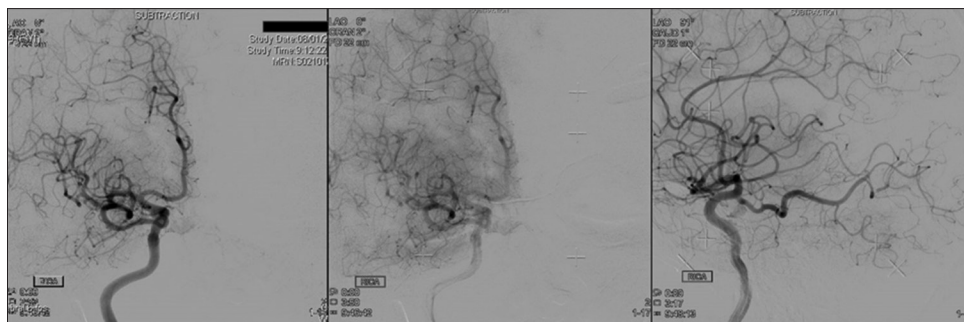


Figure 4: Digital subtraction angiography performed just before gamma knife surgery planning showing complete absence of the arteriovenous malformation

the easiest to occlude. Furthermore, there are reports of AVM recurrence after spontaneous obliteration.^[1,4,15,18,21]

CONCLUSION

Spontaneous obliteration of AVM is a rare but well-established phenomenon that bears testimony to the dynamics of this vascular disorder.

Financial support and sponsorship

Nil.

Conflicts of interest

There are no conflicts of interest.

REFERENCES

- Abdulrauf SI, Malik GM, Awad IA. Spontaneous angiographic obliteration of cerebral arteriovenous malformations. *Neurosurgery* 1999;44:280-7.
- Bogren H, Svalander C, Wickbom I. Angiography in intracranial cavernous hemangiomas. *Acta Radiol Diagn (Stockh)* 1970;10:81-9.
- Buis DR, van den Berg R, Lycklama G, van der Worp HB, Dirven CM, Vandertop WP. Spontaneous regression of brain arteriovenous malformations – A clinical study and a systematic review of the literature. *J Neurol* 2004;251:1375-82.
- Castaigne P, Buge A, Pertuiset B, Laplane D, Corbin J. Radiologically excluded, thrombosed angioma. *Bull Mem Soc Med Hop Paris* 1961;77:923-30.
- Cloft HJ. Spontaneous regression of cerebral arteriovenous malformation in hereditary hemorrhagic telangiectasia. *AJNR Am J Neuroradiol* 2002;23:1049-50.
- Du R, Hashimoto T, Tihan T, Young WL, Perry V, Lawton MT. Growth and regression of arteriovenous malformations in a patient with hereditary hemorrhagic telangiectasia. Case report. *J Neurosurg* 2007;106:470-7.
- Dyck P. Spontaneous thrombosis of an arteriovenous malformation. *Neurosurgery* 1977;1:287-90.
- Eisenman JI, Alekoubides A, Pribram H. Spontaneous thrombosis of vascular malformations of the brain. *Acta Radiol Diagn (Stockh)* 1972;13:77-85.
- Gonzalez LF, Bristol RE, Porter RW, Spetzler RF. De novo presentation of an arteriovenous malformation. Case report and review of the literature. *J Neurosurg* 2005;102:726-9.
- Krapf H, Siekmann R, Freudenstein D, Küker W, Skalej M. Spontaneous occlusion of a cerebral arteriovenous malformation: Angiography and MR imaging follow-up and review of the literature. *AJNR Am J Neuroradiol* 2001;22:1556-60.
- Kushner J, Alexander E Jr. Partial spontaneous regressive arteriovenous malformation; case report with angiographic evidence. *J Neurosurg* 1970;32:360-6.
- Lee SK, Vilela P, Willinsky R, TerBrugge KG. Spontaneous regression of cerebral arteriovenous malformations: Clinical and angiographic analysis with review of the literature. *Neuroradiology* 2002;44:11-6.
- Leung KM, Agid R, terBrugge K. Spontaneous regression of a cerebral arteriovenous malformation in a child with hereditary hemorrhagic telangiectasia. Case report. *J Neurosurg* 2006;105 5 Suppl: 428-31.
- Minakawa T, Tanaka R, Koike T, Takeuchi S, Sasaki O. Angiographic follow-up study of cerebral arteriovenous malformations with reference to their enlargement and regression. *Neurosurgery* 1989;24:68-74.
- Mizutani T, Tanaka H, Aruga T. Total recanalization of a spontaneously thrombosed arteriovenous malformation. Case report. *J Neurosurg* 1995;82:506-8.
- Moftakhar P, Hauptman JS, Malkasian D, Martin NA. Cerebral arteriovenous malformations. Part 2: Physiology. *Neurosurg Focus* 2009;26:E11.
- Mullan S, Mojtahedi S, Johnson DL, Macdonald RL. Embryological basis of some aspects of cerebral vascular fistulas and malformations. *J Neurosurg* 1996;85:1-8.
- Nukui H, Miyagi O, Tamada J, Mitsuka S, Kawafuchi J. Long-term follow-up study by cerebral angiography in cases with arteriovenous malformation of the brain. With special reference to spontaneous disappearance of arteriovenous malformation in cerebral angiography (author's transl). *Neurol Med Chir (Tokyo)* 1982;22:125-32.
- Panciani PP, Fontanella M, Carlino C, Bergui M, Ducati A. Progressive spontaneous occlusion of a cerebellar AVM: Pathogenetic hypothesis and review of literature. *Clin Neurol Neurosurg* 2008;110:502-10.
- Pasqualin A, Vivenza C, Rosta L, Scienza R, Da Pian R, Colangeli M. Spontaneous disappearance of intracranial arterio-venous malformations. *Acta Neurochir (Wien)* 1985;76:50-7.
- Patel MC, Hodgson TJ, Kemeny AA, Forster DM. Spontaneous obliteration of pial arteriovenous malformations: A review of 27 cases. *AJNR Am J Neuroradiol* 2001;22:531-6.
- Sartor K. Spontaneous closure of cerebral arteriovenous malformation demonstrated by angiography and computed tomography. *Neuroradiology* 1978;15:95-8.
- Sasaki U, Itagaki T, Shimizu H, Takahashi M. Almost complete regression of cerebral arteriovenous malformation – Report of a case (author's transl). *No Shinkei Geka* 1976;4:175-81.
- Shuey HM Jr., Day AL, Quisling RG, Sybert GW. Angiographically cryptic cerebrovascular malformations. *Neurosurgery* 1979;5:476-9.
- Sukoff MH, Barth B, Moran T. Spontaneous occlusion of a massive arteriovenous malformation – Case report. *Neuroradiology* 1972;4:121-3.
- Takano S, Nose T, Maki Y, Shinohara A, Kukita C. Spontaneous occlusion of a cerebral arteriovenous malformation – Report of a case. *No Shinkei Geka* 1987;15:991-6.
- Wakai S, Chen CH, Wu KY, Chiu CW. Spontaneous regression of a cerebral arteriovenous malformation. Report of a case and review of the literature. *Arch Neurol* 1983;40:377-80.