



Histopathological evaluation of the adrenal glands in a cat with primary hypoadrenocorticism and multiple endocrine disease

Journal of Feline Medicine and Surgery Open Reports
1–5

© The Author(s) 2022

Article reuse guidelines:

sagepub.com/journals-permissions

DOI: 10.1177/20551169221125207

journals.sagepub.com/home/jfmsopenreports

This paper was handled and processed

by the European Editorial Office (ISFM)

for publication in *JFMS Open Reports*



Emma Roberts¹ and Melanie J Dobromylskyj²

Abstract

Case summary A 6-year-old male neutered domestic longhair cat was referred for investigation of weight loss, hyporexia, vomiting and diarrhoea. The cat was diagnosed with primary hypoadrenocorticism, exocrine pancreatic insufficiency, cobalamin deficiency and a chronic enteropathy, and started on therapeutic treatment. Diabetes mellitus developed 4.5 months later, and the cat was started on insulin therapy. The cat was euthanased 10 months following the diagnosis of hypoadrenocorticism due to the development of status epilepticus, which was not associated with glucose or electrolyte abnormalities. Histopathological assessment of the adrenal glands at post-mortem examination documented lymphoplasmacytic adrenalitis, with the lymphocytic population being predominant. Immunohistochemical staining classified the lymphocytic infiltrate as T-cell rich, supportive of the cat's hypoadrenocorticism being due to autoimmune disease.

Relevance and novel information This case documents the novel use of immunohistochemical staining in combination with histopathology to further assess the adrenal glands in non-neoplastic-associated primary hypoadrenocorticism in a cat. This identified similar pathological changes to those previously described in dogs with autoimmune primary hypoadrenocorticism. Additionally, this is the first report of a cat with multiple endocrine disease that included primary hypoadrenocorticism and highlights that monitoring for the development of additional endocrine disease should be advised in these cases.

Keywords: Hypoadrenocorticism; polyendocrinopathy; immunohistochemistry; adrenal gland

Accepted: 24 August 2022

Introduction

Canine primary hypoadrenocorticism (PH) predominantly occurs as a result of autoimmune lymphoplasmacytic adrenalitis, in which there is a T-cell-rich lymphocyte population.^{1–3} The same pathogenesis is suspected to occur in cats; however, adrenal histopathology in non-neoplastic-associated PH has not yet confirmed this.^{4,5}

In dogs, PH can occur with other endocrinopathies; a concurrent endocrinopathy in feline PH has yet to be reported.^{6–10}

We document a case of feline non-neoplastic-associated PH that developed diabetes mellitus (DM), and additionally report the adrenal histopathological findings including immunohistochemistry (IHC) staining.

Case description

A male neutered domestic longhair cat aged 6 years and 1 month was presented to the primary care practice for investigation of weight loss, and a 1-month history of polyphagia progressing to hyporexia, intermittent vomiting and mixed bowel diarrhoea; fenbendazole (Panacur;

¹Highcroft Veterinary Referrals, Bristol, UK

²Finn Pathologists, Harleston, UK

Corresponding author:

Emma Roberts BVetMed (Hons), MVM, DipECVIM-CA, Highcroft Veterinary Referrals, 615 Wells Road, Bristol BS14 9BE, UK
Email: emma.roberts@cvsrvets.com



Creative Commons Non Commercial CC BY-NC: This article is distributed under the terms of the Creative Commons

Attribution-NonCommercial 4.0 License (<https://creativecommons.org/licenses/by-nc/4.0/>) which permits non-commercial use, reproduction and distribution of the work without further permission provided the original work is attributed as specified on the SAGE and Open Access pages (<https://us.sagepub.com/en-us/nam/open-access-at-sage>).

MSD Animal Health) treatment had not led to a positive response. Faecal analysis, haematology, biochemistry, cobalamin, folate and thyroxine assessment were performed. These demonstrated a pancytopenia with a non-regenerative anaemia (haematocrit 23%; reference interval [RI] 27–55), thrombocytopenia ($57 \times 10^9/l$; RI 200–600) and neutropenia ($1.9 \times 10^9/l$; RI 2.5–12.5), increased aspartate transaminase (122 U/l; RI 0–69) and alanine transaminase (ALT; 477 U/l [RI 18–77]), and cobalamin deficiency ($<111 \text{ pmol/l}$; RI 220–500). The cat was up to date on vaccinations and had outdoor access.

On referral presentation, pertinent findings included mild sinus tachycardia at 180 beats per minute (bpm), small intestinal tract thickening on abdominal palpation and hypothermia (rectal temperature 37.2°C). The cat weighed 3.95 kg and had muscle and body condition scores of 1/3 and 2/9, respectively.

Haematological assessment documented resolution of the pancytopenia detected 9 days previously; a laboratory error was thought to be the most likely cause of the previous haematological changes, but fenbendazole toxicity could not be excluded.^{11,12} Biochemistry documented hypoalbuminaemia (25.3 g/l; RI 26–42), hypochloraemia (106 mmol/l; RI 111–129), hyperphosphataemia (2.54 mmol/l; RI 0.7–2.1), azotaemia (urea 15.8 mmol/l [RI 6.1–12.5] and creatinine 183 $\mu\text{mol/l}$ [RI 45–170]), and an improvement in ALT (132 U/l; RI 18–77); sodium and potassium were normal. *Toxoplasma* species serology was negative. Feline trypsin-like immunoreactivity was consistent with exocrine pancreatic insufficiency (EPI; $<1 \mu\text{g/l}$ [RI 12–82]). Basal cortisol was undetectably low ($<37.3 \text{ nmol/l}$; RI <200). Feline leukaemia/immunodeficiency virus testing (FeLV/FIV SNAP; IDEXX UK) was negative. Urinalysis documented a specific gravity of 1.029. Abdominal ultrasonography detected mild gallbladder wall thickening, normal-sized adrenal glands with a mildly hypoechoic medulla, a small-sized pancreas with reduced parenchymal volume and diffuse small intestinal thickening, with the muscularis predominantly affected. Bile culture was negative.

An adrenocorticotrophic hormone (ACTH) stimulation test was consistent with hypocortisolism (pre- and post-ACTH values $<37.3 \text{ nmol/l}$); serum aldosterone testing confirmed hypoaldosteronism ($<20 \text{ pmol/l}$; RI 87–224). Endogenous ACTH (eACTH; $>1250 \text{ pg/ml}$ [RI 10–125]) confirmed an adrenal origin of the hypoadrenocorticism.⁵

The cat was diagnosed with PH, EPI, cobalamin deficiency and a suspected chronic enteropathy (CE); cobalamin deficiency was presumed to be secondary to EPI \pm the CE.

Prednisolone (0.5 mg/kg PO q24h [Prednicare; Animal Care]), cobalamin (0.5 mg PO q48h [Cobaloplex; Protexin Veterinary]), pancreatic enzymes (Panzym) and mirtazapine (2 mg PO q48h) were initiated. Despite the

cat being eunatraemic/eukalaemic, desoxycorticosterone pivalate (DOCP) (2.2 mg/kg SC q28d [Zycortal; Dechra Pharmaceuticals]) was initiated due to the documented hypoaldosteronism. Gastrointestinal tract biopsies were declined.

The cat's care was transferred to the primary care practice, and it responded positively with resolution of the vomiting/diarrhoea, appetite improvement and weight gain. At day 19, the previous biochemical abnormalities had resolved and the cat weighed 4.22 kg. Owing to cobalamin deficiency resolution ($>738 \text{ pmol/l}$) at day 40, supplementation was stopped, but hypcobalaminaemia (182 pmol/l) was documented on day 99 and long-term supplementation instituted. Electrolyte monitoring led to DOCP dose increases to a final dose of 2.8 mg/kg subcutaneously q28d at day 70. Weight gain plateaued at 4.5 kg. Owing to the cat being underweight and the lack of normalisation of appetite, the prednisolone dose was increased (0.75 mg/kg PO q24h) on day 70 from concern this was due to inadequate control of hypocortisolism \pm the CE.

On day 135, reassessment at the referral centre occurred due to a 2-month history of weight loss, polydipsia and worsening hyporexia. Haematology, biochemistry, cobalamin/folate assessment and urinalysis documented hyperglycaemia (22.9 mmol/l; RI 3.8–7.6) and glucosuria; fructosamine was increased (465 $\mu\text{mol/l}$; RI 220–360). Notable new abnormalities were not identified on repeat abdominal ultrasonography. The cat was diagnosed with DM and started on protamine zinc recombinant human insulin (1 IU SC q12h [ProZinc; Boehringer]); the prednisolone dose was reduced (0.5 mg/kg PO q24h). Reassessment on day 155 documented a marked improvement in the polydipsia, mild improvement in the hyporexia and weight gain. Fructosamine assessment (407 $\mu\text{mol/l}$) was consistent with good diabetic control; however, eACTH ($>1250 \text{ pg/ml}$) was supportive of inadequate glucocorticoid supplementation for the hypocortisolism and the prednisolone dose was increased (0.75 mg/kg PO q24h). On day 183, the cat's appetite had improved, and further weight gain was documented; fructosamine was 491 $\mu\text{mol/l}$. On day 248, eACTH (41.1 pg/ml) was consistent with appropriate glucocorticoid supplementation for the hypocortisolism. The cat then remained stable on treatment but had intermittent episodes of hyporexia and failed to return to its normal weight.

On day 294, the cat acutely vomited, collapsed and started seizing. It was presented to the primary care practice in status epilepticus; glucose and electrolyte imbalances were excluded as a cause of the signs and the owners elected for euthanasia. The cause was subsequently suspected to be toxin related. A post-mortem examination was performed and both adrenal glands, the pancreas and full-thickness biopsies of the duodenum, jejunum and ileum were submitted for histopathology.

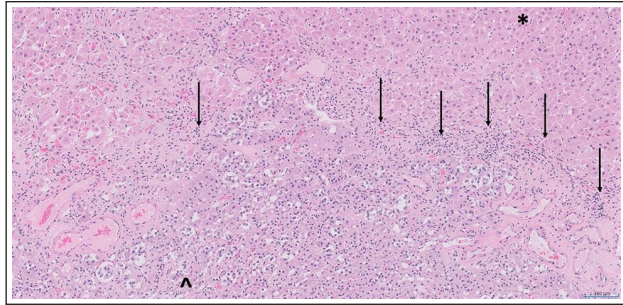


Figure 1 Histological section through one of the adrenal glands. The black arrows highlight the presence of inflammatory cell infiltrates within the parenchyma, predominantly comprising small lymphocytes with lower numbers of plasma cells (haematoxylin and eosin; $\times 100$ magnification). *Cortical parenchyma; ^medullary tissues

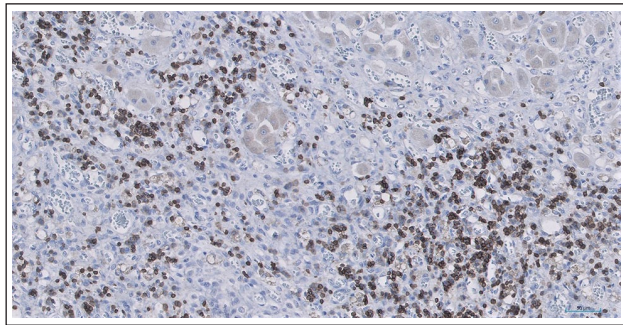


Figure 2 Immunohistochemical staining of the adrenal gland for the T-lymphocyte marker CD3. Strong positive cytoplasmic staining (brown) of the majority of the small lymphocytes within the inflammatory cell infiltrate is present (CD3, with haematoxylin counterstain; $\times 200$ magnification)

The length and width of the left and right adrenal glands were 7.18 mm \times 5.47 mm and 7.72 mm \times 5.88 mm, respectively. Histopathological assessment documented mild fibrous capsular thickening, with extension of fibrous stroma into the cortex. Both cortical and medullary tissues were present, confirmed by IHC staining for chromogranin A and synaptophysin. Sections of both adrenal glands contained low-to-moderate numbers of small lymphocytes and some plasma cells (Figure 1). IHC staining for T-cell (CD3) and B-cell (CD79a, Pax5) markers demonstrated the majority of lymphocytes to be T cells (Figure 2). Lymphoid neoplasia was excluded based on the number of T-cell lymphocytes, the lack of effacement of the adrenal glands from the lymphocytic infiltration and the evidence of fibrosis. The histopathological diagnosis was a T-cell-rich lymphoplasmacytic adrenalitis.

Pancreatic histopathology documented marked fibrous tissue infiltrates, within which were lymphoplasmacytic inflammatory cell infiltrates. The lymphocyte population

was mixed B and T cell on IHC. Congo Red staining for amyloid was negative.

Intestinal histopathology documented a diffuse mild chronic lymphoplasmacytic enteritis; the lymphocyte population was predominantly composed of T cells on IHC. However, inflammation was still perceived to be more likely than small-cell lymphoma, based on overall histological findings.^{13,14}

Discussion

This report documents the first case in which IHC has been performed on the adrenal glands in a cat with non-neoplastic-associated PH, providing further information on the pathogenesis of this disease in this species. The use of IHC has previously confirmed a T-cell-rich pan-hypophysitis, consistent with autoimmune disease, in a cat with secondary hypoadrenocorticism.¹⁵

Feline PH is also thought to occur secondary to autoimmune disease, resulting in a predominantly lymphocytic infiltration of the adrenal gland cortex, as recognised in dogs; however, neoplastic causes have also been documented.^{4,16} In the two PH cases in which adrenal histopathology was previously reported and which were not associated with neoplasia, one had adrenal cortical size reduction, cortical replacement with fibrosis and diffuse lymphocytic infiltration extending into the medulla; the other had complete adrenocortical destruction and atrophy.^{4,5} This is in comparison to cases secondary to adrenal lymphoma, in which mass lesions either encompassed or infiltrated the adrenal glands.¹⁶

In humans with autoimmune hypoadrenocorticism, lymphoplasmacytic adrenalitis is typically seen; the lymphocytic population is predominantly T cells and is responsible for the adrenocortical cellular destruction.¹⁷ Histopathological assessment in dogs with PH has also documented lymphoplasmacytic adrenalitis \pm adrenocortical atrophy, with the predominant lymphocyte population being CD4⁺ T cells, consistent with the association of canine hypoadrenocorticism and major histocompatibility complex class II genes.^{2,3} Additional support for autoimmunity is the presence of circulating autoantibodies against the P450 side-chain cleavage enzyme in 24% of cases; this has not yet been evaluated in cats.¹⁸

In our case, there was lymphoplasmacytic adrenalitis with the lymphocytic infiltrate being T-cell rich; however, adrenocortical atrophy was not identified. These findings provide further information regarding the lymphocyte population and deliver corroborative evidence to support non-neoplastic-associated PH being due to autoimmune disease in cats, confirming similarities with the canine disease.^{2,3} Ideally, further assessment of the T-cell lymphocyte population would have been performed with CD4⁺ and CD8⁺ markers.³ However,

these are not currently validated for use in cats in the UK and this remains an area for future research.

Multiple endocrinopathies can occur in dogs with hypoadrenocorticism, with concurrent hypothyroidism being most common, but DM is also reported, and similarities have been drawn to autoimmune polyendocrine syndrome type II in humans.^{6–10,19,20} However, neither histopathology of the endocrine organs nor serological testing for autoantibodies in these specific cases were performed to further assess this, and the autoimmune basis of canine DM has recently been drawn into question.^{21,22} Multiple endocrine disease in a cat including hypoadrenocorticism has not yet been reported.²³

In our case, DM developed subsequent to hypoadrenocorticism. In cats, DM is typically classified as type 2 (T2DM), and occurs secondary to decreased insulin secretion and the development of resistance to the actions of insulin on target tissues. Type 1 DM develops due to beta (β) cell destruction that is either idiopathic or due to cell-mediated autoimmune destruction, and is rarely reported.²¹ Pancreatic histopathology in T2DM is characterised by amyloid deposition within pancreatic islets and loss of β cells; mild lymphocytic infiltration can be seen in approximately 20% of cases.²⁴ Histopathological changes in cats with confirmed autoimmune pancreatitis have yet to be documented.^{25,26}

Although DM developed subsequently to prednisolone administration, T2DM was felt unlikely to be the predominant cause as this typically occurs in cats receiving higher prednisolone doses and there was no evidence of pancreatic amyloid deposition.^{24,27}

Owing to the histopathological changes, mixed lymphocytic inflammation and preceding EPI, chronic pancreatitis was the most likely cause of DM in this case.^{25,28} Although most cases of feline chronic pancreatitis are presumed to be idiopathic, response to immunosuppressive therapy in some cases is suggestive of autoimmune disease directed at the pancreas.²⁶ In English Cocker Spaniels, in which pancreatitis is presumed to be autoimmune, lymphocyte populations are predominantly CD3⁺ T lymphocytes, but there is additionally a concurrent population of CD79a⁺ B lymphocytes.²⁹ As such, although the lymphocyte infiltration in our case was mixed, as histopathological changes in cats with confirmed autoimmune pancreatitis have yet to be documented, we could not exclude an autoimmune cause of the cat's DM.^{25,26} Further work to assess whether similarities exist to humans and dogs with autoimmune pancreatitis is warranted.^{26,30}

Conclusions

To our knowledge, this is the first report of a cat with PH having a concurrent endocrinopathy, and it is also the first to report the results of adrenal gland IHC from

a cat with non-neoplastic-associated PH. The findings support the previously suspected autoimmune pathogenesis of non-neoplastic PH in cats.

Acknowledgements The authors would like to thank Georgia Lindley, the primary care practice veterinary surgeon who was involved in this case.

Conflict of interest The authors declared no potential conflicts of interest with respect to the research, authorship, and/or publication of this article.

Funding The authors received no financial support for the research, authorship, and/or publication of this article.

Ethical approval The work described in this manuscript involved the use of non-experimental (owned or unowned) animals. Established internationally recognised high standards ('best practice') of veterinary clinical care for the individual patient were always followed and/or this work involved the use of cadavers. Ethical approval from a committee was therefore not specifically required for publication in *JFMS Open Reports*. Although not required, where ethical approval was still obtained, it is stated in the manuscript.

Informed consent Informed consent (verbal or written) was obtained from the owner or legal custodian of all animal(s) described in this work (experimental or non-experimental animals, including cadavers) for all procedure(s) undertaken (prospective or retrospective studies). No animals or people are identifiable within this publication, and therefore additional informed consent for publication was not required.

ORCID iD Emma Roberts  <https://orcid.org/0000-0002-3157-9671>

References

- Adissu HA, Hamel-Jolette A and Foster RA. **Lymphocytic adenohipophysitis and adrenitis in a dog with adrenal and thyroid atrophy.** *Vet Pathol* 2010; 47: 1082–1085.
- Frank CB, Valentin SY, Scott-Moncrieff JCR, et al. **Correlation of inflammation with adrenocortical atrophy in canine adrenitis.** *J Comp Pathol* 2013; 149: 268–279.
- Friedenberg SG, Brown DL, Meurs KM, et al. **Lymphocyte subsets in the adrenal glands of dogs with primary hypoadrenocorticism.** *Vet Pathol* 2018; 55: 177–181.
- Johnessee JS, Peterson ME and Gilbertson SR. **Primary hypoadrenocorticism in a cat.** *J Am Vet Med Assoc* 1983; 183: 881–882.
- Peterson ME, Greco DS and Orth DN. **Primary hypoadrenocorticism in ten cats.** *J Vet Intern Med* 1989; 3: 55–58.
- Blois SL, Dickie E, Kruth SA, et al. **Multiple endocrine disease in dogs: 35 cases (1996–2009).** *J Am Vet Med Assoc* 2011; 238: 1616–1621.
- Cartwright JA, Stone J, Rick M, et al. **Polyglandular endocrinopathy type II (Schmidt's syndrome) in a Doberman Pinscher.** *J Small Anim Pract* 2016; 57: 491–494.
- Furukawa S, Meguri N, Koura K, et al. **A case of canine polyglandular deficiency syndrome with diabetes mellitus**

- and hypoadrenocorticism.** *Vet Sci* 2021; 8: 43. DOI: 10.3390/vetsci8030043.
- 9 Hwang SY, An JH, Lee JH, et al. **Autoimmune polyendocrine syndrome with hypoadrenocorticism and diabetes mellitus in a dog: a rare case.** *Vet Med Sci* 2021; 7: 2120–2123.
 10. Kuijlaars M, Yool DA and Ridyard AE. **Autoimmune polyendocrine syndrome in a standard poodle with concurrent non-endocrine immune-mediated diseases.** *Vet Rec Case Rep* 2021; 9: e90. DOI: 10.1002/vrc2.90.
 - 11 Gary AT, Kerl ME, Wiedmeyer CE, et al. **Bone marrow hypoplasia associated with fenbendazole administration in a dog.** *J Am Anim Hosp Assoc* 2004; 40: 224–229.
 - 12 Stokol T, Randolph JF, Nachbar S, et al. **Development of bone marrow toxicosis after albendazole administration in a dog and cat.** *J Am Vet Med Assoc* 1997; 210: 1753–1756.
 - 13 Washabau RJ, Day MJ, Willard MD, et al. **Endoscopic, biopsy, and histopathologic guidelines for the evaluation of gastrointestinal inflammation in companion animals.** *J Vet Intern Med* 2010; 24:10–26.
 - 14 Marsilio S, Ackermann MR, Lidbury JA, et al. **Results of histopathology, immunohistochemistry, and molecular clonality testing of small intestinal biopsy specimens from clinically healthy client-owned cats.** *J Vet Intern Med* 2019; 33: 551–558.
 - 15 Rudinsky AJ, Clark ES, Russell DS, et al. **Adrenal insufficiency secondary to lymphocytic panhypophysitis in a cat.** *Aust Vet J* 2015; 93: 327–331.
 - 16 Parnell NK, Powell LL, Hohenhaus AE, et al. **Hypoadrenocorticism as the primary manifestation of lymphoma in two cats.** *J Am Vet Med Assoc* 1999; 214: 1208–1211.
 - 17 Bratland E and Husebye ES. **Cellular immunity and immunopathology in autoimmune Addison's disease.** *Mol Cell Endocrinol* 2011; 336: 180–190.
 - 18 Boag AM, Christie MR, McLaughlin KA, et al. **A longitudinal study of autoantibodies against cytochrome P450 side-chain cleavage enzyme in dogs (*Canis lupus familiaris*) affected with hypoadrenocorticism (Addison's disease).** *Vet Immunol Immunopathol* 2018; 202: 41–45.
 - 19 Melendez LD, Greco DS, Turner JL, et al. **Concurrent hypoadrenocorticism and hypothyroidism in 10 dogs.** *J Vet Intern Med* 1996; 10: 182.
 - 20 Husebye ES, Anderson MS and Kämpe O. **Autoimmune polyendocrine syndromes.** *N Engl J Med* 2018; 378: 1132–1141.
 - 21 Gilor C, Niessen SJ, Furrow E, et al. **What's in a name? Classification of diabetes mellitus in veterinary medicine and why it matters.** *J Vet Intern Med* 2016; 30: 927–940.
 - 22 Gilor C, Pires J, Greathouse R, et al. **Loss of sympathetic innervation to islets of Langerhans in canine diabetes and pancreatitis is not associated with insulinitis.** *Sci Rep* 2020; 10: 19187. DOI: 10.1038/s41598-020-76091-5.
 - 23 Blois SL, Dickie EL, Kruth SA, et al. **Multiple endocrine diseases in cats: 15 cases (1997–2008).** *J Feline Med Surg* 2010; 12: 637–642.
 - 24 Zini E, Lunardi F, Zanetti R, et al. **Endocrine pancreas in cats with diabetes mellitus.** *Vet Pathol* 2016; 53: 136–144.
 - 25 De Cock HE, Forman MA, Farver TB, et al. **Prevalence and histopathologic characteristics of pancreatitis in cats.** *Vet Pathol* 2007; 44: 39–49.
 - 26 Forman MA, Steiner JM, Armstrong PJ, et al. **ACVIM consensus statement on pancreatitis in cats.** *J Vet Intern Med* 2021; 35: 703–723.
 - 27 Nerhagen S, Moberg HL, Boge GS, et al. **Prednisolone-induced diabetes mellitus in the cat: a historical cohort.** *J Feline Med Surg* 2021; 23: 175–180.
 - 28 Xenoulis PG, Zoran DL, Fosgate GT, et al. **Feline exocrine pancreatic insufficiency: a retrospective study of 150 cases.** *J Vet Intern Med* 2016; 30: 1790–1797.
 - 29 Watson PJ, Roulois A, Scase T, et al. **Characterization of chronic pancreatitis in English Cocker Spaniels.** *J Vet Intern Med* 2011; 25: 797–804.
 - 30 Coddou MF, Constantino-Casas F, Scase T, et al. **Chronic inflammatory disease in the pancreas, kidney and salivary glands of English cocker spaniels and dogs of other breeds shows similar histological features to human IgG4-related disease.** *J Comp Pathol* 2020; 177: 18–33.